

RENAL CELL CARCINOMA WITH OSSEOUS METAPLASIA OCCURRING IN A CONTRACTED KIDNEY - A RARE CASE REPORT

Harish S. Permi

Associate Professor, Department of Pathology, K S Hegde Medical Academy
Nitte University, Deralakatte, Mangalore 575018

Correspondence:

Harish S. Permi

Associate Professor, Department of Pathology, K.S. Hegde Medical Academy,
Nitte University, Deralakatte, Mangalore - 575 018

Mobile : +91 99641 31827 E-mail : drharish01@gmail.com

Abstract :

Osseous metaplasia is a rare histologic feature associated with renal cell carcinoma, occurring in a contracted kidney is still rarer. Metaplastic bone formation within the renal tumor gives an appearance similar to that of calcification. It is difficult to distinguish between bone formation and calcification on the basis of radiological imaging alone. Prognostic significance of metaplastic bone formation in renal cell carcinoma is not clear, however some report suggest good prognosis as a result of limitation of tumor spread by bone formation. This case report highlights the occurrence of renal cell carcinoma with osseous metaplasia in a contracted kidney.

Keywords : Renal cell carcinoma, Osseous, Metaplasia. Contracted kidney.

Introduction :

Renal cell carcinoma (RCC) may have calcifications within them. Heterotopic bone formation by ossification inside the renal tumor gives an appearance similar to that of calcification.^[1] Renal cell carcinoma accounts for 2% of total human cancers and the clear cell variant represents the most common histological subtype. All variants of RCC may exhibit necrosis and hemorrhage. Other degenerative changes that can be seen are edema, fibrosis, cholesterol clefts and calcification. Osseous metaplasia in RCC is, however a rare phenomena.^[2] A rare case report of renal cell carcinoma with osseous metaplasia in a contracted kidney occurring in a 38 year old male who presented with recurrent painless hematuria is presented here.

Case Report :

A 62-year-old male, presented with intermittent painless hematuria since 2 months.

Urine analysis showed hematuria and proteinuria. Haematological and biochemical investigations were within normal limits. Ultrasonography (USG) of abdomen showed a mass in

the right contracted kidney. Computerized tomography (CT) of abdomen revealed a heterogeneously enhancing mass measuring 2 x1.5 cm with calcification located in the upper pole of right contracted kidney. Right nephrectomy was done and specimen sent for histopathological examination. Grossly kidney measured 5.5x4x3 cms. Outer surface showed irregular scarring. Cut section revealed an ill-circumscribed grey tan cystic growth with areas of hemorrhage and necrosis, occupying the upper pole measuring 2x2 cm with focal hard areas which were gritty to cut. Microscopy showed renal cell carcinoma with areas of bony trabeculae and adipose tissue suggesting metaplastic bone formation. [Figure 1] Sections from surrounding renal parenchyma showed chronic pyelonephritis. Fuhrman nuclear grade was grade 2. Gerotas fascia was free from tumor. He is on regular follow with free of symptoms and recurrence.

Discussion :

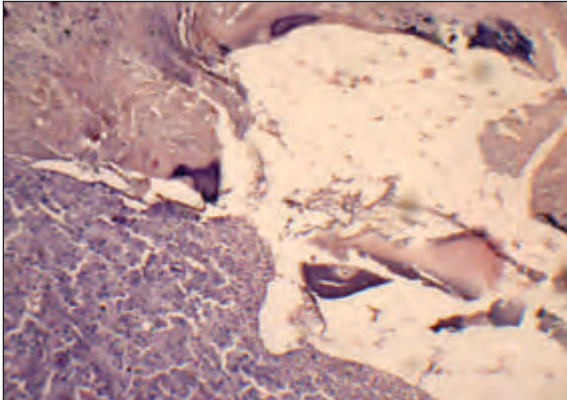
Osseous metaplasia opposed to calcification is a rare finding. It has been demonstrated in several other tumors, including primary and metastatic colorectal carcinomas predominantly in mucinous tumors, benign rectal polyps, endometrioid carcinoma of the fallopian tube, malignant melanoma, breast carcinoma, hepatocellular carcinoma,

Access this article online

Quick Response Code



Figure 1 : Microscopy showing renal cell carcinoma with bony trabeculae and adipose tissue. (Hematoxylin and Eosin X 100)



amyloid tumors of the breast and tonsil, fibrous histiocytoma and perineuroma [3]. The pathogenesis of ossification in tumors is not clear. Several hypotheses have been put forward, including the production of bone by tumor cells secondary to ischemia, necrosis or inflammation in the tumor or surrounding tissue, reparative responses in the tumor or surrounding tissues or the ossification of pre existing mucin or calcification foci. A recent study has shown, Bone morphogenetic protein 2

(BMP2) to inhibit tumor growth of RCC and induce bone formation. [4] In our case there was pre-existing chronic pyelonephritis with occurrence of renal cell carcinoma which possibly suggests pathogenesis of osseous metaplasia. The prognostic significance of osseous metaplasia in RCC is debatable. Some reports show ossification to be a favourable prognostic factor with tumors having a low nuclear grade, low stage and absence of metastatic disease at presentation [5]. However, some reports suggest that ossification can also be associated with high grade tumors and poor prognosis. [6] Our case had a favourable prognosis due to low nuclear grade, early stage and absence of metastasis at presentation and no recurrence on follow up.

Conclusion :

Renal cell carcinoma with osseous metaplasia in a contracted kidney due to chronic pyelonephritis is a rare finding. It has a favourable prognosis with limitation of tumor spread. Chronic pyelonephritis possibly plays a role in pathogenesis of metaplastic bone formation.

References

1. Singh V, Sinha RJ, Sankhwar SN, Dalela D. Heterotopic bone formation in renal cell carcinoma: A diagnostic challenge. *Indian J Can* 2008; 45:126-127.
2. Divya Kriplani, Priti P Trivedi, Manoj J Shah. Renal cell carcinoma with osseous metaplasia. *Journal of case reports* 2013;3:165-168.
3. Cribbs RK, Ishaq M, Arnold M, O'Brien J, Lamb J, Frankel WL. Renal Cell Carcinoma with massive osseous metaplasia and bone marrow elements. *Ann Diagn Pathol*. 1999; 3:294-299.
4. Wang L, Park P, Zhang H, La Marca F. Bone morphogenetic protein 2 inhibits tumor growth of human renal cell carcinomas and induces bone formation. *Int J Cancer* 2012; 131:1941-1950.
5. Hartman RJ, Helfand BT, Dalton DP. Clear cell renal cell carcinoma with osseous metaplasia: a case report. *Can J Uro* 2011; 18:5564-5567.
6. Bielsa. O, J. Loreta, O. Arango, S. Serrano, A. Gilbert-Mas. Bone metaplasia in a case of bilateral renal cell carcinoma. *Urol Int* 2001; 66:55-56.