

Case Report

FEMALE PATIENT WITH A VARIANT OF TURNER SYNDROME

Meenakshi A.¹, Prashanth Shetty², Suchetha Kumari³, Jayarama Kadandale⁴, Neetha Nandan⁵

¹Research Associate & Lecturer, ²Professor & Co-ordinator, ³Professor, ⁴E-Consultant, Diagnostic centre for Cytogenetics & Molecular Genetics, ⁵Associate Professor, Department of Obstetrics & Gynecology, K.S. Hegde Medical Academy, Nitte University, Mangalore - 575 018, India.

Correspondence :

Meenakshi A.

Research Associate/Lecturer, Diagnostic centre for Cytogenetics & Molecular genetics,
K.S. Hegde Medical Academy, Nitte University, Mangalore - 575 018, India.

Mobile: +91 78294 18612 E-mail : meenakshi@nitte.edu.in

Abstract:

The X chromosome contains determinants necessary to assure normal structural growth. Deletions of proportions of the X chromosome have been reported in a huge number of patients. We report on a mosaic short arm deletion of X chromosome (Xp-) in 14-years-old female patient with short stature, low set ears and no secondary sexual characteristics, a rare Turner syndrome variant. Chromosomal analysis using GTG-banding showed in 85% of cells and 46,X,del(Xp) in 15% of cells. The Fluorescence *in situ* hybridization technique of the cultured cells helped to perceive low grade cell line. Hence, molecular cytogenetics methods are essential to detect low level mosaicism which is important in better counseling.

Keywords : Chromosomal analysis; sex chromosome; Fluorescence *in situ* hybridization; molecular cytogenetics

Introduction :

Turner syndrome is the most common sex chromosomal abnormality in phenotypic females, and results from loss or abnormality of the second X chromosome. The most common karyotype of Turner syndrome is 45,X0 in 80% of affected females and approximately the remaining 20% may have some variants on the second X chromosome such as an isochromosome of the long arm, ring chromosome or else small short-arm deletions or interstitial long-arm deletions [1].

The incidence of Turner syndrome is estimated to occurs in 1 in 2000 to 1 in 5000 live births [2]. The main characteristics of this disorder are short stature, gonadal dysgenesis, primary amenorrhea, decreased fertility, a webbed neck, widely spaced nipples, a broad chest and anomalies of cardiac, renal and endocrine origin [1,3].

We present a female patient who carries a k a r y o t y p e mos45,X[17]/46,X,del(Xp) [3], a variant of Turner Syndrome, with some of the typical phenotype.

Case presentation:

A 14-year-old girl was referred to our cytogenetic laboratory for the reason that short stature, low set ears, webbed neck and no secondary sexual characteristics from department of obstetrics and Gynecology, K S Hegde Hospital, Mangalore. She was second born by cesarean at 40 weeks of gestation to a non-consanguineous parents the mother and father being 40 and 48 year-old respectively. Clinical examination revealed that her height was 133 cm, weight 41 kg. She had absence of secondary sexual characters, lack of axillary and pubic hair, and under developed breast (Tanner stage - I). Ultrasonography findings of pelvic organs revealed 3.8 X 0.6cms uterus, ovaries were not visualized, no adnexal masses and no free fluid noted. She has normal urinary bladder and Gall bladder, absent calculus and neoplasm. The follicular stimulating hormone (FSH) level was very high (80mIU/ml) compared to normal females (FSH-0-13mIU/ml).

Proband has 19 years elder sister with normal phenotype, she attained menarche and getting regular periods. Both of her parents were phenotypically normal. Other illness, genetic disorders, mental retardation has never occurred in the family.

Access this article online

Quick Response Code



Conventional cytogenetic analysis

Metaphase cells were obtained from PHA (Phytohemagglutinin) stimulated peripheral blood lymphocytes following standard protocols. Slides were stained by conventional Giemsa-Trypsin-Giemsa banding (GTG) technique and 20 well spread metaphases were analyzed microscopically. The chromosome analysis of the patient revealed mos45,X[17]/46,X,del(Xp)[3] (Figure 1) karyotype according to the International System for Human Cytogenetic Nomenclature (ISCN). The result described 85% of the cells has 45,X and 15% of the cell has 46,X,del(Xp).

Detection of mosaicism depends on the proportion of cells present from the additional cell lineages. In routine karyotyping, 20 cells are counted, since this number is sufficient to detect mosaicism at a level of about 5 percent. In this present case we got the second cell line more than 5 percent, even though, we decided to proceed with the FISH (Fluorescence *in situ* Hybridization) study to score additional number of cells and disclose exact mosaic pattern.

Fluorescence in situ hybridization (FISH) Analysis:

FISH analysis was performed on the same peripheral blood samples harvested for cytogenetic analysis to detect exact mosaicism. 10µl of dual-colour CEP X (Spectrum Green) and CEP Y (Spectrum Orange) probe (Vysis, USA) was applied to the sample, covered with cover slips and sealed with rubber cement. The sample and probe were co-denatured and hybridized using the ThermoBrite Denaturation/Hybridization System. The ThermoBrite unit was programmed to allow 5 minutes of denaturation at 73°C, followed by overnight hybridization at 37°C. Post hybridization wash was performed in 0.4X SSC/0.1% NP-40 at 72°C for 2 minutes) followed by a wash in 2X SSC/0.1% NP-40 at room temperature for 1 minute. The slides were air dried in the dark, then added 10µl of DAPI (4,6-diamidino-2-phenylindole) counter stain. The FISH signals were visualized using Vysis filter sets and an Olympus BX51 fluorescence microscope attached to a FISH View image acquisition and analysis system for FISH (GENASIS, Applied

Spectral Imaging, Germany).

We scored 200 interphase nuclei, among this 81% of the cells shown single green signal for X chromosome and remaining 19% of the cells shown two green signals, which authenticate the presence of second abnormal cell line 46,X,del(Xp). In addition, FISH study confirms there is no presence of Y chromosome. The final karyotype was given based on a combination of FISH analysis as well as conventional karyotyping.

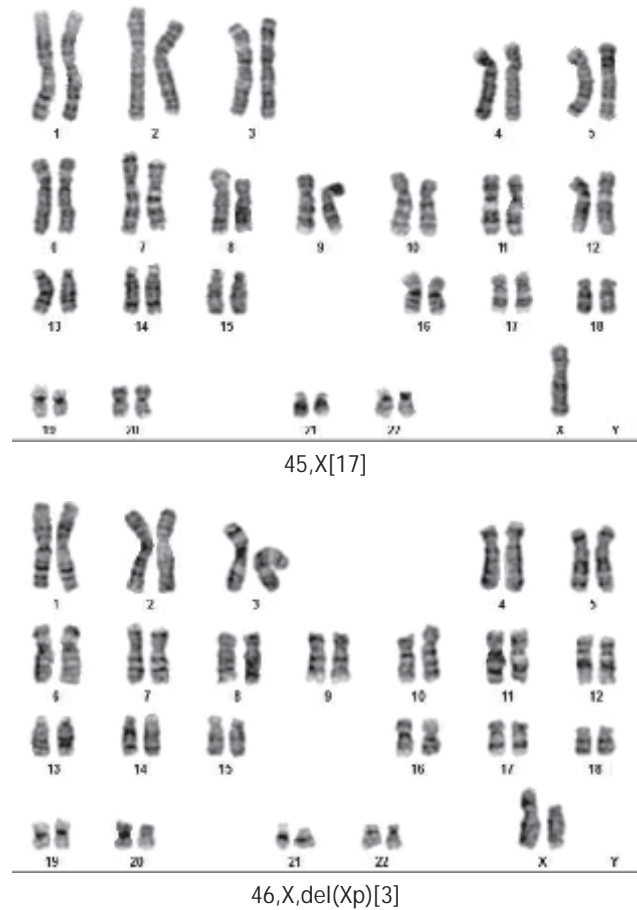


Figure 1: GTG-banded karyogram of the patient with variant Turner syndrome. 17 cells showed a 45,X karyotype and the remaining 3 cells showed deletion Xp.

Discussion:

Turner syndrome variants include female individuals with partial deletions in the “p” and/or “q” arms of one X chromosome. The deletions of certain X chromosome regions/genes can lead to specific phenotypic features which are characteristic of “full” or “classic” Turner syndrome and also deletions of the *SHOX* gene, located in

the PAR (pseudo autosomal region) at Xp22.33, are associated with short stature [4]. Most women with Xp deletion are short, apart from their ovarian function indicating that other structural determinant genes probably lie within these Xp regions [5]. Short stature was localized to a much smaller region midway within this general area between Xp11.2 to Xp22.1. In our case, patient has these characteristic Turner syndrome features might be due to loss of entire "p" arm of X chromosome.

If the status of ovarian function in adolescence is unclear, measurement of follicle-stimulating hormone, luteinizing hormone, and estradiol levels can help to determine the need for hormone-replacement therapy (HRT). Hormone-replacement therapy should be initiated at the age of about 14 years. Earlier treatment may result in a decrement in final height. Psychosocial issues and the patient's maturity and wishes also need to be considered.

The molecular mechanisms (s) responsible for gonadal failure with X chromosome deletions could involve the loss of putative ovarian determinant gene(s) necessary to be present in two copies during ovarian development. Deletions on X chromosome have been reported in a large number of patients. Deletion Xp11 region result in ovarian failure with menstrual function, even in those with normal menstruation, fertility is very rare [5].

Structural abnormalities of X chromosome variant were more common than the classic 45,X/46,XX karyotype all over the prior studies [6]. Among children with TS, those with less X-chromosome material appear to be more severely affected, especially if they lose paternal X-chromosome material [7]. The age of the parents should not be associated with the formation of structural variants and monosomic X chromosome patients (XO) show less expression than those patients who have additional Xq copies [1]. One author described that frequency of physical abnormalities in Turner syndrome vary with the pattern of karyotype, features and majority are not karyotyped until after the age of 11, usually due to the failure of puberty and he was concerned about the delay of diagnosis [8]. Our patient also diagnosed lately at the age of 14.

A region on Xp11.4 has been proposed as critical for the development of lymphedema. Evidence of fetal lymphedema is manifest as neck webbing, malrotation of ears and low posterior hair line. In our case webbing of neck and low set ears would have been noticed prenatally and diagnosed as early as possible. The prevalence of congenital heart disease among patients with Turner syndrome ranges from 17–45% with no clear phenotype genotype correlations [9]. Congenital cardiac defect and renal malformations are consistently reported in Turner syndrome, with the benevolent conditions of horse shoe kidney and duplex collecting systems being most common [2]. Even though our patient clinical information does not show any risk of congenital heart defect and renal anomalies, we are requesting the clinician to take special consideration to scrutinize blood pressure for the evaluation of cardiac anomalies.

The size of Xp deletions and corresponding genes are more severe in patients with Xp deletion, short neck was more common among them [10]. Approximately 70% of patient with turner syndrome have learning disabilities affecting nonverbal perceptual motor and visuospatial skills, a meta-analysis of 13 studies identified deficits in visuospatial organization, social cognition, nonverbal problem-solving and psychomotor functioning in patients [9]. Several studies of Joanne Rovers have examined the specific mathematics difficulties in females with multidigit addition and subtraction problems, while geometry and the ability to deal with symbols were less disturbed. Our patient also have specific problem with number work, mathematics and spatial tasks and it may be helpful to make teachers aware of this in case extra support like tutoring is needed. However many go on to further or higher education and enjoy full range of job opportunities.

Conclusion :

Turner syndromes represent a condition with both genetic and hormonal determinants that contribute to severe mathematics impairments. Early recognition of Turner syndrome and timely investigations should be helpful in improving the quality of these individuals by potentially

improving the adult height in those who respond to growth hormone therapy and in initiating sex hormone replacement. Also, early detection and management of co-existing illnesses may be life saving for these patients. Physicians should discuss infertility issues and reproductive options with their patients and reassure them about their sexual function. It is important to acknowledge the sense of loss associated with infertility, on the part of both the patient and parents. We conclude for this study that the karyotyping is definitely helpful in the evaluation

of short stature and FISH study is essential to detect low level mosaicism with normal X chromosomes in such patients for the appropriate counseling.

Acknowledgement:

The authors wish to thank the patient and her parents for providing the sample and personal information. Written informed consent was obtained from the patient. The authors are grateful to Mrs. Vani Shetty for her valuable technical help.

References:

1. Christalena S, Eirini T, Olga F, Despina M, Helen F. Iridocyclitis in a Female Patient with a Variant of Turner Syndrome. *J Genet Syndr Gene Ther.* 2013; Volume 4, Issue 10.1000196. <http://dx.doi.org/10.4172/2157-7412.1000196>
2. Bondy CA. New Issues in the Diagnosis and Management of Turner Syndrome. *Reviews in Endocrine & Metabolic Disorders.* 2005; 6:269-280.
3. Ramachandram S, Keng WT, Ariffin R, Ganesan V. A mother with variant Turner syndrome and two daughters with trisomy X: a case report. *Journal of Genetics.* 2013; Vol. 92, No. 2.
4. Mazzaschi LP, Taylor J, Robertson SP, Love DR, George AM. A Turner Syndrome Patient Carrying a Mosaic Distal X Chromosome Marker. *Hindawi Publishing Corporation Case Reports in Genetics.* 2014; <http://dx.doi.org/10.1155/2014/597314>
5. Vundinti BR, Kerketta L, Korgaonkar S, Ghosh K, Mohanty D. Molecular Cytogenetic Evaluation of Xq Deletion Mosaicism in a Case of Primary Amenorrhea. *Int J Hum Genet.* 2004; 4(1): 75-76.
6. Bharath R, Unnikrishnan AG, Thampy MV, Anilkumar A, Nisha B, Praveen VP, Nair V, Jayakumar RV, Harish Kumar., Turner Syndrome and its Variants. *Indian Journal of Pediatrics.* 2010; Volume 77, DOI-10.1007/s12098-009-0226-7
7. Rovet J. Turner Syndrome: Genetic and Hormonal Factors Contributing to a Specific Learning Disability Profile. *Learning Disabilities Research & Practice.* 2004; 19(3), 133-145.
8. Chander NV, Ahmed EF. Turner's Syndrome Variant with Three Cell Line Mosaicism and Ring X Chromosome (45, X /46, X r(X)(p21 q25)/46, Xx) in A Saudi Patient. *Bahrain Medical Bulletin.* 2001; Vol.23, No. 1.
9. Sybert VP and McCauley E. Turner's Syndrome. *N Engl J Med.* 2004; 351:1227-38.
10. Ogata T, Muroya K, Matsuo N, Shinohara O, Yorifuji T, Nishi Y, Hasegawa Y, Horikawa R, Tachibana K. Turner Syndrome and Xp Deletions: Clinical and Molecular Studies in 47 Patients. *The Journal of Clinical Endocrinology & Metabolism.* 2001; 86(11):5498-5508.