



# Clival Meningioma Removal through a Suboccipital Retrosigmoid Approach: Operative Video and Technical Nuances

Carlos Candanedo<sup>1</sup> Samuel Moscovici<sup>1</sup> Sergey Spektor<sup>1</sup>

<sup>1</sup> Department of Neurosurgery, Hadassah-Hebrew University Medical Center, Jerusalem, Israel

**Address for correspondence** Carlos Candanedo, MD, Department of Neurosurgery, Hadassah-Hebrew University Medical Center, PO Box 12000 Jerusalem, Israel, 91120 (e-mail: ccandanedomd@hotmail.com).

J Neurol Surg B 2021;82(suppl S1):S27–S28.

## Abstract

**Background** Clival meningiomas are challenging lesions that need to be managed according to the displacement of the adjacent structures. Lateral skull base approaches are needed to achieve their radical removal; however, they are associated with significant morbidity, especially when the tumor involves the basilar artery, its perforators, brainstem, and lower cranial nerves.

**Design** This is a case of a 79-year-old female patient, diagnosed with a large lower clival meningioma after suffering from headaches. It was offered a conservative treatment but on serial MRI, an increase in the meningioma's size was observed, so it was decided to remove the meningioma using a left suboccipital retrosigmoid approach.

**Settings** On a left three-quarter prone position, with facial nerve, auditory brainstem response, lower cranial nerves, and motor-evoked potentials and somatosensory-evoked potentials neurophysiologic monitoring, a right suboccipital retrosigmoid craniotomy with opening of the foramen magnum was performed, giving enough lateral visualization of the tumor. Broad base tumor pushing backward and aside the vertebral and basilar arteries, cranial nerves (7th–12th), and the brainstem was exposed and removed.

**Results** Near total resection of the meningioma was achieved, leaving a microscopic residual in the entry points of the low cranial nerves without complications. There was no neurological deficit after the surgery. Postoperative MRI revealed no signs of residual tumor.

**Conclusion:** In this case, the regular retrosigmoid approach, extended into the foramen magnum was enough for the removal of this pure clival meningioma.

The link to the video can be found at: <https://youtu.be/3d6Uj4gjmDU>.

## Keywords

- ▶ clival meningioma
- ▶ retrosigmoid approach
- ▶ foramen magnum
- ▶ operative video
- ▶ low cranial nerves



## Conflict of Interest

None declared.

[www.thieme.com/skullbasevideos](http://www.thieme.com/skullbasevideos)

[www.thieme.com/jnlsbvideos](http://www.thieme.com/jnlsbvideos)

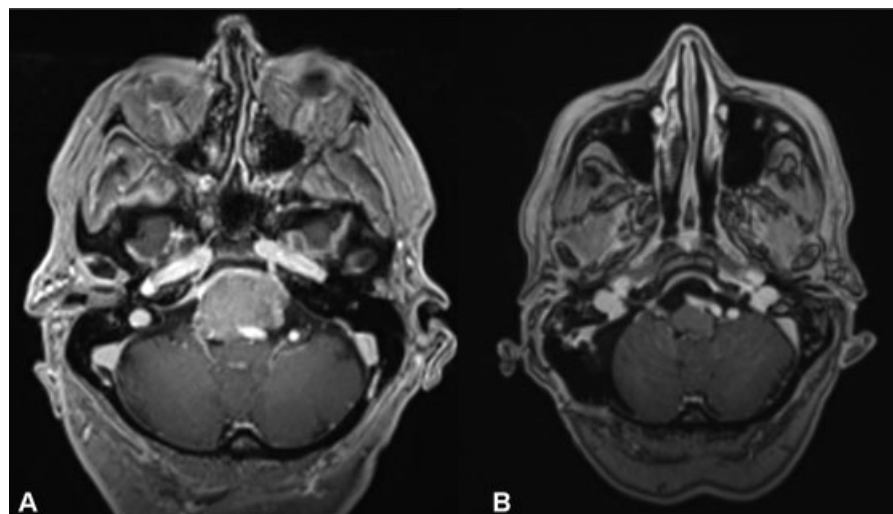
received  
March 31, 2019  
accepted after revision  
January 4, 2020  
published online  
November 17, 2020

DOI <https://doi.org/10.1055/s-0040-1705163>.  
ISSN 2193-6331.

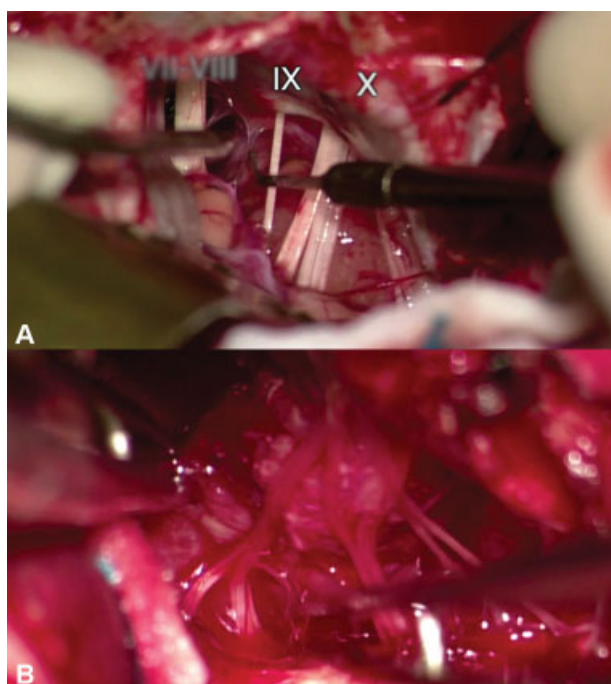
© 2020. The Author(s).

This is an open access article published by Thieme under the terms of the Creative Commons Attribution-NonDerivative-NonCommercial-License, permitting copying and reproduction so long as the original work is given appropriate credit. Contents may not be used for commercial purposes, or adapted, remixed, transformed or built upon. (<https://creativecommons.org/licenses/by-nc-nd/4.0/>)

Georg Thieme Verlag KG, Rüdigerstraße 14, 70469 Stuttgart, Germany



**Fig. 1** Pre- and Postoperative magnetic resonance imaging (MRI). (A) Preoperative Axial T1-weighted gadolinium-enhanced MRI showing a large clival meningioma involving the vertebrobasilar complex. (B) postoperative axial T1-weighted gadolinium-enhanced MRI showing no signs of tumor residual.



**Fig. 2** Intraoperative imaging. (A) Intraoperative view showing the view giving by the retrosigmoid approach. (B) View showing the tumor involving the low cranial nerve.