Article published online: 2020-04-02

Horizontal Intraarticular Dislocation of the Patella: Case Report*

Luxação intra-articular horizontal da patela: Relato de caso

Saulo Fouani de Miranda[1] Fabiano Kupczik[1] Marlus Eduardo Gunia Schiavon[1] Bruno Sbrissia[1] Gustavo Yuiti Kaneko Suzuki[1]

[1] Orthopedics and Traumatology Service, Hospital Universitário Cajuru, Curitiba, PR, Brazil

Rev Bras Ortop 2020;55(6):800–803.

Address for correspondence Saulo Fouani de Miranda, MD, Rua dos Gerânios, 718, Maringá, PR, 87060158, Brazil (e-mail: s_fm@hotmail.com).

Abstract

Intraarticular dislocation of the patella is an uncommon condition, with displacement in the horizontal or vertical plane, which may be associated with total or partial lesion/rupture of the quadriceps tendon, with osteochondral or collateral ligament injury. Risk factors are ligament laxity, patellar hypermobility, high patella, and trochlear dysplasia. This condition is more common in young people and may require blood reduction. Cases of intraarticular dislocation of the patella are rare events, requiring diagnostic suspicion and differentiated management. The aim of the present study is to report a rare case of intraarticular dislocation of the patella, as well as its clinical condition, diagnosis, management and literature review.

Keywords
- patella
- knee joint
- patellar dislocation

Resumo

Luxação intra-articular da patela é uma afecção incomum, podendo ocorrer deslocamento no plano horizontal ou vertical; pode se associar com lesão/ruptura do tendão do quadríceps, total ou parcial, com lesão osteocondral ou dos ligamentos colaterais. Fatores de risco são: frouxidão ligamentar, hipermobilidade patelar, patela alta e displasia troclear, e é mais comum em jovens, podendo necessitar de redução cruenta. Casos de luxação intra-articular da patela são eventos raros, sendo necessários uma suspeição diagnóstica e um manejo diferenciado. O objetivo deste trabalho é relatar um caso raro de luxação intra-articular da patela, assim como seu quadro clínico, diagnóstico, conduta e revisão da literatura.

Palavras-chave
- patela
- articulação do joelho
- luxação patelar

Introduction

Patellar dislocation is an emergency with an annual incidence of 5.8 per 100,000 individuals. It most commonly affects adolescents aged between 10 and 17 years who play sports.[1] The most common type of dislocation is lateral, with rare cases of dislocation of the intraarticular patella. In horizontal dislocation, which is the most common, the patella rotates on its horizontal axis, leaving its articular surface facing upwards or downwards, and in vertical dislocation, the patella rotates and the articular surface faces medial or lateral.[2] We describe an unusual case of horizontal intraarticular dislocation of the patella in an elderly patient.

* Work developed at the Knee Surgery Group, Orthopedics and Traumatology Service of the Hospital Universitário Cajuru, Curitiba, PR, Brazil.

received September 1, 2019
accepted December 12, 2019

DOI https://doi.org/10.1055/s-0040-1708516.
ISSN 0102-3616.

Copyright © 2020 by Sociedade Brasileira de Ortopedia e Traumatologia. Published by Thieme Revinter Publicações Ltda, Rio de Janeiro, Brazil

License terms

Fig. 1 Clinical examination of admission.

Case Report

A 68-year-old woman sought assistance due to a right knee trauma after falling from the same level. At the time of the accident, the patient reported to have performed a hyperflexion of the right lower limb, and hyperextension of the left lower limb. When trying to get up, she noticed a deformity in her right knee with limited flexion-extension, in addition to pain and functional limitation to walk.

On admission, she had pain and swelling in her right knee, as well as a gap in the supra-patellar region, keeping the joint flexed at 40°. (►**Fig. 1**). The active and passive extensions were limited, and it was possible to palpate the intercondylar region of the right femur, with difficulty in palpation of the upper pole of the patella.

Anteroposterior and lateral radiographs of the right knee showed a low patella, with the articular surface in contact with the intercondylar space of the femur, suggesting an intraarticular dislocation with an articular to distal/inferior face (►**Fig. 2**). As a complementary investigation, a computed tomography was performed with 3D bone and soft-tissue reconstruction that did not show fractures, and initially ruled out injuries to the extensor mechanism, with only one image showing a suspected partial injury to the fibers of the lateral retinaculum (►**Fig. 3**). A magnetic resonance imaging (MRI) of the right knee also confirmed the integrity of the patellar and quadriceps tendons (►**Fig. 4**).

Fig. 2 Initial radiographs of the right knee.

The attempted manipulation to reduce dislocation in the emergency room failed, even after analgesia with 5 mg of intravenous morphine. It was decided to take the patient to the operating room to perform a reduction under sedation, which was easily performed with a progressive extension mechanism with manipulation of the lower pole of the patella. In the sequence, the stability of the joint was tested through dynamic flexion-extension, which proved to be stable, but with bumps and crackles during the extension. The patient was maintained with an inguinal-malleolar plaster cast immobilization. The postreduction radiography showed a topical view, with signs suggestive of advanced osteoarthritis of the patellofemoral compartment and osteochondral lesion (►**Fig. 5**).

The postreduction physical examination showed a preserved right knee extensor mechanism. We opted for MRI of the right knee as a means of further investigation and registration of the case, which did not show rupture of the quadriceps tendon.

The treatment was maintained with immobilization with an inguinal-malleolar orthosis, with limb weight-bearing restriction, analgesia, cryotherapy and outpatient follow-up for rehabilitation.

Discussion

Intraarticular dislocation of the patella is an uncommon condition, and displacement may occur in the horizontal or vertical plane.[3] The first occurs after right trauma with rotation of the patella around its horizontal axis, with the articular surface facing upwards or downwards, there is an internal rotation of the femur in relation to the tibia, with a fast flexion movement and external rotation of the femur, and a constant force on the upper pole of the patella which causes it to move to the intercondylar fossa.[4] It can be associated with injury/rupture of the quadriceps tendon, which can be total or partial, with osteochondral or collateral ligament injury, requiring a complementary imaging test, such as an MRI, for diagnostic confirmation.[4,5]

The second type is more unusual, with few cases described in the literature. The most common trauma mechanism is major valgus stress with the knee in extension associated with internal tibial rotation.[2] The articular surface of the patella may be facing medial or lateral.[5] The lesion with deviation from the upper pole of the patella to the intraarticular region is six times more frequent than the deviation from the lower region.[6]

The literature shows that this type of dislocation occurs more frequently in adolescents up to 16 years old, being uncommon in the elderly.[7–9] Other associated risk factors are ligament laxity, patellar hypermobility, high patella, and trochlear dysplasia. Elderly people who have degenerative changes due to comorbidities, such as rheumatoid arthritis, diabetes mellitus, chronic kidney disease, and chronic use of

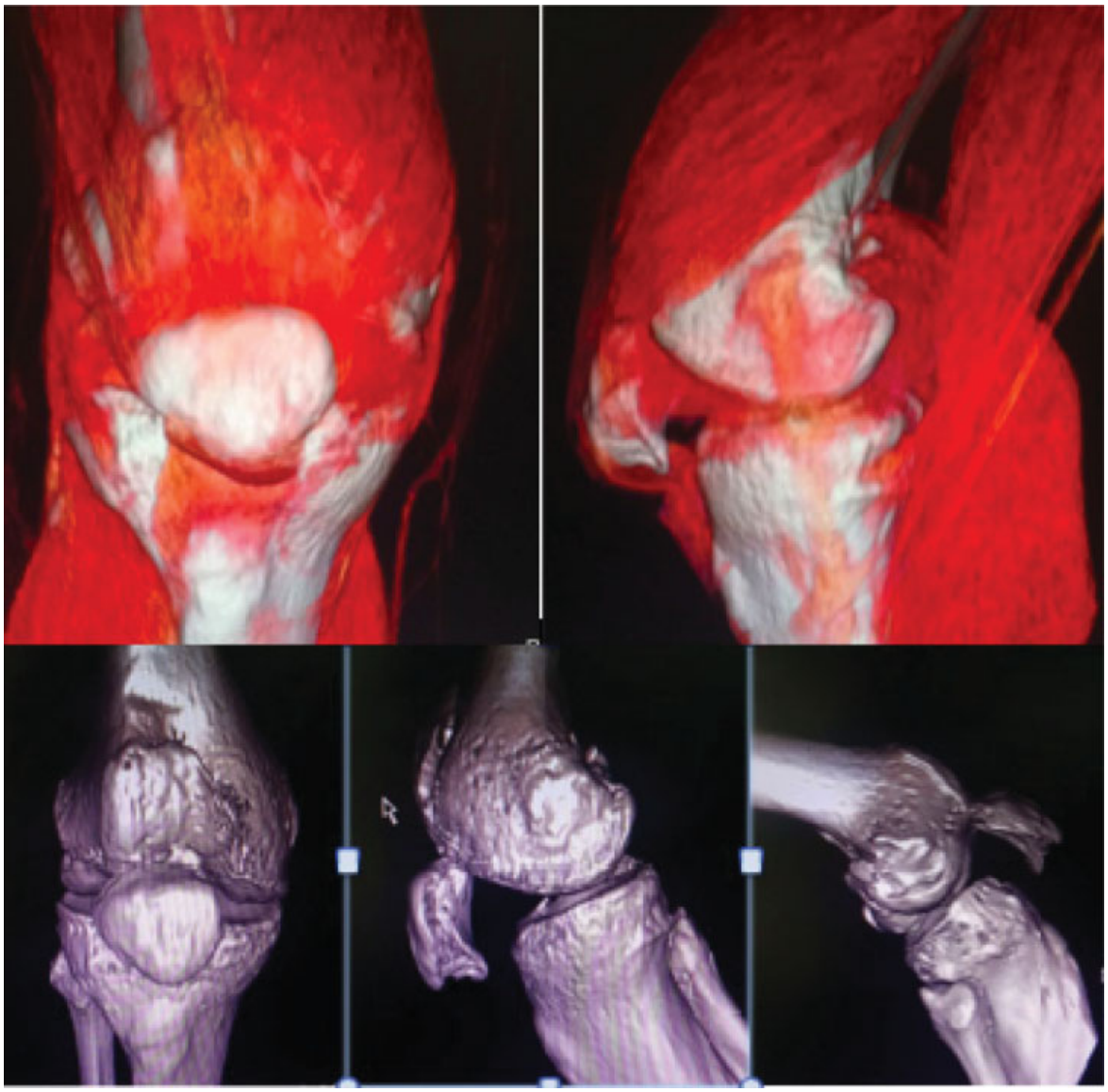

Fig. 3 Bone and soft tissue reconstruction - right knee.

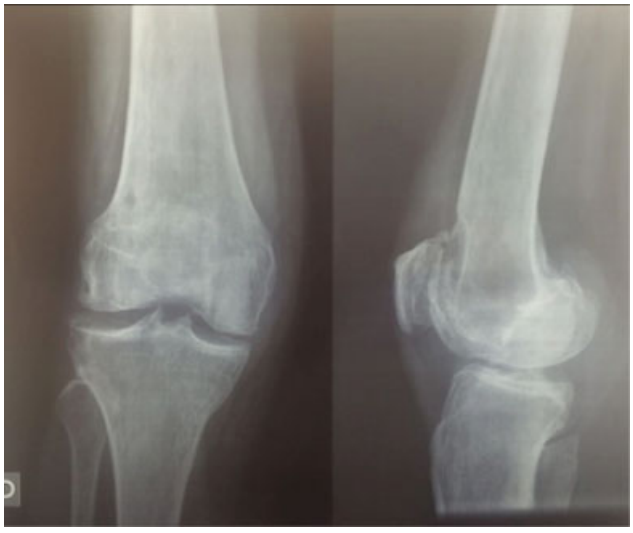

Fig. 4 Post-reduction control radiographs.

corticosteroids, which are associated with weakening or rupture of the quadriceps, are also more susceptible to this pathology.[1]

Most of these cases may require open reduction, with rare cases described with closed reduction, or bloodless, under anesthesia.[5] Choudhary and Tice[6] suggested that if the rotation of the patella is of less than 90 degrees, a closed reduction may be performed. Alioto and Kates[1] described the need for surgical treatment with a Schanz pin after failure of closed reduction, and McHugh et al[2] performed an open reduction through the longitudinal incision of the quadriceps tendon, followed by traction in an elderly patient with chronic dislocation of the patella.

Immobilization was performed for about 2 weeks, followed by early rehabilitation with strength recovery and preinjury mobility. Due to the possibility of associated injuries, such as ligament, osteochondral, or tendinous ones, the long-term

Fig. 5 Control radiographs and range of motion after 2 years of evolution.

outcome may not be as favorable, requiring outpatient follow-up for a longer time, in cases of conservative treatment.[7]

It is important to know, to be aware, and to raise the diagnostic suspicion of unusual injuries like the one reported in the present study, thus optimizing the treatment and rehabilitation of the patient. The prognosis is usually good, with a satisfactory recovery of mobility level.

Conflict of Interests

The authors have no conflict of interests to declare.

References

1 Alioto RJ, Kates S. Intra-articular vertical dislocation of the patella: a case report of an irreducible patellar dislocation and unique surgical technique. J Trauma 1994;36(02):282–284

2 McHugh G, Ryan E, Cleary M, Kenny P, O'Flanagan S, Keogh P. Intra-articular dislocation of the patella. Case Rep Orthop 2013; 2013:535803

3 Frangakis EK. Intra-articular dislocation of the patella. A case report. J Bone Joint Surg Am 1974;56(02):423–424

4 Yuguero M, Gonzalez JA, Carma A, Huguet J. Intra-articular patellar dislocation. Orthopedics 2003;26(05):517–518

5 Feneley RC. Intra-articular dislocation of the patella. Report of a case. J Bone Joint Surg Br 1968;50(03):653–655

6 Choudhary RK, Tice JW. Intra-articular dislocation of the patella with incomplete rotation–two case reports and a review of the literature. Knee 2004;11(02):125–127

7 Garner JP, Pike JM, George CD. Intra-articular dislocation of the patella: two cases and literature review. J Trauma 1999;47(04): 780–783

8 Theodorides A, Guo S, Case R. Intraarticular dislocation of patella: a case report and review of literature. Inj Extra 2010;41:103–105

9 Colville J. An unusual case of intra-articular dislocation of the patella. Injury 1978;9(04):321–322