

Case Report

Fracture of an Intravenous Cannula in the Vein during Removal : A Case Report

Jayanth B.S.¹ & Piyush M. Bhandari²¹HOD & ²Post graduate, Department of Oral And Maxillofacial, Coorg Institute of Dental Sciences, Virajpet, Coorg.

*Corresponding Author : B S Jayanth, HOD & Director of DCHKSHFS Cleft Center, Dept. of Oral and maxillofacial Surgery, Coorg Institute of Dental Sciences, Virajpet. Mobile : +91 96325 19000 E-mail : jayanth2g@gmail.com

Received : 07-07-2015 Abstract :

Review Completed : 16-03-2016

Accepted : 01-04-2016

Keywords : i.v cannula, complications

In Oral and Maxillofacial Surgery, peripheral venous cannulation is done for administrating antibiotics, fluids and supplements. Here we introduce the fracture of i.v cannula during removal inside the blood vessel. Peripheral i.v cannulation was done in radial vein with a 20G cannula in a patient with trauma for receiving antibiotics and fluids. Under sterile conditions, the broken piece of the cannula was removed from a vein with a surgical incision and the skin was sutured.

Access this article online

Quick Response Code



Introduction

Insertion of peripheral i.v lines is a key component for almost every patient who arrives to casualty for seeking treatment. In adults, routinely 18G or 20G plastic cannula are used. In the upper extremity, brachial vein, cubital vein and radial vein are commonly chosen for i.v cannulation and once in 48 hours these plastic cannula are changed. Although placement of these invasive devices is seen as a benign part of the daily practice particularly by junior staff, many complications like infiltration, thrombophlebitis, venous spasm, hematoma, air embolism, cannula associated blood stream infection and nerve, tendon and ligament injury can occur. We introduce the fracture of an i.v cannula during removal inside the blood vessel.

Historical Background

In 1657 Sir Christopher Wren invented the first instrument for intravenous therapy: A cannula made from the quill of a bird feather, which was used to inject drugs into the veins of dogs. The first demonstration of central venous

catheterization is attributed to the German physician and physiologist Werner Forssman. In 1929, Forssman inserted a 4-French ureteric catheter a distance of 65cm into his own antecubital vein, then walked to his X-ray department and radiographically confirmed the position of the catheter tip in his right atrium. In 1952, the French military surgeon Robert Aubaniac described the use of precutaneously placed subclavian vein catheters for rapid infusion of resuscitative fluids in military casualties.

Case Report

A 27 year old male patient reported to casualty with symphysis fracture. After standard work up with ECG, SPO2, Chest X-ray, complete blood picture and non-invasive blood pressure, a tourniquet was applied to the right wrist.

After disinfection of the dorsum of the hand, cannulation was done with 20G cannula. The guide needle was withdrawn and the cannula was introduced into the vein

after the back flash of blood. Over the next 48 hours, i.v fluids (one each DNS,RL,5D)was given. Inj. Taxim (1gm) BD, Inj. Gentamycin (80mg) BD and Inj. Pantoprazole (40mg) OD was given. When the cannula was withdrawn from the skin it was realized that the long piece of the cannula was broken and left in the vein. Following palpation of the cannula under the skin it was decided to remove off the broken piece surgically.under sterile conditions, the broken piece of the cannula was removed from a vein with a surgical incision and the skin was sutured.

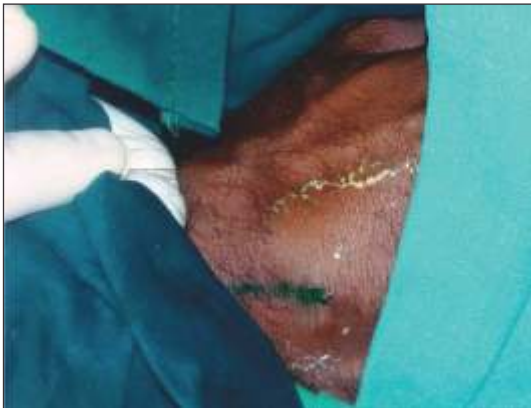


Figure 1 : Incision Marked

Discussion

Peripheral i.v.cannula are not without risk during both placement and while in situ. Although the history of over-the-needle type peripheral catheters starts in 1950's , the reports regarding i.v.cannula fracture in the literature are related to the central venous catheters with the complications such as sepsis, perforation, thrombosis, dysrhythmia, air embolism, pneumothorax and myocardial infarction.

Turner el al had reported the first case of an intravascular

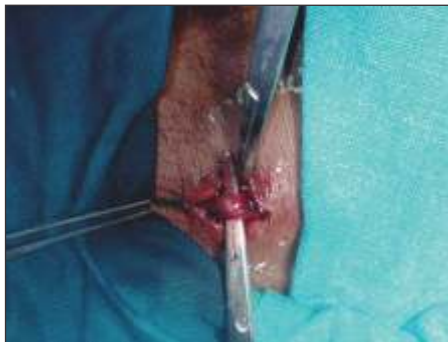

Figure 2 : Vein Identified

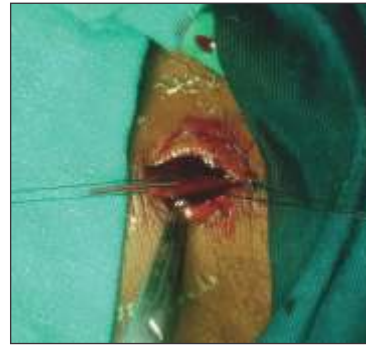


Figure 3 : Cannula Identified

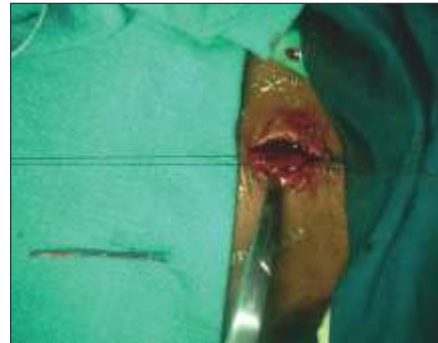

Figure 4 : Cannula Retrived

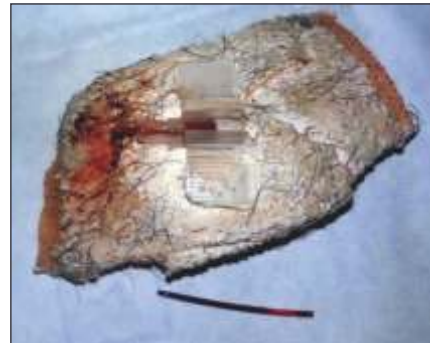

Figure 5 : Fractured IV cannula

embolization of catheter fragments in 1954 as a complication of central venous catheterization. There are two reports regarding embolism of fractured peripheral IV cannula in the literature. Cannula fracture is uncommon and usually occurs during insertion and removal.

Conclusion

As a condition, it should be considered that periodic check up of i.v cannula should be done, patient should be advised not to do vigorous wrist movement and i.v cannula to be changed every 48 hours or patients requiring long term intravenous therapy, totally implantable venous access devices(TIVADS's) should be used. Medical staff must

remember that although peripheral venous catheters are frequently used and provide an easy means of venous access for the administration of drugs and fluids, even the simplest invasive procedure such as peripheral i.v cannulation possess risks. All medical interventions should

be performed after adequate training and experience health care providers who insert peripheral i.v lines must be familiar with proper emergency interventions in case of cannula fracture within the vein and/or adjacent tissue.

References

1. Arun O, Bahar Oc, Gunduz E, Mehmet Oc, Duman A. Fracture of an intravenous cannula in the vein due to reinsertion of the guide needle: A case report. *Journal-Cardiovascular Surgery* 2014;2(2):28-29.
2. Glassberg E, Lending G, Abbou B, Lipsky AM. Something's missing: Peripheral intravenous catheter fracture. *J Am Board Fam Med* 2013; 26:805-806.
3. Nayeemuddin M, Pherwani AD, Asquith JR. Imaging and management of complications of central venous catheters. *ClinRadiol* 2013; 68:529-544.
4. Zaghal A, Khalife M, Mukherji D, Majzoub N, Shamseddine A, Hoballah J, Marangoni G, Faraj W. Update on totally implantable venous access devices. *Surgical Oncology* 2012; 207-215.
5. Singh S, Prakash J, Shukla VK, Singh LK. Intravenous catheter associated complications. *J Assoc Physicians India* 2010; 58:194-196.
6. Rivera AM, Strauss KW, van Zundert A, Mortier E. The history of peripheral intravenous catheters: How little plastic tubes revolutionized medicine. *Acta Anaesthesiol Belg* 2005; 56:271-282.
7. Turner DD, Sommers SC. Accidental passage of a polyethylene catheter from cubital vein to right atrium; report of a fatal case. *N Engl J Med* 1954; 251:744-745.