

Case Report

# Transdermal Iontophoresis on Gerhardt-Mitchell's Disease of Joints - A rear case report

Mallikarjunaiah H.S.<sup>1</sup>, Dhanesh Kumar K.U.<sup>2</sup>, Shilpa Dugani Burji<sup>3</sup><sup>1</sup>Research Scholar, NITTE University, Mangalore, <sup>2</sup>Principal and professor, Nitte Institute of Physiotherapy<sup>3</sup>Assistant Professor, Padmashree Institute of Physiotherapy.

\*Corresponding Author : Mallikarjunaiah H.S., Research Scholar, Nitte Institute of Physiotherapy, NITTE University, Mangalore.

Mobile: +91 9886309123 E-mail: mallu.neuro.physio@gmail.com.

Received : 11.05.2017

Review Completed : 25.05.2017

Accepted : 27.05.2017

## Abstract

Gerhardt-Mitchell's disease which is also named as Erythromelalgia is an unusual neurovascular pain syndrome which features with group of three characteristics i.e., raise in temperature, red color pigmentation of skin and pain with a quality of burning. All three characteristics are most importantly seen in the extremities. Erythromelalgia may occur either as a primary or secondary disorder. Clinical presentation of primary erythromelalgia is linked with severe burning pain, pronounced erythema of the skin, swelling and increased skin temperature, specifically of the feet. We present the case of a patient, 12 years old girl with primary erythromelalgia who came to our physiotherapy department with features of repeated redness, burning pain, increased warmth of the skin on anterior aspect of right foot. Computer Assisted Capillary Microscopy demonstrated reduced capillary density and capillary perfusion. Another observatory test was done by elevating patient's right leg noting the reversal in skin color from red to pale. Her detailed evaluation was carried out and physiotherapy treatment was started.

Access this article online

Quick Response Code





## Introduction

Primary erythromelalgia is a rare condition that's characterized by erythema, an increased skin temperature and burning pain in the extremities. Erythromelalgia is a merging of three Greek words: erythros means redness, melos means extremities and algos means pain.<sup>1</sup> Its occurrence rate ranges from 0.36 to 1.1 per 100,000 persons.<sup>2</sup> Many authors use these words synonymously Erythromelalgia, erythralgia and erythermalgia, while some of them differentiate between them depending on their underlined disorders.<sup>3</sup> Treating a case of PE is supremely challenging especially for its feature of pain. There are various kinds of treatment routes given for erythromelalgia. Some listed are – oral route are neuroleptic drugs and vasodilator, certain drugs through intravenous injections, some are intrusive such as by blocking Sympathetic ganglion and epidural route which are proved to be successful.<sup>1</sup> Since many being invasive procedures we treated a case of 12 year old girl

diagnosed with primary erythromelalgia by Iontophoresis with transdermal administration of diclofenac.

## Case Report

A 12-year old girl with the height of 126.8cms and weight of 26kgs came to physiotherapy department with marked redness, severe pain of right foot. Severe pain resulted in difficulty to walk. On observation we could find presence of marked redness, mild swelling and difficulty to bear weight on her right leg. At the age of 11 years she started to experience with features like warmth and reddish discoloration of skin on right foot. Hence she complained of past history of pain, pain experience was assessed for past i.e., age 11 and present i.e., age 12. Pain was assessed with Visual Analogue Scale (VAS) and depending on certain factors as mentioned in table below.

PAIN ASSESSMENT	
At Age 11	At Age 12
VAS 	VAS 
Onset - Sudden	Onset - Sudden
Precipitating factor – Exposure to heat	Precipitating factor - Exposure to heat, prolonged weight bearing on right foot and walking
Quality of pain - Burning	Quality of pain - Burning
Relieving factor - Immersion of foot in cold water	Relieving factor - Immersion of foot in cold water
Site of pain - Right foot	Site of pain - Right foot
Temporal variation - Afternoon	Temporal variation - approximately around 11am to 5pm

This suggested that pain intensity was increased from 4 to 8 on VAS in a span of one year. On palpation we could find warmth of skin with moderate tenderness with grade 2 on anterior aspect of right foot over metatarsals.

On examination we assessed for Range of Motion (ROM), Muscle strength and Gait.

Range Of Motion (ROM) using Standard Universal Goniometer		
	Right side	Left side
Plantar flexion	0-30°	0-50°
Dorsiflexion	0-15°	0-20°
Inversion	0-20°	0-35°
Eversion	0-15°	0-25°


Muscle strength according to Daniel and Worthingham's Grading		
	Right side	Left side
Plantar flexors	Poor (+)	Normal (N)
Dorsiflexors	Poor (+)	Normal (N)
Invertors	Poor (+)	Normal (N)
Evertors	Poor (+)	Normal (N)

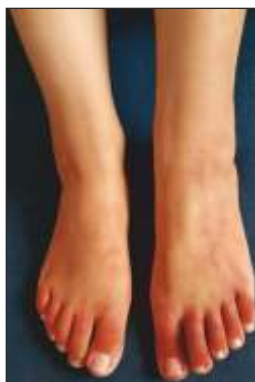On gait examination, type of gait was categorized to antalgic gait, for a reason being pain which limits the complete pattern of gait cycle. Pain can be a primary reason for decreased ROM, poor strength of muscles, variations in gait pattern. No abnormalities were seen on sensory system examination.

test performed by us revealed reversal in skin color from red to pale on raising patient's right leg.

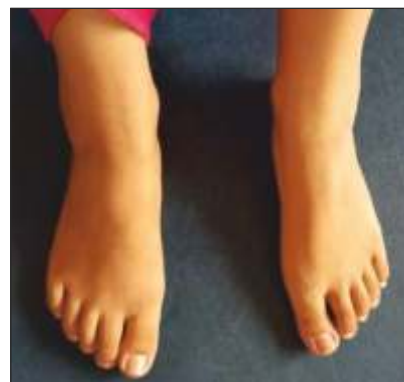Treatment was started with Iontophoresis, transdermal administration of diclofenac on day 1 of her visit continued for 4 days a week for 4 months at clinic. Besides this, dipping of her right foot in cold water was advised to be continued at home.

Computer Assisted Capillary Microscopy demonstrated reduced capillary density and capillary perfusion. Special

PAIN ASSESSMENT post to intervention	
	



Before



After

Discussion

Erythromelalgia is known for being uncommon disorder yet late confirmation shows that it is presumably more typical and there is a wide range of side effect that encounters from minor pain to fearsome conditions that can involve arms or legs.<sup>3</sup> Erythromelalgia is also called as Erythermalgia, Gerhardt Disease, Mitchell Disease, Weir-Mitchell Disease, Gerhardt-Mitchell's disease.<sup>4</sup> Symptoms of this disease are aggravated by raised body temperature. They can begin subsequent to working out, by covering hands or feet with mitten, not withstanding devouring liquor or piquant foods.<sup>5</sup> Inflammation, suppurative lesions of skin, death of localized living cells of involved limb is mostly seen. A subject had close lethal subnormal body temperature identified with frequent procedure that was applied to reduce the clinical manifestations seen because of Gerhardt-Mitchell's disease.<sup>6</sup> Mark D. P. Davis studied to examine repeated incidence and nature of variations seen with vessel structure and nerve involvement seen in subjects with Erythromelalgia. Author revealed presence of pathology related to peripheral nerves is much greater, by side erythematic and raised skin temperature of localized area associated with intensified rush of blood in blood vessels.<sup>7</sup> The intrusive treatments for Gerhardt-Mitchell's disease are related to insertion of anesthesia into lumbar spine a space between spinal cord and dura mater that inhibits the perception of pain sensation, nerve

block, infusion of anesthesia close to the proximity of plexus brachialis, a device that delivers pulsed electrical signals to control chronic pain. At certain instances if manifestations does not diminish further nitropress, lignocaine, is given intravenously for lowering the levels of blood flow through vessels that cause erythema and to attenuate with other manifestations of Gerhardt-Mitchell's disease.<sup>1</sup> All these procedures being invasive, a present case report assessed if transdermal application of diclofenac through Iontophoresis was applied in patients diagnosed with Gerhardt-Mitchell's disease, Iontophoresis would act as a management in a broader spectrum for clinical manifestations related to this condition.

Conclusion

A rare condition with Gerhardt-Mitchell's disease signified a better improvement with transdermal Iontophoresis by delivering diclofenac ions through the superficial layer of skin into the tissue. Further to this we saw a vast diminishing of clinical manifestations associated with this disease i.e. is reduction in pain, redness and skin returning to normal temperature. This led to improving ROM, muscle strength and gait. Subjective analysis of VAS which was again assessed post to the intervention revealed to be 2 on analogue scale. Hence, further randomized control trial in larger number population is required for analysis of better efficacy.

References

1. Yoo Jin Bang, Jin Seok Yeo, Si Oh Kim, Young Hoon Park. Sympathetic Block for Treating Primary Erythromelalgia. The Korean Journal of Pain. 2010;23(1):55-59.
2. Zhaoli Tang, Zhao Chen, Beisha Tang, Hong Jiang. Primary Erythromelalgia: A Review. Orphanet Journal of Rare Diseases. 2015;10:127.
3. D. Friberg, T. Chen, G. Tarr, A.vanRij. Erythromelalgia? A Clinical Study of People Who Experience Red, Hot, Painful Feet in the Community. International Journal of Vascular Medicine. 2013 April. Available from: <http://dx.doi.org/10.1155/2013/864961>
4. Mark Denis P. Davis. Erythromelalgia. Available from: <https://rarediseases.org/rare-diseases/erythromelalgia/>
5. NHS Choices. Erythromelalgia. Available from: <http://www.nhs.uk/Conditions/erythromelalgia/Pages/Introduction.aspx>
6. Antonie N Saliba. Medscape. Nov 17,2016. Available from: <http://emedicine.medscape.com/article/200071-overview#a7>
7. Mark D. P. Davis, Paola Sandroni, Thom W. Rooke, Phillip A. Low. Erythromelalgia: Vasculopathy and Neuropathy, or Both?. Archives of Dermatology. 2003;139:1337-1343.