

Review Article

A Comprehensive Review on Zygomatic Implants

Shagun Gulia¹, Monika Malik Vigarniya²

¹Assistant Professor, Department of Prosthodontics, SGT University, Gurgaon, Haryana, India, ²Senior resident, Department of Prosthodontics, SHKM Government Medical College, Nalhar, Haryana, India.

*Corresponding Author : Shagun Gulia, Assistant Professor, Department of Prosthodontics, SGT University, Gurgaon, Haryana, India.
Mobile: +91 88268 74671 E-mail : shagun.gulia@gmail.com

Received : 15.11.2017

Review Completed : 12.12.2017

Accepted : 13.12.2017

Keywords: Zygoma, Zygomatic Implants, Resorbed Maxilla, Sinus Slot Technique.

Abstract

Severely resorbed or atrophic maxilla has always posed a problem in terms of conventional implant therapy due to insufficient bone. A new approach to such situations is placing implants in the zygoma. Zygomatic implants are placed in patients with inadequate bone due to resection of the maxilla after surgery or in cases of resorbed maxilla. These are longer implants anchored in the zygoma, and present as an alternative to sinus augmentation or bone grafting. Being a technique sensitive procedure extreme care has to be taken during the placement of these implants to obtain promising results. This article reviews the zygomatic implants used in dentistry.

Access this article online

Quick Response Code



Introduction

It is an established fact that the amount of available bone is a primary criterion for implant support. If sufficient bone is not available for the placement of implants, their success is questionable.¹In severe maxillary defects following surgical resection, implant placement and the subsequent prosthetic treatment becomes very difficult due to the lack of supporting bone, soft tissues and muscles.¹Various techniques have been put forward to approach the atrophic maxilla², including use of tilted implants³, short, wide, mini implants, different grafts⁴, grafting the maxillary floor and zygoma implants.⁵

Due to the limited bone availability in posterior segments of the maxilla, risk free placement of implants of 10 mm in length is questionable. Various techniques for augmentation to improve the anatomic situation in such cases have been proposed like, on lay type maxillary ridge augmentation, inlay type maxillary ridge augmentation and sinus lift procedures. However there are disadvantages

like patient discomfort, sensitivity and pain in the donor site⁶. Also, the maxilla must remain load free for 6 months to allow the grafted bone to consolidate and the implants to osseointegrate. Because not wearing prosthesis is generally not considered socially acceptable these procedures is restricted.⁷

Another alternative to sinus grafts is zygomatic implants. It is a non-graft alternative to severely atrophic maxilla. First developed by Branemark these are placed in the upper jaw where there is inadequate alveolar bone for placing sufficient dental implants. This concept is beneficial in patients where conventional implants cannot be placed due to insufficient bone.⁸They have been successfully used to support a prosthesis in cases of patients who have undergone maxillectomy or where conventional implants cannot be placed due to atrophic maxilla or in cases where sinus grafts cannot be done or is a failure. The overall success rate of zygomatic implants is 97% as reported by Branemark.^{9,10}

In this review article, an attempt has been made to collect the data regarding zygomatic implants used in dentistry. Thorough hand search was made and electronic search using following key words such as 'atrophic maxilla, zygoma, zygomatic implants' also was carried out.

What are zygomatic implants?

These are implants which are 30 – 50 mm long and 4 mm wide, usually inserted from the palatal side. They have a 45° tilted platform and derive their anchorage in the zygoma.² They extend into the zygomatic process for good primary stability. They lie below the mucosa of the lateral wall of the sinus (figure 01)

Various studies have been done and they confirm that the survival rate is almost 98- 100 % for implants with few reported complications, using two stage protocols. This is followed by a six month healing period prior to loading the prosthesis. Zygomatic bone is excellent for the anchorage of implants since the quality of bone is superior to that of the posterior maxilla. Since the zygomatic bone has wider and thicker trabecular bone the implant exhibits initial primary stability required for loading.^{2,3,4}

Indications⁸

Zygomatic implants though are indicated and suggested by a lot of experienced surgeons and dentists, it should not be considered as the first line of treatment. They are indicated in a very few and handful situations. They are as follows:

1. When there is adequate bone anteriorly, and it is desired to provide implant stabilization posteriorly, the zygomatic implant may be indicated to avoid the need for grafting. Similarly, where grafting is indicated around the arch it may be possible to limit this to the anterior maxilla by using zygomatic fixtures posteriorly.
2. When the patient has anterior teeth but posteriorly has edentulous regions associated with extensive bone resorption.
3. Also zygomatic implants have been used to support prosthesis in case of maxillectomy.
4. Patients with large existing sinuses where grafting procedures are inevitable.²

Though these patients can be recommended for zygomatic implants, still there are some investigations that need to be done prior to beginning of the treatment. These would include preoperative assessment of the patient to find out whether the patient should undergo the treatment or not.

Preoperative assessment / investigation

1. Patient should have symptom free sinus.
2. No infections in the hard or soft tissues at the extended implantation site.

Radiographic examination is a very important step of the implant site. Following technique may be used:

1. Intra oral radiographs- to exclude any pathology in the ridge crest.
2. Panoramic radiographs – these assist in the identification of anatomic structures and to exclude any pathology of the jaw.
3. Lateral cephalograms – to know the jaw dimensions and the anteroposterior relationship between the upper and lower jaws.
4. Tomograms – this technique enables a more accurate visualization and measurement of the bony envelope in the potential implant site.

Advantages¹¹

1. Reduced surgical intervention.
2. Overall shortened time
3. Graft less procedure
4. Treatment of these patients with zygomatic implants an in office surgical procedure that allows them to use these existing maxillary dentures after surgery.
5. Infrazygomatic mini implants in vertical and horizontal directions provide acceptable anchorage in the field of orthodontics. (figure 02)¹²

Disadvantages

Though there are a number of advantages that have been listed above, this procedure does come with a few drawbacks. The zygomatic implant should never be considered as a first line of approach when treating the edentulous maxilla or one with missing molar teeth, but rather is of use in a very few number of cases. Also speech

problems are encountered with multiple zygoma implants. The application of the technique should be evaluated as it can lead to a variety of complications which are mentioned later. Evaluation should be done regarding

1. The nature of the problem resulting from tooth loss,
2. Alternative management strategies should be considered
3. Both systemic and local factors should be considered.

Apart from these evaluations certain obvious disadvantages are;

1. Access to the surgical site.
2. Difficulty in speech, due to the placement of these implants in the palate, the implant head affects the space available for the tongue, which reduces.

Complications¹¹

Now inspire of the advantages that zygomatic implants have to offer, a lot of complications listed below may arise if surgical procedure is not done accurately:

The Penetration into the nasal cavity or antral cavity by the implants.

1. Persistent infection.¹³
2. Overloading¹³
3. Speech alteration.^{14,15}
4. Problems in maintaining hygiene.¹⁴
5. Apical excess emergence in the infratemporal fossa, buccosinus fistula secondary to defective surgical closure, and chronic gingivitis.¹⁶
6. Severe sinus infection. (Due to sinus perforation.)
7. Intracerebral penetration of a zygomatic implant inserted in the pterygoid region.

Positioning of the implant at the pterygoid region must be done very carefully. Preoperative planning with computer assisted three dimensional transfer should be used.

Post operative CT scans should be done in all patients to rule out any complication. Also any neurological impairment of the patient after surgery should be investigated immediately.

Surgical Procedure⁸

Placement of an implant is known to be challenging procedure owing to the problems that may be encountered during the surgery. These problems may be the access or anatomy of the surgical site or the length of the implant body. It is necessary that the components are fully secured, that a drill guard is used to prevent soft tissue damage and lateral pressure is not too much as it may cause fracture to the osteotomy site.

Access is gained using an incision which is employed or used in creating a Le Fort I osteotomy, with wide exposure to the bony site. After this a small window is cut on the lateral wall of the sinus, inferior to the zygomatic process. This access to the maxillary antrum is established so that the soft tissue lining can be elevated without tearing and hence permitting the implant to lie on the lateral bony wall and in a sub-mucousal location. Various kinds of drills are then used to prepare the osteotomy and the hole is oriented with great care keeping in mind that the depth should not be too much to avoid damage to the floor of the bony orbit.

The head of the implant usually lays palatal to the residual alveolar ridge and is oriented laterally. The manufacturers also incorporate in the design an angled head which makes it possible to use abutments with long axes approximately normal to the occlusal plane.

Sinus Slot Technique⁹

The currently recommended surgical procedure involves a sinus window opening for better access of the final positioning of the implant. But in an already resorbed maxilla, it compromises the bone support to the ridge. Also the final prosthesis will be palatal to the ridge which may interfere with the fabrication of the convention prosthesis. To overcome these disadvantages, sinus slot technique has been recommended. Here, a slot is made directly through the buttress. This slot provides to orient the twist drills for implant placement.

The primary indication of this procedure is severely resorbed maxilla.

The contraindications include limited interarch distance as it limits the proper angulations of the long drill bits. Also, the patients with limited access due to temporomandibular disorder or soft tissue scarring due to a trauma. Lastly, the patients with acute or productive sinusitis.

This technique has significant advantages over the usual protocol suggested for zygomatic implants. These are

1. Due to reduced degloving of the zygoma, intraoperative pain control is facilitated.
2. The crestal incision gives good exposure of the ridge and the buttress.
3. The sinus slot provides good angulation for the implant.
4. On the crest of the ridge in the area of the first molar is the ultimate position of the implant platform.
5. Increased bone to implant interface (due to lateral position of the zygomatic implant.)
6. Procedures like sinus window and sinus lining elevation is eliminated
7. Sinus wall defects are reduced.
8. Due to the placement of the implant on the ridge, shortcomings like difficulty in speech and hygiene are overcome, which are otherwise seen in palatally placed implants. Therefore traditional prosthetic treatment can be done with these implants.

Pre – Operative Work Up¹⁷

It is important that the patient's health is satisfactory to allow him to undergo general anaesthesia.

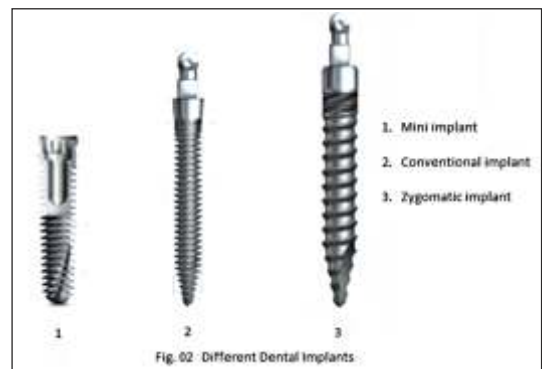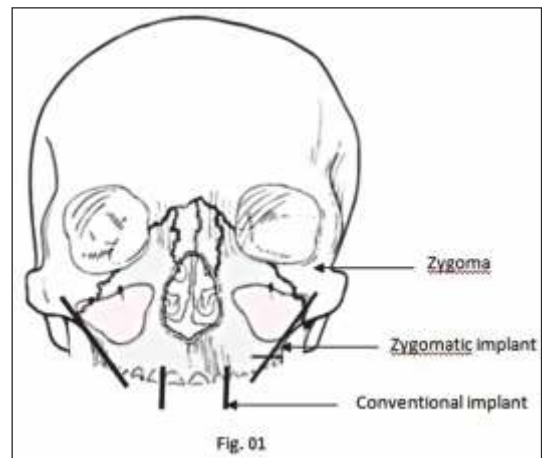
- Also sufficient anterior bone should be present for the placement of 2 or 4 anterior implants to stabilize the restoration.
- Pre-operative radiographs are extremely important and should show a healthy maxillary sinus without any pathology.
- Axial and reconstructed CT scans should indicate at least 8 -12 mm of bone in the region of the zygoma and enough bone structure in the lateral aspect of the maxilla to allow placement of zygomatic implants.
- A dentist should be consulted for immediate fabrication of a temporary cross arch bar at the time of exposure,

ensuring the stabilization of maximum implants.

Surgical Complication¹¹

If the implant is being placed in the pterygoid region as a solution for the severely atrophied maxilla, then care must be taken that it must have a proper mesiocranial direction. In such cases the implant continues upwards between both wings of the pterygoid process, where it finds itself encroaching in the scaphoid fossa of the sphenoid bone. If the implant is placed far too laterally, it will emerge in the infra-temporal fossa, and in case it is far too mesially it may traumatize the nasopharynx or the sphenoid sinus. And if it is far too cranially then it may enter the pterygopalatine fossa. Also if it is horizontal then no bony structure will be encountered.

Therefore, extreme care must be taken keeping in account the important adjacent structures next to the osteotomy site and should not be traumatized at any cost. . The orientation and depth of the implant hence play a very important role in implant placement and should not be neglected.



Discussion

Reconstruction of severely resorbed maxilla has been practiced with the help of various grafts. There are a lot of grafting procedures that have been used like crestal onlay grafting¹⁸, inlay grafts into the floor of the maxillary antrum¹⁹, iliac block graft, and Le Fort 1 osteotomy with interpositional bone grafting²⁰. Nevertheless these procedures pose complications like delayed healing time, multiple surgical procedures, other postoperative complications.^{21, 22} Onlay bone grafts in the anterior region along with zygomatic implants posteriorly has been tried and has proved to be successful in treating atrophic maxilla where otherwise a graft would have been necessary. This not only avoids unnecessary hospitalization of the patient but also reduces the risk of postoperative morbidity. Postoperative evaluation of the sinus however becomes mandatory.²³

It is believed that a newly grafted maxilla should remain load free for at least 6 months for healing to occur. However the patient will be without a prosthesis during this time which becomes a socially unacceptable for the patient.²⁴ Studies have shown that immediate loading of the zygomatic implants has been successful. However further studies to study the long-term success rate is yet to be done. Immediate loading not only improves function but also aesthetics and patient satisfaction.^{25, 26}

Zygoma implants have been shown to rehabilitate a severely atrophic posterior maxilla. These extra long implants placed external to the maxilla, anchored in the zygomatic bone provide excellent support and stability. This procedure not only avoids two surgical procedures but also avoids sinus lift and sinus graft surgery. Also placing grafts in the zygoma prevents further resorption of the alveolar ridge.²² These implants provide additional support

and retention to a conventional obturator in case of a maxillectomy patient. Inspire of the few disadvantages reported, due to the stability offered by the zygoma implants they find their use on a large scale in the era of implants today.

Also, maxillary defects arising from trauma, disease, pathological changes or after surgical resection of neoplasms, require rehabilitation by means of an obturator prosthesis. It has been shown that in cases where the remaining dentition does not provide adequate retention and support, the placement of zygomatic implants has enhanced the stability of the prosthesis.²⁷

The technique for the placement of zygomatic implants should be considered as a major surgical procedure and therefore proper training is needed. But it is still less complicated than bone grafting procedures, as harvesting of bone graft is not done.²⁷ Zygomatic implants have the highest success rate compared to all the traditional treatment modalities that are used for the atrophic maxilla inspire of the few number of implants that are placed so far.^{24, 29}

Conclusion

Today zygomatic implants are being placed in patients where conventional implant is not an option or in patients who have undergone surgery following resection of the maxilla. These implants have answered the question of implant therapy in a resorbed maxilla with insufficient bone. However it might sound tempting to follow this approach it becomes mandatory to know the complications and shortcomings of these implants. Only after the patients consent and proper training of the practitioner should zygomatic implants be considered an option.

References

1. Zygoma implant supported prosthetic rehabilitation of a patient with a maxillary defect. *Int J. Oral Maxillofac. Surg.* 2011;40:106-123
2. Immediate function in the atrophic maxilla using zygoma implants: a preliminary study. *J Prosthet Dent* 2007;97:S44-S51
3. Placement of posterior mandibular and maxillary implants for improved prosthesis support. *Int J Oral Maxillofac Implants* 2000;15:722-30
4. Bone graft remodelling and implant success rate in the treatment of the severely resorbed maxilla: A 5 year longitudinal study. *Int J Oral Maxillofac surg* 2002;31:158-64
5. Zygoma fixture in the management of advanced atrophy of the maxilla: technique long term results. *Scand J plast reconstr surg* 2004;38:70-85
6. Donor site morbidity in two different approaches to anterior iliac crest bone harvesting *clin implant dent relat res* 2003;5:161-9
7. A new approach to rehabilitate the severely atrophic maxilla using

- extra maxillary anchored implants in immediate function: a pilot study
J Prosthet Dent 2008;100:354-366
8. Introducing dental implants
 9. Sinus slot technique for simplification and improved orientation of zygomatic dental implants: a technical note *Int J. Oral Maxillofac. Implants* 2000;15:889-893
 10. Ten year survival rates of fixed prosthesis on four or six implants ad modern branemark in full edentualism *clin oral implants res* 1995;6:227-231
 11. Intracerebral penetration of a zygomatic dental implant and consequent therapeutic dilemmas; a case report *Int J. Oral Maxillofac. Implants* 2010;25:416-418
 12. Horizontal and vertical resistance strength of infrazygomatic mini-implants. *Int J. Oral Maxillofac. Surgery* 2011;40:521-525
 13. Zygoma implants for midfacial prosthetic rehabilitation using telescopes ;9 year follow up *int j prosthodont* 2009;22:20-32
 14. Clinical application of zygomatic implants for rehabilitation of the severely resorbed maxilla : a clinical report *int j oral maxillofac implants* 2003;18:566-570
 15. Initial speech problems in patients treated with multiple zygomatic implants *Int J. Oral Maxillofac. Implants* 2010;25:379-384
 16. Image based planning and clinical validation of zygoma and pterygoid implant placement in patients with severe bone atrophy using customized drill guides: preliminary results from a prospective clinical follow up study. *Int j oral and maxillofac surg* 2003;32:7-14
 17. Color atlas of dental implants surgery
 18. Maxillary alveolar ridge augmentation with onlay bone graftsand immediate endosseous implants. *J craniomaxillofac surg* 1992;20:2-7
 19. Report of the sinus consesus conference of 1996. *Int j oral maxillofac implants* 1998;13;11-22
 20. Interpositional bone grafting and le fort 1 osteotomy for reconstruction of the atrophic edentulous maxilla. A two stage technique. *Int j oral maxillofac surg* 1997;26:423-427
 21. Rehabilitation of severely resorbed maxilla with zygomatic implants: an evaluation of implant stability, tissue conditions, and patient's opinion before and after treatment *Int J. Oral Maxillofac. Implants* 2006;21:399-404
 22. The zygomatic implant:preliminary data on treatment of severely resorbed maxillae. A clinical report. *Int J. Oral Maxillofac. Implants* 2002; 17:861-865
 23. Clinical application of zygomatic implants for rehabilitation of the severely resorbed maxilla: a clinical report. . *Int J. Oral Maxillofac. Implants* 2003; 18:566-570.
 24. Surgical modifications to the branemark zygomaticus protocol in the treatment of the severely resorbed maxilla; a clinical report. *Int J. Oral Maxillofac. Implants* 2003; 18:232-237.
 25. Zygomatic implants – protocol for immediate occlusal loading; a preliminary report *J. Oral Maxillofac. Surgery* 2006; 64:804-811.
 26. Immediate stabilization of stage II of zygomatic implants: Rationale and technique *J Prosthet Dent* 2001;86:10-4
 27. Zygoma implant supported prosthetic rehabilitation after partial maxillectomy using surgical navigation: a clinical report *J Prosthet Dent* 2007; 97:121-8.
 28. Zygoma implants; a review *JIADS vol 2 April-June 2011*.
 29. Clinical evaluation of the zygoma implant:3 year follow up at 16 clinics *J. Oral Maxillofac. Surgery* 2005; 2023-2038.