



Distal Articular Fractures of the Humerus: Surgical Approach with Dynamic Elbow external Fixator

Fracturas articulares distales del húmero: Abordaje quirúrgico con fijador externo codo dinámico

Marcio Aurelio Aita¹  Ricardo Kaempf de Oliveira² Douglas Hideki Ikeuti¹ 
Gustavo Mantovani Ruggiero³ Fernando Luvizoto de Carvalho¹ Fabio Lucas Rodrigues¹

¹Surgery Department, Orthopedic and Traumatology, Hand and Microsurgery Division, Faculdade de Medicina do ABC, Santo Andre, SP, Brazil

²Orthopedic and Traumatology Department, Danta Casa de Porto Alegre, Porto Alegre, RS, Brazil

³Plastic Surgery Department, Università Degli Studi Di Milano, Milan, Italy

Address for correspondence Marcio Aurelio Aita, PhD, Orthopaedic and Traumatology Department, Faculdade Medicina ABC, Av. Príncipe de Gales, 821-Príncipe de Gales, Santo Andre, SP, 09060-650, Brazil (e-mail: marcioaita@me.com).

Rev Iberam Cir Mano 2020;48:2–9.

Abstract

Purpose To measure clinical and radiographic outcomes using external fixation in distal humeral fractures.

Methods A total of 10 elderly patients, with a mean age of 71 (range 64–84 years) years old, with unstable distal humeral fractures were treated by percutaneous reduction and fixation with an articulated external fixator. The patients were assessed on range of elbow motion, patient disabilities of the arm, shoulder, and hand (DASH), and pain visual analog scale (VAS) and radiographic evaluation at 12 months.

Results The mean range of motion was 134° of flexion, extension was of -5°. All of the elbows were clinically stable. The mean VAS was 2.2, and the mean DASH score was 14.3. Radiographic analysis showed satisfactory reduction and consolidation. All of the patients showed congruence of concentric humerus-ulnar and radius and no patient had joint stiffness or posttraumatic arthritis of the elbow. Regarding complications, we observed a patient who presented with pain in the location of the ulnar pin, which was resolved with the removal of the pin. After two months, another patient had pneumonia and died. The follow-up was of 15.44 months.

Conclusions A radiographic analysis of the patients showed fracture healing with joint congruity. In the functional clinical aspect, it was noted that patients had functional range of motion

Type of study/level of evidence Therapeutic IV

Keywords

- ▶ elbow
- ▶ fractures
- ▶ distal humerus fractures
- ▶ instability
- ▶ elderly
- ▶ external fixation

received
September 17, 2019
accepted
February 3, 2020

DOI <https://doi.org/10.1055/s-0040-1708888>.
ISSN 1698-8396.

Copyright © 2020 Thieme Revinter Publicações Ltda, Rio de Janeiro, Brazil

License terms



Resumen

Propósito Medir los resultados clínicos y radiográficos mediante fijación externa en fracturas humerales distales.

Métodos Un total de 10 pacientes de edad avanzada, con una edad media de 71 años (rango 64–84 años), con fracturas inestables del húmero distal fueron tratados mediante reducción percutánea y fijación con un fijador externo articulado. Los pacientes fueron evaluados según el rango de movimiento del codo, las discapacidades del paciente del brazo, hombro y mano (DASH) y la escala analógica visual del dolor (VAS) y la evaluación radiográfica a los 12 meses.

Resultados El rango de movimiento promedio fue de 134 ° de flexión, la extensión fue de -5 °. Todos los codos eran clínicamente estables. El VAS medio fue de 2,2 y el puntaje DASH medio fue de 14,3. El análisis radiográfico mostró una reducción y consolidación satisfactorias. Todos los pacientes mostraron congruencia de húmero-cubital concéntrico y radio y ningún paciente tenía rigidez articular o artritis postraumática del codo. Con respecto a las complicaciones, observamos a un paciente que presentaba dolor en la ubicación del pin cubital, que se resolvió con la extracción del pin. Después de dos meses, otro paciente tuvo neumonía y murió. El seguimiento fue de 15,44 meses.

Conclusiones Un análisis radiográfico de los pacientes mostró curación de fracturas con congruencia articular. En el aspecto clínico funcional, se observó que los pacientes tenían un rango de movimiento funcional

Tipo de estudio/nivel de evidencia Terapéutica IV

Palabras Clave

- ▶ codo
- ▶ fracturas
- ▶ húmero distal fracturas
- ▶ inestabilidad
- ▶ ancianos
- ▶ fijación externa

Introduction

The incidence of distal humeral fractures corresponds to ~2% of all adult elbow fractures.^{1–8} The mechanisms of injury are bimodal, and includes low-energy trauma, usually associated with osteoporotic bone in elderly patients, and high-energy, more frequent in young patients with higher incidence of complications such as soft tissue, nerves³ and vascular injuries.

In elderly patients, surgical treatment with open reduction and internal fixation using plates and screws remains the choice of treatment,^{9–14} even with high complication rates, as reduction loss, articular stiffness and soft tissue damage. According to Korner et al¹⁵ and Hausman et al¹⁶, the internal fixation is justified by the improvements in osteosynthesis techniques and implants with locking screws.

Elbow arthroplasty may be indicated in selected patients with fractures of the severely fragmented distal humerus, or in patients with osteoporosis or rheumatoid arthritis.^{17–19}

Gausepohl et al⁹ applied the dynamic external elbow fixator associated with internal fixation in the surgical treatment of complex fractures of the distal humerus in patients with osteoporosis, to protect the internal fixation and decrease complication rates.

The hypothesis of the present study is that distal humeral fractures in elderly patients treated with percutaneous reduction and fixation with an articulated external fixator would avoid complications of the open management, reducing the risk of infection and soft tissues damage.

The objective of the present study is to measure the radiographic, clinical, and functional outcomes of patients

with complete articular fractures of the distal humerus treated with an articulated external fixator.

Methods

The study design is a prospective cohort. Inclusion criteria were elderly patients (> 60 years old), with distal humeral fractures (closed or open), classified as AO 13C, comminution below the olecranon fossa, observed in radiographs and computed tomography (CT) scan (► **Figs. 1–3**). The study was approved by the Ethics Committee (CAAE: 50927715.3.0000.5484).

The patients were positioned in the supine position and submitted to general anesthesia or regional brachial plexus block. Closed maneuvers and indirect fracture reduction with longitudinal traction and percutaneous bone reduction clamps, aiming satisfactory articular surface reduction and the distal humerus alignment, were performed. The stabilization was performed with Kirschner wires and/or lag screws near the joint line of the distal humerus (► **Fig. 4**), to fix the joint surface fragments, the medial epicondyle and the lateral cross into the metaphysis.

With the reduced fracture, we positioned the elbow at 90° flexion and the forearm at 90° pronation, conducted the examination with fluoroscopy in this elbow to identify its rotation axis (imaginary line that cuts through the center of the capitellum) and passed a Kirschner wire guide (2 mm) in the center of rotation in the parallel direction to the articular surface of the distal humerus, from lateral to medial direction.

The central body of the external fixator (Elbow external fixator, Amsterdam, Fixus[®], Netherlands, and Galaxy elbow external fixator, Bussolengo, Orthofix[®], Italy) was properly

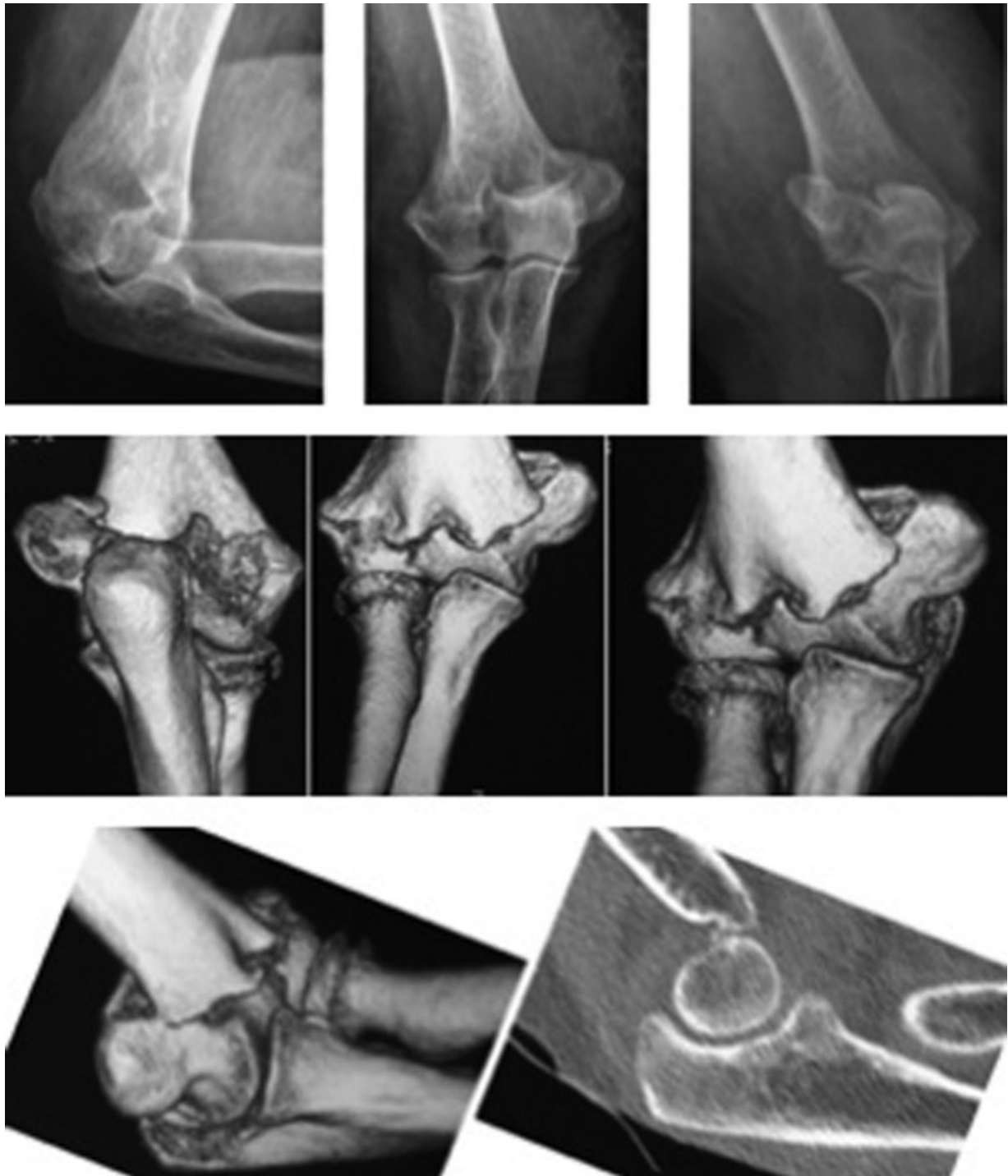

Fig. 1 Radiographic/Tomographic aspects (preoperative): distal humerus fracture (13C3).

seated in the guide wire. Two Schanz pins (5 mm) were introduced in the humerus, and two other pins (4 mm) into the ulna and connected to the clamps. Those were fixed to the rods passing through the central body. The principle of arthrodiastasis (increased joint space) can be promoted by external fixator to help reduce the articular fragments. An occlusive dressing was applied, and the final tightening of the components of the external fixator was checked.

After the procedure, patients remained in hospital for a period of 24 hours. Subsequently, they performed rehabili-

tation in the occupational therapy sector of the institution, with the specific protocol already established, which recommends elbow mobility from the 1st day after the surgery (►Fig. 5).

When patients were discharged, they were followed-up weekly in the first month. Then, the returns occurred at 2 months, 3 months, 6 months and 1 year after the surgery.

The parameters chosen for analysis were X-rays to assess articular congruence, reduction and consolidation; range of motion compared with the normal side; pain by visual

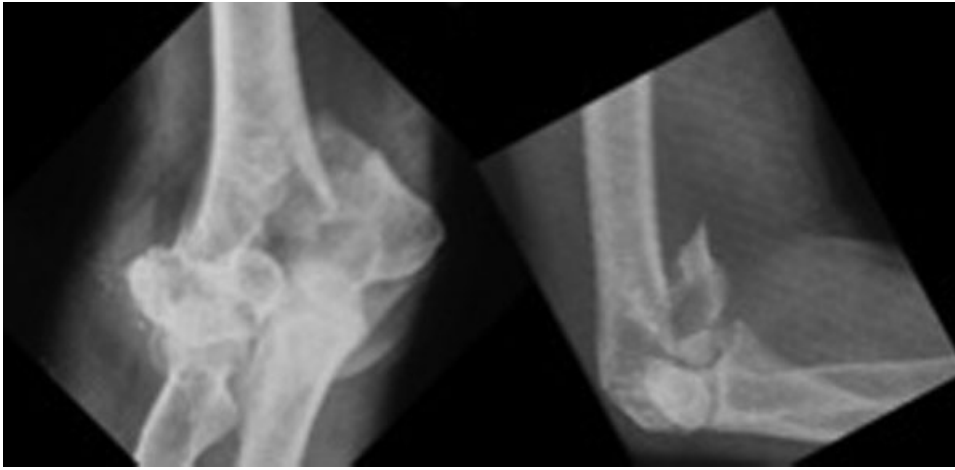


Fig. 2 Radiographic aspects (preoperative): distal humerus fracture (13C3).

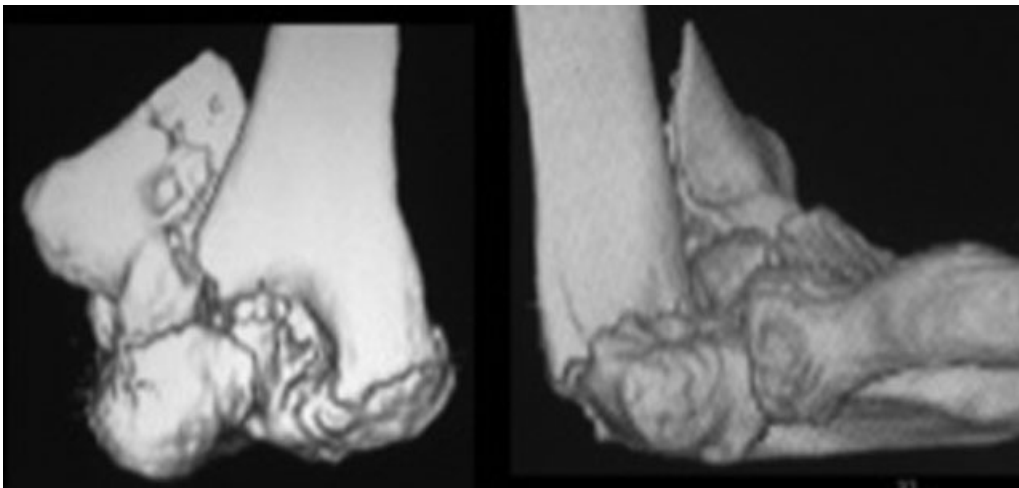


Fig. 3 Tomographic 3D aspects (preoperative): distal humerus fracture (13C3).

analogue scale (VAS) after 1 year; the quality of life by the disabilities of the arm, shoulder and hand (DASH) questionnaire and any complications and new operations if they had occurred.

For statistical analysis we adopted the significance level of 5% (0.050) to the testing. The comparison between the variables was due to the application of the test of Wilcoxon Signed Posts, to investigate possible differences between the normal ROM (opposite side) and ROM after 1 year (affected side)

Results

We evaluated a total of 10 patients, 4 men and 6 women. The mean age was ~71 years old, ranging from 64 to 84 years old. The follow-up time was 15.44 months (minimum of 12 and maximum of 21 months).

The average range of motion of the fracture side was 134° of flexion, and -5° of extension. All of the elbows were clinically stable. The mean VAS was 2.2 and the mean DASH was 14.3.

Radiographic analysis showed satisfactory reduction and consolidation. All of the patients showed congruence of concentric humerus-ulnar and radius: (►**Fig. 6**) and no

patient had joint stiffness or post-traumatic arthritis of the elbow.

A patient with pain in the ulnar pin path location was observed, which was solved with the removal of the pin, and another patient had pneumonia and came to die 2 months after the fracture. They were assessed at 12 months (see ►**Table 1**).

It was noted that the three comparisons showed 'statistical similarity' between the two time points, for the variables of interest. It was interpreted that the parameters DASH and VAS do not tend to statistical differences, suggesting quality of life and pain improvements in the patients after the treatment (see ►**Table 2**).

Discussion

The surgical approach to these elbow fractures is challenging and highly difficult.¹³ All of the current methods of internal stabilization require broad access, with triceps handling with or without osteotomy of the olecranon, which can result in stiffness and nonunion.¹⁰⁻¹⁶ Searching the stability, the mobility restoration, and the reduction of perioperative

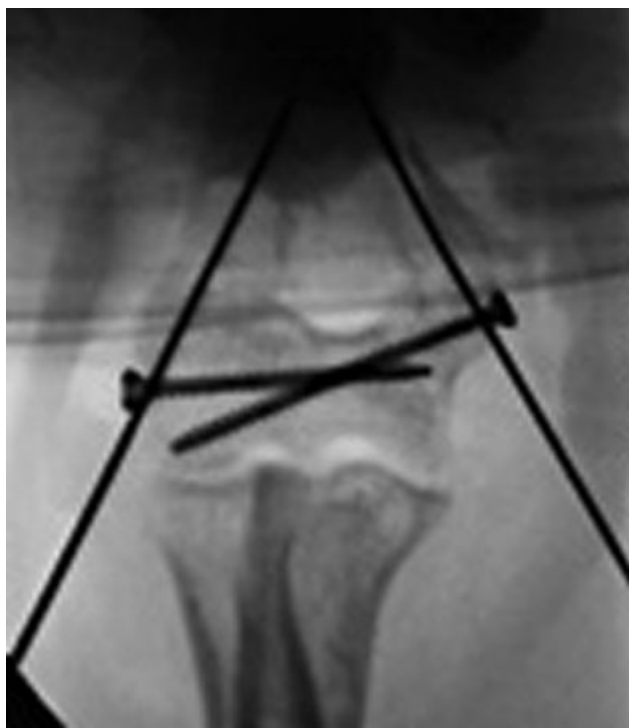

Fig. 4 Intraoperative fluoroscopic aspects. Kirschner wires and or lag screws near the joint line of the distal humerus.

complications, we proposed the use of an articular external fixator.³⁻⁶ Those patients “supported” early mobilization of the elbow.

Currently, there are several case studies using primary elbow arthroplasty¹⁷⁻²⁰ as a possible method of treatment of those fractures, with promising results: elbow mobility turns out to be a functional and safe method for those geriatric patients. But the choice of that method is still an exception in our midst.

The external fixator used in the present study (► **Fig. 7**) promoted stability and early mobility of the elbows, which influenced directly in the clinical and functional outcome of those patients who have endured such pain during the early handling of the elbow since the 1st day after surgery, with the help of physiotherapists, while hospitalized. Association between physical therapy activities and the use of analgesics was reported by most patients in the 1st month after surgery.

The average value of the flexion-extension of the elbow in our study was 129°, while for Orbay¹ (internal fixator) it was 115°, for Sorensen et al¹⁹ (arthroplasty) it was 114°, for McKee et al¹² it was 105°, and for Sørensen et al⁷ (external fixation) it was 95°. Although the sample is small, our results are superior when compared with the aforementioned studies (► **Fig. 8**)

All of our patients had consolidation and maintenance of fracture reduction (articular congruence radius-capitellum and humerus-ulna) and stability of the elbow. (see ► **Fig. 9**)

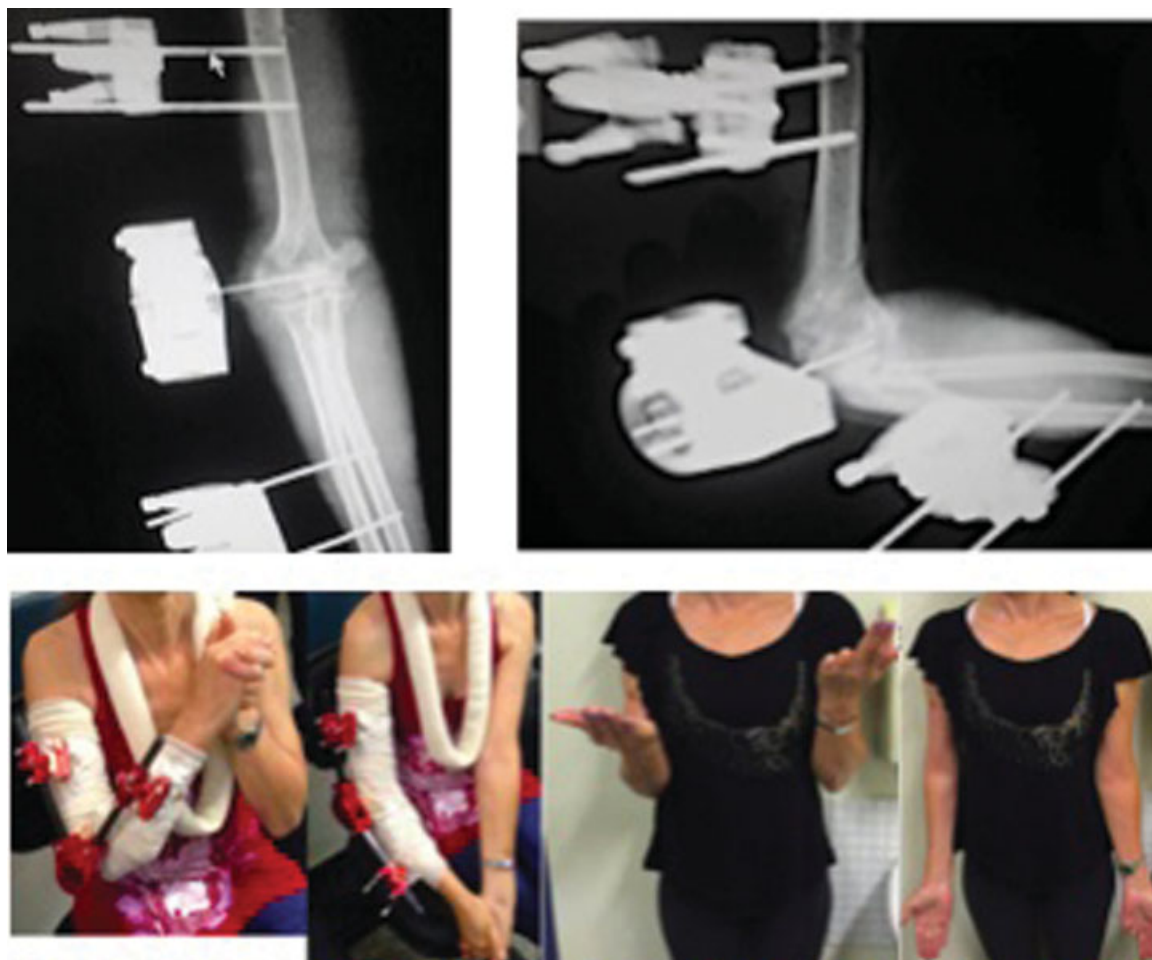


Fig. 5 Postoperative clinical and radiographic aspects showed the range of motion of the elbow.

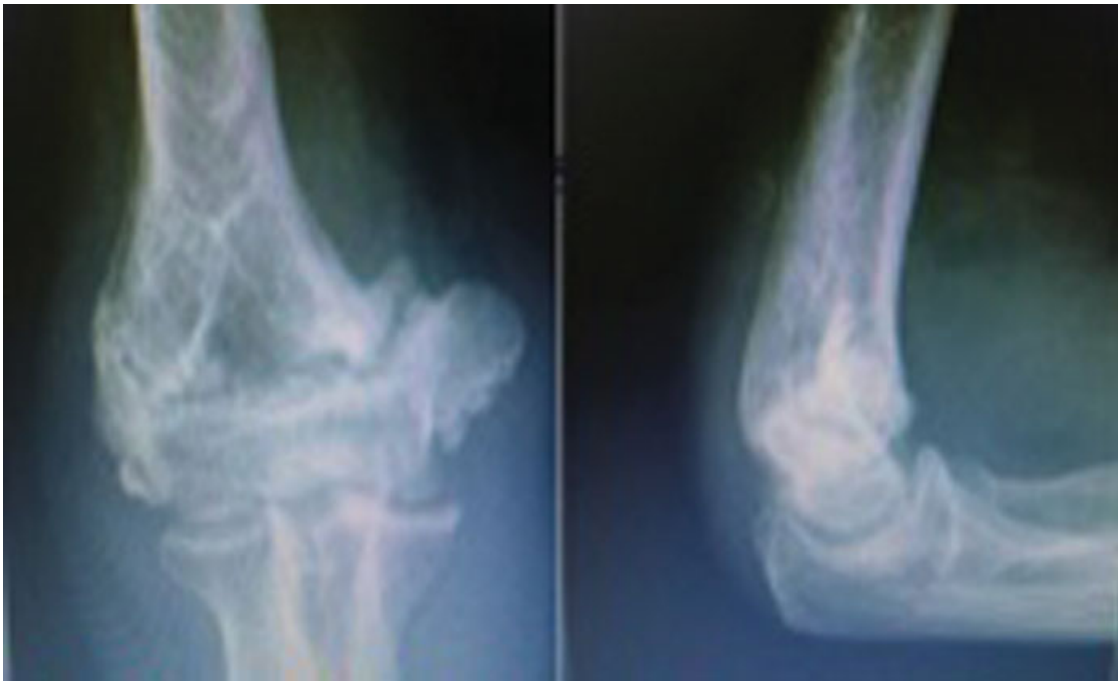


Fig. 6 Postoperative radiographic aspects – articular congruence radius-capitulum and humerus-ulnar.

Table 1 Clinical and functional aspects

Identification	Age	Follow-up	Gender	Side	ROM normal	ROM1 year	DASH normal	DASH 1 year	VAS 1 year	Complications	AO Classification
I	64	21	F	R	140	130	1	12	3	—————	13C2
II	85	21	F	L	140	140	1	12	1	—————	13C1
III	67	2	F	R	135	130	1	1	1	death	13C3
IV	66	18	M	R	140	140	1	1	1	ulnar pins release	13C1
V	64	16	M	R	140	120	1	30	3	—————	13C3
VI	84	14	F	R	140	125	1	30	4	—————	13C3
VII	65	13	F	L	130	125	1	18	3	—————	13C2
VIII	75	12	F	R	140	132	1	15	2	—————	13C3
IX	71	12	M	R	135	128	1	18	3	—————	13C3
X	73	12	M	R	135	130	1	6	1	—————	13C2

Legend: DASH, disabilities of the arm, shoulder and hand; ROM, range of motion; VAS, visual analogue scale.

Table 2 Statistic analysis of clinical and functional parameters

Variabilities	n	Mean	Standard deviation	Minimum	Maximum	Percentile 25	Percentile 50 (mediana)	Percentile 75	Significance (p-value)
ROM normal	10	139.17	2.04	135.00	140.00	138.75	140.00	140.00	0.068
ROM 1 year	10	130.83	8.01	120.00	140.00	123.75	130.00	140.00	
DASH normal	10	1.00	0.00	1.00	1.00	1.00	1.00	1.00	0.063
DASH 1 year	10	14.3	13.09	1.00	30.00	1.00	12.00	30.00	
VAS normal	10	1.00	0.00	1.00	1.00	1.00	1.00	1.00	0.102
VAS 1 year	10	2.2	1.33	1.00	4.00	1.00	2.00	3.25	

Legend: DASH, disabilities of the arm, shoulder and hand; ROM, range of motion; VAS, visual analogue scale.

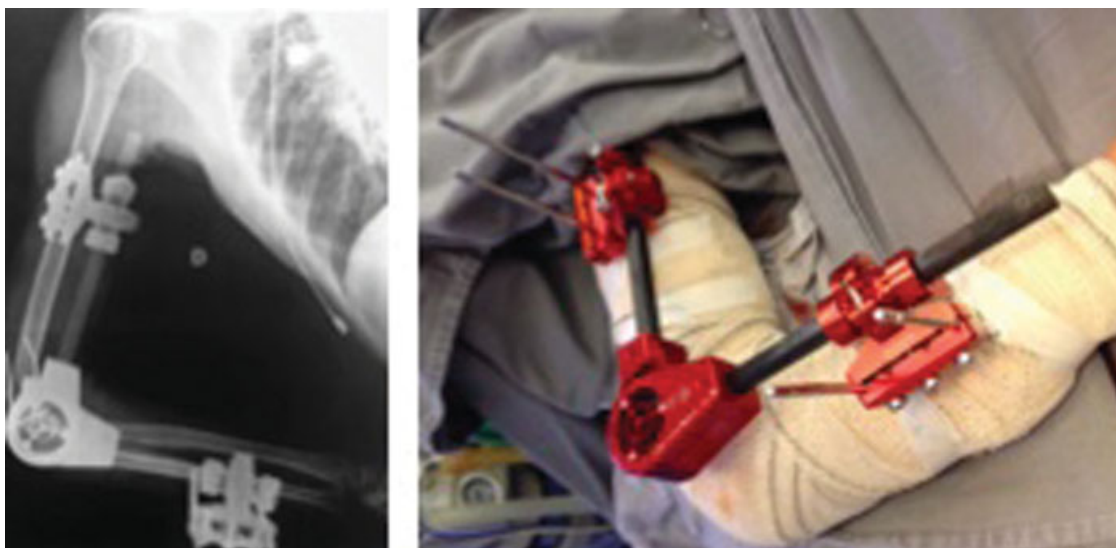

Fig. 7 Radiographic and clinical aspects (immediate postoperative).

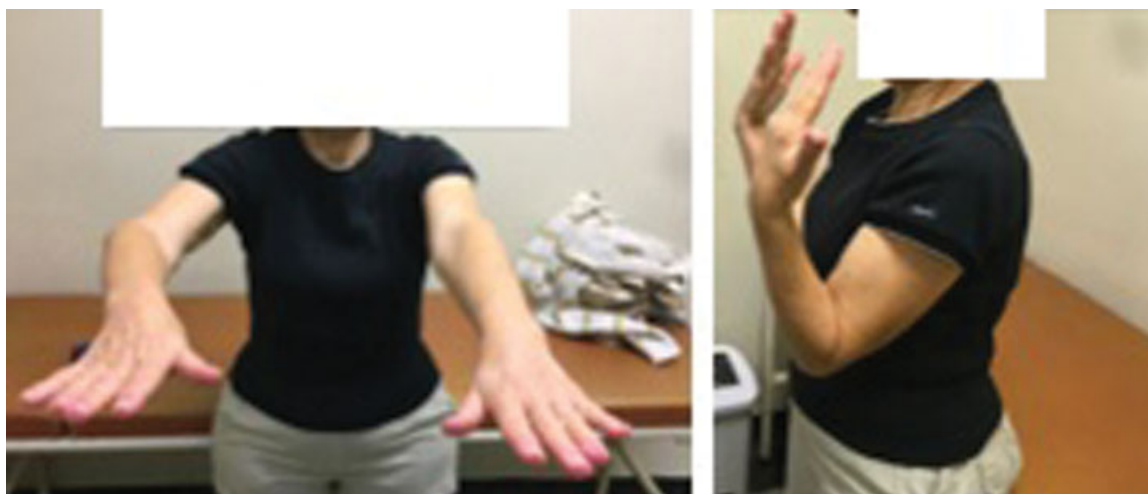


Fig. 8 Clinical aspects (postoperative): right elbow and functional ROM.

Orbay¹ didn't have complications, McKee et al¹² presented in their series of 16 patients, a case of recurrent elbow instability; Sørensen et al⁷ reported a patient with elbow dislocation. In the study of Sorensen et al, 4 out of 20 patients undergoing elbow arthroplasty presented complications (2 with infection, and 2 with ulnar nerve injury). In the present study, a patient was observed with pain in the

location of the ulnar pin path, which was solved with the removal of the pin.

The present research had the disadvantage of the need for a new procedure to remove the implant. It is a prospective cohort study and these results need to be confirmed in larger quantitative and qualitative studies.

This technique restores stability, the anatomy, and allows early mobility of the elbows of the patients. It is believed that it is a promising method for the treatment of geriatric patients with distal and articular fractures of the humerus.

It is suggested new scientific research, with greater level of evidence to validate this method. Thus, the articulated external fixator elbow can be part of the orthopedic surgeon toolbox.

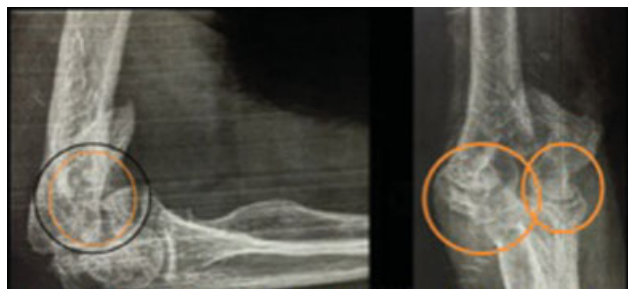

Fig. 9 Postoperative radiographic aspects after 6 months: elbow articular congruence.

Conclusion

Radiographic analysis of the patients showed fracture healing with joint congruity. In the functional clinical aspect, it was noted that patients had functional range of motion.

Ethical Approval

The research presented here was approved by and was in accordance with the ethical standards of the Faculdade de Medicina do ABC Ethics Committee on human experimentation under the CAAE number: 50927715.3.0000.5484.

Informed Consent

An informed consent document was provided to all research participants, who read and signed it according to their will.

Funding Statement The present research received no specific grant from any funding agency in the public, commercial or not-for-profit sectors.

Conflict of Interests

The authors have no conflict of interests to declare.

Acknowledgments

Translation service provided by Edith Nicole Laniado – Rua Albuquerque Lins, 1238–2b, Santa Cecília, São Paulo, State of São Paulo, Brazil.

Phone: + 55 11 3368–4600 / 55 11 99904–3418

Nicole@ibttranslations.com | www.ibttranslations.com

References

- Orbay JL, Mijares MR. The management of elbow instability using an internal joint stabilizer: preliminary results. *Clin Orthop Relat Res* 2014;472(07):2049–2060
- Ring D, Bruinsma WE, Jupiter JB. Complications of hinged external fixation compared with cross-pinning of the elbow for acute and subacute instability. *Clin Orthop Relat Res* 2014;472(07):2044–2048
- Lewandowski L, Tintle SM, Daniel C, O'Daniel JA, Fleming M, Keeling J. Circular external fixation for treatment of distal humerus fractures: case report. *J Hand Surg Am* 2013;38(06):1155–1160
- Ouyang Y, Liao Y, Liu Z, Fan C. Hinged external fixator and open surgery for severe elbow stiffness with distal humeral nonunion. *Orthopedics* 2013;36(02):e186–e192
- Feranec M, Hart R, Kozák T. [Hinged external fixation in orthopaedic and trauma surgery of the elbow]. *Acta Chir Orthop Traumatol Cech* 2013;80(06):391–395
- Banerjee D, Ghosh S, Ghosh PK, Mitra U, Dasgupta S, Jha AK. A short term experience of management of open and osteoporotic intercondylar fractures of the distal humerus using a mini-external fixator. *J Indian Med Assoc* 2011;109(06):404, 406, 408
- Sørensen AK, Søjbjerg JO. Treatment of persistent instability after posterior fracture-dislocation of the elbow: restoring stability and mobility by internal fixation and hinged external fixation. *J Shoulder Elbow Surg* 2011;20(08):1300–1309
- Stehle J, Gohlke F. [Classification of elbow stiffness and indications for surgical treatment]. *Orthopade* 2011;40(04):282–290
- Gausepohl T. [Osteosynthesis in distal intra-articular humeral fractures. External fixation with motion capacity]. *Unfallchirurg* 2011;114(02):130–135
- Allende CA, Allende BT, Allende BL, Bitar I, Gonzalez G. Intercondylar distal humerus fractures—surgical treatment and results. *Chir Main* 2004;23(02):85–95
- McKee MD, Wilson TL, Winston L, Schemitsch EH, Richards RR. Functional outcome following surgical treatment of intra-articular distal humeral fractures through a posterior approach. *J Bone Joint Surg Am* 2000;82(12):1701–1707
- McKee MD, Jupiter JB. A contemporary approach to the management of complex fractures of the distal humerus and their sequelae. *Hand Clin* 1994;10(03):479–494
- Aslam N, Willett K. Functional outcome following internal fixation of intraarticular fractures of the distal humerus (AO type C). *Acta Orthop Belg* 2004;70(02):118–122
- Flinkkilä T, Toimela J, Sirniö K, Leppilähti J. Results of parallel plate fixation of comminuted intra-articular distal humeral fractures. *J Shoulder Elbow Surg* 2014;23(05):701–707
- Korner J, Lill H, Müller LP, et al. Distal humerus fractures in elderly patients: results after open reduction and internal fixation. *Osteoporos Int* 2005;16(Suppl 2):S73–S79
- Hausman M, Panozzo A. Treatment of distal humerus fractures in the elderly. *Clin Orthop Relat Res* 2004;(425):55–63
- Cobb TK, Morrey BF. Total elbow arthroplasty as primary treatment for distal humeral fractures in elderly patients. *J Bone Joint Surg Am* 1997;79(06):826–832
- Lee KT, Lai CH, Singh S. Results of total elbow arthroplasty in the treatment of distal humerus fractures in elderly Asian patients. *J Trauma* 2006;61(04):889–892
- Sørensen BW, Brorson S, Olsen BS. Primary total elbow arthroplasty in complex fractures of the distal humerus. *World J Orthop* 2014;5(03):368–372
- Lovy AJ, Keswani A, Koehler SM, Kim J, Hausman M. Short-Term Complications of Distal Humerus Fractures in Elderly Patients: Open Reduction Internal Fixation Versus Total Elbow Arthroplasty. *Geriatr Orthop Surg Rehabil* 2016;7(01):39–44