




Combined Reconstruction of the Anterior Cruciate Ligament and Anterolateral Ligament Injury Compared to the Isolated Reconstruction of the Anterior Cruciate Ligament: A Meta-Analysis*

Reconstrução combinada do ligamento cruzado Anterior e lesão do ligamento anterolateral comparada à reconstrução isolada do ligamento cruzado anterior: Uma metanálise

Augusto Leão Bucar¹  Rodrigo Nunes de Albuquerque Pires¹ Rodrigo do Carmo Silva¹
Edicarlos André Cavalcante de Araujo¹ Messias Froes da Silva¹ Pedro Henrique Nunes de Araujo¹

¹ Department of Orthopedics, Hospital das Forças Armadas, Brasília, DF, Brazil

Address for correspondence Augusto Leão Bucar, MD, Hospital das Forças Armadas, SQNW, 310, bloco F, apartamento 509, Brasília, DF, 70675-731, Brazil (e-mail: augustobucar@hotmail.com).

Rev Bras Ortop 2021;56(1):24–30.

Abstract

The present research aims to compare the outcomes from the combined reconstruction of the anterior cruciate ligament (ACL) and of the anterolateral ligament (ALL) with the standard isolated ACL reconstruction in patients with chronic ACL injury. To do so, a meta-analysis was carried out to determine whether the combined ACL and ALL reconstruction would lead to a significant improvement in knee function according to the International Knee Documentation Committee (IKDC), the Lysholm test and KT-2000 evaluation scores and lower graft rupture rates in comparison with isolated reconstruction. To identify randomized controlled trials (RCTs) comparing the combined ACL and ALL reconstruction with the isolated ACL reconstruction, papers published between 2010 and 2019 were searched in the MEDLINE, EMBASE, SPORT-Discus, LILACS and Cochrane Central Register of Controlled Trials databases, following the Preferred Reporting Items for Systematic Reviews and Meta-Analyses (PRISMA) criteria. The stability of the knee joint is only marginally improved with the combined reconstruction of ACL and ALL, and both reconstruction techniques show functional results. The main outcomes sought were patient function and graft stability and rupture rates after ACL reconstruction. Out of the 421 studies identified, 6 were included in our meta-analysis. Study quality (internal validity) was assessed using the Cochrane risk-of-bias tool; in general, the studies included presented moderate-quality

Keywords

- anterior cruciate ligament
- anterolateral ligament
- ligament injury
- rupture
- chronic lesion

* Study performed at the Hospital das Forças Armadas, SQNW, 310, bloco F, apartamento 509, Brasília, DF, Brazil.

received

September 16, 2019

accepted after revision

March 2, 2020

published online

November 2, 2020

DOI <https://doi.org/10.1055/s-0040-1709990>.

ISSN 0102-3616.

© 2020. Sociedade Brasileira de Ortopedia e Traumatologia. All rights reserved.

This is an open access article published by Thieme under the terms of the Creative Commons Attribution-NonDerivative-NonCommercial-License, permitting copying and reproduction so long as the original work is given appropriate credit. Contents may not be used for commercial purposes, or adapted, remixed, transformed or built upon. (<https://creativecommons.org/licenses/by-nc-nd/4.0/>)

Thieme Revinter Publicações Ltda., Rua do Matoso 170, Rio de Janeiro, RJ, CEP 20270-135, Brazil

evidence. The graft rupture rate was higher in patients undergoing isolated ACL reconstruction (relative risk, 0.22; 95% confidence interval, 0.12 to 0.41; $p < 0.00001$).

Resumo

Palavras-chave

- ligamento cruzado anterior
- ligamento anterolateral
- lesão ligamentar
- ruptura
- lesão crônica

O objetivo da presente pesquisa é comparar, por meio de uma metanálise, os resultados da reconstrução combinada do ligamento cruzado anterior (LCA) e do ligamento anterolateral (LLA), comparado com a reconstrução isolada padrão, em pacientes com lesão crônica do ligamento cruzado anterior. Buscando alcançar o objetivo da pesquisa, foi realizada uma meta-análise para determinar se a combinação da reconstrução combinada LCA e LLA levaria à melhoria significativa da função do joelho, medida pelos escores de avaliação International Knee Documentation Committee (IKDC), Lysholm, KT-2000 e menor taxa de ruptura do enxerto, em comparação com a reconstrução isolada. Para identificar ensaios clínicos randomizados (ECR) comparando a reconstrução combinada do LCA e LLA com a reconstrução isolada do LCA, foram pesquisados artigos publicados entre 2010 e 2019 nas bases MEDLINE, EMBASE, SPORTDiscus, LILACS e Cochrane Central Register of Controlled Trials e seguiram os critérios de Itens de Relatórios Preferidos para Revisões Sistemáticas e Metanálises (PRISMA). A estabilidade da articulação do joelho é apenas marginalmente aprimorada com a reconstrução combinada de LCA e LLA, e ambas as técnicas de reconstrução mostram resultados funcionais. Os principais desfechos procurados foram a função do paciente e as taxas de estabilidade e ruptura do enxerto após a reconstrução do LCA. Dos 421 estudos identificados, 6 estudos foram incluídos em nossa meta-análise. A qualidade do estudo (validade interna) foi avaliada usando o instrumento Cochrane risco-de-viés; em geral, foi encontrada uma qualidade moderada de evidências dos estudos incluídos. Os pacientes submetidos à reconstrução isolada do LCA mostraram maior taxa de ruptura do enxerto (RR 0,22; índice de confiança [IC]95%: 0,12–0,41; $p < 0,00001$).

Introduction

Anterior cruciate ligament (ACL) ruptures are among the most common knee injuries; the number of ACL reconstructions has increased in recent decades, reaching ~ 130,000 procedures per year.¹

Studies have shown that the incidence of ACL reconstruction has increased over the years, particularly in women and people < 20 years old or ≥ 40 years old. However, recent researches and cost-reducing measures can improve treatment in such groups through prevention and positive results. Nevertheless, surgeons must be aware that ACL reconstruction can result in damage.¹

Anterior cruciate ligament reconstruction aims to restore knee function and stability; however, rotational stability may not be completely restored using the standard isolated reconstruction.²

Anterior cruciate ligament reconstruction is one of the most common procedures in orthopedic surgery. Nonetheless, even with surgical techniques and advancements in implants, some patients still present residual postreconstruction anterolateral rotational laxity.³

Although individual studies have not shown the superiority of combined ACL reconstruction over the isolated reconstruction in terms of function and stability, bio-

mechanical principles suggest that a combined approach may be useful; therefore, grouping randomized clinical studies available through a meta-analysis can be enlightening.

According to Saithna et al.,⁴ combined ACL and anterolateral ligament (ALL) reconstruction is associated with a significant reduction in ACL graft rupture rates and a very low rate of complications, but with an increased risk of reoperation.

Persistent rotational instability after isolated, standard ACL reconstruction has been widely described, and it has been shown to maintain a direct correlation with worse postoperative results.⁵ Anterolateral ligament injury has a relevant role in the genesis of knee rotational instability.^{3,6}

Many anatomical publications have defined the ALL as a distinct ligament.⁶ Nonetheless, some authors have proposed the association of ACL and ALL reconstruction in disabled individuals to further increase postoperative knee stability.⁷

After many years of vigorous debate in the literature, a panel of international and clinical researchers who are experts in ACL surgery has finally reached a consensus: the ALL does exist.⁸

The ALL was first described in 1879 by Dr. Paul Segond as a “resistant, pearly fibrous band” that could result in an

avulsion fracture of the tibial plateau when the knee was submitted to forceful internal rotation, the so-called Segond fracture (1879).

In the early 19th century, French anatomists Vallois and, later, Jost, took an interest in the anterolateral structures of the knee. Next, in 1976, Hughson and colleagues described a “middle third of the lateral capsular ligament,” renewing the interest on these knee structures.^{9,10} After numerous studies, the ALL received several different names, confounding the anterolateral anatomy of the knee.¹¹

Anterior cruciate ligament specialists have not reached a consensus regarding the reliability of combined reconstruction due to the controversy involving both ALL anatomy and biomechanics.^{12,13} Clinical trials with a high level of evidence and long-term follow-up can be useful in determining the reliability of combined procedure at the clinical setting.

As such, the present research aims to compare, through a meta-analysis, the outcomes from the combined ACL and ALL reconstruction with the standard isolated ACL reconstruction in patients with chronic ACL injury.

The present study hypothesizes that patients undergoing combined ACL and ALL reconstruction have less residual laxity and better clinical outcomes when compared to those submitted to isolated ACL reconstruction.

Methodology

To identify randomized controlled trials (RCTs) comparing combined ACL and ALL reconstruction with isolated ACL reconstruction, the MEDLINE, EMBASE, SPORTDiscus, LILACS and Cochrane Central Register of Controlled Trials databases were queried following the Preferred Reporting Items for Systematic Reviews and Meta-analyses (PRISMA) criteria (► **Figure 1**).

Two authors searched independently the electronic databases between April and June 2019. Trials in progress and recently completed were identified at ClinicalTrials.gov. We did not apply any language-based restrictions and translation services were used when necessary. References from relevant papers were checked for completeness. Conference summaries (available online from 2010 to 2019) from the International Society for Arthroscopy, Knee Surgery and Orthopedic Sports Medicine, the American Orthopedic Society of Sports Medicine, and the American Academy of Orthopaedic Surgeons were also included.

Our bibliographic research identified a total of 421 studies; after excluding obviously irrelevant and duplicate reports, 10 papers were retrieved for evaluation. We recognized two reports from the same study; although we have combined useful data from both papers, the most relevant information was extracted from the full-text report.⁸ We excluded another study that was not an RCT. The remaining

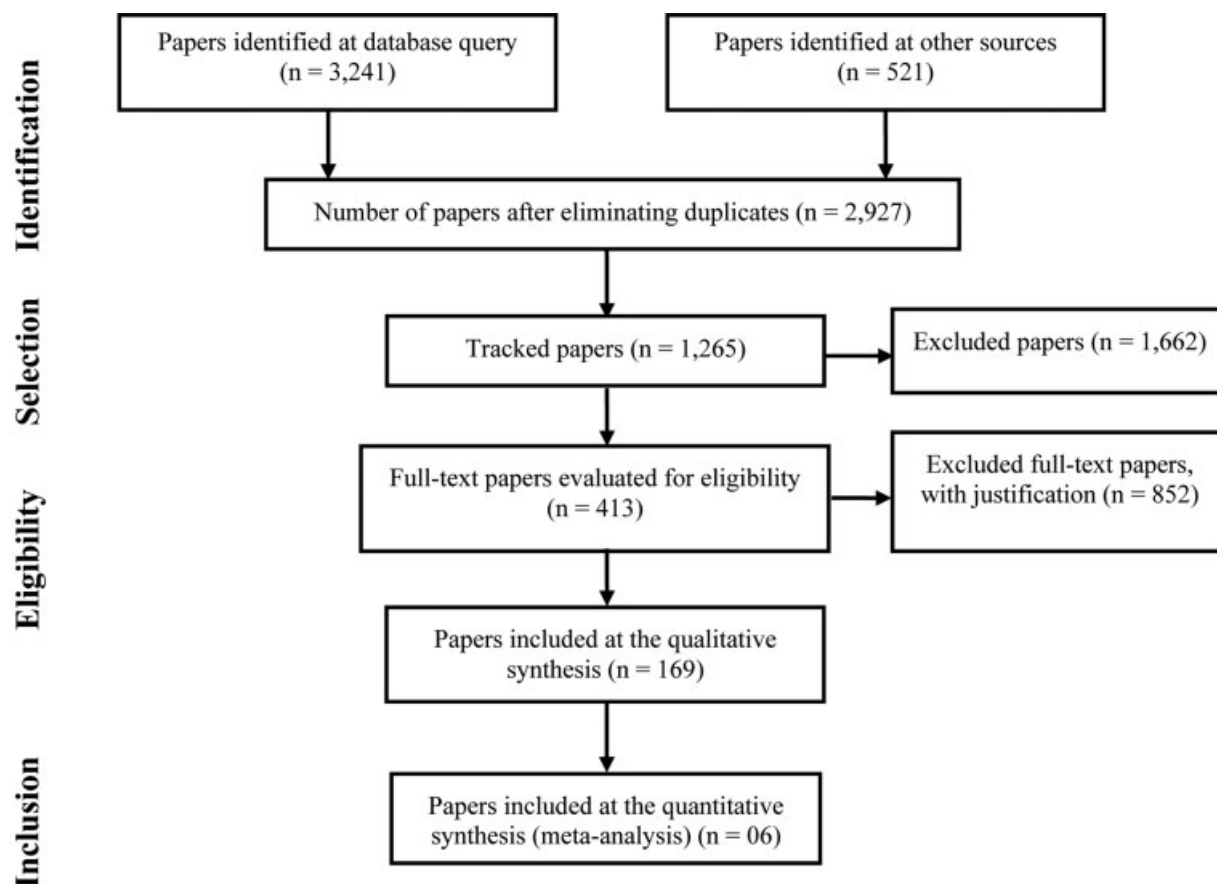


Fig. 1 Flow chart according to PRISMA.

six papers met the inclusion criteria for our systematic review.³

Study quality (internal validity) was assessed using the Cochrane risk-of-bias tool.¹¹ According to this tool, the included studies usually presented moderate quality.

All statistical analyzes were performed using the Review Manager 5.3 statistical software (RevMan 5.3; Nordic Cochrane Center, The Cochrane Collaboration, Copenhagen, Denmark).¹⁴ Treatment effects were expressed as risk ratios (RRs) for dichotomous results and mean differences for continuous results at 95% confidence intervals (95% CI). A fixed-effect meta-analysis was performed for data considered to be homogeneous. The heterogeneity of the treatment effects was assessed visually by observing CIs on forest plots, in addition to their direction and magnitude. In addition, I^2 statistics were calculated for an objective assessment of heterogeneity.

Subgroup analysis was performed when possible. Publication bias was assessed by visual inspection of funnel charts from primary results. Assessments may not be accurate due to the small number of attempts. Studies are well distributed throughout the plot and publication bias is not a major concern. As a safety measure, we searched the gray literature on this subject to find works with non-relevant or negative results.

The main results sought were patient function, stability and graft rupture after ACL reconstruction. Of the 421 studies identified, 6 papers were included ($n = 776$ participants; follow-up, 12–84 months; male-to-female ratio, 2.17:1) in our meta-analysis.

No study provided evidence level 1. Two papers reached evidence level 2 due to randomization. The remaining studies had evidence levels 3 and 4.

Results

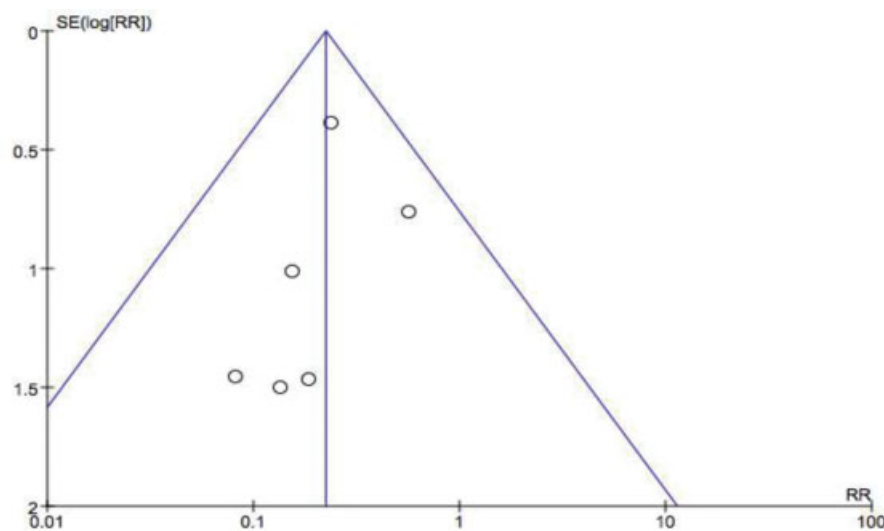
All six selected papers followed up on ACL and ALL reconstruction techniques. Together, these studies included 776

patients, 402 of whom underwent ACL and ALL reconstruction. One paper compared ACL reconstruction alone with ACL and ALL reconstruction. Another study compared three ACL reconstruction techniques: reconstruction with a single band, reconstruction with a double band and anatomical reconstruction with a single band associated with ALL reconstruction. A third study also compared three anatomical ACL reconstruction techniques: using a patellar tendon graft, quadruple graft from flexor tendons and flexor tendons graft combined with ALL reconstruction.

All statistical analyzes were performed using the Review Manager statistical software (RevMan 5.3; The Nordic Cochrane Center, The Cochrane Collaboration, Copenhagen, Denmark). Treatment effects were expressed as RRs for dichotomous outcomes and mean differences for continuous outcomes at 95% CI. A fixed-effect meta-analysis was performed for data considered homogeneous. Treatment effects heterogeneity was assessed visually by observing CIs over forest plots in addition to their direction and magnitude. In addition, I^2 statistics were calculated for an objective assessment of heterogeneity. High heterogeneity was indicated by the absence of overlapping CIs in forest plots and I^2 values $> 50\%$; in such cases, reasons for heterogeneity were investigated. Subgroup analysis was performed when feasible.

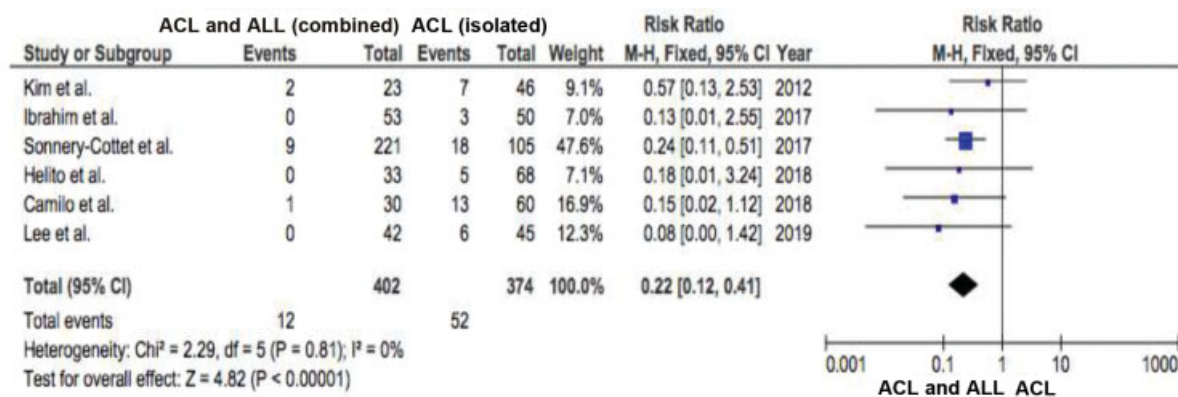
Funnel graphs show standard errors (SE) and RRs for graft rupture cases. Publication bias was assessed by visual inspection of funnel graphs from primary outcomes (►Figure 2). Assessments may not be accurate due to the small number of attempts. Studies are well distributed throughout the plot and the publication bias is not a major concern. As a safety measure, we researched the gray literature regarding this subject to find papers with nonrelevant or negative outcomes.

Regarding graft ruptures (►Figure 3), the forest plot graph shows a significant difference ($p < 0.05$) in the number of cases that underwent ACL reconstruction alone and those



Source: Figure prepared by the authors (2019).

Fig. 2 Funnel graph showing standard error (SE) and risk ratio (RR) for graft rupture.



Source: Figure prepared by the authors (2019).

Fig. 3 Forest plot graph from the meta-analysis of graft rupture cases. ACL, Anterior cruciate ligament; ALL, anterolateral ligament; 95%CI, 95% confidence interval.

submitted to combined ACL and ALL reconstruction; therefore, the graft rupture rate is significantly higher in patients undergoing isolated ACL reconstruction (RR, 0.22; 95%CI: 0.12–0.41; $p < 0.00001$).

Side-by-side mean difference (and standard deviation) in tibial anterior translation, measured with a KT-2000 arthrometer, was significant ($p < 0.05$) in patients submitted to isolated ACL reconstruction compared with those undergoing combined ACL reconstruction (RR, -0.65; 95%CI: -0.78–-0.51; $p < 0.00001$). Thus, mean tibial anterior translation is significantly lower in patients undergoing combined ACL reconstruction.

In summary, when assessing ligament laxity using a KT-2000 arthrometer, combined ACL and ALL reconstruction allows less tibial anterior translation than isolated ACL reconstruction (→ **Figure 4**).

Average Lysholm test scores did not differ significantly ($p > 0.05$) in patients undergoing isolated ACL reconstruction compared with those submitted to combined ACL reconstruction (RR, 1.11; 95%CI: -0.20–2.42; $p = 0.10$).

Mean subjective International Knee Documentation Committee (IKDC) questionnaire scores did not differ signif-

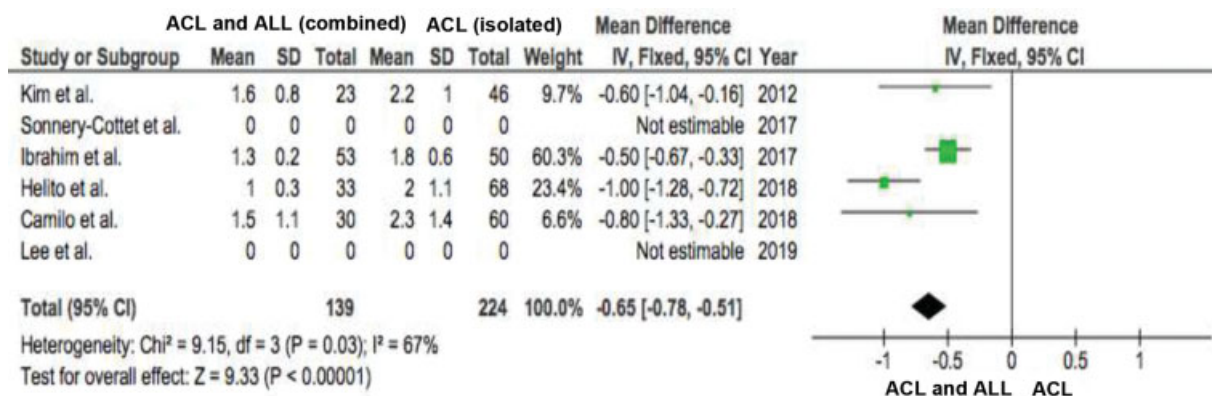
icantly ($p > 0.05$) in patients undergoing isolated ACL reconstruction compared with patients undergoing combined ACL reconstruction (RR, 1.05; 95%CI: -0.47–2.56; $p = 0.17$).

Discussion

The main finding of this meta-analysis was that, compared only to isolated ACL reconstruction, combined ACL and ALL reconstruction did not result in significant differences in knee function.

Relatively consistent results from isolated ACL reconstruction have been reported and show knee function recovery in most patients. However, rotational stability may not be restored by reconstruction alone. The main finding of our meta-analysis was that, compared with isolated ACL reconstruction, combined ACL and ALL reconstruction did not result in significant differences in knee function. Although knee stability was superior in the combined ACL reconstruction group, IKDC and Lysholm test results were only marginally improved.

Based on ligament laxity assessed using a KT-2000 arthrometer, combined ACL and ALL reconstruction allows less anterior translation than isolated ACL reconstruction. In



Source: Figure prepared by the authors (2019).

Fig. 4 Forest Plot graph from the meta-analysis comparing KT-2000 arthrometer test results after anterior cruciate ligament reconstruction. ALL, Anterolateral ligament; 95% CI, 95% confidence interval.

addition, graft failure rate improved after the combined ACL procedure.

Helito et al.³ showed evidence that combined ACL and ALL reconstruction in patients with chronic ACL injury is an effective and safe solution, leading to good functional outcomes with no complication rate increase. The clinical relevance of this finding was the possibility of indicating this type of procedure in patients presenting with > 12 months after surgical injury.³

Similar results were also noted by Saithna et al., with clinical outcomes of advanced ACL reconstruction demonstrating a significant reduction in ACL rupture currents and improved rates of return to sports compared with isolated ACL reconstruction.⁴

This finding is supported by laboratory studies showing that the association of ACL reconstruction and lateral extra-articular symptoms are procedures that protect from the accumulation of ACL loads and are the most reliable normal knee kinematics recovery compared with isolated ACL reconstruction.

An improvement in graft failure rate after combined ACL and ALL reconstruction has also been reported by Helito et al.³ In their cohort with a minimum follow-up period of 2 years, the graft failure rate was 0 and 7.3% in patients submitted to ACL and ALL and ACL reconstruction, respectively ($p > 0.05$).

Sonnery-Cottet et al., in a large prospective comparative series of 502 ACL reconstructions with 1 from 3 different surgical techniques and a minimum follow-up of 2 years, demonstrated significantly reduced rates of ACL graft rupture in a high-risk population (young, athletic patients) after combined ACL and ALL reconstruction compared to a paired cohort undergoing isolated ACL reconstruction.¹¹

Inderhaug et al. have shown that, despite numerous technical descriptions of anterolateral procedures, knowledge is limited as to the effect of knee flexion angle during graft fixation.¹⁵

To determine the effect of knee flexion angle during graft fixation on the tibiofemoral joint kinematics for a modified Lemaire tenodesis or combined ALL and ACL reconstruction, Inderhaug et al. showed that, for combined ACL and anterolateral deficiency, isolated ACL reconstruction was associated with a residual laxity both in anterior translation and internal rotation.¹⁵ Anterior translation was restored for all combinations of ACL and anterolateral procedures. Combined ACL and ALL reconstruction restored the intact knee kinematics when the graft was fixed in full extension, but the combined procedure left residual laxity in internal rotation ($p = 0.043$) when the graft was fixed at 30° and 60°. The combined ACL reconstruction and modified Lemaire procedure restored internal rotation regardless of knee flexion angle during graft fixation. When the combined ACL reconstruction and lateral procedure states were compared with the isolated ACL reconstructed state, a significant reduction in internal rotation laxity was observed with the modified Lemaire tenodesis, but not with ALL reconstruction.

In summary, the aforementioned biomechanical study demonstrated that, in a combined ACL and anterolateral

lesion, an isolated ACL reconstruction cannot restore normal knee stability.¹⁵

Based on the assessment of ligament laxity using a KT-2000 arthrometer, Kim and colleagues observed that the combined reconstruction of ACL and the posterolateral corner allowed less anterior translation than isolated ACL reconstruction.⁵ However, they failed to identify significant differences between the two groups regarding functional outcomes.

Ibrahim et al. showed that combined ACL and ALL reconstruction was effective in improving subjective and objective outcomes.¹⁶ These findings, however, were not significantly superior to isolated ACL reconstruction, except for knee fatigue test results. This may indicate that ALL reconstruction should not be performed routinely in patients undergoing ACL reconstruction.

Final Considerations

Knee joint stability improved only marginally with combined ACL and ALL reconstruction; both reconstruction techniques resulted in similar functional outcomes.

Combined ACL and ALL reconstruction significantly reduced ligament laxity assessed with a KT-2000 arthrometer; in addition, it was associated with a lower graft rupture rate compared with isolated ACL reconstruction, although there were no significant differences in functional test results between the two groups.

The main limitations of the present study included the reduced amount of papers selected for the present meta-analysis and their moderate quality.

Conflict of Interests

The authors have no conflict of interests to declare.

References

- Mall NA, Chalmers PN, Moric M, et al. Incidence and trends of anterior cruciate ligament reconstruction in the United States. *Am J Sports Med* 2014;42(10):2363–2370
- Rezende FC. Reconstrução combinada intra e extra-articular versus reconstrução intra-articular isolada do ligamento cruzado anterior: revisão sistem [tese]. São Paulo: Universidade Federal de São Paulo (UNIFESP); 2016
- Helito CP, Camargo DB, Sobrado MF, et al. Combined reconstruction of the anterolateral ligament in chronic ACL injuries leads to better clinical outcomes than isolated ACL reconstruction. *Knee Surg Sports Traumatol Arthrosc* 2018;26(12):3652–3659
- Saithna A, Thaunat M, Delaloye JR, Ouanezar H, Fayard JM, Sonnery-Cottet B. Combined ACL and anterolateral ligament reconstruction. *JBJs Essential Surg Tech* 2018;8(01):e2
- Kim SJ, Choi DH, Hwang BY. The influence of posterolateral rotatory instability on ACL reconstruction: comparison between isolated ACL reconstruction and ACL reconstruction combined with posterolateral corner reconstruction. *J Bone Joint Surg Am* 2012;94(03):253–259
- Claes S, Vereecke E, Maes M, Victor J, Verdonk P, Bellemans J. Anatomy of the anterolateral ligament of the knee. *J Anat* 2013; 223(04):321–328
- Dodds AL, Halewood C, Gupte CM, Williams A, Amis AA. The anterolateral ligament: Anatomy, length changes and association with the Segond fracture. *Bone Joint J* 2014;96-B(03):325–331

- 8 Tulloch S, Getgood A. Consideration of lateral augmentation in anatomic anterior cruciate ligament reconstruction. *Ann Joint* 2019;4:15
- 9 Hughston JC, Andrews JR, Cross MJ, Moschi A. Classification of knee ligament instabilities. Part II. The lateral compartment. *J Bone Joint Surg Am* 1976;58(02):173–179
- 10 Cavaignac E, Faruch M, Wytrykowski K, et al. Ultrasonographic Evaluation of Anterolateral Ligament Injuries: Correlation With Magnetic Resonance Imaging and Pivot-Shift Testing. *Arthroscopy* 2017;33(07):1384–1390
- 11 Sonnery-Cottet B, Saithna A, Cavalier M, et al. Anterolateral ligament reconstruction is associated with significantly reduced ACL graft rupture rates at a minimum follow-up of 2 years: a prospective comparative study of 502 patients from the SANTI study group. *Am J Sports Med* 2017;45(07):1547–1557
- 12 Guenther D, Rahnemai-Azar AA, Bell KM, et al. The anterolateral capsule of the knee behaves like a sheet of fibrous tissue. *Am J Sports Med* 2017;45(04):849–855
- 13 Kittl C, El-Daou H, Athwal KK, et al. The role of the anterolateral structures and the ACL in controlling laxity of the intact and ACL-deficient knee. *Am J Sports Med* 2016;44(02):345–354
- 14 Geeslin AG, Moatshe G, Chahla J, et al. Anterolateral Knee Extra-articular Stabilizers: A Robotic Study Comparing Anterolateral Ligament Reconstruction and Modified Lemaire Lateral Extra-articular Tenodesis. *Am J Sports Med* 2018;46(03):607–616
- 15 Inderhaug E, Stephen JM, Williams A, Amis AA. Anterolateral Tenodesis or Anterolateral Ligament Complex Reconstruction: Effect of Flexion Angle at Graft Fixation When Combined With ACL Reconstruction. *Am J Sports Med* 2017;45(13):3089–3097
- 16 Ibrahim SA, Shohdy EM, Marwan Y, et al. Anatomic reconstruction of the anterior cruciate ligament of the knee with or without reconstruction of the anterolateral ligament: a randomized clinical trial. *Am J Sports Med* 2017;45(07):1558–1566