Antegrade Double-J Stenting in Grossly Dilated and Tortuous Ureters

Manish Kiran Shreshta[1] Amey Narkhede[1] Arun Gupta[1]

[1]Department of Interventional Radiology, Sir Gangaram Hospital, New Delhi, India

Address for correspondence Arun Gupta, MD (Radiology), EBIR, Department of Interventional Radiology (Room 20A), Sir Ganga Ram Hospital, Rajinder Nagar, Delhi 110060, India (e-mail: irdrarungupta@gmail.com).

J Clin Interv Radiol ISVIR:2020;4:125–129

Abstract

Failure of retrograde approach for ureteric stenting warrants percutaneous nephrostomy with antergrade stenting to relieve the pressure symptoms and prevent the need for external drainage. However, in some tight ureteric strictures with grossly dilated tortuous ureter it may not be possible to navigate a ureteric stent across. In such instances pull through or rendezvous techniques have been advocated. Here, we have illustrated simple and novel techniques for traversing tortuous ureters with tight strictures. In one instance, a guide wire was snared via the perurethral approach and the system stabilized from both ends; the flexometallic sheath was then advanced into the urinary bladder across the stricture and a ureteric stent was deployed. In the other situation where the ureter was very tortuous, plain twisting and turning maneuver with retraction of whole assembly was done to straighten the ureter followed by advancement of the flexometallic sheath and stationing of the ureteric stent. In both the cases no significant procedure-related complications were seen and patients were discharged in stable condition. Our experience has led us to believe that occasionally all facilities may not be accessible immediately or the desired armamentarium may be unavailable for interventional radiologists, especially when the patient is on the table; in such cases, simple improvisation and techniques can come in handy to place a ureteric stent across a dilated tortuous ureter.

Keywords
- antegrade stenting
- tortuous ureter
- flexometallic sheath
- perurethral approach

Introduction

Retrograde ureteric stenting is commonly performed by endourologists to relieve benign or malignant ureteric strictures. But on failure of retrograde approach, percutaneous nephrostomy with antergrade stenting is performed by the interventional radiologist to relieve the pressure symptoms and prevent the need for external drainage.[1] However, in some tight ureteric strictures with grossly dilated tortuous ureter, a guide wire might pass through but it may not be possible to navigate a ureteric stent across. In such situations pull through or rendezvous techniques have been described, which help in steering the ureteric stent across the stricture.[2]

Technique 1

Retrograde Pull Up of Antegrade Double-J Stent in Position in Grossly Dilated Tortuous Ureter in Neurogenic Uropathy

Case 1

Clinical Details: A 14–year-old boy is a known case of atrial septal defect post endovascular surgery 7 years earlier and bilateral ureteric implant at age of 1 year for bilateral reflux. He is also a known case of syringomyelia at L2–L3 level and neurogenic bladder on clean intermittent catheterization. He also had a history of recurrent urinary tract infection (UTI). Ultrasonography (USG) was done which

DOI https://doi.org/10.1055/s-0040-1710165
ISSN 2457-0214.

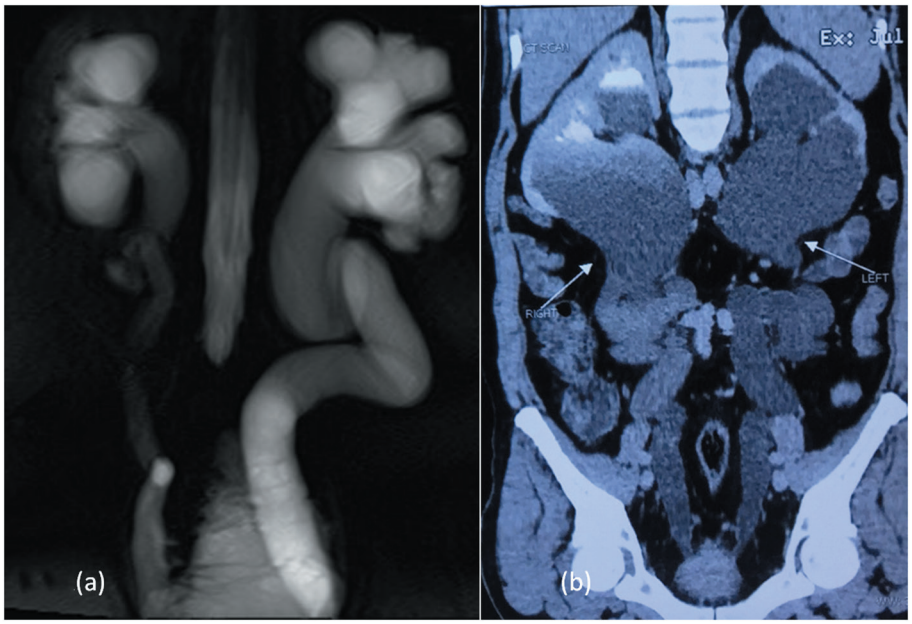

Fig. 1 Representative reformatted cross-sectional images of both cases. (**a**) Case 1—Magnetic resonance urography showing dilated toruous left ureter with gross hydronephrosis and pine cone appearance of urinary bladder (UB). (**b**) Case 2—CT urography coronal reformatted images showing bilateral gross hydroureteronephrosis (arrows) with vesico-uteric junction narrowing and nondistended UB.

showed bilateral gross hydroureteronephrosis Magnetic resonance imaging (MRI) showed partial agenesis of sacrum and coccyx with low-lying spinal cord extending up to L5, syringomyelia at L2 and L3 levels, and congenital block of C3 and C4 vertebrae. Bilateral hyroureteronephrosis with pine cone bladder and multiple diverticulae were also noted (►**Fig. 1a**). Diethylenetriaminepentacetate (DTPA) showed left obstructed hydrouerteronephrosis with moderately impaired cortical function. Right partially obstructed hydroureteronephrosis with mild moderately impaired cortical function. Cystoscopic with right retrograde pyelography was also performed.

Technique

Written informed consent was taken. Under all aseptic precaution, general anesthesia cover, USG, and fluoroscopic guidance left middle pole calyx was accessed and a 7-F introducer sheath was placed. Antegrade pyelography was performed which showed dilated tortuous ureter with narrowing at vesicoureteric junction (►**Fig. 2**). A 4-F slip catheter (Cook Medical) was used to negotiate a 0.035-in hydrophilic exchange length guide wire (Terumo) through the ureteric stricture into the bladder and contrast was injected to confirm its location (►**Fig. 2b**). Normal saline was then instilled to distend the bladder. The guide wire was then exchanged with a 0.035-in exchange length stiff guide wire (Terumo). A 7-F flexometallic sheath (65 cm) (Arrow) was passed over the wire which could not be placed into the bladder due to the tortousity of the ureter and stenosis at the vesicouretric junction. The guide wire was advanced into the urinary bladder via the urethra on which a 4-F slip catheter was placed per urethra into the urinary bladder and a goose neck snare was introduced. The renal end of the stiff guide wire was carefully advanced; its tip was snared and held in position inside the urinary bladder.

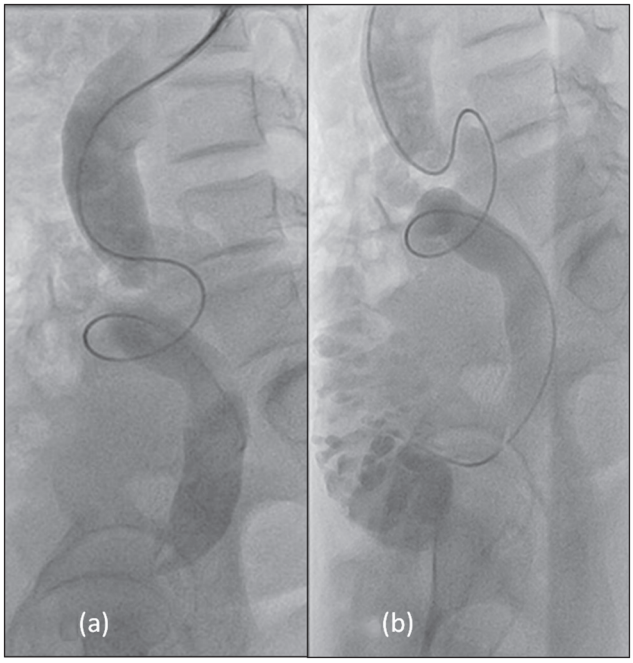

Fig. 2 Fluoroscopic images of case 1. (**a**) Uretrogram/pyelogram via the percutaneous nephrostomy sheath with slip catheter in situ showing distended tortuous ureter with short segment narrowing at the vesico-uteric junction (VUJ). (**b**) Ureterogram shows dilated tortuous ureter with sinuous course of the guide wire and slip catheter. Notice slip catheter has crossed the VUJ with contrast in urinary bladder showing pine cone appearance.

Both ends of the guide wire were secured tightly, straightened out, and the flexometallic sheath was advanced into the urinary bladder. A 6-F double-J (DJ) ureteric stent (26 cm) (Blue Neem) was inserted through the renal side along the wire into the bladder with flexometallic stent in situ.

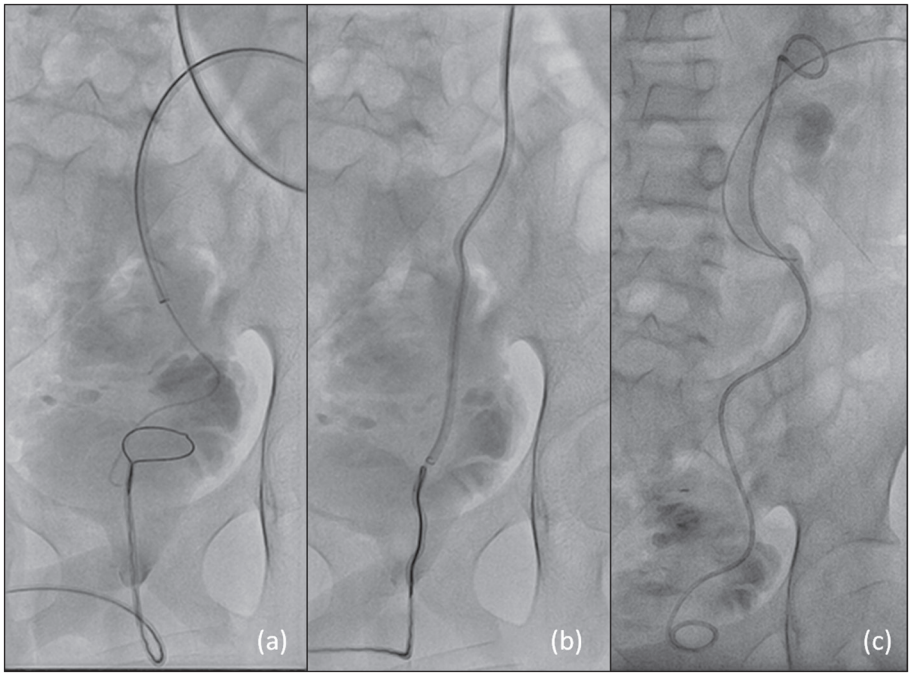

Fig. 3 Fluoroscopic images of case 1. (**a**) Lower end of the guide wire being snared via the urethra. Note the flexometallic sheath has not crossed the vesico-uteric junction (VUJ) due to the tortuosity of the ureter. (**b**) The whole assembly being straightened out by gentle pull on both ends and advancing the flexometallic sheath via the VUJ. (**c**) Final position of the double-J stent after successful placement with percutaneous access in situ.

The snare was then loosened. The guide wire and the flexometallic stent were pulled back holding the ureteric stent and pusher in position at the renal side. The guide wire was pulled back further so that the proximal loop of the ureteric stent was formed within the renal pelvis (►**Fig. 3**). A small feeding/access tube was left in renal pelvis. Foley's catheter was placed in the urinary bladder and removed the next day. The patient was discharged in stable condition.

Technique 2

Antegrade DJ Stenting after Straightening the Tortuous Dilated Ureter Using Flexometallic Sheath

Case 2

Clinical Details: A 41-year-old man was a follow-up case of bladder tumor, post transurethral resection of bladder tumor. Cystoscopic biopsy revealed cystitis glandularis. Cystoscopy also revealed diffusely inflamed bladder mucosa with erosion and nonvisualization of the ureteric orifice. His CT urography revealed bilateral gross hydroureteronephrosis with dilated tortuous ureter and narrowing at the vesicoureteric junction (►**Fig. 1b**).

Technique

The right middle pole calyx was accessed and a 7-F introducer sheath was placed under USG and fluoroscopic guidance. Antegrade pyelography was performed, which showed grossly dilated right renal pelvis with nonvisualization of ureter (►**Fig. 4a**). A 5-F slip catheter (Cook Medical) was used to negotiate a 0.035-in hydrophilic exchange length guide wire through the ureteric stricture into the bladder (►**Fig. 4b**) and contrast was injected to confirm its location. Normal saline was then instilled to distend the bladder. The guide wire was then exchanged with a 0.035-in exchange length stiff guide wire. A 7-F flexometallic sheath (65 cm) was passed over the wire which could not be negotiated into the bladder due to kinking of the sheath, attributable to the tortousity of the ureter and stenosis at the vesicouretric junction. With twisting and turning maneuver the whole assembly was pulled back slowly, which straightened the ureter. The flexometallic sheath was then advanced into the ureter with the stiff wire in situ and a 6-F DJ ureteric stent (26 cm) was inserted through the renal side along the wire into the bladder. A 10-F pigtail catheter/access tube (Surgimedik) was left in the right renal pelvis (►**Fig. 4c**). Similar methodology was performed on the left side using the twisting and turning maneuver with the steps described in (►**Fig. 5**). Foley's catheter was placed in the urinary bladder and the patient was discharged in stable condition.

Results in Both Techniques/Cases

No significant hematuria was observed. No procedure related complications were seen. The Foley's catheter was removed the following day and the patients were discharged in stable condition.

Discussion

When retrograde approach fails to cross a ureteric stricture, an antegrade approach via percutaneous nephrostomy is usually reliable to cross the stricture. A hyrophillic guide wire can be negotiated to cross the ureteric stricture which can

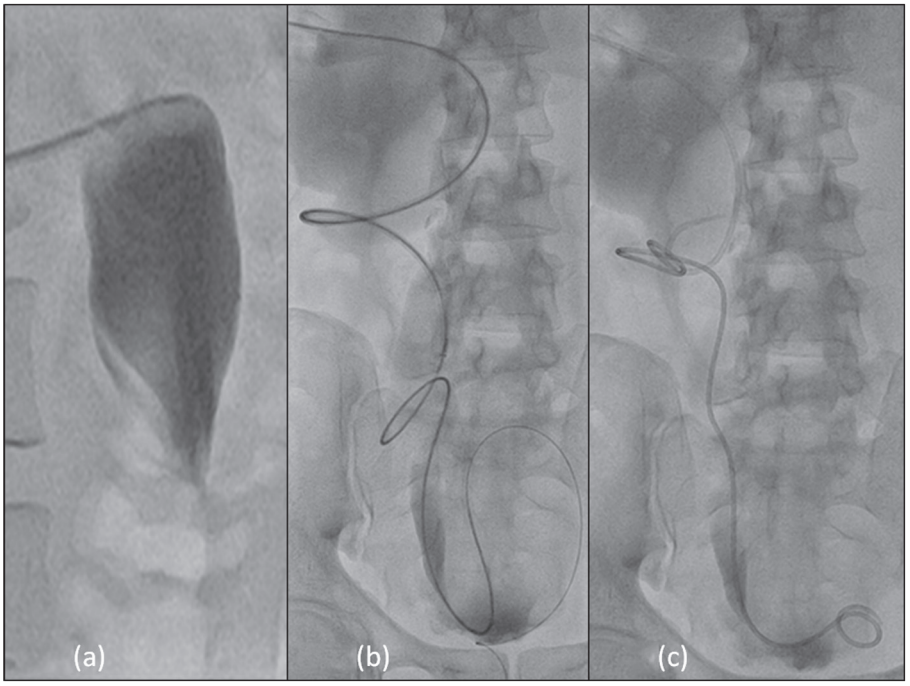

Fig. 4 Fluoroscopic images of case 2. (**a**) Magnified view of right pyelogram, showing grossly dilated right renal pelvis with nonvisualization of ureter, likely due to kinking. (**b**) Serpiginous course of the guide wire and slip catheter with kinking of the flexometallic sheath. (**c**) Right double-J stent in situ with percutaneous nephrostomy catheter in dilated right renal pelvis.

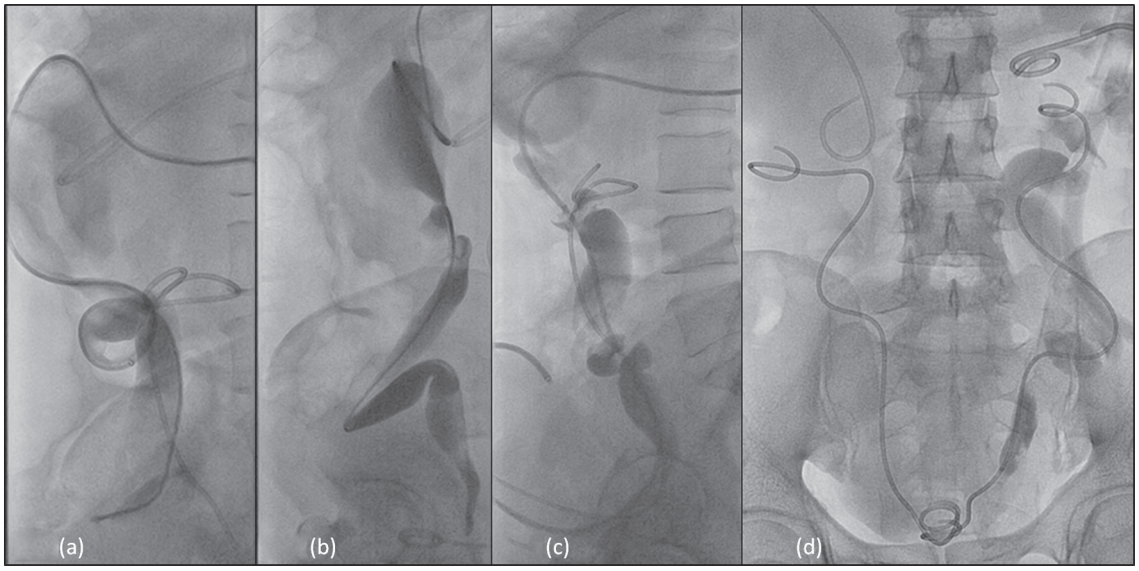

Fig. 5 Fluoroscopic images of case 2. (**a**) Partial straightening of flexometallic sheath with pull back and twisting maneuver. Visualized double-J stent is of the contralateral side placed earlier. (**b**) Ureterogram showing tortuous dilated ureter with narrowing at left vesico-uteric junction. (**c**) Lateral KUB fluoroscopic image showing straightened ureter and the flexometallic sheath in situ with its distal end in UB. (**d**) Final position of bilateral DJ stents and percutaneous nephrostomy tubes in situ after successful placement.

then be replaced by a stiff wire and balloon catheter or ureteric stent can be placed over the wire. But in some instances, due to tight stricture or tortuosity of the dilated ureter this may not be achievable. Lu et al in their study of 50 cases taken up for percutaneous internal ureteral stent placement have suggested decompressing the dilated system for few days with percutaneous nephrostomy and then reattempting the procedure.[3]

Several techniques have been described in literature such as "pull through" technique wherein the distal end of the guide wire is snared and retrieved through the urethral introducer sheath. The guide wire is then held tight in both ends and a ureteric stent is passed across the stricture and placed in situ. Combined antegrade and retrograde ureteral stenting—the rendezvous technique—has been described by Marcì et al where the distal end of the guide wire is retrieved

by cystoscopy and held in position while passing a ureteric stent over the guide wire.[2]

Our technique differs slightly to that described by other authors. Due to the gross dilatation and tortuosity of the ureter combined with short segment narrowing at the vesicoureteric junction the guide wires and the flexometallic sheaths were getting coiled up and kinked in the ureteric passage itself. So the flexometallic sheath was traversed well into the bladder to stabilize the whole assembly after straightening/fixing the guide wire via perurethral snaring. Apart from that we used 4-F slip catheter perurethra to snare the guide wire inside the urinary bladder. This was different from the pull through technique where the guide wire was retrieved through the urethral introducer or the rendezvous technique where cystoscopy was used to snare the lower end of guide wire to maintain stability. We feel that in difficult antergrade stenting with a grossly dilated tortuous ureter and short segment narrowing, perurethral snaring of guide wire combined with positioning of flexometallic sheath into the bladder can assist in stabilizing the system and enable comfortable passage of the ureteric stent.

Sometimes, as in our second case, we encounter a situation where we are able to pass a guide wire via antegrade approach into the ureter but due to the dilatation and tortuosity of the ureter it is difficult to pass a ureteric stent as the ureter is not straightened for smooth placement of the stent. Mata has described a technique employed by Fraser[4] and Clayman and Castafieda-Zufiiga[5] for straightening the dilated tortuous ureter via retrograde technique. In this technique they have employed a hollow 4- to 7-F balloon dilating catheter just distal to the difficult point, slowly dilating the balloon just enough to create a traction and pull down to straighten the ureter, hence facilitating easy passage of guide wire through the catheter.

Rich et al have also described the use of peel-away introducer set to straighten the tortuous ureteral segments. Here the guide wire is navigated to the site of obstruction/kink, followed by advancement of the introducer and peel away sheath. The introducer is then replaced by an angiographic catheter through which the soft end of a guide wire is manipulated past the obstruction, followed by advancement of the introducer, sheath, and the wire into the bladder, followed by placement of the ureteral stent. Our technique varies from the one mentioned earlier as we have used a flexometallic sheath to straighten the tortuous dilated ureter by maneuvering the sheath, pulling back and twisting the whole assembly, thereby moving it into position. Hence, sometimes in difficult situations some simple techniques can be handy avoiding the need for other equipment.

Conclusion

Our experience has been that at times all the facilities may not be accessible immediately or the desired armamentarium may be unavailable for an intervention radiologist, especially when the patient is on table; in such cases simple improvisation and techniques can come in handy as we have described to place a ureteric stent across a dilated tortuous ureter.

Conflict of Interest

There is no conflict of interest.

Acknowledgments

No financial support received.

References

1 Wirth B, Loch T, Papadopoulos I, Schmidt S. Ureteral stenting using a combined antegrade/retrograde procedure. A technique for difficult cases. Scand J Urol Nephrol 1997;31(1):35–37

2 Macrì A, Magno C, Certo A, et al. Combined antegrade and retrograde ureteral stenting: the rendezvous technique. Clin Radiol 2005;60(2):257–260

3 Lu DS, Papanicolaou N, Girard M, Lee MJ, Yoder IC. Percutaneous internal ureteral stent placement: review of technical issues and solutions in 50 consecutive cases. Clin Radiol 1994;49(4):256–261

4 Fraser KS. A technique for stenting tortuous ureters. J Urol 1987;138(4):831

5 Clayman RV, Castañeda-Zuñiga WR. Instrumentation for nephrolithotomy. In: Clayman RV, Castañeda-Zuñiga WR, eds. Techniques in Endourology: A Guide for the Percutaneous Removal of Renal and Ureteral Calculi. Chicago: Year Book Medical Publishers; 1986:185–237