


Tracheal Transection—A Novel Airway Management

Felix Fleißner¹  Max Eike Timm² Carl Philipp Lang² Thomas Lenarz² Christian Kühn¹
Daniel Benjamin Jaeger³

¹Department of Cardiac, Thoracic, Transplantation and Vascular Surgery, Hannover Medical School, Hannover, Germany

²Department of Otorhinolaryngology, Hannover Medical School, Hannover, Niedersachsen, Germany

³Department of Anesthesiology & Intensive Care Medicine, Hannover Medical School, Hannover, Niedersachsen, Germany

Address for correspondence Felix Fleißner, MD, Department of Cardiac, Thoracic, Transplantation and Vascular Surgery, Hannover Medical School, Carl-Neuberg-Strasse 1, Hannover 30625, Germany (e-mail: fleissner.felix@mh-hannover.de).

Thorac Cardiovasc Surg Rep 2020;9:e24–e28.

Abstract

Keywords

- ▶ airway
- ▶ extracorporeal life support
- ▶ trachea
- ▶ emergency room

Background Traumatic injury of the trachea is rare, especially complete transection. Its operative revision requires an interdisciplinary approach.

Case Description We hereby present a rare case of complete transection of the trachea by accident. To stabilize the patient and to allow for safe surgery, veno-venous extracorporeal support was initiated via the subclavian artery and the femoral vein. The patient was subsequently operated, and the trachea re-anastomosed with favorable outcome.

Conclusion This rare case of an accidental transection of the trachea shows the importance of a good emergency rescue chain and the ability to facilitate interdisciplinary approaches in tertiary hospitals.

Case Presentation

A 42-year-old youth worker suffered from traumatic tracheal injury during a night-time boat trip caused by a fishing line stretched across the river. He was found conscious and referred by paramedics to the nearest, primary emergency department (emergency room [ER]). After rapid hemodynamic deterioration at the primary ER, he was intubated directly through the cricotracheal wound and referred to our tertiary hospital for further treatment. At administration, the patient was sedated and cardiopulmonary impairment was regulated with moderate doses of norepinephrine and oxygen. A subsequent trauma scan using computed tomography was initiated (→ Fig. 1).

Due to the possibility of further hemodynamic instability and especially difficult airway management during the emergent operation for trachea reconstruction, we decided to partially support the patient using extracorporeal life support (ECLS). He was placed in the operating room,

where under radiographic guidance a 15-Fr (French) cannula was inserted into the left subclavian vein. An additional 23-Fr cannula was inserted into the left femoral vein and ECLS support was initiated after the application of 5,000 IE heparin at the rate of 4 L/min, SpO₂ 100%. The initial borderline blood gases improved, and we were subsequently able to fully inspect the traumatic damage after the removal of wound drapings and the cervical collar used for fixation during interhospital transfer. Close inspection of the wound showed a 15-cm long, gaping wound down to the intact esophagus and with the larynx detached from the trachea (→ Figs. 2 and 3). Despite the trauma, no vessels were injured, and bleeding was surprisingly minor. After wound debridement a surgical tracheostoma was formed followed by trachea reconstruction, which was achieved using direct, single stitched sutures. After successful reconstruction, the patient was weaned off the veno-venous-ECLS support and the cannulas were removed without complications. The patient was administered to

received
January 30, 2020
accepted
March 14, 2020

DOI <https://doi.org/10.1055/s-0040-1710586>.
ISSN 2194-7635.

© 2020 Georg Thieme Verlag KG
Stuttgart · New York

License terms



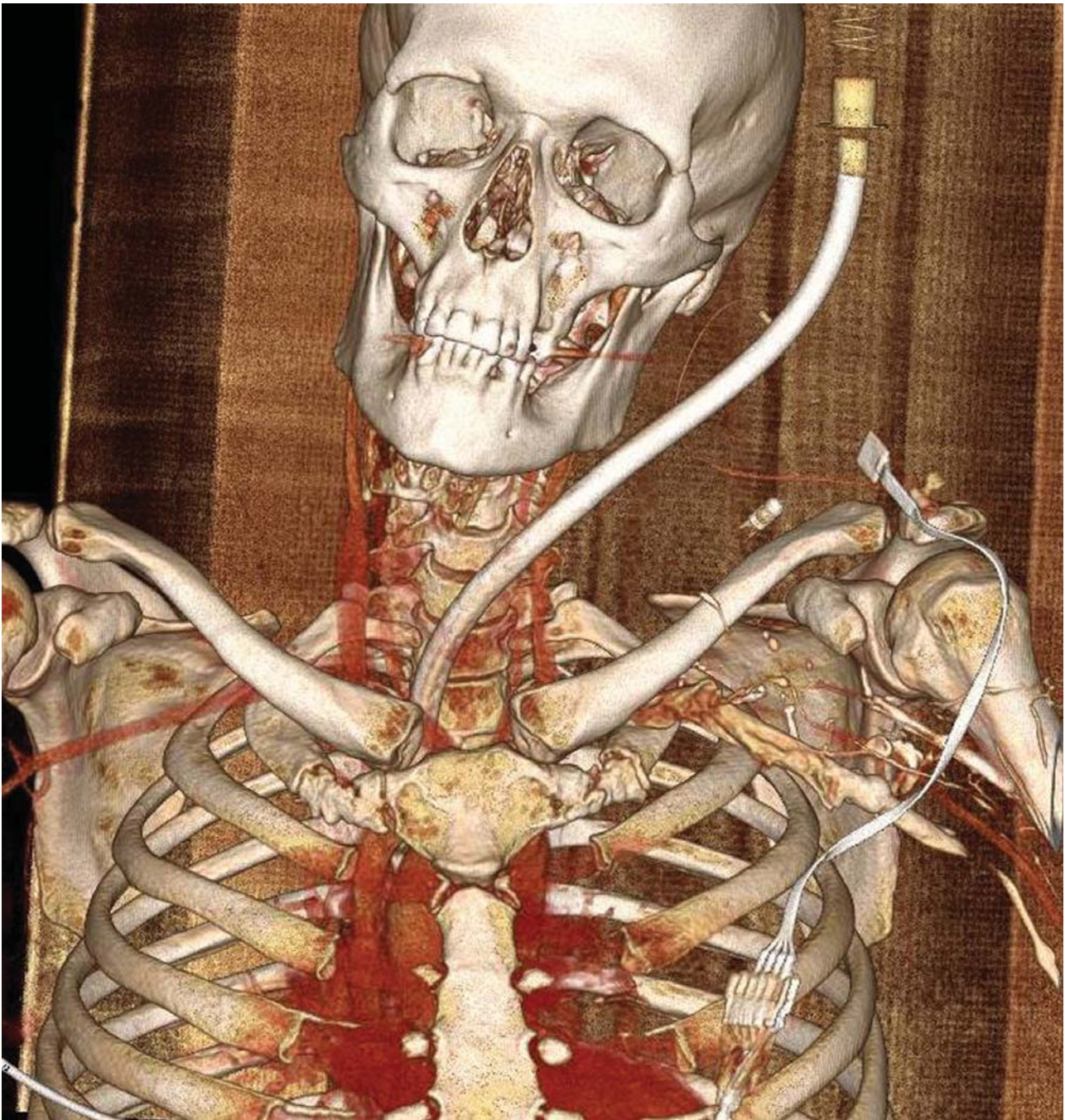


Fig. 1 Computed tomography showing the direct cannulation of the trachea.

the intensive care unit. He recovered from the trauma and was administered to the outpatient clinic, but still bearing up with tracheostoma due to paralysis of both vocal cords which is the most commonly associated injury in approximately 50% of all patients with blunt trauma.¹

Conclusion

Blunt trauma to the trachea (“clothesline injury”) is uncommon; however, several case reports have been published.² Sharp trauma, causing an open transection of the trachea is even rarer and requires distinct differences in patient man-

agement, especially airway management.³ Airway management remains vital in such a case. Facilitating the 24 × 7 ECLS standby can be of utmost importance in such or a similar case. By using ECLS support, we were able to partially replace the lung function and thus we safely accessed and operated the patient without the need for rapid and possible insecure reintubation.

Authors' Contribution

F.F. performed the ECLS implantation, literature review, reviewed the patient's paper and electronic clinical records to collect data, interpreted the data, and wrote the first draft

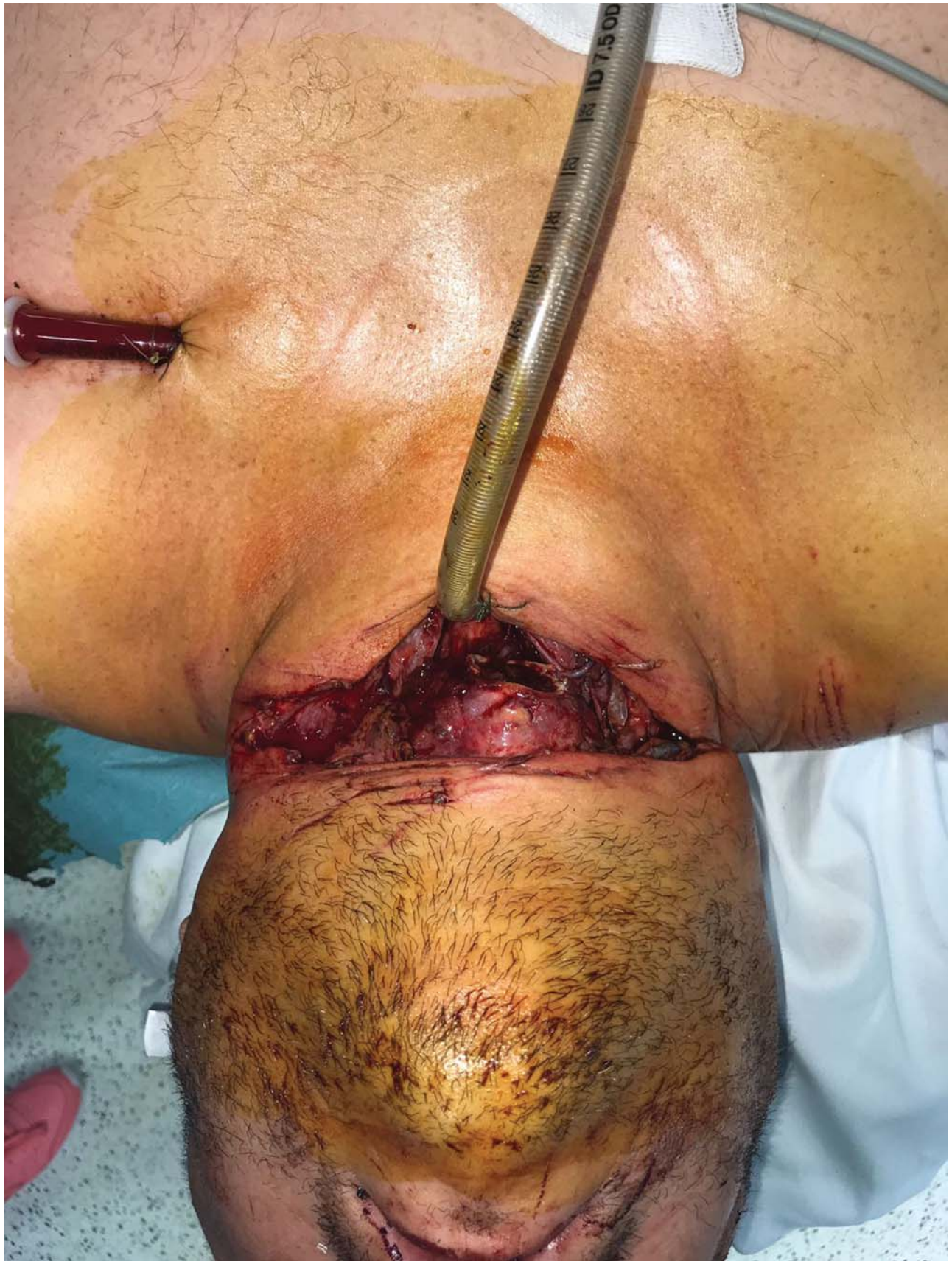

Fig. 2 A 15-Fr cannula inserted into the left subclavian vein for ECLS support. The endotracheal tube (ET) is fixed with gauze bandages and a cervical collar. ECLS, extracorporeal life support.

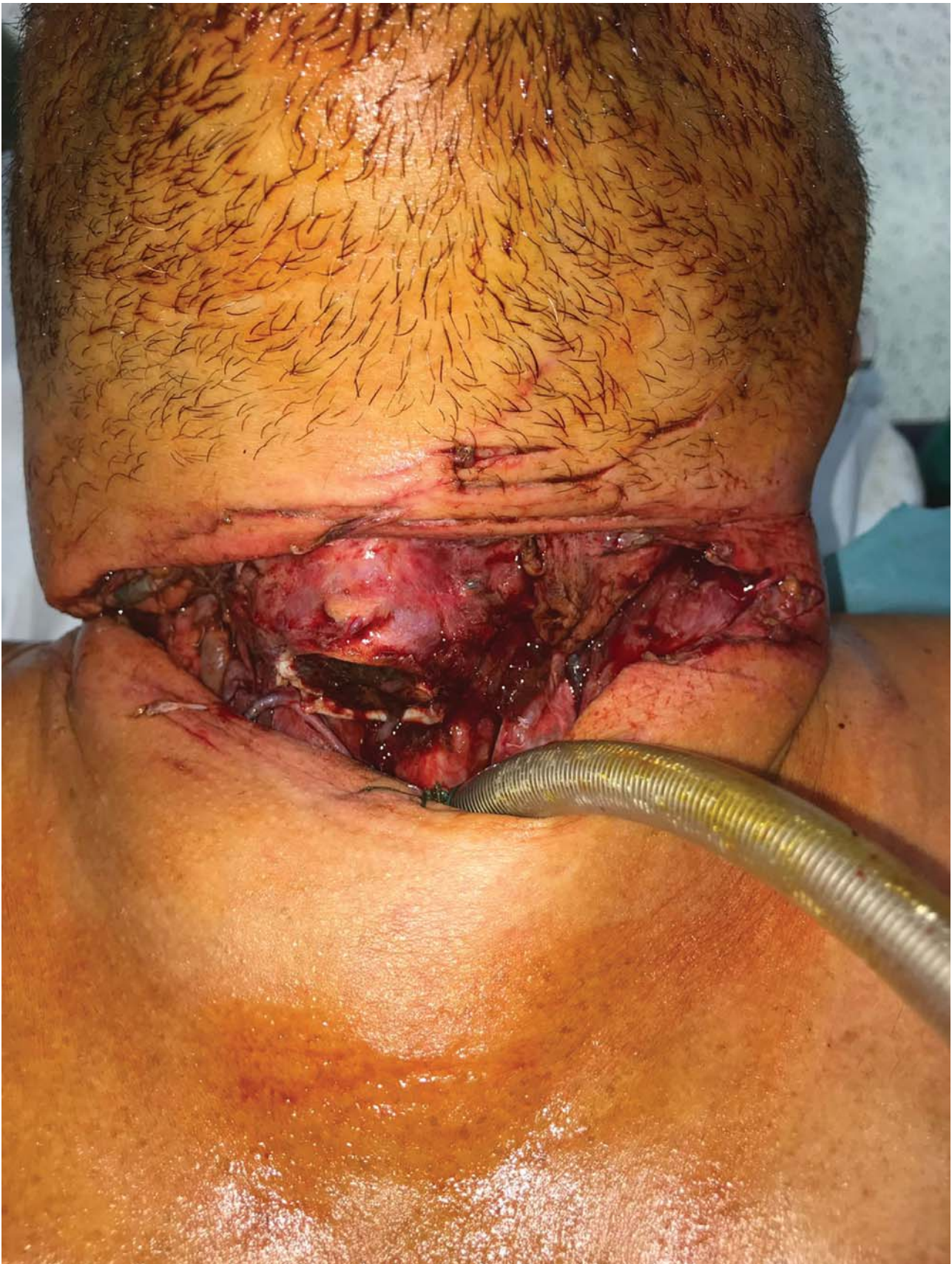

Fig. 3 Intraoperative situs of the wound. The trachea is completely dissected; however, despite the severe trauma, no major vessels were damaged.

of the article. He was also involved with critical revision of the article. D.B.J., M.E.T., C.P.L., C.K., and T.L. reviewed the patient's electronic clinical records to collect additional data and helped in interpreting the data. They were also involved in critical revision of the article and provided supervision for the first author's activities. All authors approved the final version of the article for submission.

Disclosure

The authors have no disclosures.

Source of Funding

None declared.

Conflict of Interest

None declared.

References

- 1 Reece GP, Shatney CH. Blunt injuries of the cervical trachea: review of 51 patients. *South Med J* 1988;81(12):1542–1548
- 2 Naqvi Sayyed EH, Sadik A, Beg MH, Azam H, Nadeem R, Eram A. Successful management of suicidal cut throat injury with internal jugular, tracheal and esophageal transection: a case report. *Trauma Case Rep* 2017;13:30–34
- 3 Jean YK, Potnuru P, Diez C. Airway management of near-complete tracheal transection by through-wound intubation: a case report. *A&A Pract* 2018;11(11):312–314