Pediatric Non–Brain Stem High-Grade Glioma: A Single-Center Experience

Ehsan Alimohammadi[1] Seyed Reza Bagheri[1] Nasrin Delfani[2,3] Roya Safari-Faramani[3] Maryam Janatolmakan[2]

[1]Department of Neurosurgery, Kermanshah University of Medical Sciences, Imam Reza Hospital, Kermanshah, Iran
[2]Clinical Research Development Center, Imam Reza Hospital, Kermanshah University of Medical Sciences, Kermanshah, Iran
[3]Research Center for Environmental Determinants of Health, Kermanshah University of Medical Sciences, Kermanshah, Iran

Address for correspondence Ehsan Alimohammadi, MD, Kermanshah University of Medical Sciences, Imam Reza Hospital, Kermanshah, Iran (e-mail: Hafez125@gmail.com).

Indian J Neurosurg:2020;9:162–169

Abstract

Background Pediatric high-grade gliomas (PHGGs) consist of a heterogeneous class of central nervous system (CNS) neoplasms with a poor prognosis. We aimed to present our 10-year experience in the management of children with high-grade glioma focusing on patients' survival and related factors.

Methods All pediatric patients with high- grade glioma (HGG) who were admitted to our center between May 2009 and May 2018 were investigated. Overall survival (OS) was calculated from the time of diagnosis until the day of death. The impact of suggested variables on survival was evaluated using the univariate and multivariate analyses.

Results There were 41 children with non–brain stem high-grade glioma (NBSHGG). The mean OS of patients was 21.24 ± 10.16 months. The extent of resection (p = 0.002, hazard ratio [HR] = 4.84), the grade of the tumor (p = 0.017, HR = 4.36), and temozolomide (TMZ) therapy (p = 0.038, HR = 3.57) were the independent predictors of OS in children with NBSHGG. Age, gender, tumor location, and size of tumor were not associated with the survival of these patients.

Conclusion HGGs are uncommon pediatric tumors with an aggressive nature and a poor prognosis. Our results revealed that in NBSHGG cases, children with maximal safe tumor resection and children that received temozolomide therapy as well as children with grade III of the tumor had higher survival.

► **Keywords:**
► pediatric high-grade gliomas
► overall survival
► extent of resection
► temozolomide

Introduction

Brain tumors are the most common solid cancers in pediatric patients.[1] High-grade glioma (HGG) compromises approximately 15 to 20% of all central nervous system (CNS) tumors in children.[2,3] The incidence of pediatric HGG is about 0.85 per 100,000.[4]

Although glioblastoma multiforme (WHO grade IV) is the most common primary brain tumor in adults, anaplastic astrocytoma (WHO grade III) is more common than glioblastoma in children.[5] Recent studies have established that pediatric HGGs (PHCGs) are biologically distinct from their adult counterparts, with nearly half of these patients harboring somatic mutations in histone genes.[6,7]

In spite of its relative rarity, HGG is a devastating disease in children with significant morbidity and mortality.[1,8]

Cerebral hemispheres are the most commonplace of PHGG, however, it can arise from other places including the brain stem (30%), the thalamus (13%), the spinal cord (3%), and the cerebellum (5%).[9,10]

DOI https://doi.org/10.1055/s-0040-1712067
ISSN 2277-954X.

The standard care of adult glioblastoma multiforme (GBM) consists of maximal surgical resection followed by concurrent and adjuvant chemoradiation.[11]

Although there is no such standard protocol for PHGG, a similar protocol is used by most physicians across the world.[2] Despite such a multimodal approach to treatment, patient survival is already poor.[12]

In the present study, we aimed to present our 10-year experience in managing pediatric patients with a high-grade glioma, focusing on the clinical presentation, prognostic factors, clinical outcomes, and patients' survival.

Materials and Methods

In this retrospective cohort study, we investigated pediatric patients with high-grade glioma.

All patients with 18 years of age or younger who were diagnosed to have a high-grade glioma and managed at our center between May 2009 and May 2018 were included (►**Fig. 1**). Of a total of 323 patients with a high-grade glioma managed at our center, 53 cases were found to be in the pediatric age group. We excluded 12 patients with diffuse intrinsic pontine glioma from the study. The medical records of all patients including demographic features, clinical presentation, surgical and adjuvant therapies, and follow-up data were reviewed. The present study was approved by the research committee of the Kermanshah University of Medical Sciences and the medical ethics committee. Informed written consent was obtained from all patients' relatives before any intervention and treatment and for publication of deidentified data.

All patients underwent surgical resection followed by radiation therapy.

Postoperative radiation therapy was started within 4 to 6 weeks of surgery (54 grays, at 1.8 grays per fraction daily over 6 weeks).

Twenty-five patients received concurrent temozolomide (TMZ 75 mg/m^2) followed by 6 cycles of maintenance treatment (150–200 mg/m^2 [day 1–5] every 4 weeks).

Based on the early postoperative magnetic resonance imaging (MRI), the extent of resection was classified into three groups: the total resection group (resection more than 90%), subtotal group (resection between 10 and 90%), and the biopsy group (resection < 10%).

The surgical sample of each patient was investigated by an experienced pathologist meticulously.

The immunostaining was performed for the detection of Ki67 and p53. The labeling index for p53 was defined as the percentage of immunostained cells per 200 cells in 5 fields. The presence of Ki67 was determined using the percentage of positive cells per 1,000 cells.

Statistical Analysis

Overall survival defined as the time from diagnosis till death due to all causes or the latest date of follow up. Kaplan–Meier method was used to estimate overall survival (OS). The log-rank test was employed in order to test the survival patterns. The Cox proportional hazards models were used to identify the predictors of mortality. Crude and adjusted hazard ratios with 95% confidence intervals were calculated for each variable. The level of statistical

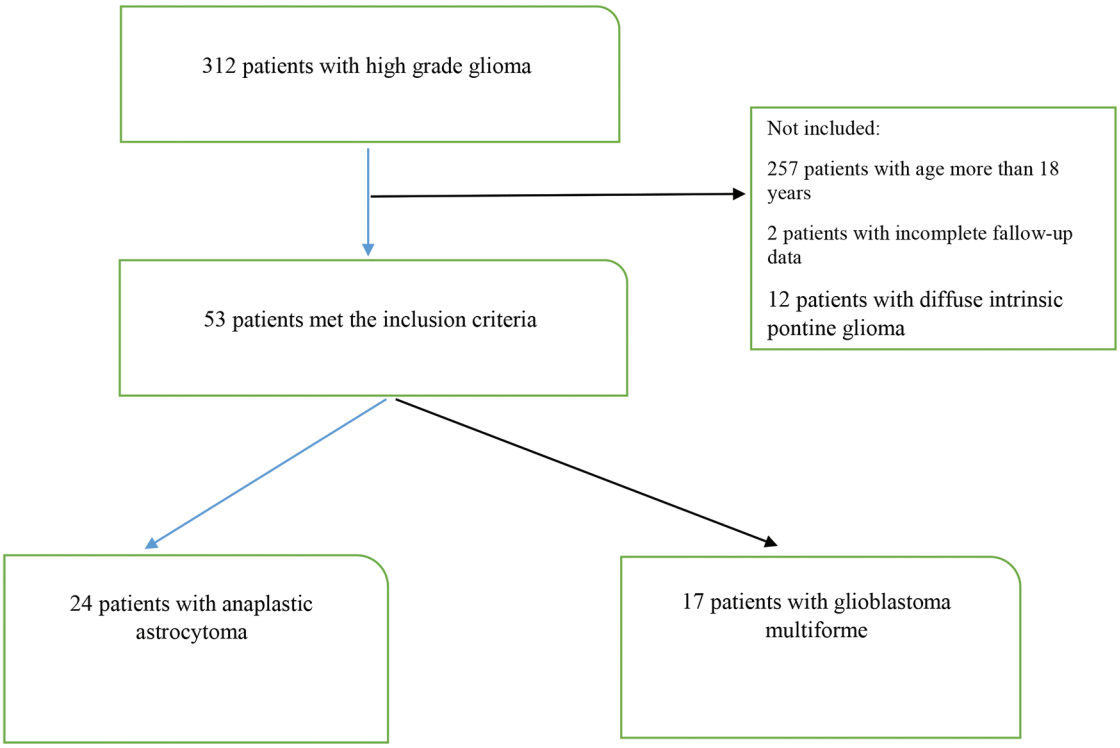

Fig. 1 Flowchart of study population.

significance was set at 0.05. The preliminary assumptions including proportional hazards assumption has been checked before the analysis; it was not violated. All analyses were performed with Stata software version 14.2 (StataCorp, College Station, Texas, United States).

Results

Non–Brain Stem High-Grade Glioma

A total of 41 children with the mean age of 9.12 ± 3.42 years were evaluated. There were 21 boys (51.2%) and 20 girls (48.8%). The mean OS was 21.24 ± 10.16 months. Anaplastic astrocytoma (grade III) and glioblastoma multiforme (grade IV) were diagnosed in 24 (58.5%) and 17 (41.5%) patients, respectively (►**Table 1**).

Different presentations of the patients have been shown in ►**Table 2**.

The most common site of the tumor was frontal (24.4%), followed by temporal (19.5%), parietal (14.6%), and thalamus (14.6%) (►**Table 1**).

Gross total resection was achieved in 19 patients (46.4%), 16 patients (39.0) underwent partial resection and biopsy was performed in 6 patients (14.6%). Age, gender, tumor location, and size of the tumor were not associated with survival (►**Table 3**). Based on the univariate analyses extent of surgery ($p = 0.001$), karnofsky performance scale (KPS) ($p < 0.0001$), TMZ therapy ($p < 0.0001$), grade of tumor ($p < 0.0001$), Ki67 ($p = 0.001$), and p53 ($p = 0.017$) were the predictors of the OS (►**Table 3**).The extent of resection ($p = 0.002$, hazard ratio [HR] = 4.84), the grade of the tumor ($p = 0.017$, HR = 4.36), and TMZ therapy ($p = 0.038$, HR = 3.57) were the independent predictors of the OS according to the adjusted Cox model (►**Table 3**, ►**Fig. 2**–**4**). According to multivariate analyses, the probability of death in children who underwent partial resection was more than those who underwent gross total tumor resection by 5 times ($p < 0.005$). The odds of death were higher in children who did not receive TMZ compared to those receiving it by 3.57 times ($p < 0.05$). Patients with GBM had a higher chance of death in comparison with those with anaplastic astrocytoma by 4.36 times ($p < 0.0001$).

Discussion

Our results showed that the extent of resection, the grade of the tumor, and temozolomide therapy were the independent predictors of OS in children with NBSHGG.

PHGGs consist of a heterogeneous class of CNS neoplasms that affect pediatric patients of different ages.[8,10] They can originate from different sites of CNS and have different histologic aspects.[11] While gliomas compromise 40 to 50% of all CNS tumors in children, supratentorial HGGs represent only 6 to 12% of all primary brain neoplasms in children.[13,14] Depending on tumor grade, PHGGs are divided into either anaplastic astrocytoma (WHO grade III) or glioblastoma multiforme (WHO grade IV). PHGGs are characterized by some histopathological features, including nuclear atypia, hypercellularity, and vascular proliferation.[2,15] Symptoms of PHGG are various and may be nonspecific. The most common presentations are increased intracranial hypertension, seizure, long tract signs, and motor weakness. Some studies have declared a higher incidence of seizure in PHGG compared with adult HGG.[5,16] The incidence of seizure has been reported in about 30% of affected children.[17,18] The reported survival for PHGG ranges from 8 to 70 months. Several factors including the extent of resection, tumor grade, age, and KPS have been suggested as the predictors of outcome in PHGG.[1,9,10] Several studies have established the positive impact of maximal safe tumor resection on the survival of children with HGG.[9,19] Nikitović et al in their study evaluated 15 children with glioblastoma. The median OS of their cases was 13.5 months. They found that there was no relationship between age, gender, type of radiotherapy, or tumor location with patient survival. However, pediatric patients who underwent gross total resection have a longer survival.[6]

In another study, Das et al investigated 65 cases with glioblastoma. The median progression-free survival and OS of their cases were 10 and 20 months, respectively. They reported that the extent of surgical tumor resection was the strongest predictor of patients' survival.[20]

Perkins et al, in a retrospective study, evaluated 24 pediatric patients with glioblastoma. In their study, median OS was 13.5 months as well as the 2-year OS rate was 32%. There was no relationship between OS and patients' age, gender, tumor location, radiation volume, radiation dose, or the use of chemotherapy. However, they found that patients with gross total resection had a longer survival.[12] Using advanced techniques such as intraoperative navigation, intraoperative magnetic resonance imaging, and intraoperative cortical mapping as well as using easily available cheaper useful alternatives like ultrasonography may help to a larger extent of tumor resection.[1,7]

Rapid analysis of the surgical sample for molecular hallmarks such as isocitrate dehydrogenase (IDH) mutation can facilitate a molecular diagnosis within no time. This could provide better intraoperative decision-making about extent of resection.[21,22]

Radiotherapy at the dose of 50 to 60 grays fractionated over 6 weeks is a significant compartment of treatment in PHGG.[5] Radiotherapy usually is not used in children younger than 3 years due to its adverse effect on the developing brain.[5,16]

The impact of concomitant and adjuvant TMZ therapy on improving survival in adults with HGG has been demonstrated.[4,23] TMZ is a cytotoxic drug acts by alkylation at the O6 position of guanine.[24] TMZ can improve survival by diminishing methylguanine DNA methyltransferase (MGMT) promoter expression in tumor cells.[25] Although our findings demonstrated that children who received TMZ had longer survival, most studies demonstrated that TMZ therapy did not improve survival in PHGG.[24,25]

Table 1 Basic characteristics of the children with non–brain stem high-grade glioma

Variable	Frequency	Percentage
Gender		
Male	21	51.2
Female	20	48.8
KPS		
>70	35	85.4
<70	6	14.6
Extent of surgical resection		
Gross total resection	19	46.4
Partial resection	16	39.0
Biopsy	6	14.6
Temozolomide therapy		
Yes	25	61.0
No	16	39.0
Tumor location		
Frontal	10	24.4
Temporal	8	19.5
Parietal	6	14.6
Occipital	4	9.8
Insular	4	9.8
Cerebellar	3	7.3
Thalamus	6	14.6
Tumor size		
<3 cm	9	22.0
3-5 cm	23	56.1
>5 cm	9	22.0
Grade of tumor		
Grade III (anaplastic astrocytoma)	24	58.5
Grade IV (glioblastoma multiforme)	17	41.5
Outcome		
Died	33	80.5
Survived	8	19.5
Ki67		
<25%	18	43.9
>25%	16	39/0
Unavailable	7	17.1
P53		
>50%	16	39.0
<50%	19	46.3
Unavailable	6	14.6
Age (mean ± standard deviation), year	9.12 ± 3.42	
Overall survival (mean ± standard deviation), month	21.24 ± 10.16	

Abbreviation: KPS, karnofsky performance scale.

Table 2 Different presentations of the children with non–brain stem high-grade glioma

Number of patients	Presentations
24	Increased intracranial pressure
18	Seizures
9	Motor weakness
3	Visual failure
2	Ataxia

Limitations

There are several limitations to this study. Our study was a retrospective analysis of a single-center experience. The small sample size and the lack of a complete molecular profile for all the cases were other important limitations of our work. In spite of the mentioned limitations, our study could be a valuable addition to our knowledge about PHGG. Finally, we suggest multicenter prospective studies to investigate prognostic factors in PHGG.

Table 3 Predictive factors of overall survival in children with non–brain stem high-grade glioma

Variable		Crude HR (95% confidence interval)	*p*-Value	Adjusted HR (95% confidence interval)	
Gender	Male	1			
	Female	0.74 (0.36, 1.52)	0.410		
KPS	>70	1		1	
	<70	7.19 (2.43, 21.30)	<0.0001	2.18 (0.65, 7.31)	0.205
Extent of surgical resection	Gross total resection	1		1	
	Partial resection	3.92 (1.74, 8.83)	0.001	4.84 (1.76, 13.26)	0.002
	Biopsy	8.88 (2.58, 30.54)	0.001	2.07 (0.49, 8.72)	0.322
Temozolomide	Yes	1		1	
	No	9.91 (3.58, 27.37)	<0.0001	3.57 (1.07, 11.84)	0.038
Tumor location	Frontal	1			
	Temporal	0.61 (0.18, 1.99)	0.413		
	Parietal	0.58 (0.19, 1.18)	0.354		
	Occipital	0.83 (0.25, 2.75)	0.765		
	Insular	0.85 (0.25, 2.93)	0.803		
	Cerebellar	1.27 (0.33, 4.78)	0.719		
	Thalamus	0.88 (0.26, 2.91)	0.845		
Tumor size	<3 cm	1			
	3–5 cm	1.77 (0.66, 4.77)	0.257		
	>5 cm	2.37 (0.78, 0.72)	0.129		
Grade of tumor	Grade III (anaplastic astrocytoma)			1	
	Grade IV (glioblastoma multiforme)	6.37 (2.79, 14.56)	<0.0001	4.36 (1.30, 14.62)	0.017
Ki67	<25%	1		1	
	>25%	7.42 (2.84, 19.41)	<0.0001	2.63 (0.74, 9.33)	0.135
	Unavailable	1.29 (0.49, 3.37)	0.597	0.78 (0.07, 8.46)	0.843
P53	>50%	1		1	
	<50%	2.62 (1.19, 5.78)	0.017	0.98 (0.31, 3.09)	0.979
	Unavailable	1.20 (0.43, 3.36)	0.723	2.33 (0.18, 30.50)	0.519
Age		1.03 (0.91, 1.15)	0.666		

Abbreviations: HR, hazard ratio; KPS, Karnofsky Performance Scale.

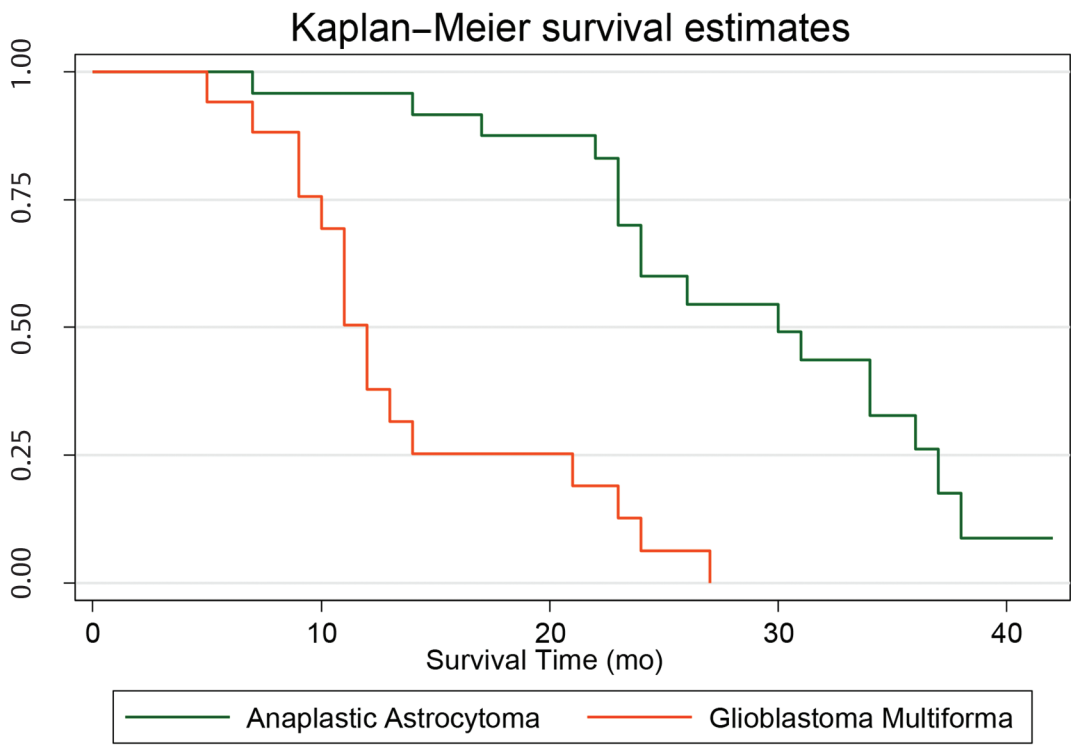

Fig. 2 Comparison of Kaplan–Meier estimates of survival between the patients with anaplastic astrocytoma and Glioblastoma multiforme (*p*-value = <0.0001).

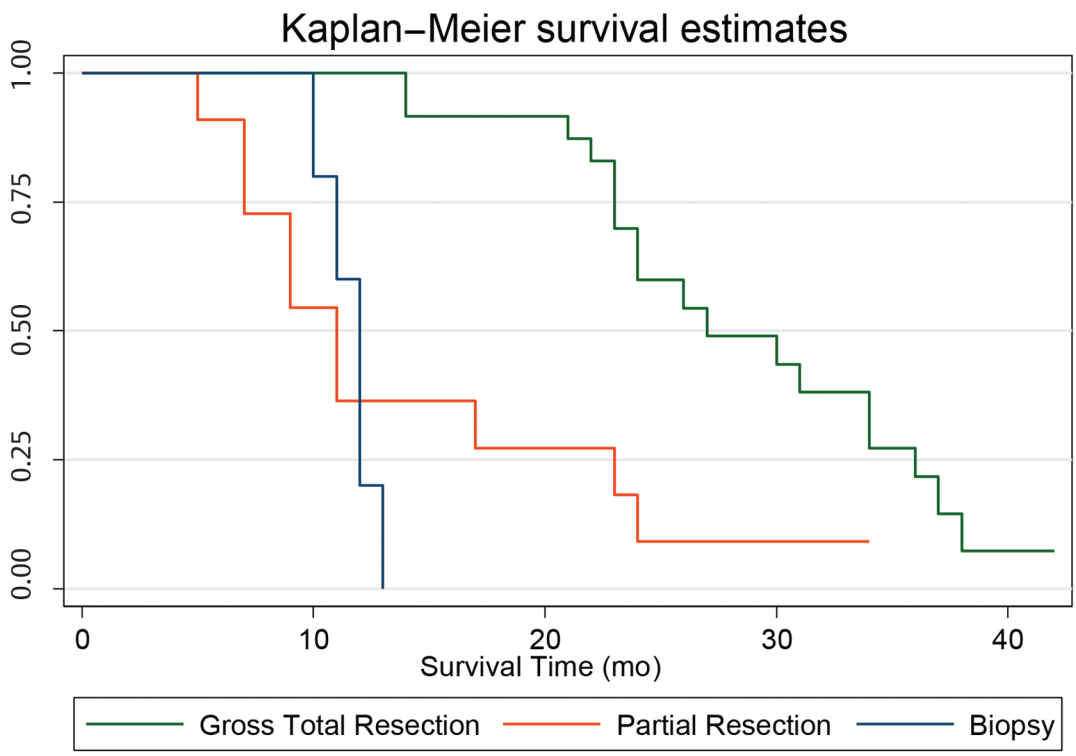

Fig. 3 Comparison of Kaplan–Meier estimates of survival between the patients with different amount of tumor resection (*p*-value = <0.0001).

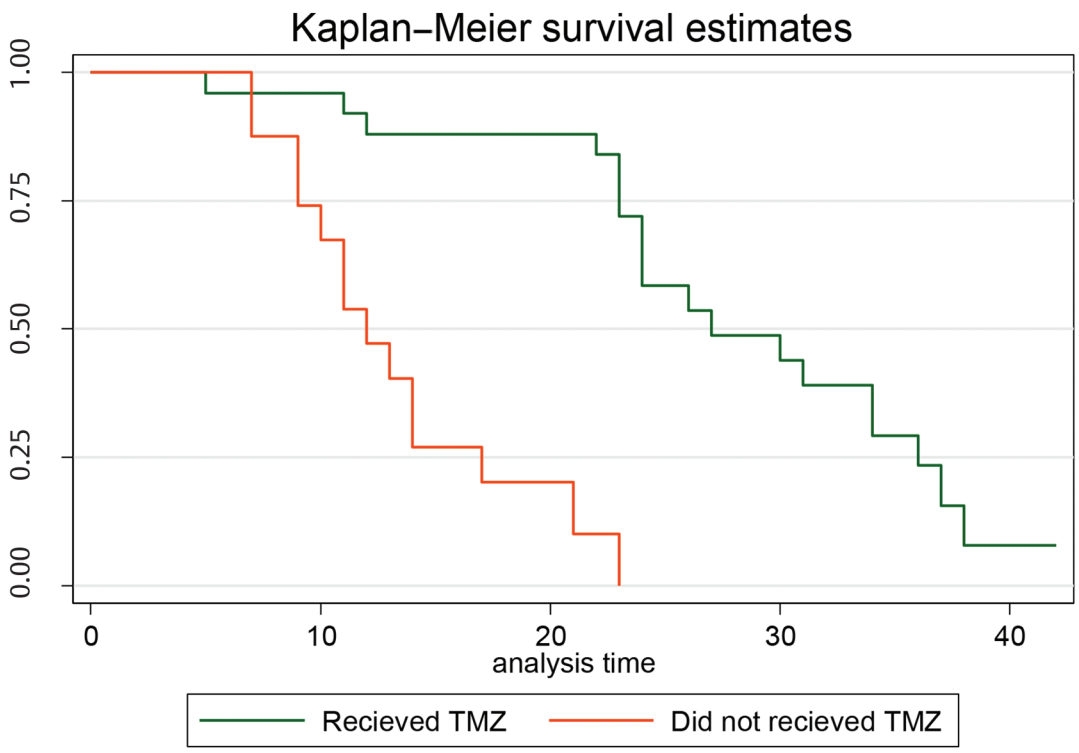

Fig. 4 Comparison of Kaplan–Meier estimates of survival between the patients received temozolomide (TMZ) with children that did not receive TMZ (*p*-value = <0.0001).

Conclusion

HGGs are uncommon pediatric tumors with an aggressive nature and a poor prognosis. Our results showed that in NBSHGG cases, those with maximal safe tumor resection and those that received temozolomide therapy as well as children with anaplastic astrocytoma had higher survival.

Note

All data are available from the corresponding author upon reasonable request.

Ethical Approval

The study received ethical approval from the Kermanshah University of Medical Science Ethics Committee.

Authors' Contributions

E. A. and S. R. B. had the idea for this study. E. A. and M. J. participated in outlining the concept and design. N. D. and M. J. did the data acquisition. E. A. and R. S. did the statistical analysis and wrote the first draft of the manuscript. E. A., S. R. B., R. S., and N. D. revised the final manuscript. All authors have read and approved the manuscript.

Funding

None.

Conflict of Interest

None declared.

Acknowledgments

We appreciate the clinical Research Development Center of Imam Reza Hospital for their wise advice.

References

1 Adams H, Adams HH, Jackson C, Rincon-Torroella J, Jallo GI, Quiñones-Hinojosa A. Evaluating extent of resection in pediatric glioblastoma: a multiple propensity score-adjusted population-based analysis. Childs Nerv Syst 2016;32(3):493–503
2 Blionas A, Giakoumettis D, Klonou A, Neromyliotis E, Karydakis P, Themistocleous MS. Paediatric gliomas: diagnosis, molecular biology and management. Ann Transl Med 2018;6(12):251
3 Bradley WG. Achieving gross total resection of brain tumors: intraoperative MR imaging can make a big difference. AJNR Am J Neuroradiol 2002;23(3):348–349
4 Broniscer A. Past, present, and future strategies in the treatment of high-grade glioma in children. Cancer Invest 2006;24(1):77–81
5 Mak KS, Lee SW, Balboni TA, Marcus KJ. Clinical outcomes and toxicity following palliative radiotherapy for childhood cancers. Pediatr Blood Cancer 2018;65(1)
6 Nikitović M, Stanić D, Pekmezović T, et al. Pediatric glioblastoma: a single institution experience. Childs Nerv Syst 2016;32(1):97–103
7 Lam S, Lin Y, Zinn P, Su J, Pan I-W. Patient and treatment factors associated with survival among pediatric glioblastoma patients: a surveillance, epidemiology, and end results study. J Clin Neurosci 2018;47:285–293
8 Perkins SM, Rubin JB, Leonard JR, et al. Glioblastoma in children: a single-institution experience. Int J Radiat Oncol Biol Phys 2011;80(4):1117–1121

9 Yang T, Temkin N, Barber J, et al. Gross total resection correlates with long-term survival in pediatric patients with glioblastoma. World Neurosurg 2013;79(3-4):537–544
10 Eisenstat DD, Pollack IF, Demers A, et al. Impact of tumor location and pathological discordance on survival of children with midline high-grade gliomas treated on Children's Cancer Group high-grade glioma study CCG-945. J Neurooncol 2015;121(3):573–581
11 Song KS, Phi JH, Cho BK, et al. Long-term outcomes in children with glioblastoma. J Neurosurg Pediatr 2010;6(2):145–149
12 Perkins SM, Rubin JB, Leonard JR, et al. Glioblastoma in children: a single-institution experience. Int J Radiat Oncol Biol Phys 2011;80(4):1117–1121
13 Fangusaro J. Pediatric high grade glioma: a review and update on tumor clinical characteristics and biology. Front Oncol 2012;2:105
14 Jones C, Karajannis MA, Jones DTW, et al. Pediatric high-grade glioma: biologically and clinically in need of new thinking. Neuro-oncol 2017;19(2):153–161
15 Das KK, Mehrotra A, Nair AP, et al. Pediatric glioblastoma: clinico-radiological profile and factors affecting the outcome. Childs Nerv Syst 2012;28(12):2055–2062
16 Ehrstedt C, Kristiansen I, Ahlsten G, et al. Clinical characteristics and late effects in CNS tumours of childhood: do not forget long term follow-up of the low grade tumours. Eur J Paediatr Neurol 2016;20(4):580–587
17 Muhammed A, Gaber MS, Elbeltagy M, et al. Risk stratification of pediatric high-grade glioma: a newly proposed prognostic score. Childs Nerv Syst 2019;35(12):2355–2362
18 Broniscer A, Gajjar A. Supratentorial high-grade astrocytoma and diffuse brainstem glioma: two challenges for the pediatric oncologist. Oncologist 2004;9(2):197–206
19 Finlay JL, Zacharoulis S. The treatment of high grade gliomas and diffuse intrinsic pontine tumors of childhood and adolescence: a historical—and futuristic—perspective. J Neurooncol 2005;75(3):253–266
20 Das KK, Mehrotra A, Nair AP, et al. Pediatric glioblastoma: clinico-radiological profile and factors affecting the outcome. Childs Nerv Syst 2012;28(12):2055–2062
21 Koschmann C, Zamler D, MacKay A, et al. Characterizing and targeting PDGFRA alterations in pediatric high-grade glioma. Oncotarget 2016;7(40):65696–65706
22 Uppar AM, Sugur H, Prabhuraj AR, et al. H3K27M, IDH1, and ATRX expression in pediatric GBM and their clinical and prognostic significance. Childs Nerv Syst 2019;35(9):1537–1545
23 Stupp R, Mason WP, van den Bent MJ, et al; European Organisation for Research and Treatment of Cancer Brain Tumor and Radiotherapy Groups; National Cancer Institute of Canada Clinical Trials Group. Radiotherapy plus concomitant and adjuvant temozolomide for glioblastoma. N Engl J Med 2005;352(10):987–996
24 Cohen KJ, Pollack IF, Zhou T, et al. Temozolomide in the treatment of high-grade gliomas in children: a report from the Children's Oncology Group. Neuro-oncol 2011;13(3):317–323
25 Jakacki RI, Cohen KJ, Buxton A, et al. Phase 2 study of concurrent radiotherapy and temozolomide followed by temozolomide and lomustine in the treatment of children with high-grade glioma: a report of the Children's Oncology Group ACNS0423 study. Neuro-oncol 2016;18(10):1442–1450

