



# Larger Chondral Lesions Treated with Collagen Membrane – Matrix-Induced Autologous Chondrogenesis – Show Larger Increase in Clinical Scores

## *Lesões condrais maiores tratadas com uso de membrana de colágeno – condrogênese autóloga induzida por matriz – apresentam maior aumento nos escores clínicos*

Mateus Kenji Christo Miyahira<sup>1</sup> João Victor Novaretti<sup>2</sup> Diego Costa Astur<sup>2</sup>   
Camila Cohen Kaleka<sup>1</sup> Joicemar Tarouco Amaro<sup>1</sup> Moisés Cohen<sup>2</sup>

<sup>1</sup> Cohen Institute of Orthopedics, Rehabilitation and Sports Medicine, São Paulo, SP, Brazil

<sup>2</sup> Department of Orthopedics and Traumatology, Escola Paulista de Medicina, Universidade Federal de São Paulo, São Paulo, SP, Brazil

Address for correspondence: Mateus Kenji Christo Miyahira, Instituto Cohen, Av Lineu de Paula Machado, 660, Cidade Jardim, São Paulo, SP, 05601-000, Brazil (e-mail: kenjimiyahira23@hotmail.com).

Rev Bras Ortop 2021;56(3):333–339.

### Abstract

**Objective** To evaluate clinically and radiologically the results of the treatment of chondral lesions using collagen membrane - autologous matrix-induced chondrogenesis (AMIC).

**Methods** This is a series of observational cases, in which 15 patients undergoing AMIC were analyzed. The clinical evaluation was made by comparing the Lysholm and International Knee Document Committee (IKDC) scores in the pre- and postoperative period of 12 months, and radiological evaluation using the Magnetic Resonance Observation of Cartilage Repair Tissue (MOCART) score in the same postoperative period.

**Results** The mean age of the patients was 39.2 years old, and the mean size of the chondral lesions was 1.55cm<sup>2</sup>. There was a significant improvement in clinical scores, with a mean increase of 24.6 points on Lysholm and of 24.3 on IKDC after 12 months. In the radiological evaluation, MOCART had a mean of 65 points. It was observed that the larger the size of the lesion, the greater the improvement in scores.

**Conclusion** Evaluating subjective clinical scores, the treatment of chondral lesions with the collagen membrane showed good results, as well as the evaluation of MOCART, with greater benefit in larger lesions.

### Keywords

- ▶ articular cartilage
- ▶ chondrogenesis
- ▶ collagen
- ▶ knee injuries

\* Work developed at the Department of Orthopedics and Traumatology, Universidade Federal de São Paulo (UNIFESP), São Paulo, SP, Brazil.

received  
December 11, 2019  
accepted  
March 2, 2020  
published online  
September 25, 2020

DOI <https://doi.org/10.1055/s-0040-1712493>.  
ISSN 0102-3616.

© 2020. Sociedade Brasileira de Ortopedia e Traumatologia. All rights reserved.

This is an open access article published by Thieme under the terms of the Creative Commons Attribution-NonDerivative-NonCommercial-License, permitting copying and reproduction so long as the original work is given appropriate credit. Contents may not be used for commercial purposes, or adapted, remixed, transformed or built upon. (<https://creativecommons.org/licenses/by-nc-nd/4.0/>)

Thieme Revinter Publicações Ltda., Rua do Matoso 170, Rio de Janeiro, RJ, CEP 20270-135, Brazil

**Resumo****Palavras-chave**

- cartilagem articular
- condrogênese
- colágeno
- traumatismos do joelho

**Objetivo** Avaliar clínica e radiologicamente os resultados do tratamento das lesões condrais com a membrana de colágeno – condrogênese autóloga induzida por matriz.

**Métodos** Trata-se de uma série de casos observacional, na qual foram analisados 15 pacientes submetidos a condrogênese autóloga induzida por matriz. A avaliação clínica foi feita comparando os escores de Lysholm e International Knee Document Committee (IKDC, na sigla em inglês) no pré- e pós-operatório de 12 meses, e avaliação radiológica através do escore de Magnetic Resonance Observation of Cartilage Repair Tissue (MOCART, na sigla em inglês) no mesmo período de pós-operatório.

**Resultados** A média de idade dos pacientes foi 39,2 anos, e a média do tamanho das lesões condrais foi de 1,55cm<sup>2</sup>. Houve uma melhora significativa nos escores clínicos, com média de aumento de 24,6 pontos no Lysholm e de 24,3 no IKDC, após 12 meses. Na avaliação radiológica, o MOCART teve média de 65 pontos. Observou-se que quanto maior o tamanho da lesão, maior foi a melhora nos escores.

**Conclusão** Avaliando escores clínicos subjetivos, o tratamento das lesões condrais com a membrana de colágeno mostrou bons resultados, assim como a avaliação de MOCART, com maior benefício em lesões maiores.

**Introduction**

The biomechanical function of the matrix of proteoglycans and collagen fibers of the cartilage is to absorb compressive and tension loads that act on the joint.<sup>1</sup> Cartilage injuries are seen in up to 11% of arthroscopies, half of which are > 2 cm<sup>2</sup> in size.<sup>2</sup> Most are related to trauma or osteochondritis dissecans.

The healing capacity of cartilage is limited<sup>3,4</sup> and may lead to osteoarthritis.<sup>5</sup> One of the greatest challenges for the orthopedic surgeon remains the treatment of chondral injuries.<sup>6</sup> Due to the low healing potential, and the degree of discomfort that these lesions cause, surgical intervention has been widely used in an attempt to fill cartilage defects.<sup>7,8</sup> Mesenchymal cells are the source for regeneration.<sup>9</sup>

Pridie,<sup>10</sup> in 1959, was the first to stimulate repair using blood from the bone marrow. Steadman et al.,<sup>11</sup> in 2001, introduced the microfracture technique. Microfracture is a technique for recruiting mesenchymal cells, as the clot provides a favorable medium for cartilage repair tissue.<sup>12</sup> The “fibrocartilage-like” scar tissue<sup>13</sup> prevents osteoarthritis and improves patient symptoms.<sup>14</sup>

As the formed clot does not have good mechanical resistance, the use of the collagen membrane has been proposed.<sup>15–17</sup> Autologous matrix-induced chondrogenesis (AMIC) is a technique that combines microfractures with the collagen membrane.<sup>18</sup> While microperforations are indicated for defects < 2 cm<sup>2</sup>, AMIC is indicated for larger defects.<sup>19</sup>

The objective of the present study is to evaluate clinically and radiologically the results of the treatment for chondral lesions of the knee using the collagen membrane – AMIC.

**Methodology**

The present study is an observational case series of patients with chondral injuries of the knee, operated between 2015 and 2018 using collagen membrane by the AMIC technique, and approved by the ethics committee of the institution.

All of the patients participating in the present study were informed about the surgical technique indicated and other treatment options, its advantages and disadvantages, and agreed with the performance of the chosen procedure.

The indications were patients between 15 and 55 years of age, with chondral lesions of 0.5 to 5.0 centimeters in diameter, in the patella, trochlea or femoral condyles, grades III or IV of ICRS (Internacional cartilage repair society), active and symptomatic. Patients with a history of previous surgery for cartilage, poor alignment of the affected lower limb or ligament instability that were not corrected previously or concurrently with the procedure, were not included. The exclusion criteria were patients who abandoned outpatient follow-up or did not agree to participate.

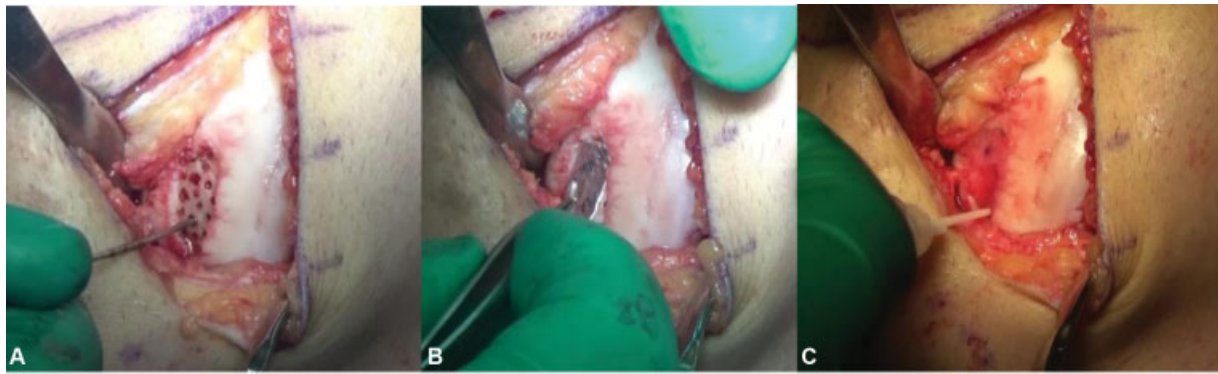
A total of 15 patients were included in the study, 12 men and 3 women, all operated by the same surgeon.

**Preoperative evaluation**

Patients who had suspected chondral lesions in the knee, according to anamnesis and physical examination, underwent complementary imaging tests for diagnostic completion, with radiographs and magnetic resonance imaging (MRI), being able to characterize and measure chondral lesion and to identify ligament injuries or poor alignment of the lower limbs. Thus, patients who met the criteria for inclusion in the study were identified.

**Surgical technique**

First, arthroscopy of the affected knee was performed, to locate the chondral lesion, and to evaluate the ligaments and menisci. Then, afterwards, a longitudinal parapatellar arthrotomy was performed according to the joint region to be operated. When there was any other concomitant surgical procedure, such as reconstruction of the anterior cruciate ligament or valgus osteotomy of the tibia, chondroplasty was always performed last.



**Fig. 1** A, debrided and microperforated chondral lesion area. B, metallic mold used to measure dimensions of the lesion. C, final aspect showing the collagen membrane fixed by fibrin glue.

After debridement of the chondral defect, removal of degenerate and unviable cartilaginous tissue, curettage of the lesion bed was performed, removing the whole calcified layer and preserving the subchondral bone (►Figure 1).

Using a metallic template, the size and shape of the lesion was precisely defined, and the porcine type I/III collagen membrane (Chondrogide; Geistlich Pharma AG, Wolhusen, Switzerland) that would cover the defect was cut out. Then, microperforations were made in the subchondral bone, freehand, with 2 to 4 mm of distance between them. The membrane was then placed over the defect and provisionally fixed with two needles. The definitive fixation of the membrane was made with absorbable monocryl 5.0 thread and complemented with fibrin glue at the edges of the lesion.

### Rehabilitation

Despite the different surgical procedures associated with the use of the collagen membrane, the rehabilitation protocol started with three weeks of immobilization with joint brace and without weight unloading on the operated limb.

In order to reduce the inflammatory condition, until the 5<sup>th</sup> week, an increase in the range of motion and activation of the quadriceps muscle was initiated. After that, until the 8<sup>th</sup> week, the patient was encouraged to walk without using an orthosis, progressively, until the gait normalized. Between 6 and 8 months, the patient was allowed to play contact sports.

### Data Collection

Demographic data such as age, gender, laterality, size and location of the chondral lesion, and associated procedures were collected from the database. The preoperative clinical evaluation was performed using the Lysholm<sup>20</sup> and the International Knee Document Committee (IKDC)<sup>21</sup> scores, and the 1-year postoperative follow-up, through Lysholm, IKDC, and the Magnetic Resonance Observation of Cartilage Repair Tissue (MOCART) radiological score.<sup>22</sup> This score is a rating system that seeks to assess the repair tissue in its extent, signal strength, defect filling, integration with the adjacent cartilage, among others.

### Statistical analysis

Initially, all variables were analyzed descriptively. For quantitative variables, this analysis was performed by observing

the minimum and maximum values, and calculating means, standard deviations (SDs) and quartiles. For qualitative variables, absolute and relative frequencies were calculated. For the comparison of means of two evaluation moments, the paired Student t test was used.<sup>23</sup> To study the correlations between the deltas of the scores and variables evaluated in the study, the Pearson correlation coefficient was used. The software used for the calculations was SPSS Statistics for Windows, Version 17.0 (SPSS Inc., Chicago, IL, USA). The level of significance used for the tests was 5%.

### Results

A total of 15 patients aged between 15 and 54 years old (mean of 39.2 years old) were evaluated, 3 women and 12 men. The lesions affected the femoral trochlea in six cases, the patella in five cases and the femoral condyles in four cases. ►Table 1 presents the frequency distribution of the lesion site.

The size of the lesions ranged from 0.6 cm<sup>2</sup> to 2.34 cm<sup>2</sup>, measured using preoperative MRIs, and the body mass index (BMI) ranged from 21.6 kg/m<sup>2</sup> to 32.5 kg/m<sup>2</sup>, as shown in ►Table 2, with the descriptive values of these variables.

The Lysholm and IKDC scores were assessed before and after surgery, at 12 months. There was a significant increase in the means of the Lysholm score (55.9 versus 80.5) and of the IKDC score (51.6 versus 75.9) from pre- to postoperative ( $p < 0.001$ ) (►Figures 2 and 3).

The Tegner and MOCART scores were evaluated in a single moment and are described in ►Table 3. Through the results obtained with MRI scans after 1 year, it was shown that all patients maintained the filling of the chondral lesion with repair tissue, with good integration of the edges. The average MOCART score was 65 points, ranging from 50 to 75.

For the study of possible correlations between variables, and the pre- and postoperative variation of the scores, the delta of variation of the scores presented in ►Table 4 was calculated.

In ►Table 5, the correlation coefficients between age, lesion size, BMI and the deltas of variation of the Lysholm and IKDC scores are presented. There is a positive and significant correlation between the size of the lesion and the delta of variation of the IKDC score. Therefore, the greater the lesion size, the greater the delta of variation of the IKDC

**Table 1** Frequency distribution of the lesion site for the 15 patients evaluated

| Lesion site | n  | %     |
|-------------|----|-------|
| MFC + LFC   | 1  | 6.7   |
| MFC R       | 3  | 20.0  |
| Patella R   | 3  | 20.0  |
| Patella L   | 2  | 13.3  |
| Trochlea R  | 4  | 26.7  |
| Trochlea L  | 2  | 13.3  |
| Total       | 15 | 100.0 |

Abbreviations: L, left; LFC, lateral femoral condyle; MFC, medial femoral condyle; R, right.

**Table 2** Descriptive values of lesion size and body mass index of the 15 patients

| Variable | n  | Mean | SD   | Minimum | Maximum |
|----------|----|------|------|---------|---------|
| Size     | 15 | 1.55 | 0.58 | 0.60    | 2.34    |
| BMI      | 15 | 27.6 | 2.6  | 21.6    | 32.5    |

Abbreviations: BMI, body mass index; SD, standard deviation.

score (►Figure 4). No relationship was found between the observed improvement, age and BMI.

## Discussion

The most important finding of the present study was that patients with larger chondral lesions had a greater increase in clinical scores, therefore a greater benefit with the

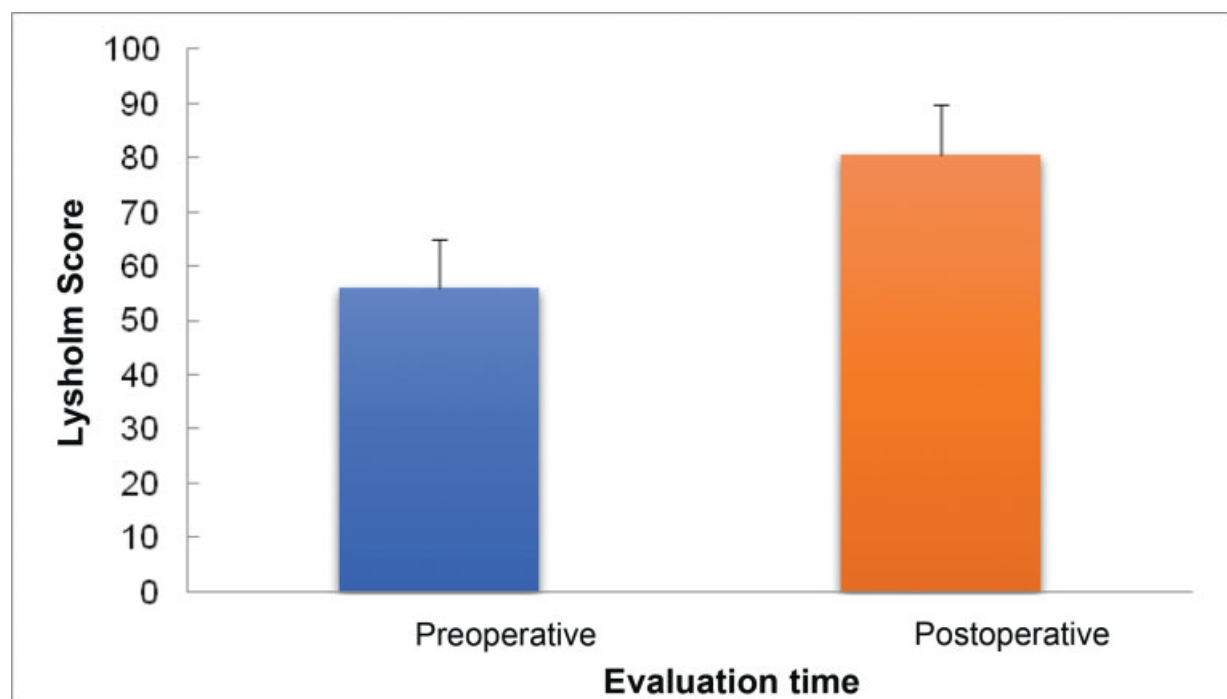
treatment. These results show agreement with the previous study published by our group.<sup>24</sup> There was no significant impact of age and BMI on the results found in the present study.

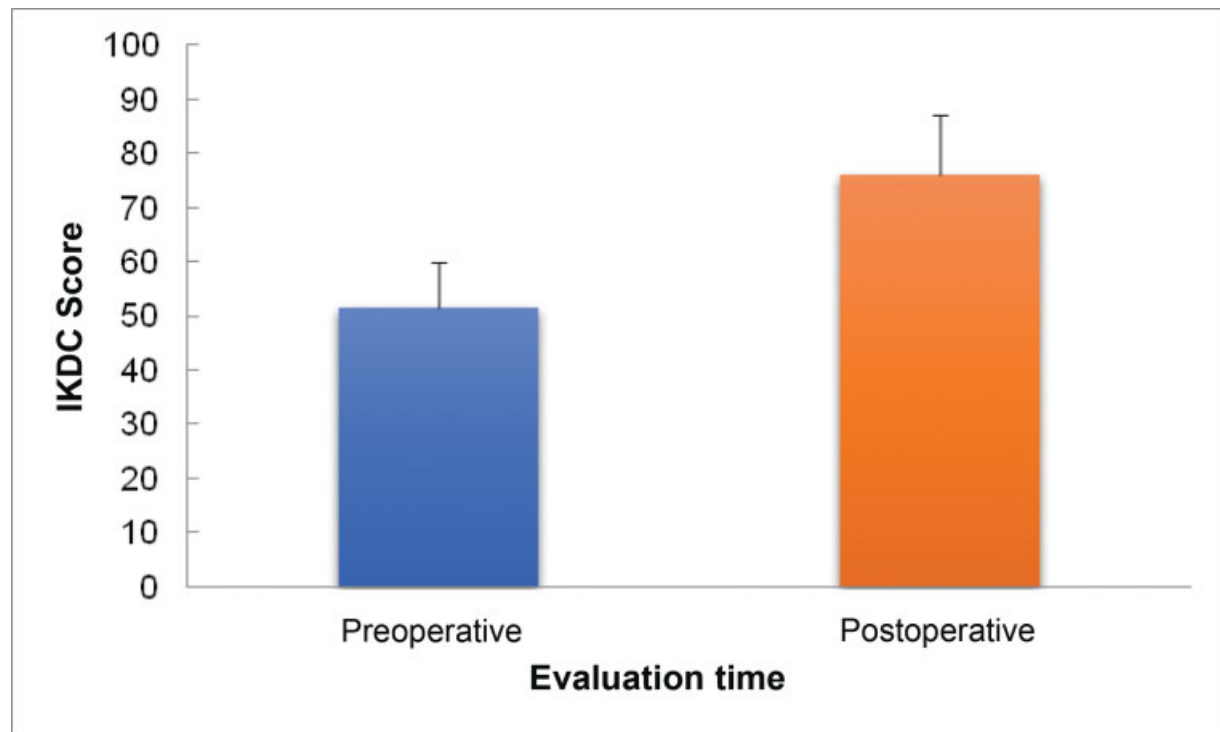
The AMIC technique has been used by several surgeons, being established as an option in the treatment of cartilage defects. Previous studies have shown the ability of microfractures in the subchondral bone to take mesenchymal cells from the bone marrow to the cartilage region, promoting the supply of growth factors and cytokines. *In vitro* tests have already shown that the collagen membrane can retain mesenchymal cells, which can improve the regenerative capacity of the microfracture technique.<sup>15</sup>

A 2008 study compared the results of treating chondral lesions with microfractures, using or not the collagen membrane in acetabular lesions. It was shown that a more sustained improvement in clinical scores was achieved with the use of the membrane.<sup>25</sup>

Compared with other surgical procedures to treat cartilage defects, the combination of microfractures with the collagen membrane is a good option, with a low-cost surgical time, without morbidity of a healthy donor area or need for cell proliferation *in vitro*, as in autologous osteochondral transplantation and autologous chondrocyte transplantation, respectively. The same technique of the present study, performed arthroscopically, has already been described by Piontek et al., presenting promising results.<sup>26</sup> Schagemann et al.,<sup>27</sup> in 2018, compared the AMIC arthroscopic technique with the *mini open* technique, similar to our work, concluding that there is no difference in the results in the medium term, with 2 years of follow-up.

Dhollander et al.<sup>28</sup> have already reported satisfactory improvements 2 years after the operation, but with a tendency to deterioration of the repair tissue, analyzed

**Fig. 2** Mean and standard deviation of the Lysholm score in the pre- and postoperative period.



**Fig. 3** Mean and standard deviation of the International Knee Documentation Committee (IKDC) score in the pre- and postoperative period.

**Table 3** Descriptive values of the Tegner and Mocart scores of the 15 patients

| Variable | n  | Mean | SD  | Minimum | Maximum |
|----------|----|------|-----|---------|---------|
| Tegner   | 15 | 3.9  | 1.1 | 2.0     | 6.0     |
| MOCART   | 15 | 65.0 | 7.8 | 50.0    | 75.0    |

Abbreviations: MOCART, Magnetic Resonance Observation of Cartilage Repair Tissue; SD, standard deviation.

**Table 4** Descriptive values of the delta scores of variations of the Lysholm and International Knee Documentation Committee scores of the 15 patients

| Variable | n  | Mean | SD  | Minimum | Maximum |
|----------|----|------|-----|---------|---------|
| Lysholm  | 15 | 24.6 | 9.0 | 11.0    | 41.0    |
| IKDC     | 15 | 24.3 | 7.1 | 12.6    | 33.4    |

Abbreviations: IKDC, International Knee Documentation Committee; SD, standard deviation.

by MRI. In our series of cases, the improvements were good or excellent. Through imaging exams, no repair tissue thinning or overgrowth was observed. Other studies have already shown that there is no clinical improvement at the same pace as the repair tissue evolution observed by MRI scans.<sup>22</sup> We believe that the radiological evaluation can be indicative of treatment failure, but not an indication of success.

**Table 5** Pearson correlation coefficients

|      |         | Lysholm Delta | IKDC Delta |
|------|---------|---------------|------------|
| Age  | r       | 0.266         | -0.188     |
|      | p-value | 0.338         | 0.502      |
|      | n       | 15            | 15         |
| Size | r       | -0.143        | 0.593      |
|      | p-value | 0.610         | 0.020      |
|      | n       | 15            | 15         |
| BMI  | r       | 0.450         | -0.017     |
|      | p-value | 0.092         | 0.953      |
|      | n       | 15            | 15         |

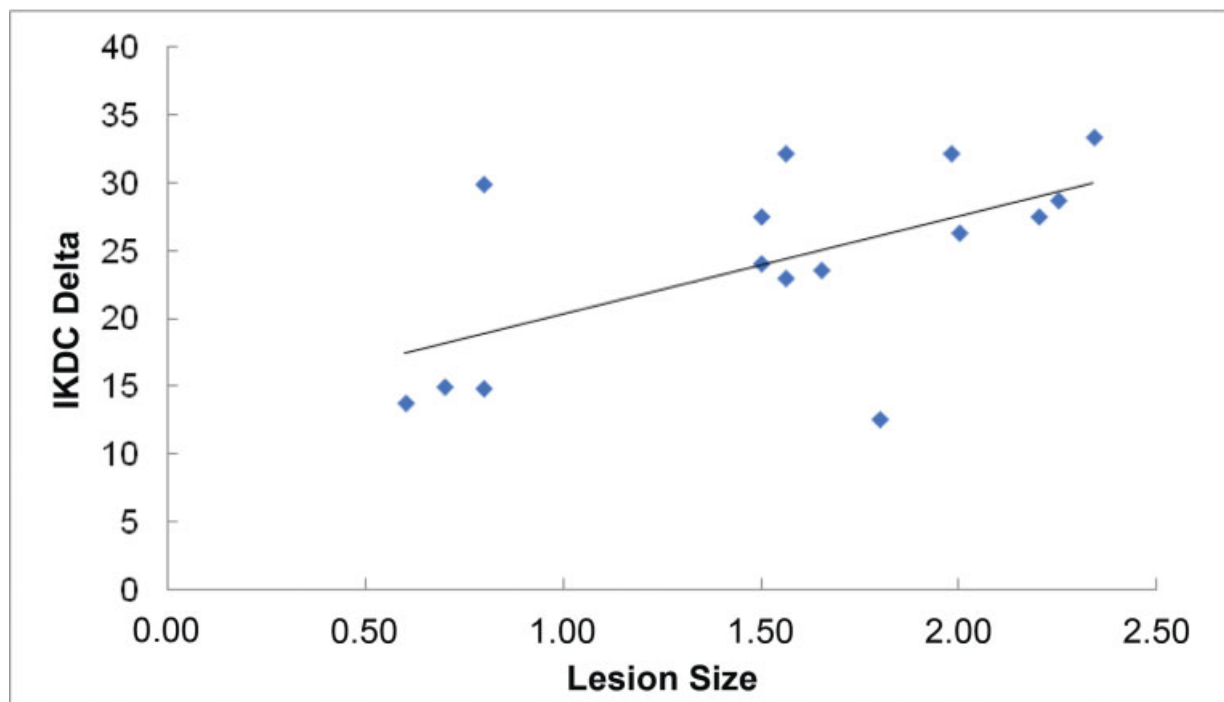
Abbreviation: BMI, body mass index; IKDC, International Knee Documentation Committee.

There are limitations that must be considered when evaluating the present work. The small number of patients reflects a reality for the surgeons of the country, due to the access to the necessary material for the procedure. Because of this, the lesions are described in different parts of the joint, with various concurrent procedures, making the sample more heterogeneous.

## Conclusion

Evaluating subjective clinical scores, the treatment of chondral lesions with the collagen membrane showed good





**Fig. 4** Scatter plot of lesion size and delta variation of the International Knee Documentation Committee (IKDC) score.

results, as well as the MOCART evaluation, and that there is a greater benefit in larger lesions.

#### Financial Support

There was no financial support from public, commercial, or non-profit sources.

#### Conflict of Interests

The authors have no conflict of interests to declare.

#### References

- Gottardi R, Hansen U, Raiteri R, et al. Supramolecular Organization of Collagen Fibrils in Healthy and Osteoarthritic Human Knee and Hip Joint Cartilage. *PLoS One* 2016;11(10):e0163552
- Arøen A, Løken S, Heir S, et al. Articular cartilage lesions in 993 consecutive knee arthroscopies. *Am J Sports Med* 2004;32(01):211–215
- Buckwalter JA, Mankin HJ. Articular cartilage: degeneration and osteoarthritis, repair, regeneration, and transplantation. *Instr Course Lect* 1998;47:487–504
- Raimondi MT, Bonacina E, Candiani G, et al. Comparative chondrogenesis of human cells in a 3D integrated experimental-computational mechanobiology model. *Biomech Model Mechanobiol* 2011;10(02):259–268
- Heir S, Nerhus TK, Røtterud JH, et al. Focal cartilage defects in the knee impair quality of life as much as severe osteoarthritis: a comparison of knee injury and osteoarthritis outcome score in 4 patient categories scheduled for knee surgery. *Am J Sports Med* 2010;38(02):231–237
- Farr J, Gomoll AH. 2016 barriers to cartilage restoration. *J Clin Orthop Trauma* 2016;7(03):183–186
- Kubosch EJ, Erdle B, Izadpanah K, et al. Clinical outcome and T2 assessment following autologous matrix-induced chondrogenesis in osteochondral lesions of the talus. *Int Orthop* 2016;40(01):65–71
- Steinwachs M. New technique for cell-seeded collagen-matrix-supported autologous chondrocyte transplantation. *Arthroscopy* 2009;25(02):208–211
- Kon E, Filardo G, Di Matteo B, Perdida F, Marcacci M. Matrix assisted autologous chondrocyte transplantation for cartilage treatment: A systematic review. *Bone Joint Res* 2013;2(02):18–25
- Pridie K. A method of resurfacing osteoarthritic knee joints. *J Bone Joint Surg Br* 1959;41:618–619
- Steadman JR, Rodkey WG, Rodrigo JJ. Microfracture: surgical technique and rehabilitation to treat chondral defects. *Clin Orthop Relat Res* 2001;(391, Suppl):S362–S369
- Richter W. Mesenchymal stem cells and cartilage in situ regeneration. *J Intern Med* 2009;266(04):390–405
- Hunziker EB. Articular cartilage repair: basic science and clinical progress. A review of the current status and prospects. *Osteoarthritis Cartilage* 2002;10(06):432–463
- Kusano T, Jakob RP, Gautier E, Magnussen RA, Hoogewoud H, Jacobi M. Treatment of isolated chondral and osteochondral defects in the knee by autologous matrix-induced chondrogenesis (AMIC). *Knee Surg Sports Traumatol Arthrosc* 2012;20(10):2109–2115
- Bark S, Piontek T, Behrens P, Mkalaluh S, Varoga D, Gille J. Enhanced microfracture techniques in cartilage knee surgery: Fact or fiction? *World J Orthop* 2014;5(04):444–449
- Gille J, Behrens P, Volpi P, et al. Outcome of Autologous Matrix Induced Chondrogenesis (AMIC) in cartilage knee surgery: data of the AMIC Registry. *Arch Orthop Trauma Surg* 2013;133(01):87–93
- Benthien JP, Behrens P. Autologous matrix-induced chondrogenesis (AMIC). A one-step procedure for retropatellar articular resurfacing. *Acta Orthop Belg* 2010;76(02):260–263
- Behrens P. Matrixgekoppelte Mikrofrakturierung. *Arthroskopie* 2005;18:193–197
- Anders S, Martin Volz, Frick H, Gellissen J. A randomized, controlled trial comparing autologous matrix induced chondrogenesis (AMIC) to microfracture: analysis of 1- and 2-year follow-up data of 2 centers. *Open Orthop J* 2013;7(Suppl 1):M4:133–143
- Peccin MS, Cicconelli R, Cohen M. Questionário específico para sintomas do joelho Lysholm Knee Scoring Scale –Tradução e

- validação para a língua Portuguesa. *Acta Ortop Bras* 2006;14(05): 268–272
- 21 Hefti F, Müller W, Jakob RP, Stäubli HU. Evaluation of knee ligament injuries with the IKDC form. *Knee Surg Sports Traumatol Arthrosc* 1993;1(3-4):226–234
  - 22 Marlovits S, Striessnig G, Resinger CT, et al. Definition of pertinent parameters for the evaluation of articular cartilage repair tissue with high-resolution magnetic resonance imaging. *Eur J Radiol* 2004;52(03):310–319
  - 23 Rosner B. *Fundamentals of Biostatistics*. 2<sup>nd</sup>. Boston: PWS Publishers; 1986
  - 24 Astur DC, Lopes JC, Santos MA, Kaleka CC, Amaro JT, Cohen M. Surgical treatment of chondral knee defects using a collagen membrane - autologous matrix-induced chondrogenesis. *Rev Bras Ortop* 2018;53(06):733–739
  - 25 Fontana A, de Girolamo L. Sustained five-year benefit of autologous matrix-induced chondrogenesis for femoral acetabular impingement-induced chondral lesions compared with microfracture treatment. *Bone Joint J* 2015;97-B(05):628–635
  - 26 Piontek T, Ciemniowska-Gorzela K, Szulc A, Naczek J, Słomczykowski M. All-arthroscopic AMIC procedure for repair of cartilage defects of the knee. *Knee Surg Sports Traumatol Arthrosc* 2012;20(05):922–925
  - 27 Schagemann J, Behrens P, Paech A, et al. Mid-term outcome of arthroscopic AMIC for the treatment of articular cartilage defects in the knee joint is equivalent to mini-open procedures. *Arch Orthop Trauma Surg* 2018;138(06):819–825
  - 28 Dhollander A, Moens K, Van der Maas J, Verdonk P, Almqvist KF, Victor J. Treatment of patellofemoral cartilage defects in the knee by autologous matrix-induced chondrogenesis (AMIC). *Acta Orthop Belg* 2014;80(02):251–259