



Unsuspected Paraganglioma—Infratemporal Fossa

Nikhat Sultana J¹ Shekhar R. Gurralla¹ Lakshman K. Kommula¹ Gnana R. Boola²

¹Department of Neuroanaesthesia and Critical Care, Apollo Hospital, Hyderabad, Telangana, India
²Department of Neurosurgery, Apollo Health City, Hyderabad, Telangana, India

Address for correspondence Nikhat Sultana J, MBBS, MD, Department of Neuroanaesthesia and Critical Care, Apollo Hospital, Hyderabad, Telangana 500033, India (e-mail: nikisultana860@outlook.com).

J Neuroanaesthesiol Crit Care:2021;8:142–143.

Abstract

Paraganglioma of the infratemporal fossa is exceedingly rare, with no more than a handful of documented cases. Undiagnosed paraganglioma poses a great challenge. We present a 39-year-old hypertensive female, who presented with giddiness and headache for 3 months and four episodes of syncope over 3 months. CT and MRI revealed an enhancing infratemporal region space-occupying mass close proximity to petrous carotid artery. Intraoperatively, the patient had hemodynamic instability (tachycardia and hypertension) when the mass was surgically manipulated. Diagnosis of paraganglioma was suspected, based on hemodynamic instability, which was later confirmed by histopathology. Undiagnosed paraganglioma pose a great challenge to the anesthetic management. Low-threshold of suspicion has to be there to avoid significant morbidity and mortality.

Keywords

- ▶ paraganglionoma
- ▶ infratemporal fossa
- ▶ undiagnosed catecholamine secreting tumor

Introduction

Paraganglioma has no characteristic CT and MRI radiological findings. Surgical excision whenever possible is the definitive treatment for cure. Undiagnosed paraganglioma when handled during surgical excision poses a huge challenge as a result of sudden release of vasoactive catecholamines.

Case Description

A 39-year-old female, known hypertensive on tablet amlodipine (5 mg once a day), presented with giddiness and headache on the left side for 3 months and four episodes of syncope in the last 3 months. Her neurological examination revealed no abnormal findings, blood pressure was 130/74 mm Hg, and presurgical blood work up was normal. CT and MRI of brain revealed a space-occupying lesion (▶ **Fig. 1**) in the left petrous bone, extending into the subtemporal and infratemporal regions. After proper surgical evaluation, decision for surgical excision of lesion was made. Preoperative differential diagnosis of trigeminal nerve schwannoma, soft tissue sarcoma in close proximity to petrous carotid artery was considered.

On the day of surgery, anesthesia was induced using propofol 100 mg, fentanyl 100 micro gram, and neuromuscular

relaxation was facilitated with inj cisatracurium 10 mg. Vascular access lines (arterial line and central line) were secured. The patient was positioned in a semiright lateral position. The patient was hemodynamically stable. Fluctuation of blood pressure and heart rate was noted after start of procedure but was managed. Subtemporal transzygomatic approach of craniotomy was used to expose the tumor. When the surgeon was handling the tumor, there was sudden hypertension and tachycardia (~200–240 mm Hg/180–200 mm Hg of blood pressure and heart rate of 140–170 bpm). With initial suspicion of inadequate depth of anesthesia, bolus dose of muscle relaxant, opioid, and propofol was administered, and she was started on dexmedetomidine in a cascade-like manner. There was persistent hypertension and tachycardia accompanied by increased blood loss from the surgical site. In order to get a control over hemodynamic instability, the surgeon was asked to stop momentarily. There was a period of hypotension that set in rapidly (up to 60/40 mm Hg).

With ongoing blood loss, hypovolemia was considered, and adequate volume was replaced with crystalloid, followed by blood products. Once hemodynamics was stable, excision was attempted, avoiding carotid artery handling. Hypertension and bleeding recurred. Incremental bolus doses of labetalol (150 mg throughout the surgery) and

Published online
June 14, 2020

DOI <https://doi.org/10.1055/s-0040-1712853>
ISSN 2348-0548.

© 2020. Indian Society of Neuroanaesthesiology and Critical Care. This is an open access article published by Thieme under the terms of the Creative Commons Attribution-NonDerivative-NonCommercial-License, permitting copying and reproduction so long as the original work is given appropriate credit. Contents may not be used for commercial purposes, or adapted, remixed, transformed or built upon. (<https://creativecommons.org/licenses/by-nc-nd/4.0/>). Thieme Medical and Scientific Publishers Pvt. Ltd. A-12, 2nd Floor, Sector 2, Noida-201301 UP, India

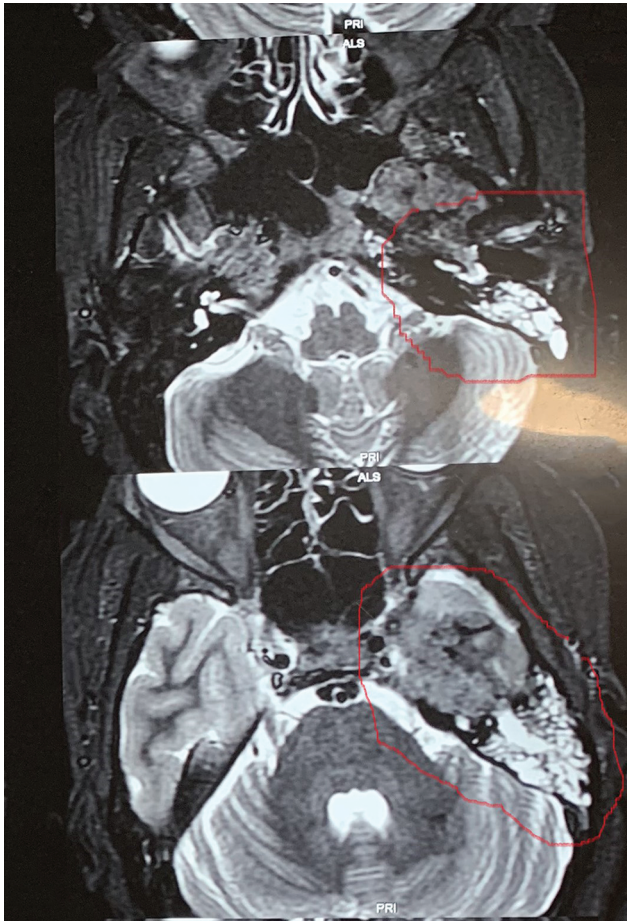


Fig. 1Y MRI showing left infratemporal space occupying lesion.

metoprolol (10 mg) were required. This clinical response to tumor handling led to suspicion of catecholamine-secreting tumor and she was started on sodium nitroprusside infusion. Tumor tissue that was sent for (frozen section) histopathological examination was a benign tumor. Paraganglioma was expected in the final report. Radical surgery was deferred under these circumstances. Low-dose of norepinephrine was used to maintain mean arterial pressure of 70 mm Hg.

Total replacement of fluids was 1250 mL of blood, crystalloids, and two packs of packed blood cell. Postprocedure, the patient was extubated immediately and had no new neurological deficits. Intensive care monitoring for 24 hours was done.

Rest of the Course in Hospital was Uneventful

Histopathological examination revealed “zellballen pattern,” confirming the diagnosis of paraganglionoma. Immune studies showed positive results for chromogranin, EMA was negative, and sustentacular cells were positive for S100. These pointed to catecholamine-secreting tumor.

DOTA-TATE positron emission tomography (PET) was done electively to rule out syndromic lesions. A subcentimeter

lesion was found at the region of celiac plexus along with the residual tumor.

Discussion

Paraganglioma is a rare and highly vascular tumor of neural crest origin which comprise only 0.6% of all head and neck tumors.¹ Its tumor derived from the sympathetic and parasympathetic nervous systems; therefore, it appears anywhere from the cranial base to the epididymis.² Histopathology, it typically shows polygonal chief cells are centrally distributed in the cell clusters, and arranged into compact cell nests or balls of cells (termed zellballen). Sustentacular cells are peripherally situated. This aspect typically confers a whorled configuration.³

Functional paraganglioma can prove to be a challenge to anesthesiologists because of its ability to secrete catecholamines. Usually, catecholamine release from the paraganglioma is triggered by a direct pressure on the tumor, for example, during surgical manipulation. A catecholamine storm can cause serious complications such as severe hypertension, myocardial infarction, coronary spasm, arrhythmias, cardiomyopathy, stroke, and pulmonary edema.² Total surgical excision alone or in conjunction with preoperative embolization are the preferred treatment modalities.⁴

Conclusion

Functional paraganglioma can prove to be a challenge to anesthesiologists because of its ability to release catecholamine during surgery. This situation can be very catastrophic, especially when an undiagnosed paraganglioma is attempted. It poses a great challenge in perioperative management to all disciplines involved. Hence, a low-threshold of suspicion should be observed in case of sudden and severe hemodynamic instability during head and neck tumor surgery.

Conflict of Interest

None declared.

Reference

- 1 Tritter AG, Selber J, Kupferman ME. Surgical management of a functional paraganglioma of the infratemporal fossa. *J Neurosurg Rep* 2015;76(1):e1–e7
- 2 Renard J, Clerici T, Licker M, Triponez F. Pheochromocytoma and abdominal paraganglioma. *J Visc Surg* 2011;148(6):e409–e416
- 3 Naggara O, Varlet P, Page P, Oppenheim C, Meder JF. Suprasellar paraganglioma: a case report and review of the literature. *Neuroradiology* 2005;47(10):753–757
- 4 Düzlü M, Tutar H, Karamert R, et al. Temporal bone paragangliomas: 15 years experience. *Rev Bras Otorrinolaringol (Engl Ed)* 2018;84(1):58–65