

Full-Thickness Skin Grafts and Quilting Sutures for the Reconstruction of Internal Nasal Lining

PD Dr. med. Antoniu-Oreste Gostian¹ Dr. med. Matthias Balk¹ Dr. med. Achim Stegmann¹
 Prof. Dr. med. Dr. h.c. Heinrich Iro¹ Prof. Dr. med. Jochen Wurm¹

¹Department of Otolaryngology - Head and Neck Surgery, University Erlangen - Nuremberg, Erlangen, Germany

Address for correspondence Dr. med. Matthias Balk, Department of ENT, Erlangen University Hospital, Waldstraße 1, Erlangen 91054, Bayern, Germany (e-mail: matthias.balk@uk-erlangen.de).

Facial Plast Surg 2020;36:297–304.

Abstract

Restoration of the inner nasal lining is an essential factor in successful nasal reconstruction. Among various methods, free full-thickness skin grafting represents a readily available and feasible technique. A prerequisite for success is a secure and immobile fixation to the undersurface of the nourishing forehead flap. This retrospective study aims to evaluate the results of multiple quilting sutures to secure free full-thickness skin grafts for the reconstruction of the inner nasal lining in partial and extended nasal reconstruction. Between February 1, 2015, and December 31 2018, 16 patients underwent three-stage nasal reconstruction of all three layers using a forehead flap. All full-thickness free flaps were harvested from either the neck or inguinal area and fixated to the undersurface of the distal part of the forehead flap by multiple quilting sutures. All but one free skin grafts healed well (seven ♀; mean: 63 years; range: 52–81). Four patients developed minor complications that resolved completely through conservative treatment. One patient with a history of stroke, extensive nicotine abuse, and arterial hypertension developed flap necrosis that required two surgical revisions and ended up with a stenosis of the left nostril. The follow-up time averaged 18.4 months (range: 3–55 months). Multiple quilting sutures are an effective and feasible option to fixate full-thickness free skin grafts on the undersurface of the forehead flap for the reconstruction of the inner nasal lining. They are not associated with increased risks for necrosis and can be applied even to extended full-thickness nasal defects in selected cases.

Keywords

- ▶ reconstructive surgery
- ▶ internal nasal lining
- ▶ skin graft
- ▶ nasal reconstruction

The reconstruction of full-thickness nasal defects represents a special surgical challenge.¹ The reconstruction of the internal lining adds to the complexity of the surgical procedure due to limited local tissue suitable for reconstruction. However, it is of utmost importance for the prevention of a secondary intranasal healing resulting in scar contraction, which may manifest as external aesthetic distortion, alar retraction, or vestibular stenosis, which significantly impair both shape and function.^{2,3}

Accordingly, many different surgical techniques have been described for the reconstruction of the intranasal lining, such as pedicled cutaneous flaps, hinge over flaps, perinasal second

flaps, fascial flaps, second forehead flap for lining, composite grafts, intranasal lining flaps, and free tissue transfer.^{2,4–6}

According to these authors, free skin grafts represent a simple and readily available alternative option. They are best suitable for full-thickness defects of the alar and sidewalls of the nose. However, failures of free skin grafts are reported to reach up to 25%.⁷

One of the most essential conditions for an optimal result while using free skin grafts is the secure but not too tight immobilization of the freely transplanted skin in addition to a broad contact to the nourishing forehead flap. For this, various kinds of nasal packages have been proposed that

need to be left in place for up to 7 days.² However, multiple days of nasal package cause considerable discomfort to the treated patients, and the exact positioning of the grafts to the forehead flap cannot be controlled visually.

The technique to reconstruct the internal lining by fixating a full-thickness free skin graft to the undersurface of the forehead flap with quilting sutures has proven to be a feasible option in restoring the inner lining of the reconstructed nose.^{4,8,9} However, reports on using quilting mattress sutures are scarce and usually advocate the use of merely one or very few sutures, if any, in order to not jeopardize the last vascular meadow of the nourishing pedicled forehead flap.^{8,10,11}

In our department, we have been using multiple quilting sutures to ensure optimal immobile positioning alongside with a broad contact between the transplanted free skin graft and the undersurface of the forehead flap. Based on our positive experiences, this technique has become our standard procedure for securing free skin transplants to the undersurface of the forehead flap for the reconstruction of the inner lining of the nose.

In this study, we evaluate the results of this technique applied in three-stage and three-layer nasal reconstruction of variable sizes.

Materials, Patients, and Methods

This retrospective study was based on chart reviews, pre- and postoperative examination, and pre- and postoperative photo documentation of patients who had undergone three-stage nasal reconstruction of full-thickness defects between January 1, 2015, and December 31, 2018, at a single tertiary referral center. The study was conducted according to the Declaration of Helsinki and approved by the Ethics Committee of Erlangen University. Inclusion criteria were as follows: age \geq 18 years, full-thickness defects of the nose due to oncological resection, or traumatic injuries involving single or multiple nasal subunits of the nasal ala, sidewall, and tip of the nose (**Table 1**). Resection of the septum was limited to the cranial part of the septum, as required, based on oncological requirements. All surgical steps of the three-stage reconstruction technique were performed at our department.

The following exclusion criteria applied: single-stage reconstruction, total or subtotal defects not involving all three layers, nose reconstruction using other regional or distant flaps different from the forehead flap, and total or subtotal resection of the septum.

Review of the medical charts and the surgical reports revealed the patients' demographic data, the individual cause including histology and tumor stage in cases of malignant disease, the sizes of the nasal defects, and the time spans between the stages of the nasal reconstruction, as well as the total follow-up time (**Table 1**).

Surgical Procedure

Reconstruction of full-thickness nasal defects was performed according to the three-stage procedure described in detail by Menick.^{8,10} In general, in oncological cases with the need of adjuvant radiation, nose reconstruction was initiated at least

1 year after the end of the adjuvant treatment and exclusion of tumor recurrence.

At the beginning of the first stage of reconstruction, a full-thickness free skin graft was gained from the neck or inguinal area and tailored to the individual size of the defect inside the nose (**Fig. 1a, b**). The full-thickness free skin graft was then sutured to the surrounding inner lining creating everted wound edges (**Fig. 1c**). In cases involving the resection of the cranial septum, the septal mucosa was partially elevated on either one or both sides of the remaining septum. Subsequently, either one or two tailored full-thickness skin grafts were sutured to the available nasal mucosa depending on the individual defect.

With respect to the covering nasal skin, each defect affecting more than 50% of the respective nasal subunit was enlarged to reconstruct the subunit as a whole (**Fig. 2**). An individually designed full-thickness paramedian forehead flap (including the frontalis muscle and its fascia) was raised and transposed for the reconstruction of the outer nasal layer (**Figs. 1d, 3a**). Even in cases with larger skin defects, no expanded forehead flaps were used for reconstruction to avoid shrinking of the forehead flap alongside with the full-thickness skin grafts impeding the insertion of cartilage in the subsequent reconstruction stage.

Subsequently, each free skin grafts was fixated to the undersurface of the forehead flap with multiple closely situated absorbable quilting sutures (Vicryl 4-0, Ethicon) (**Figs. 1d, 3b**) distributed over its entire surface. They were passed from extranasal through the forehead flap, intranasal through the free skin graft, and returned to the surface of the forehead flap (**Fig. 3a, c**). Attention was paid to keep the distance of approximately 3 to 4 mm between the quilting sutures.

Great care needs to be taken not to tighten the sutures too firmly but still tight enough to ensure a distinct fixation of the graft to the forehead flap. Accordingly, the quilting sutures allowed fixation and immobilization of the free skin transplants in the inner nose, thus enabling an optimal contact with the overlying nourishing vascularized forehead flap (**Fig. 3c**). Of note, the transplanted free skin grafts do not provide any stability to the nasal framework that is being addressed in the second step of the reconstruction. The first stage of reconstruction ends with meticulous suturing of the forehead flap to the surrounding wound edges of the external skin (Prolene 6-0, Ethicon) (**Fig. 3b**). Both-sided nasal packing (Meroceel, Medtronic) was placed in every case at the end of the operation and was always removed the next day. All patients received a single shot of 2 g of ceftriaxone intravenously during surgery. In case of known allergies to cephalosporins, patients received clindamycin 600 mg intravenously. The second stage of nasal reconstruction was performed after a mean period of 5.4 weeks (range: 4-9 weeks). This consists of complete elevation and thinning of the forehead flap as appropriate and reconstruction of the cartilaginous framework of the nose. Depending on the size of the defect and the available septal cartilage, either septal, ear, or rib cartilage was used. This second stage of nasal reconstruction is of utmost importance since only a strong cartilaginous framework can prevent from shrink-wrap of

Table 1 Characteristics of all patients

Patient no.	Sex	Age (years)	Histopathology	Lining defect	Covered skin defect	Time to second reconstruction stage (weeks)	Follow-up (months)
1	Female	74	Basal cell carcinoma	Complete ala on one side, subtotal ala on the other side, complete cartilaginous sidewall on one side	Complete tip and complete nasal ala on one side, subtotal ala on the other side, complete dorsum and sidewall on the right side, cartilaginous dorsum on the left side	5	26
2	Male	53	Squamous cell carcinoma	Complete ala and cartilaginous sidewall, upper third of the cranial septum	Cartilaginous sidewall, complete ala	5	33
3	Female	62	Basal cell carcinoma	Subtotal ala, partial cartilaginous sidewall	Subtotal ala, total right sidewall	5	15
4	Male	53	Squamous cell carcinoma	Subtotal ala, partial cartilaginous sidewall	Complete tip, subtotal ala on both sides, partial cartilaginous sidewalls both sides, cartilaginous dorsum	5	33
5	Female	52	Basal cell carcinoma	Subtotal ala	Complete tip and left ala, left cartilaginous sidewall, cartilaginous dorsum	7	4
6	Female	81	Basal cell carcinoma	Complete ala, partial cartilaginous sidewall	Complete ala, partial cartilaginous sidewall	5	10
7	Male	77	Basal cell carcinoma	Half of both the ala and 4 mm of the central cartilaginous sidewall, upper half of the cartilaginous septum	Complete tip and cartilaginous dorsum, subtotal ala on both sides	7	8
8	Male	61	Squamous cell carcinoma	Upper third of The cartilaginous septum, complete ala and cartilaginous sidewall	Cartilaginous sidewall, complete ala	5	9
9	Male	59	Trauma	Lateral third of the ala and the alar base	Lateral third of the ala and the alar base	5	3
10	Female	67	Basal cell carcinoma	Subtotal ala, part. cartilaginous sidewall, soft triangle on the other side	Complete tip, subtotal ala on both sides	5	3
11	Female	52	Basal cell carcinoma	Subtotal ala on one side, soft triangle on the other side	Complete tip and subtotal ala on both sides	5	3
12	Female	81	Basal cell carcinoma	Subtotal ala, subtotal sidewall, partial cranial septum	Partial tip, subtotal ala, dorsum and sidewalls	5	4
13	Male	57	Squamous cell carcinoma	Upper third of. cartilaginous septum, subtotal ala, and complete cartilaginous sidewall	Complete tip, left subtotal ala, complete sidewalls and nasal dorsum	4	26
14	Male	65	Squamous cell carcinoma	Complete sidewall, complete ala	Complete sidewall, complete ala	5	32
15	Male	57	Squamous cell carcinoma	Complete ala and cartilaginous sidewall	Complete ala, cartilaginous sidewall	9	30
16	Male	55	Basal cell carcinoma	Subtotal ala	Subtotal ala	4	12

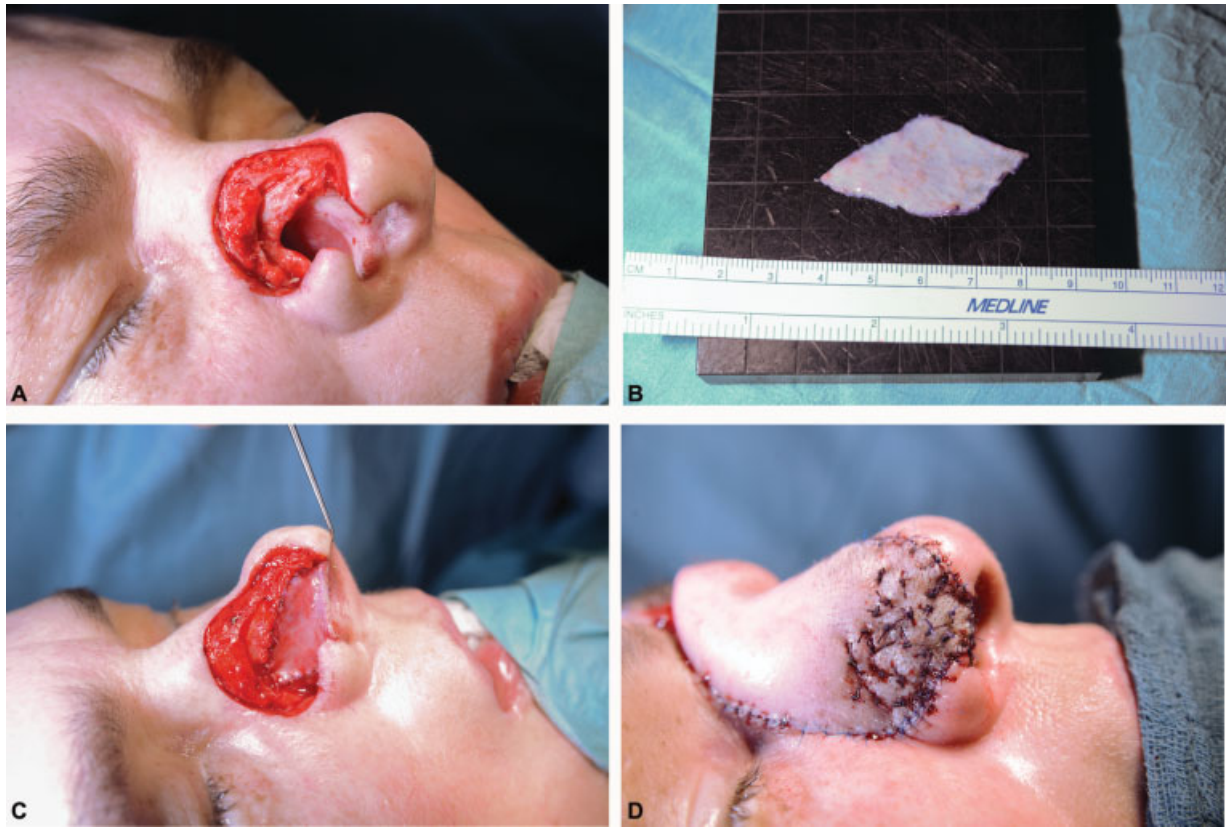


Fig. 1 Operative findings of patient 3. (a) Defect of the right nasal ala involving all three layers. (b) Harvested free skin graft from the neck. (c) Reconstruction of the inner lining with the free skin graft sutured in place. (d) A forehead flap from the left side has been used to restore the outer layers of the right nose. The multiple quilting sutures at the caudal part of the forehead can be seen and immobilize the underlying free skin graft. Of note, that patient had a low hairline but refused to undergo skin expansion prior to reconstruction.

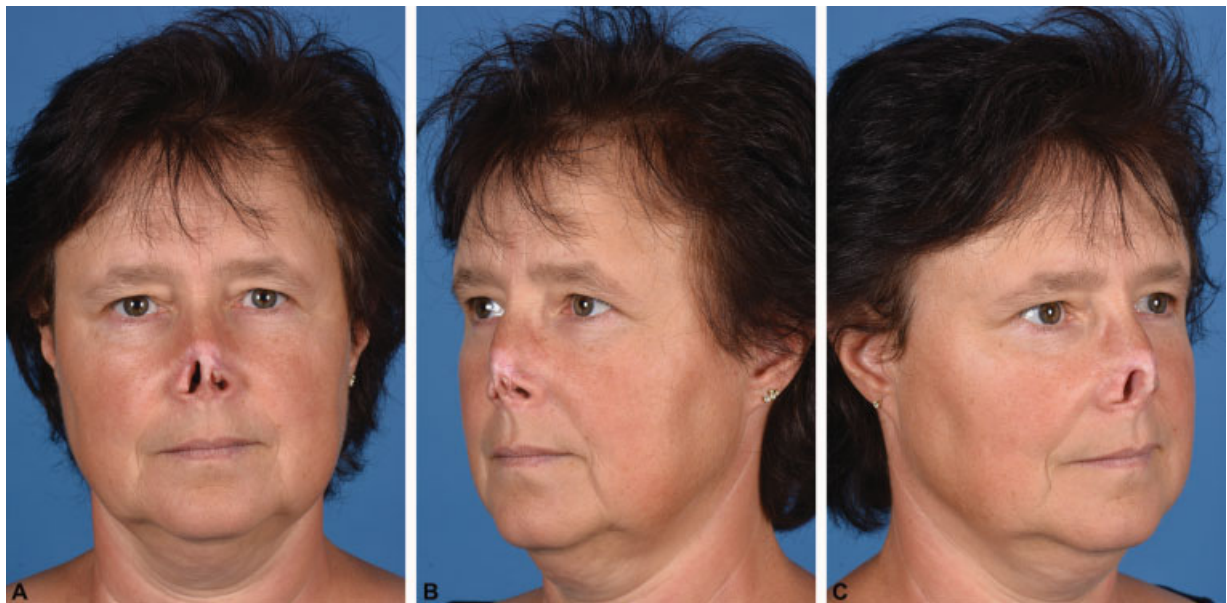

Fig. 2 (a-c) Preoperative full-thickness defect of the nose following resection of basal cell carcinoma of patient 11.

the skin envelope, resulting in alar retraction and additional distortion.

In the third reconstruction stage, the pedicled forehead flap was cut alongside with minor surgical refinements, if needed (► **Fig. 4**).

In the following, postoperative major complications are defined as those requiring additional surgical intervention. In contrast, minor complications are defined as any deviation from the normal and uneventful postoperative course that required no/or only conservative treatment.

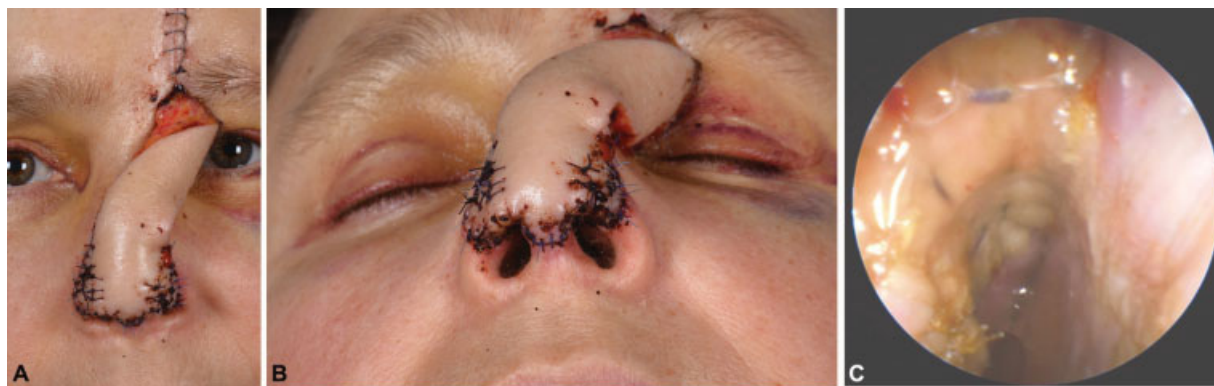

Fig. 3 Result after the first stage of reconstruction of patient presented in ►Fig. 2 (patient 11). (a) The defect has been reconstructed with a forehead flap from the left side. The multiple quilting sutures on both sides of the nasal tip can be seen. (b) The tied knots of the quilting sutures seen on the surface of the forehead flap right next to its caudal border. Also, the free skin grafts reconstruct the inner lining of both vestibules of the nose. (c) The quilting sutures that have been passed through the graft and the forehead flap visualized endoscopically in the right nasal cavity immobilizing them to the undersurface of the forehead flap.

Results

Between February 1, 2015, and October 31, 2018, a total of 46 patients underwent total or partial nasal reconstruction in our department. Out of these, 16 patients (seven ♀; mean: 63 years; range: 52–81 years.) required reconstruction of the inner nasal lining with the use of transplanted free full-thickness skin grafts harvested from the neck or inguinal area and secured in place with multiple quilting sutures as described earlier.

The reconstruction was necessary after resection of basal cell carcinomas in nine cases, six patients suffered from squamous cell carcinoma, and one patient needed nasal reconstruction after a bike accident. ►Table 1 displays the patient characteristics and extents of the underlying defects, which are presented in greater detail here.

Four patients presented with a subtotal defect of the ala alone, and another four patients showed a subtotal alar defect combined with a subtotal defect of the cartilaginous sidewall. One patient suffered from a subtotal alar defect and a total loss of the cartilaginous sidewall. In this context, a “subtotal alar” defect is defined as cases where remnants of the alar lobule were used for lining reconstruction in combination with the full-thickness skin graft. We refer to a “subtotal defect of the cartilaginous sidewall” if less than 5 mm of the original lining was left to be sutured to the full-thickness skin graft.

A total of six patients showed a complete defect of the nasal ala. Out of these, one patient presented with an additional subtotal defect of the cartilaginous sidewall, three patients with complete defects of the cartilaginous sidewalls, and two patients with complete defects of the entire nasal sidewall also involving the bony structures.

One patient presented with a central lining defect involving one-third of both ala and approximately 4 mm of the paramedian cartilaginous sidewalls on both sides.

Septal resection was necessary in 5 out of the included 16 patients and was limited to approximately one-third of the dorsal septum. In three patients, partial septal resection was accompanied by subtotal or total defects involving the ala.

The size of the paramedian forehead flap used to reconstruct the skin defect hardly correlates with the existing lining defect. This can be explained by the fact that the skin defect after resection was much bigger than the lining defect from the beginning or that the skin defect was enlarged to reconstruct the subunits of the nose as a whole for better aesthetic outcomes. Therefore, the reconstruction of the skin defect involved the complete nasal tip in combination with the nasal ala and/or the nasal sidewall in seven patients. In eight patients, the paramedian forehead flap was used to reconstruct the complete nasal ala together with the adjacent part of the nasal tip subunit and the nasal sidewall as required.

Following the first step of nasal reconstruction, take rate of free skin grafts was 94% (15 out of 16) independent of the defect size. Except for one patient, there were no relevant signs of contraction indicating complete loss of the used skin grafts. None of the presented patients showed any necrosis of the forehead flap. Moreover, none of the transplanted free skin grafts was negatively affected by the subsequent second and third stages of reconstruction. In other words, with respect to the graft take rate of 94%, the free skin grafts did not hamper the coverage and survival of the cartilage grafts transplanted during the second stage of reconstruction.

However, one patient (patient 6) presented with a partly necrotic free skin graft transplant. Revision surgery consisted of using another full-thickness free skin graft transplant harvested from the neck and sutured in the same way to the undersurface of the forehead flap. During the planned second step of the nasal reconstruction, the free skin graft transplant was partly necrotic again, and therefore the surgeon refrained from harvesting another full-thickness skin graft leaving the undersurface of the forehead flap uncovered for secondary healing. After finishing the third reconstruction step, the patient presented, as expected, with a retraction of the left nasal wing and a stenosis of the left nostril. The patient refused further surgery to the nose. Relevant auxiliary diagnoses of this patient are extensive nicotine abuse, arterial hypertension, and the condition after a stroke.

Four patients presented with minor complications. Patient 1 developed a minor complication due to a slight

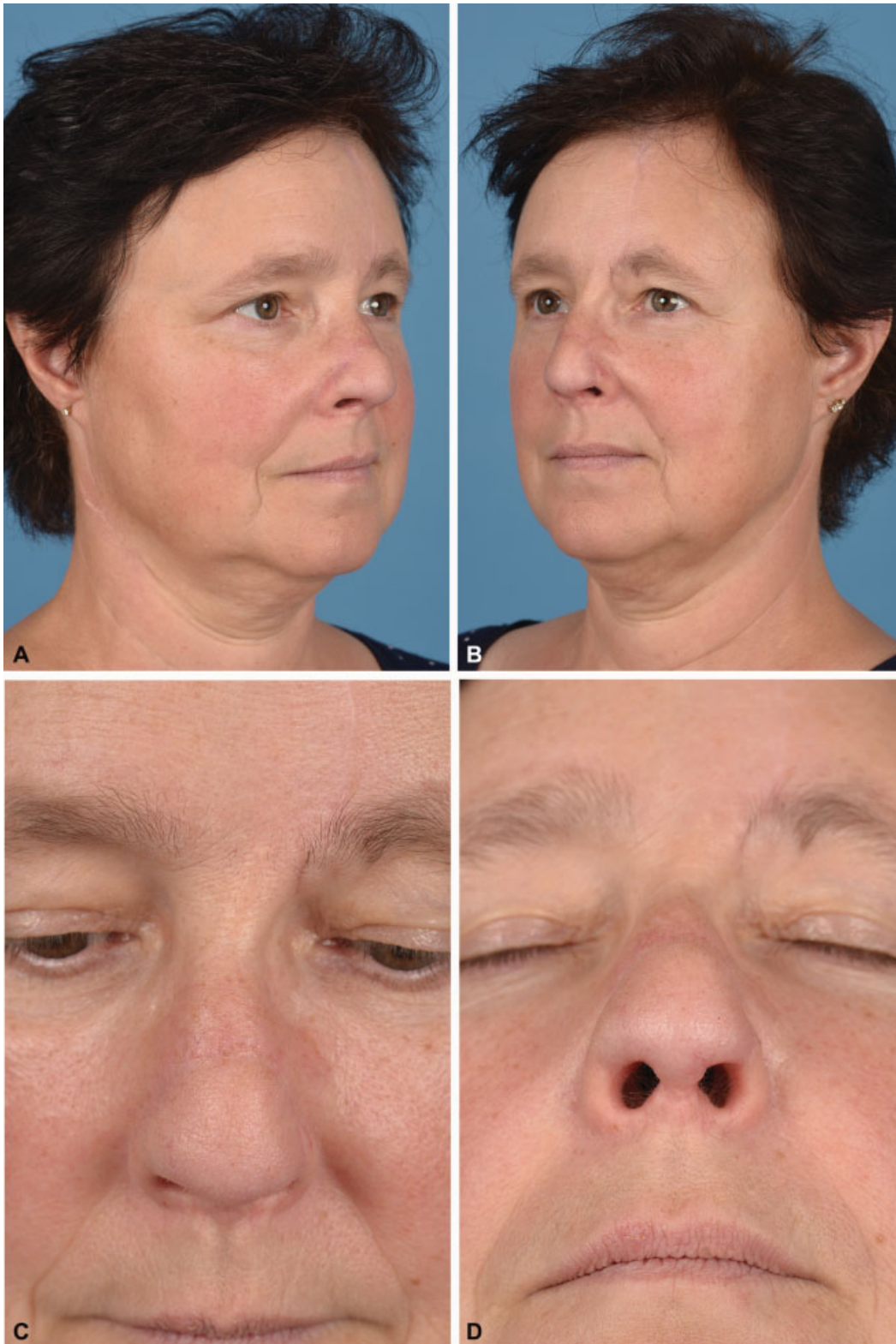

Fig. 4 (a-d) Final reconstruction result of the patient presented in ► **Figs. 2 and 3** (patient 11). Of note, the very distal part of the forehead flap on both sides shows no hints of the formerly placed quilting sutures.

contraction of the nasal wing. The patient was very satisfied with the aesthetic result and accordingly refused additional surgery.

Further minor complications that were not related to the free skin grafts involved a perforation of the nasal septum of

patient 2 that occurred 3 months after adjuvant radiotherapy due to a squamous cell carcinoma (pT2 pN1 cM0 G2 R0, UICC [Union for International Cancer Control] stage III) of the nasal vestibule. Patient 3 developed a chronic pain syndrome that was successfully treated with metamizole 500 mg (2-2-2-2

dose regimen) and amitriptyline 75 mg (0-0-1). A small dehiscence of the forehead flap that healed under conservative treatment occurred in patient 5.

The follow-up time averaged 18.4 months (range: 3–55 months). The second stage of the nasal reconstruction was performed after a mean period of 5.4 weeks (range: 4–9 weeks). The third reconstruction stage was performed after a mean period of 10.5 weeks (range: 9–16 weeks) following the first step. Hospitalization for the first step averaged 5.8 days (range: 4–7 days). Duration of surgery for the first step of nasal reconstruction averaged 227.4 minutes (range: 108–338 minutes).

Discussion

This retrospective study shows that the fixation of a full-thickness free skin graft to the undersurface of the forehead flap with multiple quilting sutures is a safe procedure for reconstruction of the internal lining of the nose.

The presented results do not correspond to the reported failure rates of free skin grafts that can be expected to reach up to 25%.⁷ Revision surgery, as needed in one of the presented cases, can be performed using free skin grafts again as they are easy to harvest and accessible and can be resutured in the same manner.

As presented, we did not experience an increased rate of late complications such as relevant contraction that may be associated with the use of free skin grafts inside the nose.² In this regard, the reconstructed cartilaginous framework during the second reconstruction stage is of utmost importance for the avoidance of contractions and the overall stability of the reconstructed nose.

Our results are in line with reports on favorable outcomes by restoring the inner nasal lining with full-thickness free skin grafts. However, these reports favor placing only few quilting sutures aiming to not jeopardize the skin grafts and the forehead flap at the same time.^{4,8}

The presented technique of multiple quilting sutures allows for a direct positioning, visualization, and, consequently, control of the graft placement and immobilization, in contrast to relying solely on nasal dressings, which contribute to the presented favorable outcomes. In this regard, it needs to be emphasized not to tighten the free skin grafts too firmly to the forehead flap. This crucial step relies on the surgeon's discretion and perception that may add to the complexity of the described technique.

As the quilting sutures precisely secure the free skin grafts, the nasal packing is dispensable for graft stenting and can be removed at the first postoperative day. Thus, patient discomfort due to the nasal dressing for several days can be expected to be distinctly reduced in comparison with leaving foam packing in the nose for 7 days.^{2,11}

Free skin grafts are mostly recommended for defects of the nasal alar and nasal sidewalls but are not considered suitable for complete reconstruction of the inner nasal lining. This especially applies to cases where the central support of the nose is lost due to extended resection of the caudal septum. Obviously larger free skin grafts required under these circum-

stances cannot be sufficiently attached to the forehead flap. Necrosis of the free skin graft would be inevitable. However, if suitable parts of the posterior septum are still available, the use of a septal pivot flap might be an option to rebuild the central support of the nose during the first stage of reconstruction. This may add another step to the reconstruction; however, if the septal pivot flap and its adherent mucosa survived free skin grafts, then it can be sutured to the septal mucosa to reconstruct the remaining lining defect. In patients who require a total reconstruction of the nose including the central support of the septum, a free forearm flap might be the only option to restore the lining defect.^{2,5,6,12} Potentially increased donor site morbidity and, in some cases, nasal obstruction due to the intranasal bulking of the free flap have to be taken into consideration.^{1,2} In such cases and those in which the central support cannot be established by a septal pivot flap, the sole use of free skin grafts secured to a forehead flap by quilting sutures is obviously not an option. Among our patients, only limited resection of the dorsal septum was necessary in five cases to obtain clear oncological margins. None of these patients required a septal pivot flap. From our experience, the free skin graft can be sutured to the remaining septal mucosa and secured to the forehead flap by quilting sutures without further restrictions during the first stage of reconstruction. Subsequently missing septal structures and central support can successfully be restored during the second stage using either ear or rib cartilage. Based on our favorable results, even larger lining defects, independent from the actual defect size, can successfully be reconstructed by the presented technique if the described requirements are fulfilled.

However, the most crucial prerequisite for the reconstruction of greater parts of the inner lining involving the nasal sidewall and the ala is a secure and immobile attachment of the free skin grafts to a nourishing recipient bed, that is, the forehead flap, using multiple quilting sutures.

Alternatively, a folded forehead flap may also be used to restore the inner nasal lining. This technique implies the major advantage that one step in the reconstruction process is usually dispensable. Restoration of the cartilaginous framework can be performed during the first stage already in most cases. In addition, a second surgery site to harvest the full-thickness skin graft with potentially donor site morbidity is not needed. Nonetheless, several drawbacks apply to a folded forehead flaps as well. The size of the lining defect is limited using a regular folded forehead flap; however, it is very challenging to reconstruct the whole internal nasal sidewall and the skin defect with a single folded forehead flap only. An expanded forehead flap may be an option in these cases; however, this requires weeks of potentially unpleasant preparations for the patient.

A folded forehead flap cannot be thinned out arbitrarily during the first step of reconstruction. This may lead to intranasal bulking, especially in the area of the nasal vestibule, resulting in impaired nasal breathing. Subsequent thinning of folded forehead flap is obviously possible, but this can be challenging with the transplanted cartilage in place. On the other hand, this would at least add a third step to the reconstruction. In contrast, beginning with the first stage of

reconstruction the thickness of a free skin graft shows only minor differences compared with the natural internal nasal lining. A folded forehead flap may also lead to a bulky and unnatural appearance along the alar rim, even after division of the flap and further thinning. This can rather be avoided by using a free full-thickness skin graft for lining reconstruction.

Turn-over flaps obtained from nasal skin adjacent to the defect represent another option to reconstruct the inner lining of the nose.¹³ However, depending on the amount of the remaining skin, they are often limited in size and will enlarge the defect of the external skin envelope. Moreover, due to the small bridge between the flap and the adjacent tissue, survival of the turn-over flap may be an issue.

Flaps elevated from the remaining septal mucosa and rotated into the lining defect may also be appropriate. This technique inevitably leaves one side of the septal cartilage uncovered. In our experience, this may lead to a crucial destabilization of the cartilages, resulting in saddling of the cartilaginous dorsum. These shortcomings represent the main reason why septal mucosa flaps were abandoned in nasal reconstruction at our institution.

Out of the experienced complications, necrosis of the transplanted full-thickness free skin graft was the most serious one and occurred in 1 out of the 16 patients.

However, this patient revealed serious secondary illnesses mostly due to his extensive nicotine abuse that have definitely contributed to this unfavorable outcome. According to these experiences, severe cardiovascular diseases and excessive smoking may represent a relative contraindication for the use of free full-thickness skin grafts. However, this issue applies to all surgical techniques used for nasal reconstruction. In general, the performed quilting suture technique was not associated with an increased occurrence for serious complications, especially flap necrosis. Similarly, the quilting sutures did not adversely affect the surface of the forehead flap in the reconstruction of the skin and soft tissue defect of the nose. Based on our experiences and in view of the discussed limitations, the presented technique can be advocated as a feasible and effective method to reconstruct the inner lining. Still, the application and safety of free full-thickness skin grafts in large defects cannot be generalized and warrants thorough individual decision-making.

Despite the favorable outcomes, some limitations of the study apply. The presented results entail the inevitable bias of the applied design of a retrospective study. In addition, the results need to be considered in view of the relatively low number of the patients included in this study, which, however, can be considered as comparatively high.^{3,6}

In addition to the information on the affected nasal subunits, no exact measures of the sizes of the applied free skin grafts are provided due to the retrospective nature of the presented study.

In our hands, quilting sutures allow for secure placement of transplanted full-thickness free skin grafts on the undersurface of the forehead flap, allowing for consistently favorable results. Based on these favorable results particularly

after a long follow-up, this technique has evolved to our preferred technique for the reconstruction of the inner nasal lining in appropriate cases.

Conclusion

Full-thickness free skin grafts fixated on the undersurface of the forehead flap with multiple quilting sutures is a feasible and effective amendment for the reconstruction of the inner nasal lining in full-thickness defects of the nose. The multiple quilting sutures are not associated with diminished free skin graft take rates or impaired vascularization but, in fact, allow for high and reliable survival of full-thickness free skin grafts.

Funding

All authors declare that there was no financial support.

Conflict of Interest

All authors declare that there was no conflict of interest during the preparation of this article. This material has never been published and is not currently under evaluation in any other peer-reviewed publication.

Acknowledgments

None.

References

- 1 Fischer H, Gubisch W. Nasal reconstruction: a challenge for plastic surgery. *Dtsch Arztebl* 2008;105(43):741–746
- 2 Haack S, Fischer H, Gubisch W. Lining in nasal reconstruction. *Facial Plast Surg* 2014;30(03):287–299
- 3 Park SS, Cook TA, Wang TD. The epithelial 'turn-in' flap in nasal reconstruction. *Arch Otolaryngol Head Neck Surg* 1995;121(10):1122–1127
- 4 Zenga J, Chi JJ. Reconstruction of the intranasal lining. *Facial Plast Surg* 2017;33(01):67–73
- 5 Moore EJ, Strome SA, Kasperbauer JL, Sherris DA, Manning LA. Vascularized radial forearm free tissue transfer for lining in nasal reconstruction. *Laryngoscope* 2003;113(12):2078–2085
- 6 Seth R, Revenaugh PC, Scharpf J, Shipchandler TZ, Fritz MA. Free anterolateral thigh fascia lata flap for complex nasal lining defects. *JAMA Facial Plast Surg* 2013;15(01):21–28
- 7 Menick FJ. *Nasal Reconstruction: Art and Practice*. Philadelphia, PA: Saunders-Elsevier; 2009
- 8 Menick FJ. The use of skin grafts for nasal lining. *Clin Plast Surg* 2001;28(02):311–321, viii
- 9 Gassner H, Sadick H, Haubner F, Artinger V, Kuehnel T. Prelamination to reconstruct internal nasal lining. *Facial Plast Surg* 2013;29(05):411–416
- 10 Menick FJ. A 10-year experience in nasal reconstruction with the three-stage forehead flap. *Plast Reconstr Surg* 2002;109(06):1839–1855, discussion 1856–1861
- 11 Iacobucci JJ, Stevenson TR. Bolster dressing to support a full-thickness skin graft. *Ann Plast Surg* 1987;18(06):550–551
- 12 Acikel C, Bayram I, Eren F, Celikoz B. Free temporoparietal fascial flaps and full-thickness skin grafts in aesthetic restoration of the nose. *Aesthetic Plast Surg* 2002;26(06):416–418
- 13 Ulug BT, Kuran I. Nasal reconstruction based on subunit principle combined with turn-over island nasal skin flap for nasal lining restoration. *Ann Plast Surg* 2008;61(05):521–526