



Failure factors for carpal tunnel syndrome surgical treatment: When and how to perform a revision carpal tunnel decompression surgery

Fatores de insucesso do tratamento cirúrgico da síndrome do túnel do carpo: Quando e como revisar a cirurgia de descompressão do túnel do carpo

Carlos Henrique Fernandes¹ João Baptista Gomes dos Santos¹ Francisco Schwartz-Fernandes²
A. Lee Ostermann³ Flávio Faloppa¹

¹ Orthopedics and Traumatology Department, Escola Paulista de Medicina, Universidade Federal de São Paulo, São Paulo, SP, Brazil

² USF Health Morsani College of Medicine, Tampa, Florida, United States

³ Hand and Orthopaedic Surgery Jefferson Medical College, Thomas Jefferson University, Philadelphia, Pennsylvania, United States

Address for correspondence Carlos Henrique Fernandes, MD, PhD, Avenida Leôncio de Magalhães, 1021, São Paulo, SP, Brazil (e-mail: carloshandsurgery@gmail.com).

Rev Bras Ortop 2022;57(5):718–725.

Abstract

Despite being a procedure widely used all over the world with high rates of symptom remission, surgical treatment of carpal tunnel syndrome may present unsatisfactory outcomes. Such outcomes may be manifested clinically by non-remission of symptoms, remission of symptoms with recurrence a time after surgery or appearance of different symptoms after surgery. Different factors are related to this unsuccessful surgical treatment of carpal tunnel syndrome. Prevention can be achieved through a thorough preoperative clinical evaluation of the patient. As such, the surgeon will be able to make differential or concomitant diagnoses, as well as determine factors related to patient dissatisfaction. Perioperative factors include the correct identification of anatomical structures for complete median nerve decompression. Numerous procedures have been described for managing postoperative factors. Among them, the most common is adhesion around the median nerve, which has been treated with relative success using different vascularized flaps or autologous or homologous tissue coverage. The approach to cases with unsuccessful surgical treatment of carpal tunnel syndrome is discussed in more detail in the text.

Keywords

- ▶ carpal tunnel syndrome/diagnosis
- ▶ carpal tunnel syndrome/surgery
- ▶ carpal tunnel syndrome/complications
- ▶ recurrence
- ▶ surgical flaps

Resumo

Apesar de ser um procedimento amplamente utilizado em todo o mundo e com elevadas taxas de remissão dos sintomas, o tratamento cirúrgico da síndrome do túnel do carpo pode apresentar resultados não satisfatórios ao paciente. Esse resultado não satisfatório pode se manifestar clinicamente pela não remissão dos sintomas, remissão dos sintomas mas

received
December 20, 2019
accepted
April 20, 2020
published online
September 22, 2020

DOI <https://doi.org/10.1055/s-0040-1713759>.
ISSN 0102-3616.

© 2020. Sociedade Brasileira de Ortopedia e Traumatologia. All rights reserved.

This is an open access article published by Thieme under the terms of the Creative Commons Attribution-NonDerivative-NonCommercial-License, permitting copying and reproduction so long as the original work is given appropriate credit. Contents may not be used for commercial purposes, or adapted, remixed, transformed or built upon. (<https://creativecommons.org/licenses/by-nc-nd/4.0/>)

Thieme Revinter Publicações Ltda., Rua do Matoso 170, Rio de Janeiro, RJ, CEP 20270-135, Brazil

Palavras-chave

- ▶ síndrome do túnel do carpo/diagnóstico
- ▶ síndrome do túnel do carpo/cirurgia
- ▶ síndrome do túnel do carpo/complicações
- ▶ recidiva
- ▶ retalhos cirúrgicos

recorrência desses após um período de tempo da cirurgia ou aparecimento de diferentes sintomas após a cirurgia. Diferentes fatores estão relacionados a esse insucesso do tratamento cirúrgico da síndrome do túnel do carpo (ITCSTC). A prevenção pode ser conseguida por meio de minuciosa avaliação clínica do paciente no período pré-operatório. Dessa forma o cirurgião poderá fazer diagnósticos diferenciais ou diagnósticos concomitantes, assim como identificar fatores ligados a insatisfação do paciente. Os fatores per-operatórios incluem a correta identificação das estruturas anatômicas para completa descompressão do nervo mediano. Inúmeros procedimentos têm sido descritos para o tratamento dos fatores que ocorrem no período pós-operatório. Desses o mais comum, a formação de aderências em torno do nervo mediano, tem sido tratado com relativo sucesso utilizando diferentes retalhos vascularizados ou cobertura com o uso de tecido autólogo ou homólogo. Descreveremos a abordagem do ITCSTC com maiores detalhes no texto.

Introduction

Carpal tunnel syndrome (CTS) affects 3% to 5% of the general population.¹ Karpitskaya et al.² observed that obesity, hypothyroidism, and diabetes are more prevalent in patients with CTS when compared to the general population but found no differences regarding smoking. Approximately 2 to 4 in every 100 adults with CTS symptoms will undergo surgical treatment.³ Surgical treatment of carpal tunnel syndrome, which consists in transverse carpal ligament sectioning to decompress the median nerve, has proven to be effective for symptom remission.⁴ Even though this is a common procedure, cases of patient dissatisfaction after surgical treatment are more frequent than expected.⁵ Studies show that relapses can occur in 3% to 20% of cases.^{6,7} This situation causes patient dissatisfaction and frustration for the surgeon. In the United States, a lawsuit after a CTS surgery can cost the surgeon US\$ 300,000.00 to US\$ 600,000.00.⁸

Failure of CTS surgical treatment can present itself as three different clinical situations regarding symptoms. In the first one, patients have persistent symptoms after surgery. In the second clinical situation, symptoms remit temporarily after surgical treatment and then recur. In the third situation, there is symptom remission after surgery, but patients have different postoperative complaints.⁹ Zieske et al.¹⁰ reported that persistent symptoms are responsible for approximately 40% of complaints in patients undergoing CTS surgery revision. Postoperative symptom worsening and thenar muscles paralysis are related to an iatrogenic injury and account for 15% and 67% of the causes of unsuccessful CTS surgical treatment.¹⁰⁻¹² In cases of suspected iatrogenic injury, early reintervention is indicated for diagnostic confirmation and treatment.⁵

It is very important that the surgeon identifies possible factors that may result in unsuccessful CTS surgical treatment to prevent its occurrence. A CTS surgery revision must be well planned considering that up to 40% of patients present unfavorable outcomes.^{10,13}

Supported by studies found in the literature, this review reflects the authors' experience with CTS surgical treatment in patients who were not satisfied with the initial procedure.

Factors for the unsuccessful surgical treatment of carpal tunnel syndrome

Several factors that can lead to the unsuccessful surgical treatment of CTS. These factors can be divided into preoperative, perioperative, and postoperative factors. It is not always easy for the surgeon to recognize these factors. Diagnosis and surgical procedures are often underestimated, considered simple and easy by both patients and surgeons.

The first factor to be considered is the preoperative diagnosis, differential diagnoses, and associated conditions. By definition, a syndrome is a set of signs and symptoms associated with a known or unknown entity. There is abundant medical literature showing a wide range of signs and symptoms in CTS patients. In 2009, the American Academy of Orthopedic Surgeons (AAOS) published recommendations for CTS diagnosis. These recommendations are not absolute and treatment must always be based on the physician's independent judgment and according to individual clinical circumstances.¹⁴ AAOS recommendations include that the surgeon have a detailed clinical history of the patient, perform a physical examination, including personal features, provocative tests, sensitivity tests, muscle examination and/or discriminatory tests for differential diagnoses.¹⁴ Despite these recommendations, CTS diagnosis is not always easy. There is no "cake recipe" for this diagnosis. The most common presentation of CTS is paresthesia affecting the radial fingers of the hand, including the thumb, index and middle fingers, but the clinical presentation can vary in each individual subject.¹⁵ In addition to the variable clinical presentation, most cases with subjective symptoms, the syndrome can occur in association or concomitance with systemic conditions. It is worth remembering that the

tingling hand sensation, the most frequent complaint in CTS patients, can be observed in the general population, with no carpal tunnel syndrome.¹ A detailed clinical evaluation includes provocative tests, the Tinel signal, the Durkan maneuver, the Phalen test and the “scratch collapse test.”¹⁶ The Tinel sign has 60% sensitivity and 67% specificity, whereas the Phalen test has 75% sensitivity and 47% specificity.¹⁷

Hand sensitivity can be evaluated using different methods, such as the two-point discrimination test and the nylon monofilament test.^{18,19} The monofilament test combined with the Phalen wrist flexion test has 82% sensitivity and 86% specificity for CTS diagnosis.²⁰ Provocative, sensitivity and strength tests are limited by their subjectivity. Responses to provocative tests, monofilament stimuli or the force required to hold a dynamometer are determined by the patient. A surgeon is unable to know if a patient is simulating a response during the examination.

Electroneuromyography (ENMG) is considered the gold standard for diagnostic confirmation and may reveal changes in asymptomatic patients.²¹ ENMG must be performed for differential diagnosis in cases of thenar atrophy and/or persistent numbness or if surgical treatment is being considered for a clinical suspicion. In these cases, ENMG must be performed according to the guidelines from the American Academy of Neurology (AAN), the American Association of Neuromuscular and Electrodiagnostic Medicine (AANEM) and the American Academy of Physical Medicine and Rehabilitation (AAPMR).¹⁴ Grading compression intensity as mild, moderate or severe is useful because sensorial symptoms resolution is faster in patients with mild or moderate CTS compared to those with severe CTS.²² Since ENMG is limited by the postsurgical persistence of electrical changes even in asymptomatic patients, we believe that it is not a good parameter for evaluating outcomes from median nerve decompression at the carpal tunnel. An exception is postsurgical symptoms worsening in cases with suspected iatrogenic injury, in which ENMG reveals deterioration of evaluated parameters.

Ultrasound can aid diagnostic confirmation. A study shows that the presurgical cross-sectional area of the median nerve decreases from the 4th postoperative week on.²³ A disadvantage is that ultrasound is an operator-dependent examination.

Additional tests, such as magnetic resonance imaging, computed axial tomography or evoked potential testes, must not be used routinely.¹⁴

Self-assessment protocols can be used to assess the severity of symptoms and hand function in CTS patients. The questionnaire created by Levine has been used in international research, and it was translated and validated for Brazilian Portuguese.²⁴ A disadvantage of the Levine questionnaire is that it is long and time-consuming. The questionnaire developed by Atroshi, called CTS-6, is short, easy to understand by the patient and quick to fill out; in addition, it was translated into Brazilian Portuguese.²⁵ The Brief Michigan Hand Questionnaire is also short and easy to apply but is less specific to CTS.²⁶

In certain clinical situations, an accurate diagnosis can prevent patient dissatisfaction after surgical treatment for CTS.²⁰ The first situation is when the patient has manual paresthetic symptoms, but nervous compression occurs in another site rather than the carpal tunnel. The most common differential diagnoses are pronator teres syndrome, compression by the lacertus fibrosus and cervical disc hernias. The second situation is characterized by symptoms of median nerve compression at the carpal tunnel, but with a concomitant second site of nervous compression, the so-called double compression. Median nerve compression at the carpal tunnel may be concomitant to ulnar nerve compression, representing a challenging diagnosis. The literature describes that outcomes from CTS surgical treatment are less predictable when there is a second site of nervous compression.⁹ In a third situation, the patient presents median nerve compression at the carpal tunnel, but has comorbidities that manifest as paresthetic symptoms, such as fibromyalgia, diabetes mellitus, hypothyroidism, gout, rheumatoid arthritis, neuritis and other peripheral nerves conditions.^{27,28} Postoperative symptom improvement is usually more slowly in patients with these comorbidities compared to healthy individuals, despite the significant upgrading in symptom severity scores.²⁹ A fourth situation is characterized by median nerve compression at the carpal tunnel and psychological comorbidities affecting the patient's perception. Such comorbidities include depression and secondary gains from health conditions.³⁰ Discordant expectations between the surgeon and patient regarding treatment outcome can lead to conflicts. The surgeon must explain to the patient the possible realistic surgical results. In severe and long-lasting nerve compressions, symptoms such as numbness and muscle changes may not resolve completely after surgery.³¹

The previous presence of trapeziometacarpal arthrosis, De Quervain tenosynovitis and trigger finger must be investigated, diagnosed and reported because they interfere with patient satisfaction after surgical CTS decompression.^{29,32} The treatment of these concomitant conditions must be carried out concurrently with median nerve release to avoid postoperative residual symptoms. The literature is controversial as to whether surgical CTS treatment accelerates or predisposes to the appearance of trigger finger.^{33,34}

In case of doubts regarding benefits from surgery, a steroid injection within the carpal tunnel can be made in an attempt to predict the surgical outcome.³⁵

The most common perioperative causes of unsuccessful CTS surgical treatment are incomplete section of the transverse carpal ligament (TCL), iatrogenic intraoperative nerve damage and failure to identify anatomical tendon changes. Zhang et al.⁹ reported that incomplete decompression accounts for 50% to 58% of patients with persistent symptoms and that it can result in an acute worsening of symptoms due to median nerve compression. The location of incomplete release is not correlated with an open or endoscopic surgical technique.¹² In most cases, incomplete

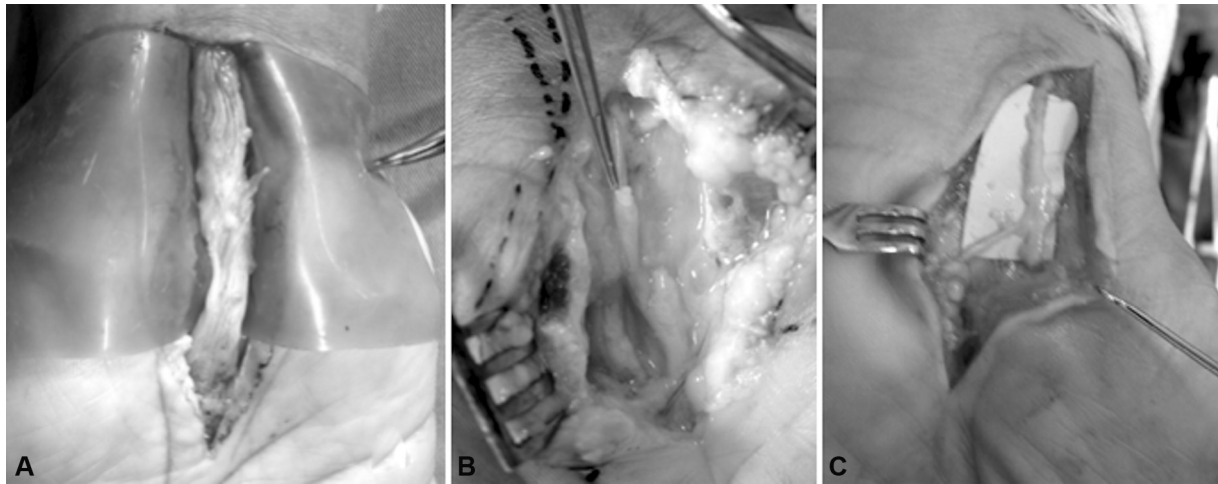


Fig. 1 Photography of revisions carpal tunnel decompression surgery demonstrating iatrogenic intraoperative nerve damage. (A) Median nerve injury. (B) Digital nerve injury. (C) Palmar cutaneous nerve injury.

release is due to the integrity of distal TCL fibers or proximal transverse fibers at the wrist crease and distal antebrachial fascia.^{12,36} Iatrogenic intraoperative nerve damage usually presents with constant paresthetic symptoms that are not altered by wrist position or time of day. In a retrospective study on unsuccessful CTS surgical treatment, Karl et al.³⁷ observed that only 0.6% of the complications were due to median nerve injury, whereas 0.12% resulted from digital nerve injury, 0.03% were caused by palmar cutaneous nerve injury and 0.01% were due to a motor branch injury (► **Fig. 1**). Failure to recognize the presence of anatomical musculotendinous variations is described as a possible cause for secondary compression and sustained clinical symptoms.^{38,39}

Postoperative causes for unsuccessful CTS surgical treatment are cicatricial adhesions around the median nerve and transverse carpal ligament reconstruction by the scar tissue.³⁵ Tung et al.¹¹ reported finding healing adhesions around the median nerve in 88% of their patients undergoing surgical revision. These adhesions can be localized or found throughout the nerve contour but are sufficient to prevent nerve excursion within the carpal tunnel and decrease nerve vascularization.³⁶ TCL reconstitution was observed during revision surgery. Jones et al.¹² and Mosier et al.⁴⁰ observed TCL reconstitution with scar tissue during surgical revisions performed mostly less than 1 year after the index procedure. These adhesions around the median nerve can be avoided by using the ulnar approach with eccentric opening of the flexor retinaculum in the most ulnar region, preventing the formation of scar tissue just above the median nerve.⁴¹

When to Review a Carpal Tunnel Surgery

The revision of a median nerve decompression surgery is indicated in patients with incomplete median nerve decompression, iatrogenic nerve damage and those with recurrent CTS after a prolonged period of symptom relief.^{13,40}

O'Malley et al.⁴² recommend surgical revision in patients who continue to present hand paresthesia during the Phalen test, night awakening or paresthetic symptoms exacerbated by physical or labor activities. These authors believe that if the primary incision was considered adequate and these symptoms were not present, a revision will not result in a satisfactory outcome. Stang et al.⁴³ agree that surgical revision outcomes are positive, with pain, neurological symptoms, and strength improvement, especially in patients with recurrences. In a recent prospective study, Stirling et al.⁴⁴ confirmed that patients undergoing open carpal tunnel decompression revision showed a significant improvement in function and health-related quality of life.

Surgical revision failures were related to different factors.¹¹ Cobb and Amadio⁷ reported that the existence of a labor claim made by the patient, the presence of symptoms at the ulnar nerve distribution and absence of abnormalities in a preoperative electroneuromyography are risk factors for surgical revision failure.

How to Perform a Revision Carpal Tunnel Decompression Surgery

A revision carpal tunnel decompression surgery must be performed through an open approach. This approach will allow a better visualization of potential residual compression sites and the presence of possible anatomical variations or adhesions around the median nerve. The incision must start 5 to 7 cm proximal to the wrist flexion crease, include the pre-existing scar and continue in Bruner zigzag up to the palm of the hand.⁵ Due to the difficulty dissection resulting from the healing tissue at the pre-existing scar region, greater care must be taken to avoid an iatrogenic injury to the median nerve. During nerve evaluation with a magnifying glass or microscope, we must be aware of regions of circumferential compression similar to an hourglass which justifies recurrent or persistent compression. Any tissue that

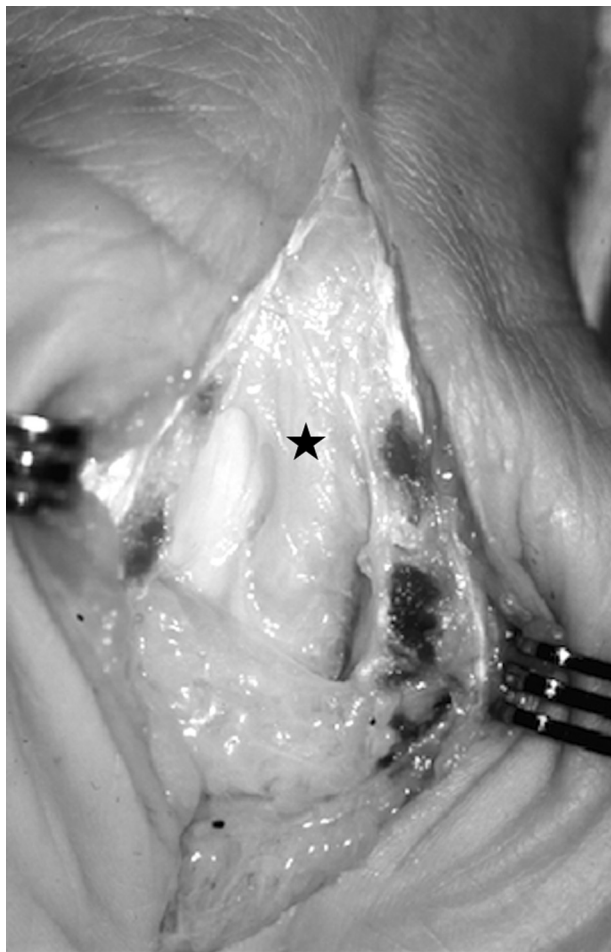

Fig. 2 Open approach to allow visualization of potential residual compression sites and adhesions around the median nerve (star).

may compress the median nerve must be removed at this surgical stage (► **Fig. 2**). Any totally or partially damaged nerve site must be repaired with a nerve graft. Ulnar nerve decompression in the Guyon canal can be performed if required.⁵

Ancillary procedures are often required to restore median nerve slippage, minimize scarring and improve neural circulation.^{45,46} The nerve can be covered with synthetic materials, autologous tissue (such as vein interposition around the median nerve) or soft tissue flaps.^{47,48}

Synthetic materials can be used for median nerve protection. Collagen compounds are the main elements of the extracellular matrix. As an advantage, these materials require no additional incisions; however, there is no clinical evidence of their superiority over other methods.⁴⁹

The concept of vein interposition, placing the vein around the median nerve as a barrier to prevent scarring, was originally described in rats but it has been used clinically.^{48,50} The surgical technique consists of releasing the median nerve from cicatricial adhesions and identifying the region to be covered by a vein. After harvesting 25 to 30 cm, the saphenous vein is opened longitudinally. With the

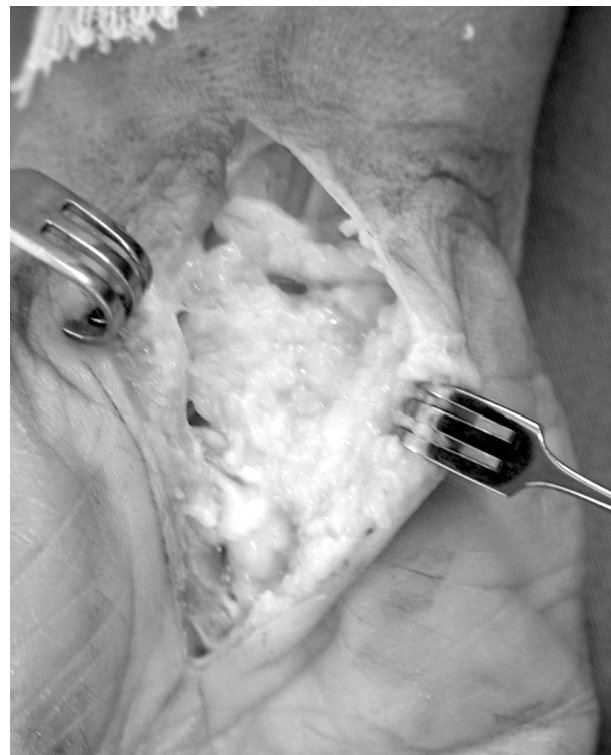

Fig. 3 An hypothenar fat pad flap was performed to interpose adipose tissue from the hypothenar eminence between the median nerve and overlying transverse carpal ligament and surgical scar.

intima contacting the median nerve, the vein is wrapped around the nerve and an 8-0 suture is placed at every 360 degrees to keep the vein in place. In a clinical trial, Varitimidis et al.⁵⁰ observed improvements in pain, paresthetic symptoms, sensitivity assessed by two-point discrimination and electroneuromyography parameters. As a disadvantage, this technique requires an additional incision for graft harvest.

Different flaps have been described for median nerve protection and local circulation improvement. An adipose flap of the hypothenar eminence was popularized by Strickland⁵¹ (► **Fig. 3**). After median nerve decompression and adhesions removal, an adipose tissue flap is placed between the median nerve and the TCL.^{51,52} Silva et al.⁵² observed symptoms improvement in 13 of 15 patients who underwent surgery using this flap technique. Zummioti et al.⁴⁵ obtained good outcomes in 15 patients. Fusetti et al.⁴⁶ observed symptom resolution 6 months after surgery in 18 of 20 patients treated with this flap. The hypothenar fat flap can also be performed in a so-called reverse form, in which the flap is rotated 180 degrees to cover the carpal tunnel⁵³ (► **Fig. 4**).

The fascial radial artery flap was used in six patients with good outcomes, but it has the disadvantage of sacrificing the radial artery.⁵⁴ A dorsal forearm flap was used with good results, with the advantage of preserving the radial artery.⁵⁵

Vogelin et al.⁵⁶ used a posterior interosseous artery flap and, for an average follow-up of 2 years, 12 of 14 patients presented significant pain improvement.

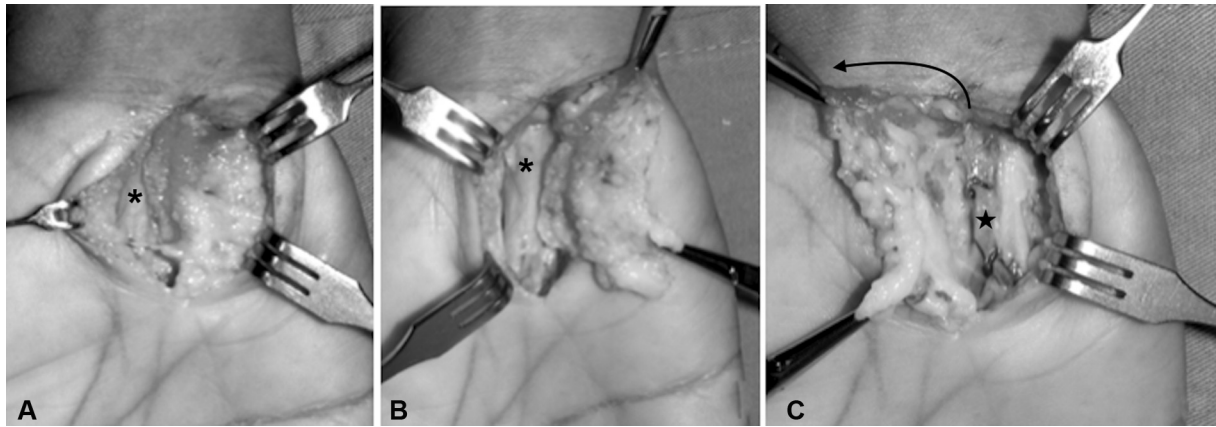


Fig. 4 After remotion of tissue that may compress the median nerve (*), the adipose tissue is dissected until the hypothenar muscles and palmar brevis muscle are identified (A). As the flap is irrigated by the ulnar artery (star), it is raised (B), rotated 180 degrees (black arrow) and transposed in the radial direction to cover the median nerve (C).

Treatment options include muscle flaps, but their disadvantage is that the amount of tissue may be inadequate to cover the entire region.⁵⁷

Free flaps are technically more laborious, and they must be used as a last resource in patients who have undergone several previous procedures, including local flaps.⁵⁷

A systematic meta-analysis compared outcomes from a simple surgical revision with a revision associated with a flap for median nerve protection. Ninety-four patients from 14 studies treated with flap coverage were compared with 364 patients from nine studies using open decompression and neurolysis alone. The flap group had a success rate of 86% compared to 75% in the group with no flap ($P = 0.001$). Despite the higher success rate, the flap group had a higher number of complications, such as paresthesia, scar sensitivity and wound issues.⁵⁸

Final Considerations

CTS surgical treatment can be unsuccessful in a significant number of patients who have undergone carpal tunnel release. In these cases, we recommend starting with a new clinical evaluation to rule out differential diagnoses. If it is confirmed that the problem is local, make an enlarged incision that includes the pre-existing surgical scar and release the median nerve from any compression or scar around it. If there are significant scars or perineural fibrosis, a flap must be performed to decrease the formation of new adhesions and provide interposition with neovascularization.

Conflict of Interests

The authors declare that there is no conflict of interest.

References

- Atroshi I, Gummesson C, Johnsson R, Ornstein E, Ranstam J, Rosén I. Prevalence of carpal tunnel syndrome in a general population. *JAMA* 1999;282(02):153–158
- Karpitskaya Y, Novak CB, Mackinnon SE. Prevalence of smoking, obesity, diabetes mellitus, and thyroid disease in patients with carpal tunnel syndrome. *Ann Plast Surg* 2002;48(03):269–273
- Pourmemari MH, Heliövaara M, Viikari-Juntura E, Shiri R. Carpal tunnel release: Lifetime prevalence, annual incidence, and risk factors. *Muscle Nerve* 2018;58(04):497–502
- Verdugo RJ, Salinas RA, Castillo JL, Cea JG. Surgical versus non-surgical treatment for carpal tunnel syndrome. *Cochrane Database Syst Rev* 2008;(04):CD001552
- Lauder A, Mithani S, Leversedge FJ. Management of recalcitrant carpal tunnel syndrome. *J Am Acad Orthop Surg* 2019;27(15):551–562
- Louie D, Earp B, Blazar P. Long-term outcomes of carpal tunnel release: a critical review of the literature. *Hand (N Y)* 2012;7(03):242–246
- Cobb TK, Amadio PC. Reoperation for carpal tunnel syndrome. *Hand Clin* 1996;12(02):313–323
- Gil JA, Bokshan S, Genovese T, Got C, Daniels AH. Medical malpractice following carpal tunnel surgery. *Orthopedics* 2018;41(04):e569–e571
- Zhang D, Earp BE, Blazar P. Evaluation and Management of Unsuccessful Carpal Tunnel Release. *J Hand Surg Am* 2019;44(09):779–786
- Zieske L, Ebersole GC, Davidge K, Fox I, Mackinnon SE. Revision carpal tunnel surgery: a 10-year review of intraoperative findings and outcomes. *J Hand Surg Am* 2013;38(08):1530–1539
- Tung TH, Mackinnon SE. Secondary carpal tunnel surgery. *Plast Reconstr Surg* 2001;107(07):1830–1843, quiz 1844, 1933
- Jones NF, Ahn HC, Eo S. Revision surgery for persistent and recurrent carpal tunnel syndrome and for failed carpal tunnel release. *Plast Reconstr Surg* 2012;129(03):683–692
- Beck JD, Brothers JG, Maloney PJ, Deegan JH, Tang X, Klena JC. Predicting the outcome of revision carpal tunnel release. *J Hand Surg Am* 2012;37(02):282–287
- Keith MW, Masear V, Chung KC, et al. American Academy of Orthopaedic Surgeons Clinical Practice Guideline on diagnosis of carpal tunnel syndrome. *J Bone Joint Surg Am* 2009;91(10):2478–2479
- Elfar JC, Calfee RP, Stern PJ. Topographical assessment of symptom resolution following open carpal tunnel release. *J Hand Surg Am* 2009;34(07):1188–1192
- Cheng CJ, Mackinnon-Patterson B, Beck JL, Mackinnon SE. Scratch collapse test for evaluation of carpal and cubital tunnel syndrome. *J Hand Surg Am* 2008;33(09):1518–1524

- 17 Dawson DM. Entrapment neuropathies of the upper extremities. *N Engl J Med* 1993;329(27):2013–2018
- 18 Dellon AL, Mackinnon SE, Brandt KE. The markings of the Semmes-Weinstein nylon monofilaments. *J Hand Surg Am* 1993;18(04):756–757
- 19 Lehman LF, Orsini MB, Nicholl AR. The development and adaptation of the Semmes-Weinstein monofilaments in Brazil. *J Hand Ther* 1993;6(04):290–297
- 20 Chammas M, Boretto J, Burmann LM, Ramos RM, Dos Santos Neto FC, Silva JB. Carpal tunnel syndrome - Part I (anatomy, physiology, etiology and diagnosis). *Rev Bras Ortop* 2014;49(05):429–436
- 21 Fowler JR, Byrne K, Pan T, Goitz RJ. False-positive rates for nerve conduction studies and ultrasound in patients without clinical signs and symptoms of carpal tunnel syndrome. *J Hand Surg Am* 2019;44(03):181–185
- 22 Fowler JR, Munsch M, Huang Y, Hagberg WC, Imbriglia JE. Pre-operative electrodiagnostic testing predicts time to resolution of symptoms after carpal tunnel release. *J Hand Surg Eur Vol* 2016;41(02):137–142
- 23 Pimentel BF, Abicalaf CA, Braga L, et al. Cross-sectional area of the median nerve characterized by Ultrasound in Patients With Carpal Tunnel Syndrome Before and After the Release of the Transverse Carpal Ligament. *J Diagn Med Sonogr* 2013;29(03):116–121
- 24 de Campos CC, Manzano GM, de Andrade LB, Castelo Filho A, Nóbrega JAM. Tradução e validação do questionário de avaliação de gravidade dos sintomas e do estado funcional na síndrome do túnel do carpo. *Arq Neuropsiquiatr* 2003;61(01):51–55
- 25 Matsuo RP, Fernandes CH, Meirelles LM, Raduan Neto J, Dos Santos JBG, Fallopa F. Translation and cross-cultural adaptation of the 6-item carpal tunnel syndrome symptoms scale and palmar pain scale questionnaire into Brazilian Portuguese. *Hand (N Y)* 2016;11(02):168–172
- 26 Fernandes CH, Neto JR, Meirelles LM, Pereira CN, Dos Santos JB, Fallopa F. Translation and cultural adaptation of the Brief Michigan Hand Questionnaire to Brazilian Portuguese language. *Hand (N Y)* 2014;9(03):370–374
- 27 Eroğlu A, Sarı E, Topuz AK, Şimşek H, Pusat S. Recurrent carpal tunnel syndrome: Evaluation and treatment of the possible causes. *World J Clin Cases* 2018;6(10):365–372
- 28 Straub TA. Endoscopic carpal tunnel release: a prospective analysis of factors associated with unsatisfactory results. *Arthroscopy* 1999;15(03):269–274
- 29 Kim JH, Gong HS, Lee HJ, Lee YH, Rhee SH, Baek GH. Pre- and post-operative comorbidities in idiopathic carpal tunnel syndrome: cervical arthritis, basal joint arthritis of the thumb, and trigger digit. *J Hand Surg Eur Vol* 2013;38(01):50–56
- 30 Lozano Calderón SA, Paiva A, Ring D. Patient satisfaction after open carpal tunnel release correlates with depression. *J Hand Surg Am* 2008;33(03):303–307
- 31 Kamiya H, Kimura M, Hoshino S, Kobayashi M, Sonoo M. Prognosis of severe carpal tunnel syndrome with absent compound muscle action potential. *Muscle Nerve* 2016;54(03):427–431
- 32 Joshy S, Thomas B, Ghosh S, Haidar SG, Deshmukh SC. Patient satisfaction following carpal-tunnel decompression: a comparison of patients with and without osteoarthritis of the wrist. *Int Orthop* 2007;31(01):1–3
- 33 Harada K, Nakashima H, Teramoto K, Nagai T, Hoshino S, Yone-mitsu H. Trigger digits-associated carpal tunnel syndrome: relationship between carpal tunnel release and trigger digits. *Hand Surg* 2005;10(2-3):205–208
- 34 Gancarczyk SM, Strauch RJ. Carpal tunnel syndrome and trigger digit: common diagnoses that occur “hand in hand”. *J Hand Surg Am* 2013;38(08):1635–1637
- 35 Green DP. Diagnostic and therapeutic value of carpal tunnel injection. *J Hand Surg Am* 1984;9(06):850–854
- 36 Stutz N, Gohritz A, van Schoonhoven J, Lanz U. Revision surgery after carpal tunnel release—analysis of the pathology in 200 cases during a 2 year period. *J Hand Surg Am* 2006;31(01):68–71
- 37 Karl JW, Gancarczyk SM, Strauch RJ. Complications of carpal tunnel release. *Orthop Clin North Am* 2016;47(02):425–433
- 38 Mimura T, Uchiyama S, Hayashi M, Uemura K, Moriya H, Kato H. Flexor carpi radialis brevis muscle: A case report and its prevalence in patients with carpal tunnel syndrome. *J Orthop Sci* 2017;22(06):1026–1030
- 39 Keese GR, Wongworawat MD, Frykman G. The clinical significance of the palmaris longus tendon in the pathophysiology of carpal tunnel syndrome. *J Hand Surg [Br]* 2006;31(06):657–660
- 40 Mosier BA, Hughes TB. Recurrent carpal tunnel syndrome. *Hand Clin* 2013;29(03):427–434
- 41 Galbiatti JA, Komatsu S, Faloppa F, Albertoni WM, Silva SE. Via de acesso ulnar na síndrome do túnel do carpo -. *Rev Bras Ortop* 1991;26(11/12):389–394
- 42 O'Malley MJ, Evanoff M, Terrono AL, Millender LH. Factors that determine reexploration treatment of carpal tunnel syndrome. *J Hand Surg Am* 1992;17(04):638–641
- 43 Stang F, Stütz N, Lanz U, van Schoonhoven J, Prommersberger KJ. [Results after revision surgery for carpal tunnel release]. *Handchir Mikrochir Plast Chir* 2008;40(05):289–293
- 44 Stirling PHC, Yeoman TFM, Duckworth AD, Clement ND, Jenkins PJ, McEachan JE. Decompression for recurrent carpal tunnel syndrome provides significant functional improvement and patient satisfaction. *J Hand Surg Eur Vol* 2020;45(03):250–254
- 45 Zumiotti AV, Ohno PE, Prada FS, Azze RJ. Complicações do tratamento cirúrgico da síndrome do túnel do carpo. *Rev Bras Ortop* 1996;31(03):199–202
- 46 Fusetti C, Garavaglia G, Mathoulin C, Petri JG, Lucchina S. A reliable and simple solution for recalcitrant carpal tunnel syndrome: the hypothenar fat pad flap. *Am J Orthop* 2009;38(04):181–186
- 47 Chamas M, Boretto J, Burmann LM, Ramos RM, Santos Neto FC, Silva JB. Síndrome do túnel do Carpo- Parte II (Tratamento). *Rev Bras Ortop* 2014;49(05):437–445
- 48 Xu J, Sotereanos DG, Moller AR, et al. Nerve wrapping with vein grafts in a rat model: a safe technique for the treatment of recurrent chronic compressive neuropathy. *J Reconstr Microsurg* 1998;14(05):323–328, discussion 329–330
- 49 Dy CJ, Aunins B, Brogan DM. Barriers to epineural scarring: Role in treatment of Traumatic nerve injury and chronic compressive neuropathy. *J Hand Surg Am* 2018;43(04):360–367
- 50 Varitimidis SE, Vardakas DG, Goebel F, Sotereanos DG. Treatment of recurrent compressive neuropathy of peripheral nerves in the upper extremity with an autologous vein insulator. *J Hand Surg Am* 2001;26(02):296–302
- 51 Strickland JW, Idler RS, Lourie GM, Plancher KD. The hypothenar fat pad flap for management of recalcitrant carpal tunnel syndrome. *J Hand Surg Am* 1996;21(05):840–848
- 52 Silva JB, Fontes Neto P, Rio JT, Fridman M. Retalho hipotenariano-adiposo na recidiva da síndrome do túnel do carpo. *Rev Bras Ortop* 1996;31(12):1019–1022
- 53 Ramos RFM, Meneguzzi K, Pelliccioli A, Varela G, Calcagnotto FN, Silva JB. Retalho tenar adipofascial reverso para cobertura do nervo mediano hipertrofiado em macrodactilia. *Rev Bras Cir Plást* 2015;30(04):674–679
- 54 Tham SK, Ireland DC, Riccio M, Morrison WA. Reverse radial artery fascial flap: a treatment for the chronically scarred median nerve in recurrent carpal tunnel syndrome. *J Hand Surg Am* 1996;21(05):849–854

- 55 Galbiatti JA, Gilbert A, Brunelli F, et al. Study of anatomical bases of a latero-dorsal flap of the forearm preserving the radial artery. *Rev Paul Med* 1992;110(01):14-19
- 56 Vögelin E, Bignion D, Constantinescu M, Büchler U. [Revision surgery after carpal tunnel release using a posterior interosseous artery island flap]. *Handchir Mikrochir Plast Chir* 2008;40(02):122-127
- 57 Abzug JM, Jacoby SM, Osterman AL. Surgical options for recalcitrant carpal tunnel syndrome with perineural fibrosis. *Hand (N Y)* 2012;7(01):23-29
- 58 Soltani AM, Allan BJ, Best MJ, Mir HS, Panthaki ZJ. A systematic review of the literature on the outcomes of treatment for recurrent and persistent carpal tunnel syndrome. *Plast Reconstr Surg* 2013;132(01):114-121