

# Tumoral Calcinosis: Case Report and Review

Piyush Vaghasiya<sup>1</sup> Lathika Shetty<sup>2</sup> Molahalli Shantharam Shetty<sup>3</sup> Muthur Ajith Kumar<sup>1</sup>

<sup>1</sup>Department of Orthopaedics, Tejasvini Hospital and Shantharam Shetty Institute of Orthopaedics and Traumatology, Mangalore, Karnataka, India

<sup>2</sup>Department of Radiodiagnosis, K.S. Hegde Medical Academy, Mangalore, Karnataka, India

<sup>3</sup>Nitte (Deemed to be University), Mangalore, Karnataka, India

**Address for correspondence** Piyush Vaghasiya, MD, Department of Orthopaedics, Tejasvini Hospital and Shantharam Shetty Institute of Orthopaedics and Traumatology, Mangalore, Karnataka, India (e-mail: dr.piyushdineshbhai@gmail.com).

J Health Allied Sci NU:2020;10:90–96

## Abstract

### Keywords

- tumoral calcinosis
- calcification
- calcium deposition
- tumor
- KLOTHO
- phosphate binders

Tumoral calcinosis (TC) is an uncommon disorder characterized by the deposition of calcium phosphate in periarticular tissues. TC has been a controversial clinico-pathological entity first described in 1943. The calcium deposits are usually present in the large joints such as the hips and shoulders. Patients often present with localized swelling and reduced mobility around the involved joints which interfere with activities of daily living. A 12-year-old boy presented at our clinic with a painful swelling around his left elbow joint with 6-month duration over which the swellings progressively increased. Radiological imaging identified a soft tissue calcified mass present around both elbow joints. Excision and biopsy of the left elbow demonstrated a tumor consisting of myxoid material with multiple areas of calcification with a well-defined capsule. Microscopy confirmed typical features of TC. We present our case report due to unusual clinical presentation noted in this case.

## Introduction

Tumoral calcinosis (TC) is a periarticular calcific lesion of which the exact etiology and incidence is unknown.<sup>1</sup> It involves deposition of calcium within the surrounding soft tissue, commonly of the large joints such as the hip and shoulder but has been reported in joints such as the elbow, wrist, knee joint, scalp, larynx, spine, and sacrum.<sup>2–6</sup> It commonly presents in pediatric or adolescent age groups as a painless, firm, and swelling around the affected joint that may lead to limitations in the joint function.<sup>7–9</sup> Our report presents an example of such a case and discusses the pathogenesis and treatment of bilateral elbow TC in a pediatric patient.

## Historical Review

Dr. M.H. Duret was the first person to report a case of tumoral calcinosis in 1899 who named it as “endothelium calcific.”<sup>10</sup> The term “TC” was first coined by Inclan et al in 1943 for a disease characterized by a large juxta-articular, lobular calcified mass without visceral or skin calcifications in patients with normal serum calcium and phosphorus levels.<sup>11</sup> The characteristic pathological features of these lesions

were the presence of multiple cysts filled with calcified deposits lined by histiocytes, giant cells, and xanthomatous histiocytes.<sup>12</sup>

## Etiology, Pathogenesis, and Classification

The etiology of TC still remains uncertain.<sup>4</sup>

Three most prominent theories of the pathogenesis of the TC lesions are as follows:

- Repetitive trauma leads to reparative dysfunction.
- Periarticular forces dissecting histiocytic aggregates that initiate osteoclastic activity.
- Hemorrhage from microtrauma causes an exaggerated reparative response.<sup>13</sup>

### Classification

- Primary normo-phosphatemic TC: Normal calcium and phosphate levels are the hallmark of this condition. Usually presenting before the second decade of life in tropical or subtropical regions. Recent literature shows growing evidence of a familial basis for this type of pathology, involving mutations in the gene encoding for SAMD-9 protein.<sup>14</sup>

- Primary hyperphosphatemic TC: These patients present with normal calcium levels but abnormally increased phosphate levels. The usual presentation is during the first and second decades of life.<sup>15,16</sup> Genetic predisposition is a feature of this type of TC where hyperphosphatemia arises due to reduced urinary phosphate excretion caused by recessive mutations in GalNAc transferase three genes, *GALNT3*, and *KLOTHO*, that causes the inactivation of *FGF23*, a phosphaturic hormone.<sup>17-20</sup>
- Secondary TC: Most commonly seen in patients suffering from chronic renal failure.

## Differential Diagnosis for tumoral calcinosis

► **Table 1** shows that there are many causes of metabolic and dystrophic calcification.<sup>21</sup>

## Treatment Options

The treatment of any periarticular calcinosis depends largely on its underlying cause. Surgical excision of lesion is well

documented but not without the possibility of recurrence. This may be due to inadequate removal of the tumor tissue.

With regard to TC surgical excision is combined with phosphate deprivation (using aluminum hydroxide) in conjunction with acetazolamide to synergistically with phosphate restricted diet (dairy products, nuts, beans, grain products, etc.) lower the phosphate levels in the body and has proven to be an effective therapy.<sup>22</sup> Low-dose oral anticoagulant therapy has also been utilized to prevent and reverse many subcutaneous lesions. However recently, modified fine-needle aspiration performed with ultrasonographic guidance using a double small-gauge needle technique relieved pain and disability.<sup>23</sup>

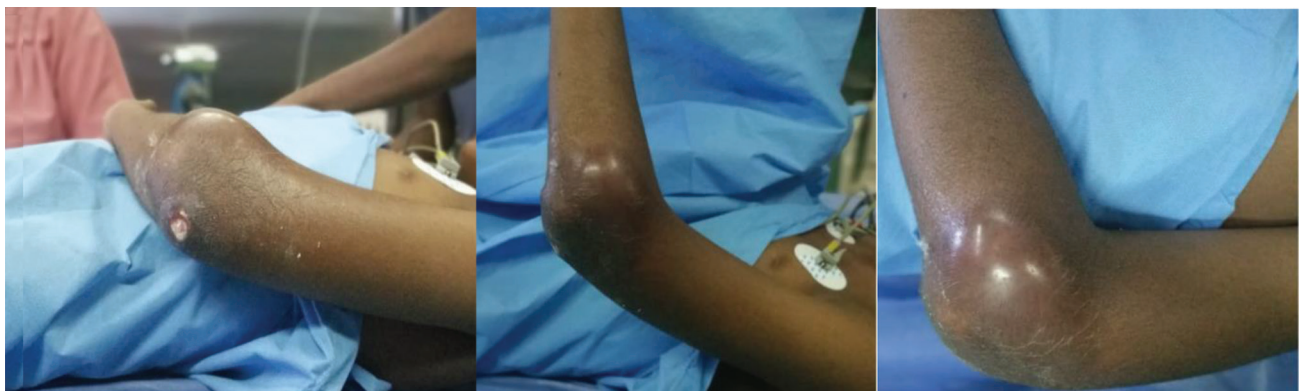In accordance with previous literature, the treatment protocol for TC should be based entirely on the symptomatology of the patient. If there is severe joint disability or associated complications such as nerve compression, infection, or deformity, the patient may undergo a surgical excision followed by medical treatment with condition phosphate deprivation agents mentioned earlier.<sup>24</sup> On the other hand, patients with underlying secondary or tertiary hyperparathyroidism must undergo subtotal or total parathyroidectomy if the medical treatment fails.<sup>25</sup>

**Table 1** Differential Diagnosis for tumoral calcinosis

Causes of dystrophic calcification	Causes of metabolic calcification
Degenerative diseases <ul style="list-style-type: none"> <li>• Calcium pyrophosphate deposition disease</li> <li>• Calcific tendonitis</li> <li>• Calcific bursitis</li> <li>• Myositis ossificans</li> </ul>	Hyperphosphatemia <ul style="list-style-type: none"> <li>• Chronic renal failure</li> </ul>
Connective tissue diseases <ul style="list-style-type: none"> <li>• Systemic lupus erythematosus</li> <li>• Progressive systemic sclerosis</li> <li>• Dermatomyositis</li> <li>• Polymyositis</li> </ul>	Hypercalcemia <ul style="list-style-type: none"> <li>• Hypervitaminosis D</li> <li>• Sarcoidosis</li> <li>• Primary hyperparathyroidism</li> <li>• Milk alkali syndrome</li> </ul>
Neoplastic diseases <ul style="list-style-type: none"> <li>• Osteosarcoma</li> <li>• Chondrosarcoma</li> <li>• Synovial sarcoma</li> <li>• Metaplasia</li> </ul>	Hyperuricemia <ul style="list-style-type: none"> <li>• Tophaceous gout</li> </ul>

## Case Report

A 12-year-old right hand dominant boy presented to our outpatient department with history of multiple and progressive masses in the left elbow over a period of 6 months. The lesion was painful and associated with a yellow discharge for a period of 10 days. He did report two episodes of low-grade fever. General examination revealed a well-nourished and healthy child with restricted movement in the left elbow on examining the left elbow a tender, solitary 4 × 3 cm elliptical lesion was noted over the posterolateral aspect. The skin over the elbow appeared shiny with a local rise of temperature. The swellings were firm, nonfluctuant, nodular in consistency with a multiple overlying punctums of which some had ulcerated with a purulent discharge. The patient had no regional lymphadenopathy and completely restricted range of movement. The right elbow also demonstrated a region of thickened skin of 2 × 3 cm with ill-defined margins. However, no local skin changes and no restriction of movement (► **Fig. 1**).



**Fig. 1** Left elbow of the patient.

Preoperative photos showing calcified mass with collection mainly at posterolateral aspect of elbow.

Preoperative anteroposterior (AP) and lateral radiographs of the left elbow showing multiple oval-shaped calcified masses mainly at the posterolateral region of elbow (►Fig. 2).

Preoperative radiograph of right elbow AP and lateral view showing calcified mass over elbow but less benign compare with left elbow (►Fig. 3).

His blood investigations were all within normal limits including serum uric acid level (5.4 mg/dL) except for a slightly elevated serum phosphate. Ultrasonographic imaging of thyroid and parathyroid glands were unremarkable.

## Management

While examination, we had noted firm mass with thickened skin of right elbow but asymptomatic. Hence, we operated only on left elbow with debridement of narcotic and unhealthy tissue and excision of mass which was sent

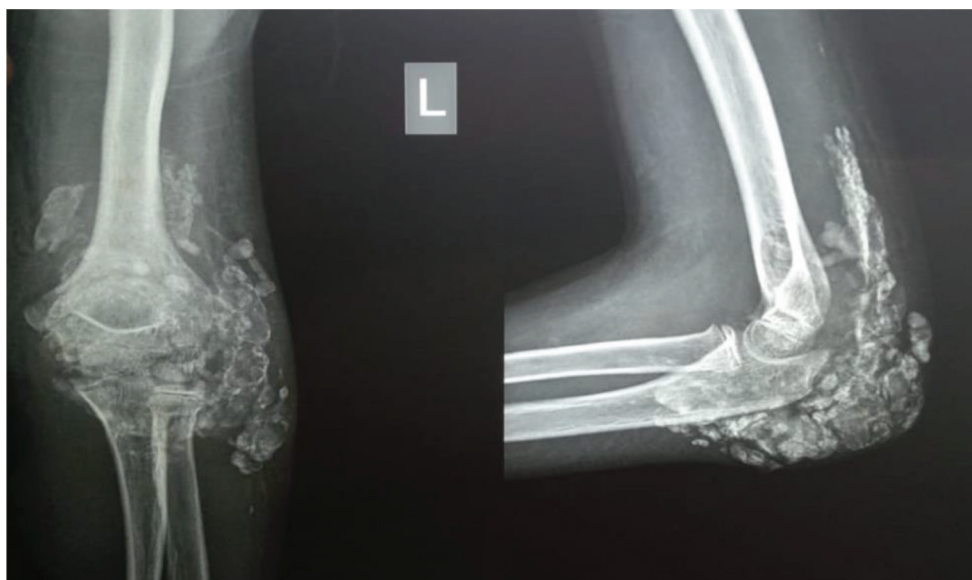
to biopsy to conform our diagnosis. Wound was closed by primary suturing and immobilised limb till suture removal followed by rehabilitation with active and passive mobilization of elbow.

Surgical excision in the left elbow was performed using a posterior approach. The excised material consisted multiple lobulated yellow colored masses within a well-defined capsule. Cut surfaces of the lobules were yellowish white with chalky granular deposits (►Fig. 4).

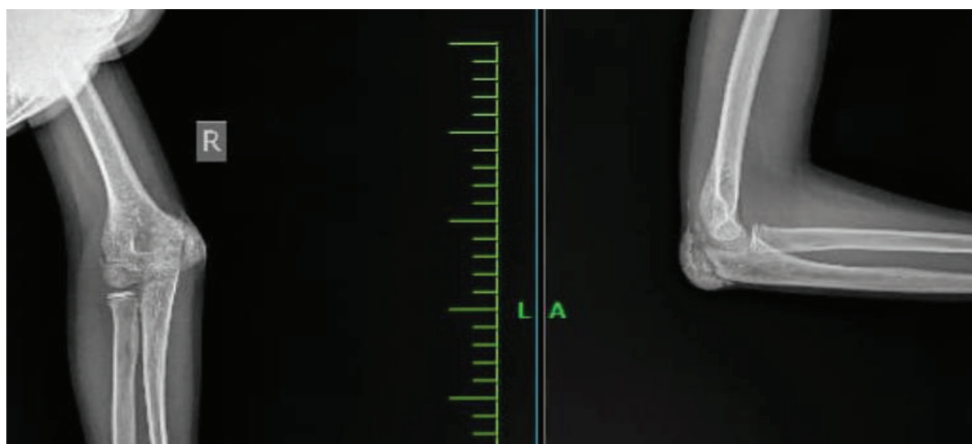Image showing: (A) yellow chocky type material from subcutaneous layer, (B) mass extending up to triceps muscle, (C) mass not communicating to deep layers, and (D) image showing specimen of varies size.

Postoperative X-ray after excision of mass confirmed the complete removal of the calcified tissue (►Fig. 5).

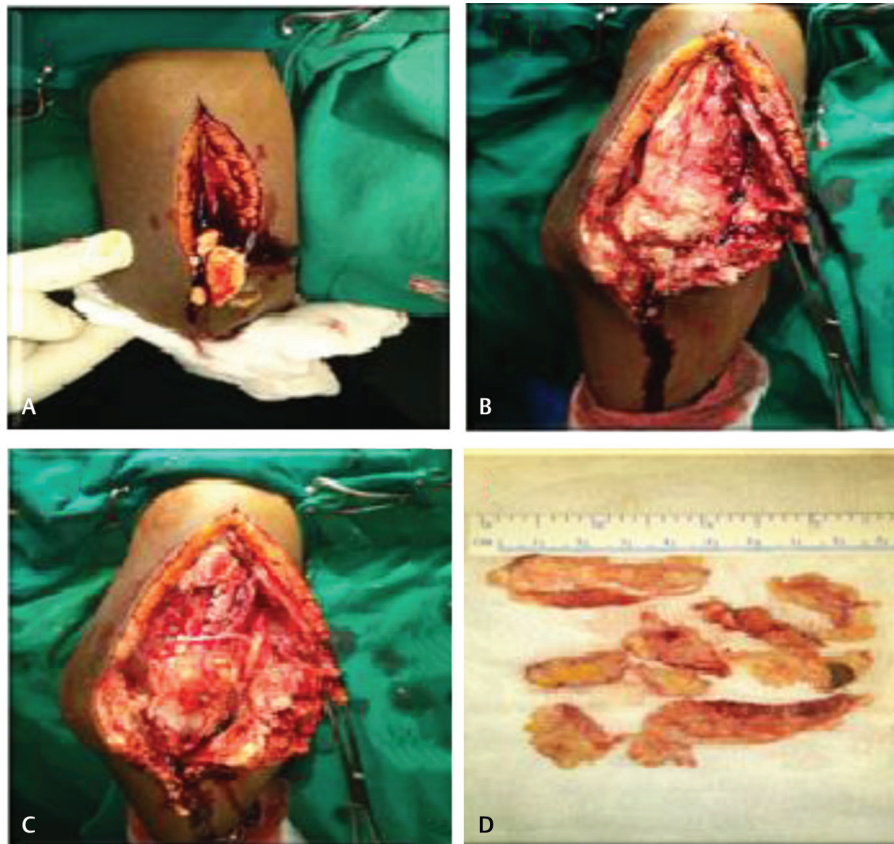
Microscopy revealed coarse calcific deposits with plasma cells and lymphocytes surrounded by fibrosis. These features were suggestive of TC. There were no features of malignant neoplastic cells within specimen (►Fig. 6).



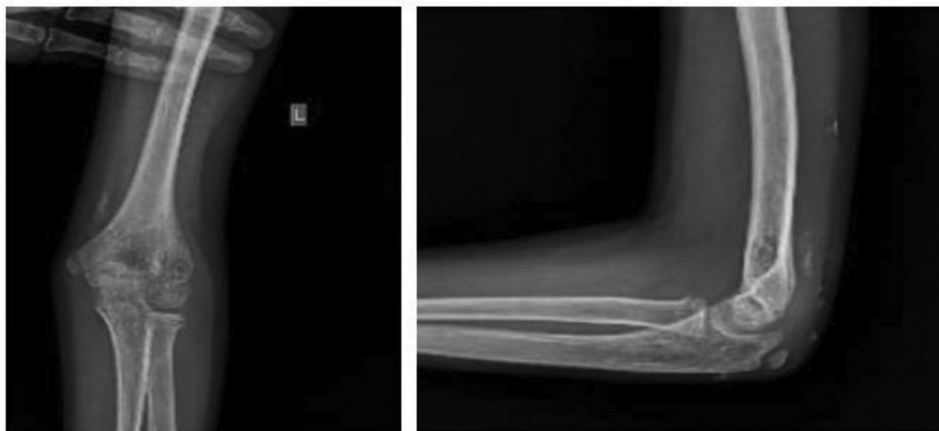
**Fig. 2** Preoperative radiograph of left elbow showing calcified mass over posterolateral region.



**Fig. 3** Preoperative radiograph of the right elbow showing small oval shape calcified mass over posteromedial region.



**Fig. 4** Surgical excision of mass showing lobulated mass within well defined capsule.



**Fig. 5** Postoperative radiograph of the left elbow shows complete removal of elbow.

### Postoperation and Rehabilitation

Elbow mobilization was started after wound healing. ►**Fig. 7** shows range of motion after 2 weeks of surgery.

### Follow-up and Outcomes

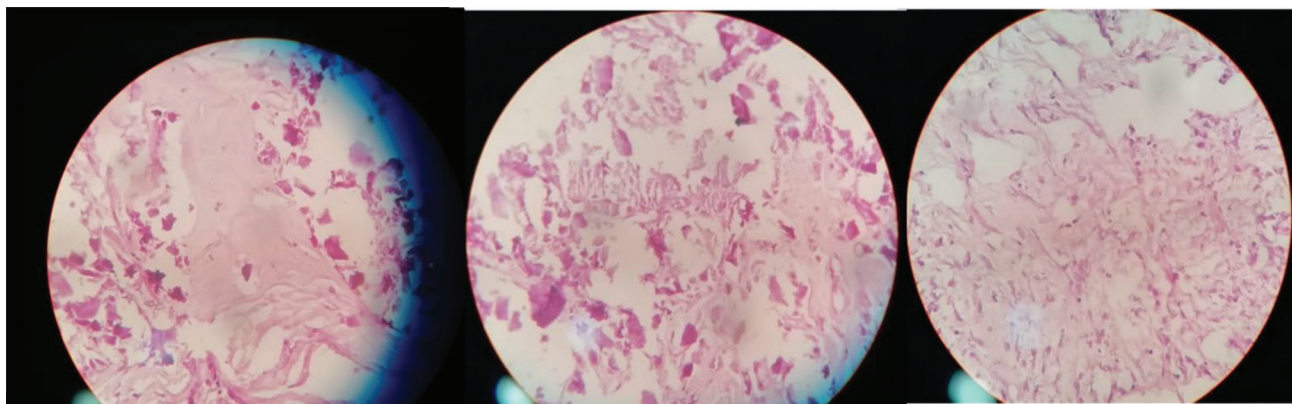
Clinical photograph demonstrating range of motion and postoperative radiographs of bilateral elbow joints 9 months after surgery showing no recurrence of mass or calcium deposition. The patient regained full range of movements in bilateral elbows (►**Fig. 8**).

### Discussion

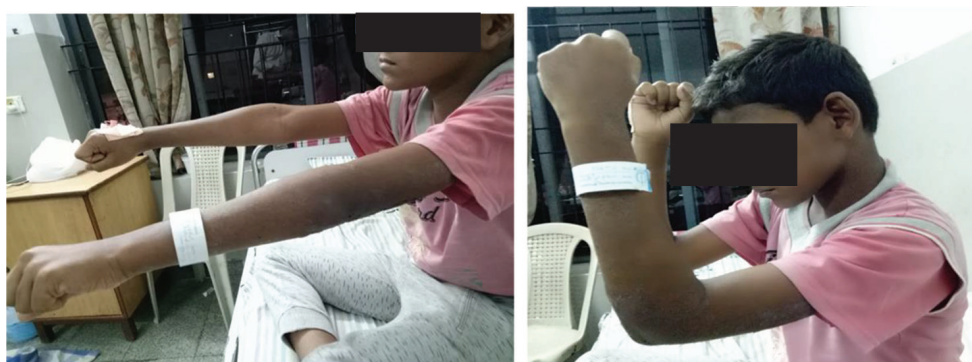TC is a rare and benign uncommon pathological condition in which calcified deposits of hydroxyapatite or amorphous calcium phosphate crystals are deposited in the periarticular connective tissue.<sup>26</sup> However, they are not true neoplasms as they do not possess of mitotic cells.<sup>4</sup> Despite many theories, the exact pathogenesis remains unknown as seen in our case which had no history of trauma to the elbow (►**Fig. 9**).

TC usually presents as a painless, firm swelling with, multiple masses but can become painful as a result of





**Fig. 6** Histopathology specimen of calcified tissue which shows that calcific deposition shows plasma cells with lymphocyte deposition surrounded by fibrosis.



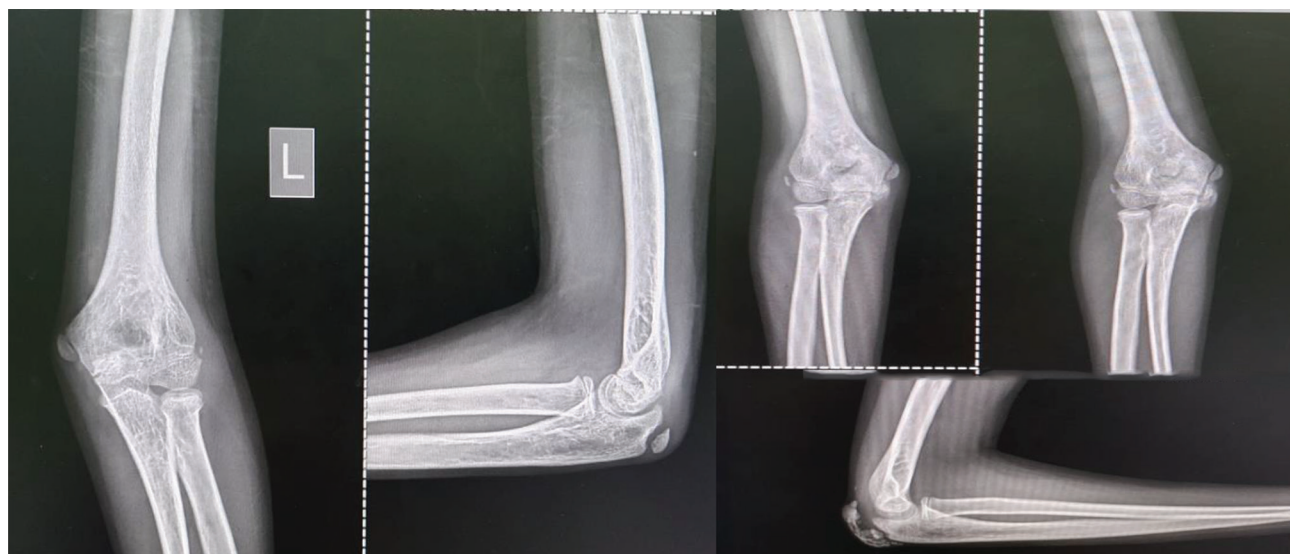**Fig. 7** Immediate postoperative image showing elbow range of motion that started after wound healing.



**Fig. 8** Follow-up image of full range of motion of elbow joint. No complaints of pain or swelling over joints was made.

ulceration.<sup>11</sup> In such situations, patients may present with signs of infection and discharge over the swelling site. Diagnosis can be tedious in view of various other similar presenting lesions that are difficult because there are many conditions with similar appearing lesions. Laboratory investigations in a case of TC are often nonconclusive, and only in cases of hyperphosphatemic TC, we ruled out gout since his uric acid was within normal limit.<sup>27</sup> Plain radiographs are often useful in diagnosis where multiple areas of well-circumscribed and nodular masses with fibrous septae are noted appearing as a “cobblestone” or “chicken-wire” appearance. A horizontal beam may show the “sedimentation sign” due to the mineral portion pooling dependently.<sup>28</sup>

The treatment of TC is governed by the site, size, type of the lesion, and relations of the lesion, as well as the symptoms of the patient. A medical line of management may be utilized when treating the primary variety and should be considered prior to surgical intervention. Medical management involves phosphate depletion with dietary restriction of phosphorus and phosphate binding chelating agents such as oral aluminum.<sup>29-31</sup> However, if the swelling is large in size causing significant disability to the involved joint and there are cutaneous complications such as ulceration surgery may be considered as it offers pain relief as restores normal joint function.<sup>32</sup> In the case of our patient, the swelling was large in size, causing significant loss in joint function along with



**Fig. 9** Postoperative radiograph of bilateral elbows that showed no evidence recurrence of mass.

skin ulceration and with signs of infection as the patient had febrile episodes. Therefore, we decided to take a surgical approach by excising the entire lesion from the left elbow followed by confirmation with biopsy. In the case of the right elbow, the patient did not report any loss in joint function or skin complications; therefore, we decided to treat him conservatively with phosphate diet restriction and assess the elbow on consecutive follow-ups.

Tumoral calcinosis though a rare condition should be considered a possible diagnosis in this age group and radiographic picture. As it is not a typical neoplasm or a bony tumor the decision to intervene is entirely based upon the patient's disability and complications as a result of the pathology. Post operatively our patient achieved excellent results with complete healing of the skin over the elbow joint and restoration of complete joint function. On subsequent follow ups we have been monitoring his right elbow and he continued to remain without significant loss of joint function and free of any associated complications.

#### Conflict of Interest

None declared.

#### References

- 1 Fitz-Henley M. Image and diagnosis: calcinosis cutis. *West Indian Med J* 2002;51:246–272
- 2 Dimitroulis G. Tumoral calcinosis of the articular disc of the temporomandibular joint: a rare entity. *J Oral Maxillofac Surg* 2004;62(12):1551–1553
- 3 McKee PH, Liomba NG, Hutt MS. Tumoral calcinosis: a pathological study of fifty-six cases. *Br J Dermatol* 1982;107(6):669–674
- 4 Ohashi K, Yamada T, Ishikawa T, Yamaguchi S, Nakajima H, Takagi M. Idiopathic tumoral calcinosis involving the cervical spine. *Skeletal Radiol* 1996;25(4):388–390
- 5 Viegas SF, Evans EB, Calhoun J, Goodwiller SE. Tumoral calcinosis: a case report and review of the literature. *J Hand Surg Am* 1985;10(5):744–748

- 6 Greenberg SB. Tumoral calcinosis in an infant. *Pediatr Radiol* 1990;20(3):206–207
- 7 McGuinness FE. Hyperphosphataemic tumoral calcinosis in Bedouin Arabs—clinical and radiological features. *Clin Radiol* 1995;50(4):259–264
- 8 McClatchie S, Bremner AD. Tumoral calcinosis: an unrecognized disease. *BMJ* 1969;1(5637):153–155
- 9 Inclan A, Leon P, Camejo MG. Tumoral calcinosis. *J Am Med Assoc* 1943;121(7):490–495
- 10 Rambani R, Dhillon MS, Aggarwal R. Tumoral calcinosis with unusual presentation: a case report. *Acta Orthop Belg* 2003;69(4):368–372
- 11 Slavin G, Klenerman L, Darby A, Bansal S. Tumoral calcinosis in England. *BMJ* 1973;1(5846):147–149
- 12 Fathi I, Sakr M. Review of tumoral calcinosis: a rare clinico-pathological entity. *World J Clin Cases* 2014;2(9):409–414
- 13 Lufkin EG, Wilson DM, Smith LH, et al. Phosphorus excretion in tumoral calcinosis: response to parathyroid hormone and acetazolamide. *J Clin Endocrinol Metab* 1980;50(4):648–653
- 14 Durant DM, Riley LH II, Burger PC, McCarthy EF. Tumoral calcinosis of the spine: a study of 21 cases. *Spine* 2001;26(15):1673–1679
- 15 HersHKovitz D, Gross Y, Nahum S, et al. Functional characterization of SAMD9, a protein deficient in normophosphatemic familial tumoral calcinosis. *J Invest Dermatol* 2011;131(3):662–669
- 16 Topaz O, Shurman DL, Bergman R, et al. Mutations in GALNT3, encoding a protein involved in O-linked glycosylation, cause familial tumoral calcinosis. *Nat Genet* 2004;36(6):579–581
- 17 Benet-Pagès A, Orlik P, Strom TM, Lorenz-Depiereux B. An FGF23 missense mutation causes familial tumoral calcinosis with hyperphosphatemia. *Hum Mol Genet* 2005;14(3):385–390
- 18 Larsson T, Yu X, Davis SI, et al. A novel recessive mutation in fibroblast growth factor-23 causes familial tumoral calcinosis. *J Clin Endocrinol Metab* 2005;90(4):2424–2427
- 19 Ichikawa S, Imel EA, Kreiter ML, et al. A homozygous missense mutation in human KLOTHO causes severe tumoral calcinosis. *J Clin Invest* 2007;117(9):2684–2691
- 20 Slavin RE, Wen J, Kumar D, Evans EB. Familial tumoral calcinosis: a clinical, histopathologic, and ultrastructural study with an analysis of its calcifying process and pathogenesis. *Am J Surg Pathol* 1993;17(8):788–802
- 21 Olsen KM, Chew FS. Tumoral calcinosis: pearls, polemics, and alternative possibilities. *Radiographics* 2006;26(3):871–885

- 22 Yamaguchi T, Sugimoto T, Imai Y, Fukase M, Fujita T, Chihara K. Successful treatment of hyperphosphatemic tumoral calcinosis with long-term acetazolamide. *Bone* 1995;16(4, Suppl):247S–250S
- 23 Aina R, Cardinal E, Bureau NJ, Aubin B, Brassard P. Calcific shoulder tendinitis: treatment with modified US-guided fine-needle technique. *Radiology* 2001;221(2):455–461
- 24 Kumaran MS, Bhadada S, Bhansali A, Shriram M, Kumar B. Young boy with multiple periarticular swellings and discharging sinuses: tumoral calcinosis. *Indian J Pediatr* 2004;71(12):e74–e76
- 25 Möckel G, Buttgereit F, Labs K, Perka C. Tumoral calcinosis revisited: pathophysiology and treatment. *Rheumatol Int* 2005;25(1):55–59
- 26 Emery KH, Fletcher BD. The soft tissues. In: Kuhn JP, Slovis TL, eds. *Caffey's Pediatric Diagnostic Imaging*. 10th edition. Philadelphia, PA: Mosby; 2004:2009–11
- 27 Murray RO, Jacobson HG, Stoker DJ. *Radiology of Skeletal Disorders*. 3rd edition. London: Churchill Livingstone; 1990: 822–823
- 28 Martinez S, Vogler JB II, Harrelson JM, Lyles KW. Imaging of tumoral calcinosis: new observations. *Radiology* 1990;174(1):215–222
- 29 Mozaffarian G, Lafferty FW, Pearson OH. Treatment of tumoral calcinosis with phosphorus deprivation. *Ann Intern Med* 1972;77(5):741–745
- 30 Kirk TS, Simon MA. Tumoral calcinosis. Report of a case with successful medical management. *J Bone Joint Surg Am* 1981;63(7):1167–1169
- 31 Davies M, Clements MR, Mawer EB, Freemont AJ. Tumoral calcinosis: clinical and metabolic response to phosphorus deprivation. *QJM* 1987;63(3):493–503
- 32 Farzan M, Farhoud AR. Tumoral calcinosis: what is the treatment? Report of two cases of different types and review of the literature. *Am J Orthop* 2011;40(9):E170–E176