

# Femoroacetabular Impingement and Acetabular Labral Tears – Part 3: Surgical Treatment\*

## *Impacto femoroacetabular e lesão do lábio acetabular – Parte 3: Tratamento cirúrgico*

Marcelo C. Queiroz<sup>1</sup>  Walter Ricioli Junior<sup>1</sup>  Leandro Ejnisman<sup>2</sup>   
Henrique Melo de Campos Gurgel<sup>2</sup>  Helder de Souza Miyahara<sup>2</sup>  Giancarlo Cavalli Polesello<sup>1</sup> 

<sup>1</sup> Faculty of Medical Sciences, Santa Casa de Misericórdia de São Paulo (FCMSCSP), São Paulo, SP, Brazil

<sup>2</sup> Instituto de Ortopedia e Traumatologia, Hospital das Clínicas, Faculdade de Medicina, Universidade de São Paulo (IOT-HCFMUSP), São Paulo, SP, Brazil

Address for correspondence: Marcelo Cavalheiro de Queiroz, MD, MSc, Department of Orthopedics and Traumatology, Faculty of Medical Sciences, Santa Casa de Misericórdia de São Paulo (FCMSCSP), Rua Dr. Cesário Motta Junior, 112, Bairro Vila Buarque, São Paulo, SP, 01221-020, Brazil (e-mail: macqueiroz@yahoo.com).

Rev Bras Ortop 2020;55(5):532–536.

### Abstract

#### Keywords

- ▶ hip
- ▶ femoroacetabular impingement/therapy
- ▶ femoroacetabular impingement/surgery
- ▶ arthroscopy

In the last 15 years, the diagnosis of femoroacetabular impingement has become more frequent; with the advance of surgical indications, different techniques have been developed. Surgical treatment includes a wide variety of options, namely: periacetabular osteotomy, surgical hip dislocation, arthroscopy with osteochondroplasty via a small incision, modified anterior approach technique and exclusively arthroscopic technique. The type of approach should be chosen according to the complexity of the morphology of the femoroacetabular impingement and to the surgeon's training. The techniques most used today are arthroscopy, surgical dislocation of the hip, and periacetabular osteotomy. The present article aims to describe the current main surgical techniques used to treat femoroacetabular impingement, their indications, advantages and disadvantages, complications and clinical results.

### Resumo

#### Palavras-chave

- ▶ quadril
- ▶ impacto femoroacetabular/terapia
- ▶ impacto femoroacetabular/cirurgia
- ▶ artroscopia

Nos últimos 15 anos, o diagnóstico do impacto femoroacetabular tem se tornado cada vez mais frequente; com o avanço do entendimento de quais pacientes potencialmente se beneficiariam do tratamento cirúrgico, diferentes técnicas foram desenvolvidas. O tratamento cirúrgico inclui grande variedade de opções, sendo elas: osteotomia periacetabular, técnica de luxação cirúrgica do quadril, artroscopia com osteocondroplastia via pequena incisão, técnica via anterior modificada, e técnica exclusivamente artroscópica. O tipo de abordagem deve ser escolhido de acordo com a complexidade da morfologia do impacto femoroacetabular e o treinamento do cirurgião. As técnicas mais utilizadas atualmente são a artroscopia, a luxação cirúrgica do quadril e a osteotomia periacetabular. O presente artigo busca descrever as principais técnicas cirúrgicas utilizadas para o tratamento do impacto femoroacetabular, suas indicações, vantagens e desvantagens, complicações e resultados clínicos.

\* Study carried out in the Hip Group of the Department of Orthopedics and Traumatology of the Faculty of Medical Sciences, Santa Casa de Misericórdia de São Paulo (FCMSCSP), São Paulo, SP, Brazil.

## Introduction

In the last 15 years, the diagnosis of femoroacetabular impingement (FAI) has become increasingly frequent; with the advance of the understanding of which patients would potentially benefit from surgical treatment, different techniques have been developed. Surgical treatment includes a wide variety of options: periacetabular osteotomy,<sup>1</sup> technique of surgical dislocation of the hip,<sup>2</sup> arthroscopy with osteochondroplasty via small incision,<sup>3</sup> modified anterior approach technique<sup>4</sup> and exclusively arthroscopic technique.<sup>5</sup> The type of approach should be chosen according to the complexity of the FAI morphology and to the surgeon's training.

The most used techniques currently are arthroscopy, surgical hip dislocation, and periacetabular osteotomy.

The technique initially developed was the surgical dislocation of the hip,<sup>2</sup> which allows almost circumferential access to the femoral neck, and its greatest advantage is the possibility of performing associated procedures such as trochanteric advancement, relative stretching of the cervix, and femoral osteotomies. It requires a wide route, longer time of load protection and movements due to osteotomy and, although infrequent, may present with trochanteric pseudoarthrosis and need for removal of the screws.

Hip arthroscopy has had a major development in the last 10 years<sup>5</sup> and has replaced controlled dislocation as the procedure of choice for most cases. It is extremely important to accurately diagnose the deformity to make sure that it is possible to be treated arthroscopically. Anterolateral pathologies, which are the most common ones, are addressed extremely effectively by video.

Periacetabular osteotomy,<sup>1</sup> although its precise indication is for the treatment of acetabular dysplasia, can be used in the treatment of acetabular retroversion. In this type of situation, the osteotomy is corrected in reverse, that is, performed anteverion and extension of the acetabulum.

Regardless of the technique, the principles of treatment are the same: correction of bone deformities and treatment of chondrolabral lesions.

## Surgical Hip Dislocation

Surgical hip dislocation was described by Ganz et al. in 2001<sup>2</sup> after studies on femoral head vascularization<sup>6</sup> and the finding that it would be possible to perform femoral head dislocation, keeping the medial femoral circumflex artery intact. For this, a digastric trochanteric osteotomy, an anterior capsulotomy and anterior hip dislocation are performed. For the preservation of the vascularization of the head, the key is an exchange-level osteotomy at the correct level, that is, superior to the posterior edge of the middle gluteus to the lower edge of the vastus lateralis. Osteotomy can be performed in an incomplete anterior manner and with a step<sup>7</sup> for greater postreduction stability and greater congruence of the fragments. Screws of large or small fragments can be used for fixation of osteotomy. (→ **Figure 1**)

This route has the advantage of allowing almost circumferential access to the femoral neck and performing associated procedures such as trochanteric advancement, relative

stretching of the neck, and femoral osteotomies. As disadvantages, it requires a wide pathway, longer load protection time and active abduction due to trochanteric osteotomy, and, although infrequent, it may present with pseudoarthrosis, osteonecrosis of the femoral head, heterotopic ossification, and need for removal of the screws.<sup>8</sup>

The clinical results described for the treatment of FAI with surgical dislocation are encouraging,<sup>9</sup> with good results reported with a minimum follow-up of 5<sup>10,11</sup> and 10 years.<sup>12</sup>

## Hip Arthroscopy

Arthroscopy for the treatment of FAI is recent.<sup>5,13–15</sup> Important advances in arthroscopic technique and materials have allowed deformities to be addressed in a less invasive manner. Arthroscopic treatment of FAI can be performed by osteoplasty of the proximal femur, resection of acetabular overcover, and repair/refixation of acetabular lip or debridement, in cases in which this is not possible.

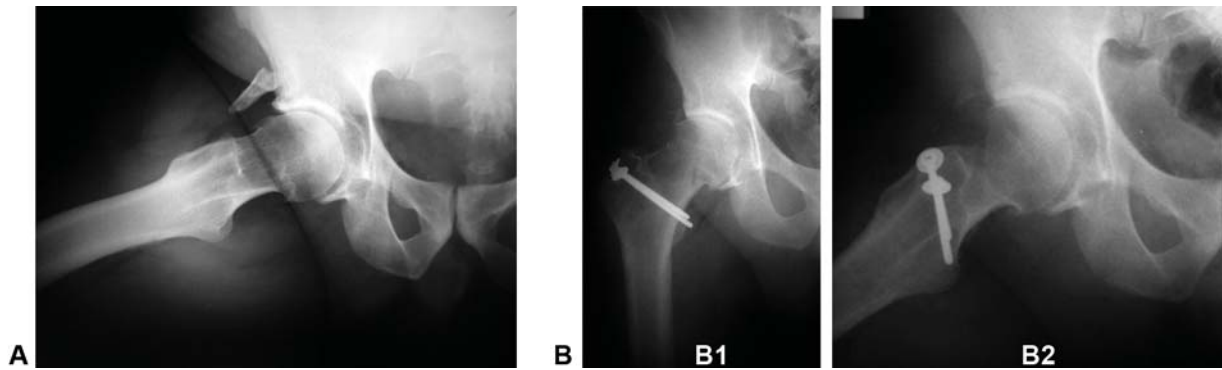
In the arthroscopic technique, the correction of bone deformities is done with the aid of bone shavers. This resection should be meticulous (→ **Figure 2**), as the major cause of hip revision arthroscopies is insufficient resections of the FAI deformity that lead to persistent hip clamping.<sup>16–18</sup> The surgeon uses direct visualization, radiology and therapeutic testing as a guide for intraoperative resection. In this test, the patient's limb is loose from traction, and the hip is placed in flexion and internal rotation while the surgeon directly observes if there is any residual impact. If any bone conflict can still be observed in any area, it must be corrected.

The arthroscopic anatomy has been widely studied, establishing arthroscopic portals that are well defined, safe, and with anatomical technique in relation to the preservation of femoral neck vascularization.<sup>1,9,20</sup>

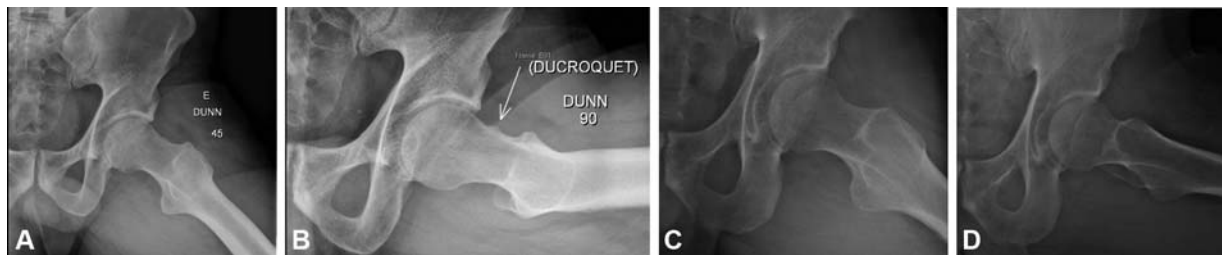
Lip repair can also be performed arthroscopically. Initially, acetabular labral lesions were debrided, but later studies demonstrated superior clinical results with lip repair.<sup>21</sup> Labral lesions are repaired by means of absorbable anchors. Generally, multiple anchors are required for proper repair, depending on the size of the lesion. In complex lesions of the acetabular lip, in which the labial tissue is not healthy for repair, it is recommended reconstruction of the acetabular lip, which can be performed with autologous graft of the iliotibial band, femoral head ligament or allografts.<sup>22,23</sup>

The orthopedist should be familiar with arthroscopic anatomy, as there may be difficulty in guiding the location and regarding the required amount of bone resection. Insufficient bone resection results in residual impact and is an important reason for reoperations.<sup>17,18</sup> On the other hand, excessive resection is associated with risk of femoral neck fracture and instability.<sup>24</sup> Anatomical studies have proven that both open and arthroscopic cervical osteoplasties, when performed by trained surgeons, show equal precision.<sup>25,26</sup> and clinical studies have demonstrated the efficacy of restoration of femoral offset by arthroscopic route.<sup>27,28</sup> Thus, the arthroscopic treatment technique of FAI is feasible and reproducible.

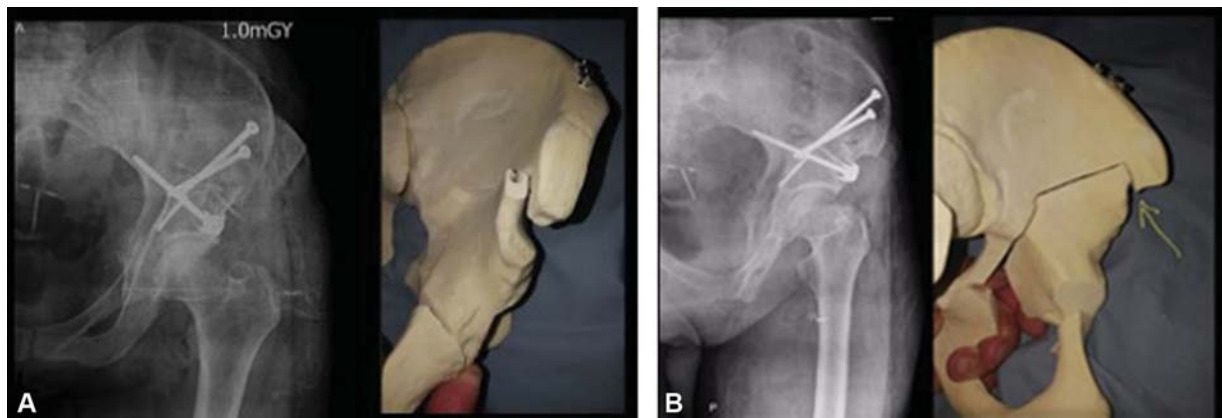
The results of hip arthroscopy for FAI treatment and labral injury are promising, with excellent satisfaction rates, improvement of clinical scores, and high rates of return to sport. A



**Fig. 1** Radiographic image of surgical treatment of femoroacetabular impingement by the technique of surgical hip dislocation for resection of CAM type deformity. (A) radiography hip right preoperative profile. (B) AP hip radiograph (B1) and postoperative profile (B2) with screws fixing trochanteric osteotomy. Source: Archive of the hip group of the Faculty of Medical Sciences of Santa Casa de São Paulo.



**Fig. 2** Images of surgical treatment of femoroacetabular impingement by arthroscopic technique. (A and B) Preoperative radiographic image of CAM deformity. (C and D) Arthroscopic postresection image of CAM-type deformity. Source: Personal archive (MCQ).



**Fig. 3** Postoperative images of surgical treatment of femoroacetabular impingement by reverse periacetabular osteotomy technique. (A) Left postoperative AP incidence radiographic image of the left hip. On the right plastic model images with simulation of reverse periacetabular osteotomy. (B): Alar postoperative radiographic image of the left hip. On the right plastic model images with simulation of reverse periacetabular osteotomy. Yellow arrow indicating cranial region of the fragment that may need to be resected to perform the correction. Source: Images courtesy of Dr. Javier Perez.

recent systematic review evaluated predictors of good prognosis for patients undergoing arthroscopy.<sup>29</sup> A total of 39 studies with more than 9,000 patients were included. Predictors of good prognosis were considered: young patients, male gender, lower body mass index (BMI) (< 24.5), Tonnis classification 0, and pain relief after intra-articular anesthetic infiltration. Predictors of poor prognosis were considered: age greater than 45 years, female gender, high BMI, arthritic alterations, decreased joint space (< 2 mm), chondral defects, increased lateral center-edge (CE) angle, and patients undergoing labral debridement. Another systematic review evaluated the rate of return to sport after hip arthroscopy for FAI.<sup>30</sup> Thirty-one

studies with a total of 19,111 patients were evaluated. The rate of return to sports was 87.7%. A correlation was found between shorter time of preoperative symptoms and a higher rate of return to sports. In comparison with physiotherapy treatment, hip arthroscopy presents better results,<sup>31–33</sup> fewer complications, although with the same clinical results as surgical dislocation,<sup>9</sup> it provides a higher probability of returning to sports activity and earlier than surgical dislocation.<sup>34,35</sup>

The incidence of complications in hip arthroscopy is about 1.5%,<sup>36</sup> with the most common complication being reversible nerve dysfunction. The most common cause of reoperation after arthroscopy for FAI is insufficient bone resection and

persistence of conflict between the acetabulum and femoral head/neck.<sup>17,18</sup> Other complications are also related to the surgical technique, such as cartilage deformation (scuffing) by instrumental abrasion, penetration of the acetabular lip, and joint penetration by the material for fixation of the acetabular lip (anchors). The positioning of the patient on the traction table and the traction time are paramount to avoid neurological and cutaneous lesions, and the maximum recommended traction time is 2 hours.<sup>37</sup> Cases of femoral neck fracture are described in the literature, and resection is considered safe up to the limit of 30% of the femoral neck diameter.<sup>24</sup>

### Periacetabular Osteotomy Reverse

Periacetabular osteotomy (PAO) was described in 1988 for the treatment of acetabular hip dysplasia.<sup>1</sup> Acetabular retroversion is one of the causes of pincer impact and can be corrected through a reverse acetabular osteotomy, that is, performed anteversion and extension of the acetabulum. The acetabular retroversion is different from a previous focal overcover. In retroversion beyond the crossing signal, the signal of the back wall is positive. Other possible indications of reverse PAO are severe acetabular protrusions, in which the angle of the ceiling is negative, and a resection of the acetabular rim could result in a dysplastic acetabulum.

The surgical technique is the same as the original PAO, except for the correction of the fragment, which must be anticipated (internal rotation) and extended. These corrections tend to lateralize and distalize the center of rotation, and eventually it may be necessary to remove wedges from the regions of the corrections to allow the necessary rotation. The most common correction is to remove a wedge from the upper ilium to osteotomy and shorten the stable part of the osteotomy of the pubic branch. Fragment rotation is usually more difficult. The optimal correction is obtained with the angle of the ceiling between 1 and 10 degrees, CE angle from 25 to 30 degrees, correction of the crossing signal and the signal of the back wall. (– **Figure 3**)

Reverse PAO results for the treatment of acetabular retroversion are limited. A series of 29 hips showed good and excellent results in 26 hips (89% of cases) with an average follow-up of 30 months.<sup>38</sup> Another series with a mean follow-up of 5 years, showed an improvement in the average Harris hip score from 58 to 93, and the need for reoperation in 13% of the cases.<sup>39</sup>

Complications are similar to those already described for conventional PAO, hematoma, infection, paralysis or nerve injury, heterotopic ossification, and need for implant removal.<sup>40</sup>

### Final Considerations

The type of approach should be chosen according to the complexity of the morphology of the FAI and the training of the surgeon. The most used techniques currently are arthroscopy, hip surgical dislocation, and reverse PAO, each with its indications, advantages and disadvantages, complications, and clinical results.

### Conflict of Interests

The authors declare that there is no conflict of interests.

### References

- Ganz R, Klaue K, Vinh TS, Mast JW. A new periacetabular osteotomy for the treatment of hip dysplasias. Technique and preliminary results. *Clin Orthop Relat Res* 1988;(232):26–36
- Ganz R, Gill TJ, Gautier E, Ganz K, Krügel N, Berlemann U. Surgical dislocation of the adult hip a technique with full access to the femoral head and acetabulum without the risk of avascular necrosis. *J Bone Joint Surg Br* 2001;83(08):1119–1124
- Clohisey JC, Zebala LP, Nepple JJ, Pashos G. Combined hip arthroscopy and limited open osteochondroplasty for anterior femoroacetabular impingement. *J Bone Joint Surg Am* 2010;92(08):1697–1706
- Ribas M, Marín-Peña OR, Regenbrecht B, De La Torre B, Vilarrubias JM. Hip osteoplasty by an anterior minimally invasive approach for active patients with femoroacetabular impingement. *Hip Int* 2007;17(02):91–98
- Philippon MJ, Schenker ML. Arthroscopy for the treatment of femoroacetabular impingement in the athlete. *Clin Sports Med* 2006;25(02):299–308, ix
- Gautier E, Ganz K, Krügel N, Gill T, Ganz R. Anatomy of the medial femoral circumflex artery and its surgical implications. *J Bone Joint Surg Br* 2000;82(05):679–683
- Bastian JD, Wolf AT, Wyss TF, Nötzli HP. Stepped osteotomy of the trochanter for stable, anatomic refixation. *Clin Orthop Relat Res* 2009;467(03):732–738
- Sink EL, Beaulé PE, Sucato D, et al. Multicenter study of complications following surgical dislocation of the hip. *J Bone Joint Surg Am* 2011;93(12):1132–1136
- Nwachukwu BU, Rebolledo BJ, McCormick F, Rosas S, Harris JD, Kelly BT. Arthroscopic Versus Open Treatment of Femoroacetabular Impingement: A Systematic Review of Medium- to Long-Term Outcomes. *Am J Sports Med* 2016;44(04):1062–1068
- Stappacher SD, Huebner C, Schwab JM, Tannast M, Siebenrock KA. Surgical hip dislocation for treatment of femoroacetabular impingement: factors predicting 5-year survivorship. *Clin Orthop Relat Res* 2014;472(01):337–348
- Polesello GC, Lima FR, Guimaraes RP, Ricioli W, Queiroz MC. Arthroscopic treatment of femoroacetabular impingement: minimum five-year follow-up. *Hip Int* 2014;24(04):381–386
- Stappacher SD, Anwander H, Zurmühle CA, Tannast M, Siebenrock KA. Eighty percent of patients with surgical hip dislocation for femoroacetabular impingement have a good clinical result without osteoarthritis progression at 10 years. *Clin Orthop Relat Res* 2015;473(04):1333–1341
- Byrd JW, Jones KS. Arthroscopic femoroplasty in the management of cam-type femoroacetabular impingement. *Clin Orthop Relat Res* 2009;467(03):739–746
- Bardakos NV, Vasconcelos JC, Villar RN. Early outcome of hip arthroscopy for femoroacetabular impingement: the role of femoral osteoplasty in symptomatic improvement. *J Bone Joint Surg Br* 2008;90(12):1570–1575
- Polesello GC, Queiroz MC, Ono NK, Honda EK, Guimarães RP, Junior WR. Arthroscopic Treatment of Femoroacetabular Impingement. *Rev Bras Ortop* 2015;44(03):230–238
- Bogunovic L, Gottlieb M, Pashos G, Baca G, Clohisey JC. Why do hip arthroscopy procedures fail? *Clin Orthop Relat Res* 2013;471(08):2523–2529
- Heyworth BE, Shindle MK, Voos JE, Rudzki JR, Kelly BT. Radiologic and intraoperative findings in revision hip arthroscopy. *Arthroscopy* 2007;23(12):1295–1302
- Philippon MJ, Schenker ML, Briggs KK, Kuppersmith DA, Maxwell RB, Stubbs AJ. Revision hip arthroscopy. *Am J Sports Med* 2007;35(11):1918–1921

- 19 Byrd JW, Pappas JN, Pedley MJ. Hip arthroscopy: an anatomic study of portal placement and relationship to the extra-articular structures. *Arthroscopy* 1995;11(04):418–423
- 20 Robertson WJ, Kelly BT. The safe zone for hip arthroscopy: a cadaveric assessment of central, peripheral, and lateral compartment portal placement. *Arthroscopy* 2008;24(09):1019–1026
- 21 Riff AJ, Kunze KN, Movassaghi K, et al. Systematic Review of Hip Arthroscopy for Femoroacetabular Impingement: The Importance of Labral Repair and Capsular Closure. *Arthroscopy* 2019;35(02):646–656.e3
- 22 Atzmon R, Radparvar JR, Sharfman ZT, Dallich AA, Amar E, Rath E. Graft choices for acetabular labral reconstruction. *J Hip Preserv Surg* 2018;5(04):329–338
- 23 Ejnisman L, Philippon MJ, Lertwanich P. Acetabular labral tears: diagnosis, repair, and a method for labral reconstruction. *Clin Sports Med* 2011;30(02):317–329
- 24 Mardones RM, Gonzalez C, Chen Q, Zobitz M, Kaufman KR, Trousdale RT. Surgical treatment of femoroacetabular impingement: evaluation of the effect of the size of the resection. Surgical technique. *J Bone Joint Surg Am* 2006;88(Suppl 1 Pt 1):84–91
- 25 Sussmann PS, Ranawat AS, Lipman J, Lorich DG, Padgett DE, Kelly BT. Arthroscopic versus open osteoplasty of the head-neck junction: a cadaveric investigation. *Arthroscopy* 2007;23(12):1257–1264
- 26 Mardones R, Lara J, Donndorff A, et al. Surgical correction of “cam-type” femoroacetabular impingement: a cadaveric comparison of open versus arthroscopic debridement. *Arthroscopy* 2009;25(02):175–182
- 27 Bedi A, Zaltz I, De La Torre K, Kelly BT. Radiographic comparison of surgical hip dislocation and hip arthroscopy for treatment of cam deformity in femoroacetabular impingement. *Am J Sports Med* 2011;39(Suppl):20S–28S
- 28 Domb BG, Stake CE, Botser IB, Jackson TJ. Surgical dislocation of the hip versus arthroscopic treatment of femoroacetabular impingement: a prospective matched-pair study with average 2-year follow-up. *Arthroscopy* 2013;29(09):1506–1513
- 29 Sogbein OA, Shah A, Kay J, et al. Predictors of Outcomes After Hip Arthroscopic Surgery for Femoroacetabular Impingement: A Systematic Review. *Orthop J Sports Med* 2019;7(06):2325967119848982
- 30 Minkara AA, Westermann RW, Rosneck J, Lynch TS. Systematic Review and Meta-analysis of Outcomes After Hip Arthroscopy in Femoroacetabular Impingement. *Am J Sports Med* 2019;47(02):488–500
- 31 Dwyer T, Whelan D, Shah PS, Ajrawat P, Hoit G, Chahal J. Operative Versus Nonoperative Treatment of Femoroacetabular Impingement Syndrome: A Meta-analysis of Short-Term Outcomes. *Arthroscopy* 2020;36(01):263–273
- 32 Palmer AJR, Ayyar Gupta V, Fernquest S, et al. FAIT Study Group. Arthroscopic hip surgery compared with physiotherapy and activity modification for the treatment of symptomatic femoroacetabular impingement: multicentre randomised controlled trial. *BMJ* 2019;364:1185
- 33 Griffin DR, Dickenson EJ, Wall PDH, et al. FASHIoN Study Group. Hip arthroscopy versus best conservative care for the treatment of femoroacetabular impingement syndrome (UK FASHIoN): a multicentre randomised controlled trial. *Lancet* 2018;391(10136):2225–2235
- 34 Botser IB, Smith TW Jr, Nasser R, Domb BG. Open surgical dislocation versus arthroscopy for femoroacetabular impingement: a comparison of clinical outcomes. *Arthroscopy* 2011;27(02):270–278
- 35 O'Connor M, Minkara AA, Westermann RW, Rosneck J, Lynch TS. Return to Play After Hip Arthroscopy: A Systematic Review and Meta-analysis. *Am J Sports Med* 2018;46(11):2780–2788
- 36 Souza BG, Dani WS, Honda EK, et al. Do complications in hip arthroscopy change with experience? *Arthroscopy* 2010;26(08):1053–1057
- 37 Flierl MA, Stahel PF, Hak DJ, Morgan SJ, Smith WR. Traction table-related complications in orthopaedic surgery. *J Am Acad Orthop Surg* 2010;18(11):668–675
- 38 Siebenrock KA, Schoeniger R, Ganz R. Anterior femoro-acetabular impingement due to acetabular retroversion. Treatment with periacetabular osteotomy. *J Bone Joint Surg Am* 2003;85(02):278–286
- 39 Parry JA, Swann RP, Erickson JA, Peters CL, Trousdale RT, Sierra RJ. Midterm Outcomes of Reverse (Anteverting) Periacetabular Osteotomy in Patients With Hip Impingement Secondary to Acetabular Retroversion. *Am J Sports Med* 2016;44(03):672–676
- 40 Clohisy JC, Schutz AL, St John L, Schoenecker PL, Wright RW. Periacetabular osteotomy: a systematic literature review. *Clin Orthop Relat Res* 2009;467(08):2041–2052