



Rare Presentation of Schwannoma in the Ankle: A Case Report*

Apresentação rara de schwannoma no tornozelo: Um relato de caso

Prateek Kumar Gupta¹ Ashis Acharya¹ Shakti Swarup Panda¹

¹ Department of Sports Medicine, Sir Ganga Ram Hospital, New Delhi, India

Address for correspondence Prateek Kumar Gupta, MBBS, MS, MCh, FRCS, Department of Orthopedics, Sir Ganga Ram Hospital, Sarhadi Gandhi Marg, Old Rajinder Nagar, New Delhi, 110060, India (e-mail: sportsmedicinedelhi@yahoo.com).

Rev Bras Ortop 2021;56(1):118–120.

Abstract

Schwannomas are benign slow-growing tumors that constitute 8% of all soft-tissue tumors. The clinical signs and symptoms are often misinterpreted because of the low incidence, and these tumors are often misdiagnosed. A 39-year-old male patient presented with non-traumatic solitary swelling in the posteromedial aspect of the right ankle that gradually increased in size and was associated with pain. Clinically, the swelling was firm, non-fluctuant, and was not associated with sensorimotor impairment. Surgical excision of the swelling was performed without damaging the surrounding vessels and nerves. The histopathological examination of the excised tumor revealed a schwannoma.

Keywords

- ▶ ankle
- ▶ schwannoma
- ▶ rare location
- ▶ case report

Resumo

Schwannomas são tumores benignos de crescimento lento, e constituem 8% de todos os tumores de tecido mole. Os sinais clínicos e sintomas são muitas vezes mal interpretados por causa da baixa incidência, e, muitas vezes, esses tumores são mal diagnosticados. Um paciente do sexo masculino de 39 anos apresentou um inchaço solitário não traumático sobre o aspecto posteromedial do tornozelo direito, que aumentou gradualmente de tamanho e estava associado a dor. O inchaço era clinicamente firme, não flutuante, e não associado a qualquer comprometimento sensório-motor. A excisão cirúrgica do inchaço foi feita sem danificar os vasos e os nervos circundantes. O exame histopatológico do tumor excisado revelou schwannoma.

Palavras-chave

- ▶ tornozelo
- ▶ schwannoma
- ▶ localização rara
- ▶ relato de caso

Introduction

Schwannomas are benign slow-growing soft-tissue tumors that arise from Schwann cells of the peripheral nerve sheaths. They constitute 8% of all soft-tissue tumors.¹ Of all the reported

cases, between 12% and 19% are located in the upper extremity, and between 10% to 13%, in the lower extremity. Its common locations are the flexor surface of the extremities, the neck, the mediastinum, the retroperitoneum, the posterior spinal roots, and the cerebellopontine angle.² The clinical signs and symptoms are often misinterpreted because of the low incidence, and schwannomas are often misdiagnosed as other soft-tissue tumors, such as neurofibroma.

* Work developed at Department of Sports Medicine, Sir Ganga Ram Hospital, Sarhadi Gandhi Marg, Old Rajinder Nagar, New Delhi, India.

received
February 29, 2020
accepted
April 15, 2020
published online
September 22, 2020

DOI <https://doi.org/10.1055/s-0040-1714224>.
ISSN 0102-3616.

© 2020. Sociedade Brasileira de Ortopedia e Traumatologia. All rights reserved.

This is an open access article published by Thieme under the terms of the Creative Commons Attribution-NonDerivative-NonCommercial-License, permitting copying and reproduction so long as the original work is given appropriate credit. Contents may not be used for commercial purposes, or adapted, remixed, transformed or built upon. (<https://creativecommons.org/licenses/by-nc-nd/4.0/>)

Thieme Revinter Publicações Ltda., Rua do Matoso 170, Rio de Janeiro, RJ, CEP 20270-135, Brazil

Case Presentation

A 39-year-old male patient presented to the outpatient department with complaints of a non-traumatic solitary swelling over the posteromedial aspect of the right ankle associated with mild pain. He had noticed the swelling 15 years before, and it gradually increased in size and was associated with pain that was mild to moderate in intensity and intermittent in nature. There was no significant family history.

The clinical findings showed firm swelling over the posteromedial aspect of the ankle measuring $3 \times 2 \times 2$ cm approximately, and it was non-fluctuant, non-pedunculated, non-compressive, and with no transillumination present. There was no sensorimotor impairment in the right leg and foot.

A magnetic resonance imaging (MRI) scan of the leg (**Fig. 1a,b,c**) revealed a well-circumscribed lesion in the subcutaneous plane in the posteromedial aspect of the distal third of the leg abutting underlying soleus and tAchilles

tendon with no definitive evidence of infiltration likely benign lesion? neurogenic.

We proceeded with the surgical excision of the swelling after we obtained consent and the complications were explained. The skin overlying the swelling was incised in a curved fashion, and a dissection was performed to demarcate the capsule of the tumor that was incised. Further fine blunt dissection was performed circumferentially along the branch of the posterior tibial nerve, with the perineural sheath attached. The tumor was retracted and removed without damaging the surrounding vessels and nerves (**Fig. 2a,b**).

The nerve was fully preserved and examined before closure. The excised tumor was sent for a histological study (**Fig. 2c**). The postoperative period was uneventful, with good skin healing and well-preserved nerves.

The histopathological examination revealed a Schwannoma (**Fig. 3**) consisting of Antoni type A tissue, which is composed of highly cellular spindle-shaped cells

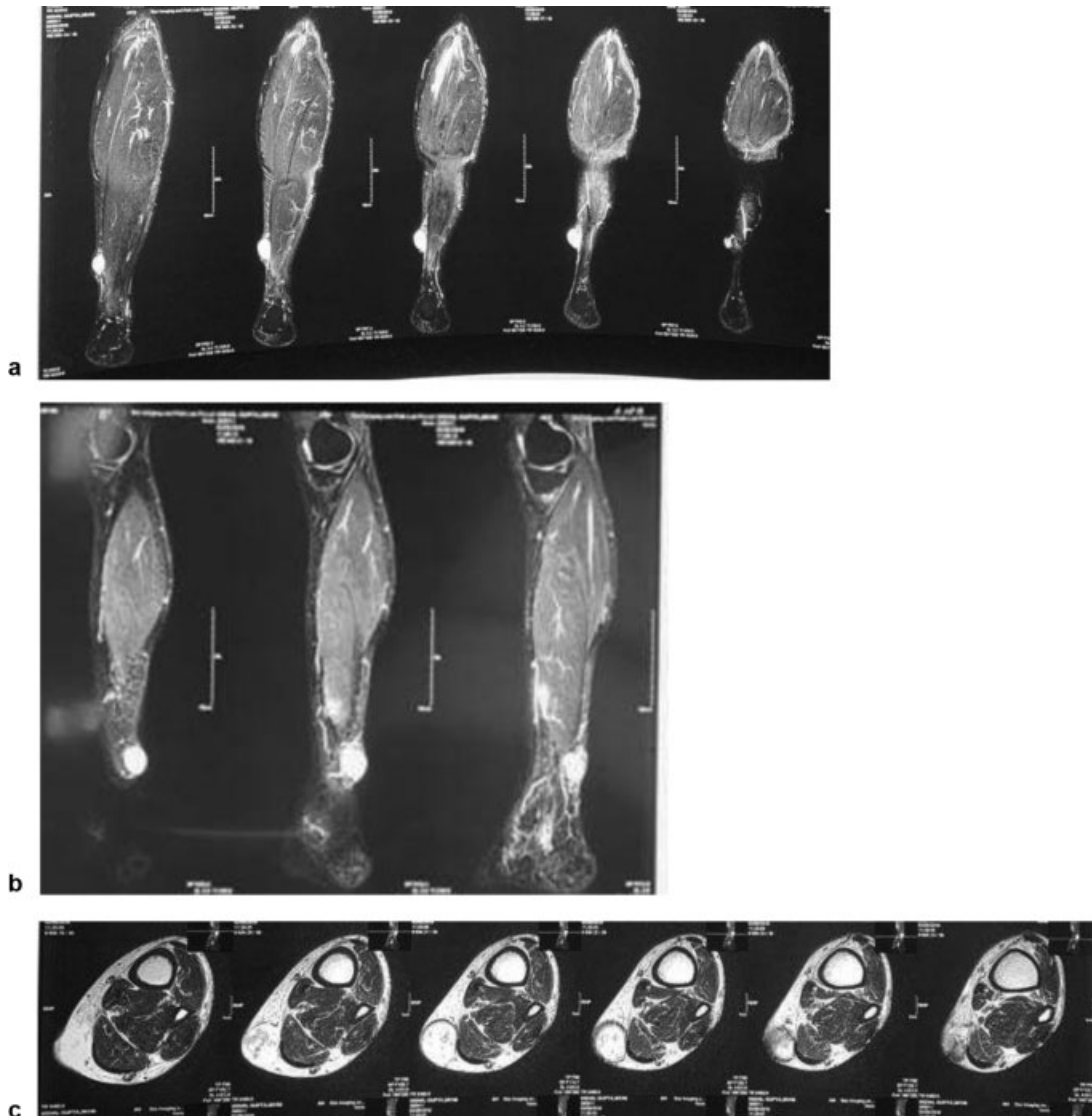


Fig. 1 (a) Magnetic resonance imaging scan (MRI) showing posteromedial swelling over the distal third of the leg in coronal view. (b) MRI showing posteromedial swelling over the distal third of the leg in sagittal view. (c) MRI showing posteromedial swelling over the distal third of the leg in axial view.

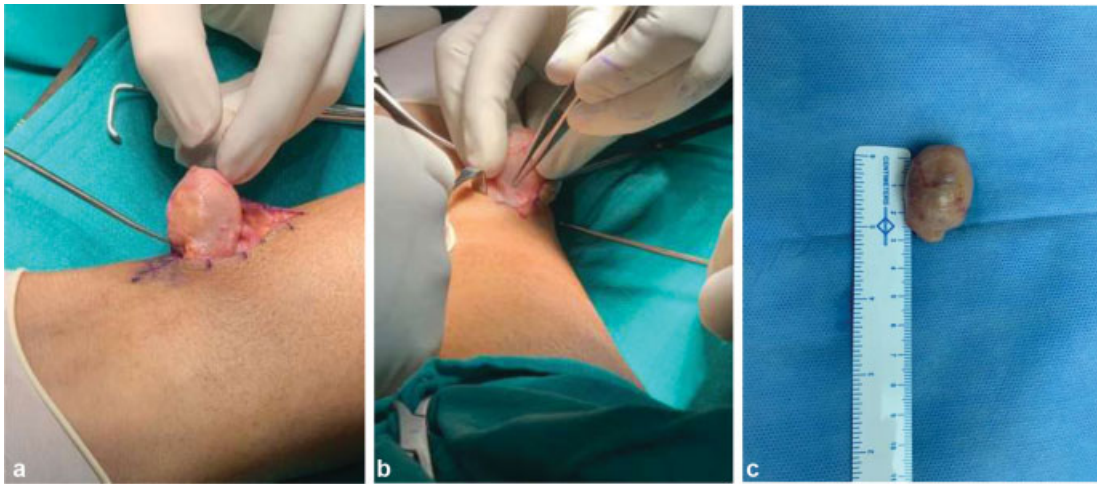


Fig. 2 (a) Intraoperative image showing the tumor attached to the underlying neurovascular tissue, as well as other soft tissues. (b) Fine dissection of the neurovascular structures from the tumor. (c) Measurement of the dimension of the excised tumor.

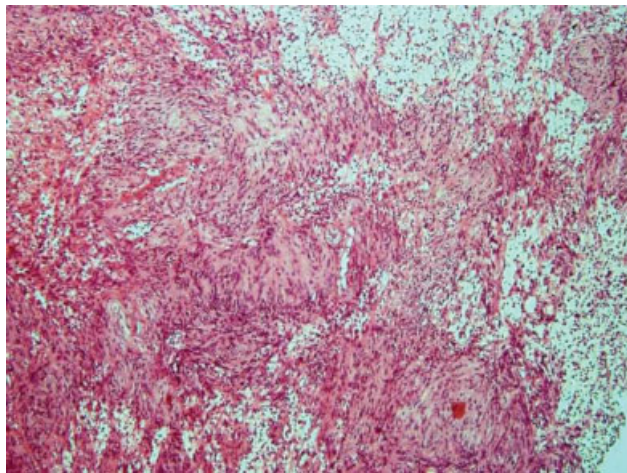


Fig. 3 Histopathological slide showing a tumor composed of cellular areas of oval to spindle cells with thin oval nuclei and formation of Verocay bodies (Antoni type A tissue) and loose paucicellular area of Antoni type B tissue.

surrounding the Verocay bodies and Antoni type B tissue, which consists Schwann cells.

Discussion

Schwannomas in the lower extremities are limited to less than 10% of all cases, according to a study by Albert et al.³ Our case is rare, as the literature search results show very few case reports of schwannomas affecting the posterior tibial nerve.

Delay in the diagnosis is often peculiar in cases of tibial-nerve schwannoma; our patient was operated after 15 years of the onset of symptoms. A similar delay in diagnosis, of up to 10 years, was reported by Ghaly.⁴ Smith and Amis⁵ reported pain in the foot for 8 years before the recognition of a schwannoma, while Nawabi and Sinisi⁶ suggested that the mean time to diagnose the schwannoma was of 86.5 months (more than 7 years).

Extracapsular excision is a commonly-used technique⁷ that may be associated with the risk of developing postoperative neurological deficits. During tumor dissection, to reduce the risk of damage to the nerve fascicles, Hussain et al.⁸ proposed tumor release by incising the capsule far laterally to the path of the nerve and dissecting circumferentially, with the epineural capsule behind to act as a protective covering; in our case, we incised the capsule in the dorsal aspect, as we knew that the nerve was in the ventral aspect. This was followed by dissection until the nerve and further fine dissection separating it from the parent nerve.

The present is a report of a rare location of a schwannoma of the posterior tibial nerve in the posteromedial aspect of the ankle, which was managed by excision, with no neurovascular damage.

Conflict of Interests

The authors have no conflict of interests to declare.

References

- Adani R, Baccarani A, Guidi E, Tarallo L. Schwannomas of the upper extremity: diagnosis and treatment. *Chir Organi Mov* 2008; 92(02):85–88
- Fletcher CD. Peripheral nerve sheath tumors. A clinicopathologic update. *Pathol Annu* 1990;25(Pt 1):53–74
- Albert P, Patel J, Badawy K, et al. Peripheral Nerve Schwannoma: A Review of Varying Clinical Presentations and Imaging Findings. *J Foot Ankle Surg* 2017;56(03):632–637
- Ghaly RF. A posterior tibial nerve neurilemoma unrecognized for 10 years: case report. *Neurosurgery* 2001;48(03):668–672
- Smith W, Amis JA. Neurilemoma of the tibial nerve. A case report. *J Bone Joint Surg Am* 1992;74(03):443–444
- Nawabi DH, Sinisi M. Schwannoma of the posterior tibial nerve: the problem of delay in diagnosis. *The Journal of bone and joint surgery* 2007;89-B(06):814–816
- Rockwell GM, Thoma A, Salama S. Schwannoma of the hand and wrist. *Plast Reconstr Surg* 2003;111(03):1227–1232
- Hussain M, Jhattu H, Pandya A, et al. A precise excision technique for schwannomas. *Eur J Plast Surg* 2012;36(02):111–114