



# Acute Carpal Tunnel Syndrome due to Persistent Median Artery thrombosis: Case report\*

## *Síndrome do túnel do carpo aguda por trombose da artéria mediana: Relato de caso*

Yussef Ali Abdouni<sup>1</sup> João Pedro Farina Brunelli<sup>2</sup> Marco Antônio Soares Munia<sup>3</sup>

<sup>1</sup> Department of Orthopedics and Traumatology, Irmandade of Santa Casa of Misericórdia of São Paulo, São Paulo, SP, Brazil

<sup>2</sup> Hand Surgery Group, Irmandade of Santa Casa of Misericórdia from São Paulo, São Paulo, SP, Brazil

<sup>3</sup> Department of Vascular Surgery, Israelita Albert Einstein Hospital, São Paulo, SP, Brazil

Endereço para correspondência João Pedro Farina Brunelli, MD, R. Dr. Cesário Mota Júnior, 112, Vila Buarque, São Paulo, SP, 01221-010, Brazil (e-mail: brunelli.joao@gmail.com).

Rev Bras Ortop 2023;58(2):347–350.

### Abstract

#### Keywords

- ▶ carpal tunnel syndrome
- ▶ thrombosis
- ▶ arteries
- ▶ compressive syndrome

Carpal tunnel syndrome is the most common compressive neuropathy of the upper limb, affecting ~4% of the general population. The clinical picture is characterized by pain and, mainly, paresthesia in the median nerve territory, of insidious onset and, in the most severe cases, loss of strength and atrophy of the thenar musculature is observed. It is an extremely common pathology in the daily practice of hand surgery, and in most cases, it can be treated with conservative methods. We present here an atypical case of carpal tunnel syndrome, of acute onset, triggered by persistent median artery (PMA) thrombosis, condition associated with distal embolization and hypoperfusion of the limb.

### Resumo

#### Palavras-chave

- ▶ síndrome do túnel do carpo
- ▶ trombose
- ▶ artérias
- ▶ síndrome compressiva

A síndrome do túnel do carpo é a neuropatia compressiva mais comum do membro superior, afetando ~4% da população geral. O quadro clínico caracteriza-se por dor e, principalmente, parestesia no território do nervo mediano, de início insidioso e, nos casos mais graves, observa-se perda de força e atrofia da musculatura tenar. Trata-se de patologia extremamente comum na prática diária de cirurgia da mão, e na maior parte dos casos pode ser tratada com métodos conservadores. Apresentamos aqui um caso atípico de síndrome do túnel do carpo, de surgimento agudo, desencadeado pela trombose da artéria mediana persistente, quadro associado com embolização distal e hipoperfusão do membro.

\* Work developed at the Department of Orthopedics and Traumatology, Irmandade of Santa Casa de Misericórdia of São Paulo, São Paulo, SP, Brazil.

received

April 10, 2020

accepted

May 5, 2020

article published online

September 25, 2020

DOI <https://doi.org/10.1055/s-0040-1714228>.

ISSN 0102-3616.

© 2020. Sociedade Brasileira de Ortopedia e Traumatologia. All rights reserved.

This is an open access article published by Thieme under the terms of the Creative Commons Attribution-NonDerivative-NonCommercial-License, permitting copying and reproduction so long as the original work is given appropriate credit. Contents may not be used for commercial purposes, or adapted, remixed, transformed or built upon. (<https://creativecommons.org/licenses/by-nc-nd/4.0/>)

Thieme Revinter Publicações Ltda., Rua do Matoso 170, Rio de Janeiro, RJ, CEP 20270-135, Brazil

## Introduction

Carpal tunnel syndrome is the most common compressive neuropathy of the upper limb, affecting ~ 4% of the general population.<sup>1</sup> The clinical picture is characterized by pain and, mainly, paresthesia in the median nerve territory, of insidious onset and, in the most severe cases, loss of strength and atrophy of the thenar musculature is observed.<sup>2</sup> The carpal tunnel is an osteofibrous, inelastic channel, it has as roof the transverse carpal ligament, through which 10 structures pass: the 4 superficial flexors and the 4 deep flexors of the fingers, the long flexor of the thumb and the median nerve.

The etiology of compression of the median nerve inside the carpal canal is related to the decrease in the content or to an increase in the content. Among the congenital factors possibly associated with the onset of symptoms, we find the persistence of the median artery, described since 1958 as an intraoperative finding in carpal tunnel syndrome.<sup>3</sup>

The median artery is an embryonic remnant that can persist in 1 to 16% of the population.<sup>4</sup> It is the dominant artery in the embryonic hand, but Kleinert et al.<sup>5</sup> observed significant participation of the median artery in the superficial palmar arch in only 0.5% of cases. It is an anatomical variation that appears as a satellite vessel of the median nerve, following its path in the anterior aspect of the forearm, passing below the retinaculum of the flexors and extending to the palmar region. There is great variability in the origin of the median artery, which may arise from the radial artery, the ulnar artery or even the anterior interosseous artery. Its diameter varies from 0.8 to 2.5 mm, with an average of 1.3 mm, and is frequently associated with the bipartite median nerve.<sup>6,7</sup>

The relationship between the persistent median artery and carpal tunnel syndrome, a chronic disease, was emphasized by Lavey and Pearl.<sup>8</sup> Barfred et al.<sup>9</sup> observed two groups with distinct behavior: one with typical symptoms, with insidious onset and chronic evolution, and the other with acutely triggered symptoms, with severe pain and paresthesia. In the first group, the surgical finding was that of a patent median artery while in the second there was thrombosis of the artery. Other authors have also reported median artery thrombosis as the cause of an acute carpal tunnel syndrome.<sup>9</sup> In these cases, electroneuromyography is generally not able to confirm the diagnosis, since the condition is triggered by an acute nerve ischemia and the detectable changes on examination, related to axonal degeneration, are not present at the beginning. Thus, in the face of clinical suspicion, doppler ultrasonography is the most suitable test for diagnostic confirmation.<sup>10</sup>

As the installation and evolution of thrombosis occur quickly, the symptoms appear intensely and the treatment, for acute cases, is surgical, with opening of the canal and resection of the thrombosed artery, which usually leads to immediate relief of symptoms.<sup>3,6</sup>

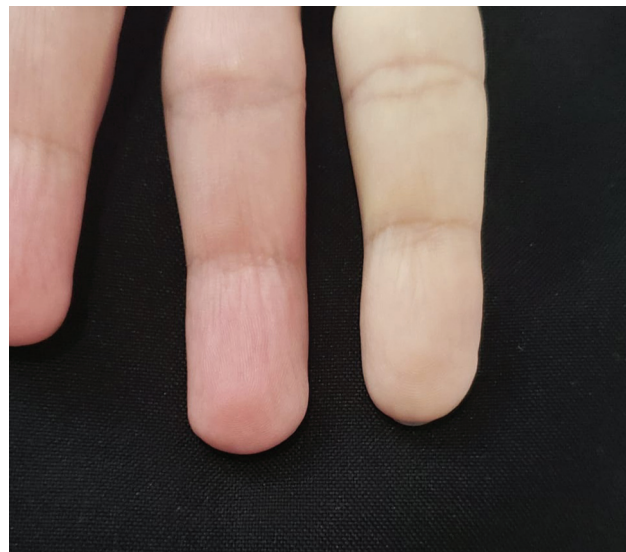We present an unusual case of carpal tunnel syndrome, acute onset, triggered by persistent median artery thrombosis.

## Case report

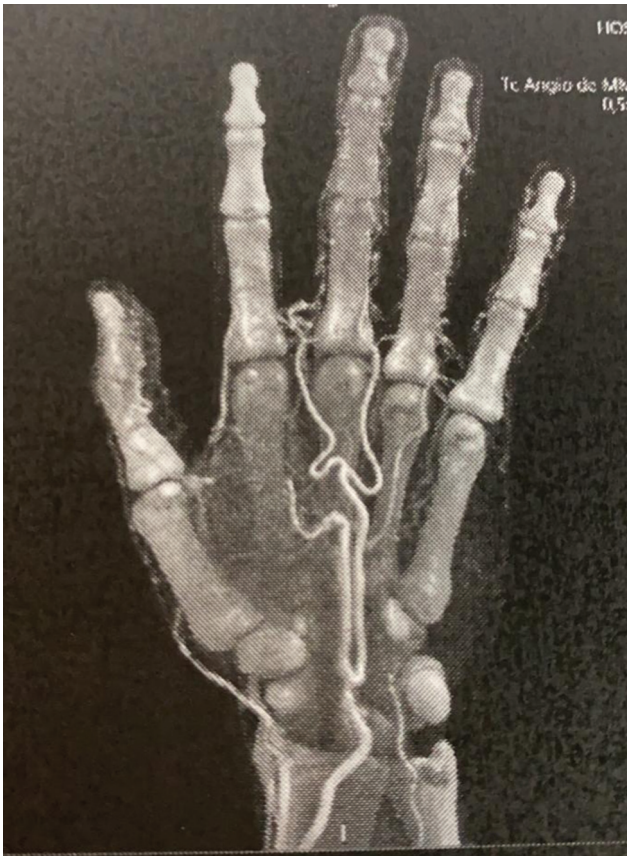Male patient, 54 years old, white, left-handed, businessman, HIV carrier, using triple antiretroviral regimen (tenofovir, dolutegravir and lamivudine). He sought the emergency room, complaining of his left-hand indicator which was cold, pale, with severe pain and numbness for 1 day long (► **Figure 1**). He denied similar symptoms before this episode. A vascular surgery team was called in and, not observing patency of the palmar arch by the Allen test, requested an angiogram (► **Figure 2**), which showed a persistent and large median artery, being predominant in the circulation of the hand, with signs of thrombosis at the level of the carpal canal and embolization for the digital artery of the 2<sup>nd</sup> finger. Anticoagulant therapy with subcutaneous 60 mg enoxaparin was introduced twice daily, combined with a peripheral arterial vasodilator (alprostadil 40 µg in intravenous infusion, twice daily).

Evaluation of the hand surgery team was requested, testing positive for Phalen and Tinel tests on the affected side, and surgical treatment was indicated, which was performed the following day. In the intraoperative period, the large median artery was observed under the transverse ligament and, after opening it, the artery was pulsating, hardened in its intracanal path (► **Figure 3A-B**). Resection of the thrombosed segment was not performed, as the median artery was dominant in the hand and, with the drug therapy instituted, recanalization of the vessel was expected.

On the first postoperative day, the patient already reported significant improvement in pain and paresthesia but maintained a slower perfusion and a cold sensation in the 2<sup>nd</sup> finger. After 7 days, the perfusion was already normalized, with no difference in sensitivity, color or temperature of the affected finger compared with the others (► **Figure 4**).



**Fig. 1** Preoperative clinical aspect showing poor perfusion of the index and middle fingers.



**Fig. 2** Angiotomography showing persistent and dominant median artery. Reduced perfusion on the 2<sup>nd</sup> finger.

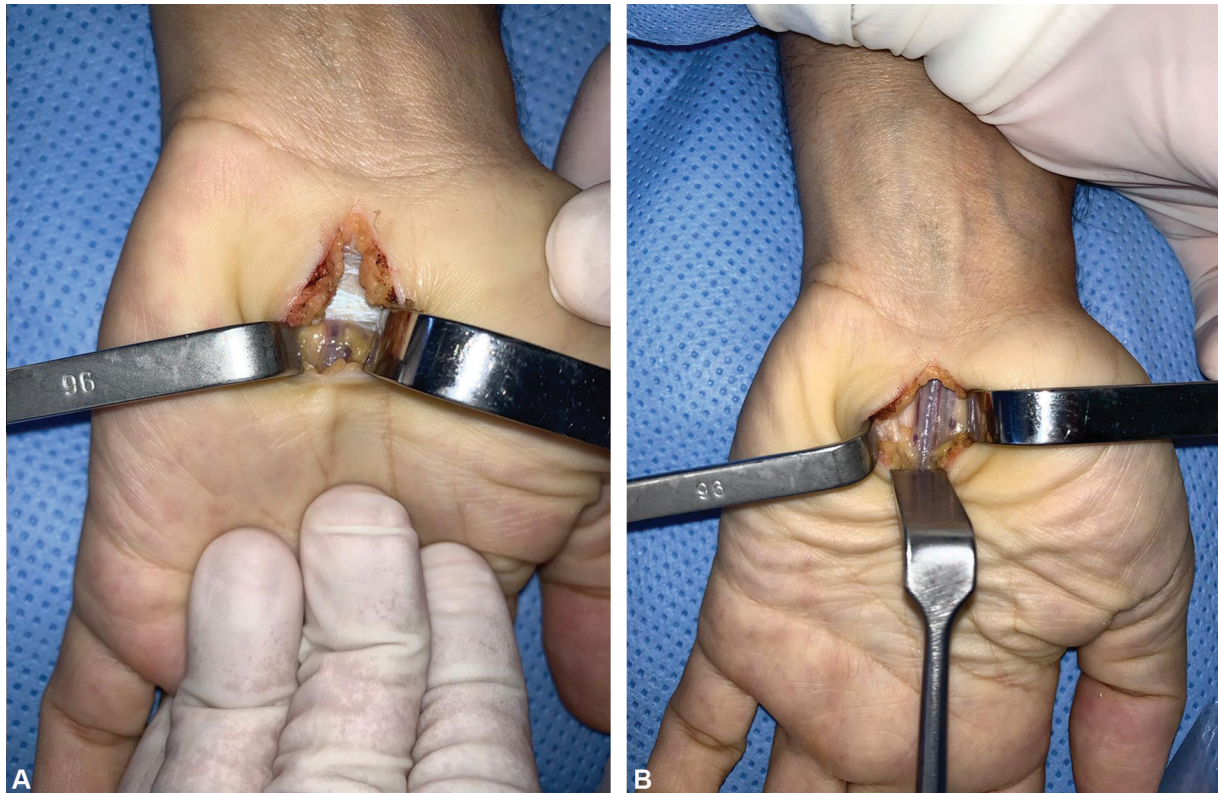
## Discussion

Anatomical studies show that the median artery can persist in up to 16% of the population, being responsible for the increase of the content inside the carpal canal and leading chronically to the typical symptoms of the median nerve compression syndrome.<sup>4</sup> However, thrombosis of this vessel is related, in some reports in the literature, to carpal tunnel syndrome in its acute form. The cause of thrombosis is generally described as associated with repetitive trauma to the artery walls.<sup>6</sup>

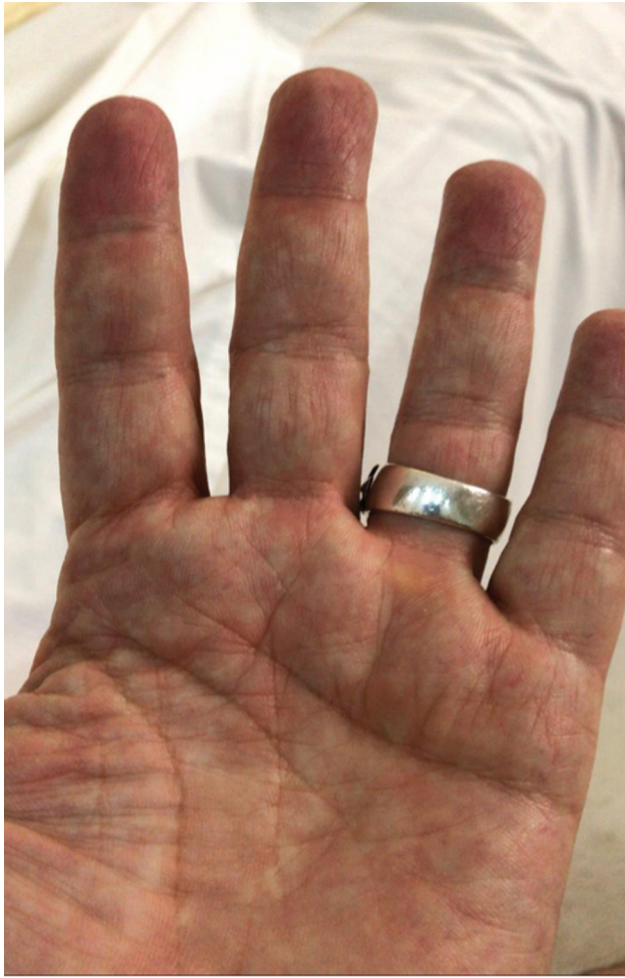The etiology of vasculopathies associated with HIV infection is probably of multifactorial origin. For practical purposes, they are classified as HIV-associated vasculitis, vasculitis secondary to antiretroviral therapy, or both. Several types of endovascular lesions have been reported, usually caused by vasculitis, forming a heterogeneous group of disorders characterized histologically by the presence of inflammatory infiltrate in the blood vessel wall.

In the case presented here, there was no trauma or repetitive effort that could justify the endothelial lesion causing thrombosis, with vasculopathy resulting from HIV infection, or from the antiretroviral treatment itself, as the main hypothesis.

The exam of choice for confirming persistent median artery thrombosis is the doppler;<sup>10</sup> however, angiotomography can show more details and with more precision, such as the dominance of the median artery in the perfusion of the hand and the embolization for the digital artery. Once the diagnosis is confirmed, surgical treatment should be instituted, since the condition of severe pain, resulting from acute compression, does not usually revert spontaneously.<sup>3,6</sup>



**Fig. 3 A** (left) - median artery compressed under the transverse ligament. **B** (right) - median artery after release of the carpal tunnel.



**Fig. 4** 2<sup>nd</sup> finger perfusion fully restored 1 week after surgery.

Despite being dominant in the embryonic phase, the median artery, when it persists, presents itself as a remnant, without significant repercussion on the vascularization of the hand.<sup>5</sup> We did not find, in the literature, a report of the dominant median artery related to carpal tunnel syndrome. The treatment instituted in this case differed from previous

studies in the literature, with only decompression being performed, without, however, resecting the thrombosed artery.

#### Financial Support

The authors declare that they have not received financial support from public, private, or non-profit sources for the conduction of the present study.

#### Conflito de interesses

Os autores declaram não haver conflito de interesses.

#### Referências

- 1 Atroshi I, Gummesson C, Johnsson R, Ornstein E, Ranstam J, Rosén I. Prevalence of carpal tunnel syndrome in a general population. *JAMA* 1999;282(02):153-158
- 2 Katz JN, Larson MG, Sabra A, et al. The carpal tunnel syndrome: diagnostic utility of the history and physical examination findings. *Ann Intern Med* 1990;112(05):321-327
- 3 De Abreu LB, Moreira RG. Median-nerve compression at the wrist. *J Bone Joint Surg Am* 1958;40-A(06):1426-1427
- 4 Lindley SG, Kleinert JM. Prevalence of anatomic variations encountered in elective carpal tunnel release. *J Hand Surg Am* 2003;28(05):849-855
- 5 Kleinert JM, Fleming SG, Abel CS, Firrell J. Radial and ulnar artery dominance in normal digits. *J Hand Surg Am* 1989;14(03):504-508
- 6 Mazer N, Barbieri CH, Zatiti SCA, Velludo MAL. Síndrome do túnel carpal aguda associada a trombose da artéria mediana persistente. *Rev Bras Ortop* 1993;28(04):201-203
- 7 Chammas M, Boretto J, Burmann LM, Ramos RM, Santos Neto FC, Silva JB. Síndrome do túnel do carpo - Parte I (anatomia, fisiologia, etiologia e diagnóstico). *Rev Bras Ortop* 2014;49(05):429-436
- 8 Lavey EB, Pearl RM. Patent median artery as a cause of carpal tunnel syndrome. *Ann Plast Surg* 1981;7(03):236-238
- 9 Barfred T, Højlund AP, Bertheussen K. Median artery in carpal tunnel syndrome. *J Hand Surg Am* 1985;10(6 Pt 1):864-867
- 10 Gassner EM, Schocke M, Peer S, Schwabegger A, Jaschke W, Bodner G. Persistent median artery in the carpal tunnel: color Doppler ultrasonographic findings. *J Ultrasound Med* 2002;21(04):455-461