

Use of Polydioxanone Threads as an Alternative in Nonsurgical Procedures in Facial Rejuvenation

Roxana Cobo, MD¹ 

¹Department of Otolaryngology, Centro Médico Imbanaco, Cali, Colombia

Address for correspondence Roxana Cobo, MD, Carrera 38A #5A-100 cons 222A, Centro Medico Imbanaco, Cali 760044, Colombia (e-mail: rcobo@imbanaco.com.co).

Facial Plast Surg 2020;36:447–452.

Abstract

Minimally invasive cosmetic procedures are in increasing demand worldwide. Patients are constantly searching for office-based techniques that can help improve the signs of aging but without the morbidity of a surgical procedure. Thread lifting with polydioxanone (PDO) sutures is a cosmetic procedure where lax tissue is lifted and repositioned trying to create a more youthful looking facial contour. The threads are absorbable and come in different shapes and lengths. The rate of complications and the downtime of the procedure are low, which are something patients are looking for. Ideally, these procedures should be performed by trained specialists who have complete knowledge of the facial anatomy, thus enhancing and improving results. Thread lifting with PDO absorbable threads has become an excellent option for minimally invasive facial rejuvenation procedures with a high satisfaction among patients and very few complications. It is a new tool that can be introduced in the armamentarium of specialists who work in the field of facial plastic surgery and who can offer this option to their patients with improved outcomes.

Keywords

- ▶ thread lifting
- ▶ PDO absorbable threads
- ▶ minimally invasive procedures
- ▶ facial rejuvenation
- ▶ facial plastic surgery

Facial aging is an ongoing process that is usually accompanied by the loss of skin elasticity and loss of facial volume. This can result in brow ptosis, jowl formation, marked nasolabial folds, and loose skin in the neck area. Surgical rhytidectomy techniques are considered the “gold standard” in facial rejuvenation. These procedures can not only result in partial or permanent complications, but they are also associated with long downtime periods and lengthy postsurgical swelling and edema.

Over the years minimally invasive procedures have become increasingly popular with an escalating demand of office-based procedures. There is a trend in patients seeking facial rejuvenating alternatives that do not have long recovery periods, have decreased morbidity and downtime, and can still give some improvement to facial skin sagging.

“Suture suspension” of the face is not a new procedure. Thread lifting, also known as “the lunch-time face lift,” was first promoted by Sulamanidze and colleagues in the 1990s.^{1,2} Suture material has evolved over the years progressing from nonabsorbable suture material to barbed permanent sutures.^{3–5}

Today, the material of choice in thread lifting is the use of absorbable sutures. It has very few complications and has the additional benefit of stimulating collagen production. This procedure has gained popularity worldwide and is something that is being performed by general practitioners and specialists alike. This being said, it is an excellent nonsurgical procedure that facial plastic surgeons and other specialists can perform in their offices with good outcomes. Although there are several types of absorbable threads in the market today, this article discusses the use and clinical applications of polydioxanone (PDO) threads, techniques involved, and results.

The Mechanisms of PDO Thread Lifting

PDO is a synthetic absorbable surgical suture that has been used in surgery for many years. The suture material is reabsorbed completely by the body in 4 to 6 months. This reabsorption is done by hydrolysis, triggering fibroblast production, which in turn produces more collagen in the targeted area.⁵ When the thread is inserted, there is granulation tissue production and

formation of the different types of collagen found in the human skin. Type 1 and type 3 collagen are created and end up playing a role in the tensile strength of the human dermis.⁶ Myofibroblasts and fibroblasts are generated in this new granulation tissue. The myofibroblasts are related to wound contraction and healing, and play a role in skin elasticity of the treated area and tightening of the skin as part of the skin regeneration process.⁷

In addition to this, when barbed sutures are used under the skin, they will tighten and lift the loose areas of the face creating better definition and contour. The formation of fibrous tissue will help the suture in keeping the ptotic tissue in place. The final result of repositioning lax tissue, generation of myofibroblasts and fibroblasts, and neocollagenesis will have an impact on skin texture, tone, pore size, and elasticity.^{5,8-10}

Types of PDO Threads

There are three main types of PDO threads: smooth monofilament plain threads, monofilament spiral or screw, multiple monofilament threads, and barbed sutures. These sutures have evolved over the years and today there is a large variety of sutures the specialist can use depending on the patient's specific needs. The PDO threads either smooth or barbed are contained either in a cannula or in a needle. The thread either smooth or barbed has a V-shape where half of the thread is inside the needle or cannula and the other half is outside held in place with a fixing sponge (►Fig. 1).⁸

Monofilament Threads

These threads are smooth, do not have cogs or barbs, and are placed using a "free-floating" technique. The diameter and length of the smooth thread vary. Needle thickness oscillates from 18 to 31 gauge needles and the length varies depending on the area that is being treated. When smooth threads are being inserted in the subdermal plane, simply removing the needle or cannula will automatically leave the thread in place. The same principle applies for spiral, or screw, or multiple monofilament threads (broom). These smooth threads produce a firming effect, help regenerate tissue, and improve quality of the skin, but they do not give the patient important lifting of tissue. Screw, spiral, or broom threads give additional volume to areas where there has been loss of volume. In all of these smooth types of threads, the production of collagen around them improves volume, skin elasticity, and skin texture (►Fig. 2A, B).




Fig. 1 Schematic description of a polydioxanone thread.⁸ All threads have a hurb which is the cap of the needle or cannula. The thread is inserted through the hurb and exits through the tip of the needle or cannula leaving half of the thread out and fixed to the exterior portion of the needle or cannula with a small sponge.

Cog PDO Threads

Cog PDO threads have barbs or spikes that can be unidirectional, bidirectional, or multidirectional. Today barbed sutures should be 4D or 6D. This means that the thread has barbs on four or six sides (360 degrees) augmenting the pull the thread will have on the tissue. The barbs that each suture has are cogs that clasp the skin and help suspend the tissue in different areas of the face. Bidirectional threads and threads with barbs on four to six sides will have a better hold on tissue than unidirectional threads. The great advantage of these new barbed sutures is that they do not need to be suspended to a deeper anatomic structure like periosteum or deep temporalis fascia. The multiple barbs suspend the tissue when it is lifted helping improve skin laxity and ptosis (►Fig. 2C, D).⁵

Types of Procedures with PDO Threads

Two types of procedures can be performed with PDO threads: creation of a MESH and a lifting procedure.

MESH Procedure

This is done with smooth threads. A mesh or a net is created with thin smooth threads inserted subcutaneously in areas where there is slight hollowness or tissue resorption. These smooth threads can be inserted in the cheek and jowl area, the jawline area, the temporal region, and the submental area (►Fig. 3). The objective is to create a mesh with smooth threads so there will be a good production of collagen and myofibroblasts. Even though this will not create a clear lifting effect, it will improve skin texture and elasticity. The number of threads used will depend on how many areas are targeted. In the jawline area, from 6 to 9 threads can be used per side, in the jowl area 5 to 10 threads per side, and in the temporal area 3 to 5 per side. These smooth threads will create a nice mesh-like structure that will be a good complement to the suspension threads.⁷

Cog Thread Lifting Procedure

The Cog threads used by the author are 4D and 6D bidirectional threads. Fixation points are usually placed slightly in front of the hairline above the zygomatic arch or on the most prominent area of the malar bone to try and obtain a lift in the jowl area and the nasolabial fold. Marionette lines are usually corrected by placing the fixation point at the ear lobe (►Fig. 4). From the fixation points, the vectors are defined. A correct definition of the pull of the different vectors will have a direct impact on the final result. This will also help in defining the number of sutures that are going to be used.

Patient Selection

Patient selection is particularly important if any success is going to be achieved with thread lifting procedures. Patients need to understand that this will not replace facial rejuvenation surgery and it will not achieve the same results. The best candidates for this procedure are usually men or women between 40 and 50 years who have mild signs of aging (skin

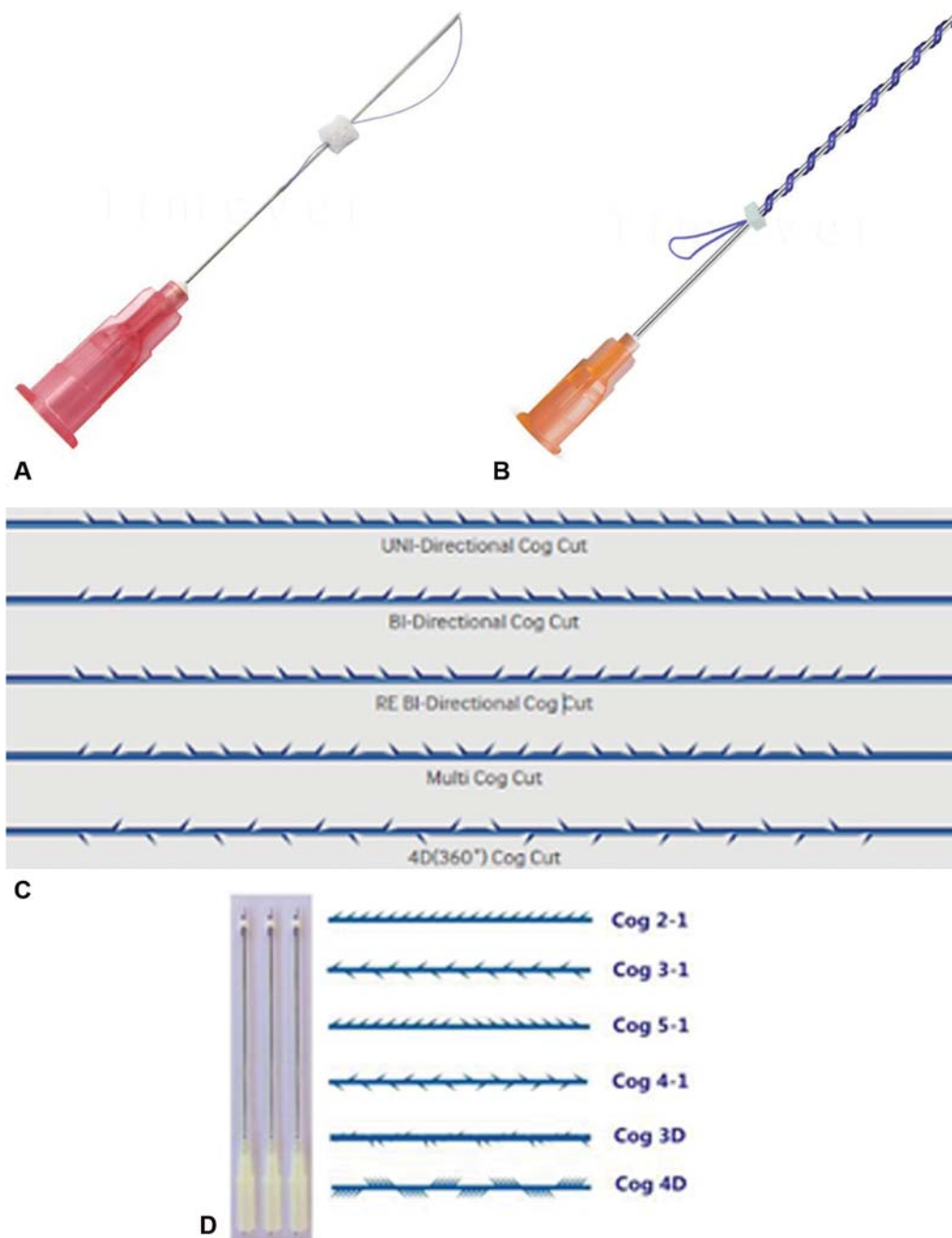


Fig. 2 Types of threads. Threads can be smooth or barbed. (A, B) Smooth threads can be single or multiple or they can have a screw-like shape. Their main function is collagenesis. (C, D) The barbed threads can be unidirectional or bidirectional. They can have barbs or cones. These are the ones that create the lifting of the structures. The references vary and what is used will depend on what is available in different countries.

laxity, jowls, rhytids) and are not ready or do not want a surgical procedure. Heavily overweight patients, patients with severe skin laxity, or thick-skinned patients are not the best candidates for thread lifting. Candidates without realistic expectations are not good candidates and should not be offered this procedure.

Thread Lifting Technique

Thread lifting should be appropriately planned. Using two or three fingers, or the palm of the hand, the patient's skin is elevated and the fixation point and vector of the pull are

designed and drawn on the patient (→ Fig. 4). Since these are threads that are not fixed to the deep temporalis fascia or to periosteum, the fixing points should be near ligament structures that can give the sutures some additional stability.

The author uses a combination technique where smooth threads are combined with Cog barbed sutures to obtain improved results. Standard photographs are taken and vectors are defined and marked depending on the patient's needs. Areas to be treated are covered with anesthetic cream for approximately 1 hour.

Areas of the face to be treated are cleansed and prepped with betadine solutions. Barbed suture entry sites are injected

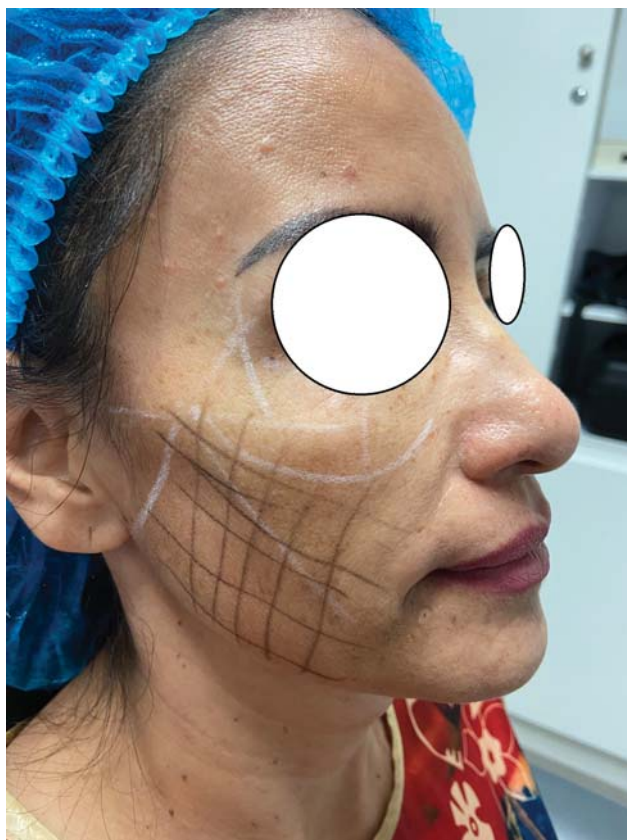

Fig. 3 Mesh procedure is usually done with smooth threads. A mesh is drawn in black creating a net where smooth threads will be introduced creating a subcutaneous mesh that stimulates collagen production. A similar mesh can be placed along the jawline in the temporal area and in the neck.

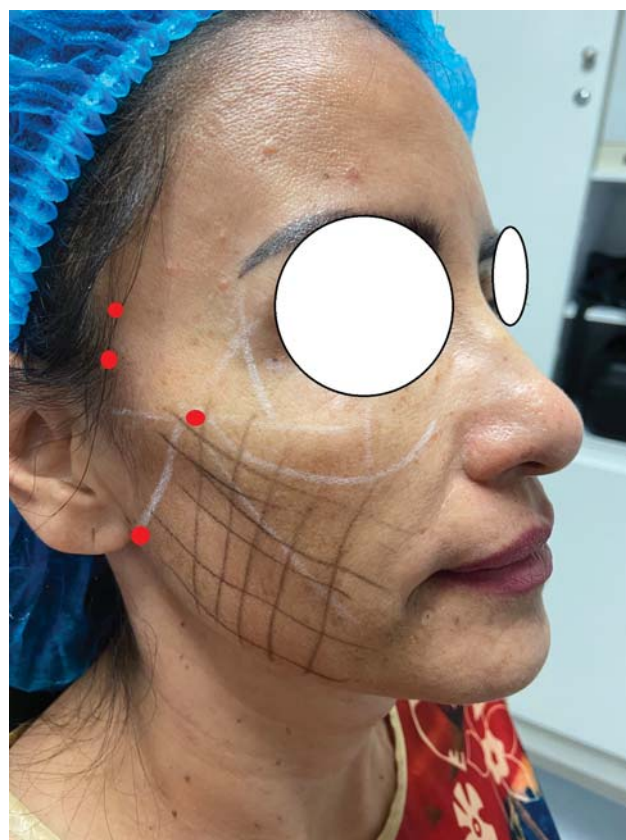

Fig. 4 Fixation points and definition of vectors. Fixation points (red dots) are placed in areas near ligament or bony structures. This helps anchor the sutures in points where they will have additional support. Once the fixation points are defined, the vector of the pull is defined depending on what the patient wants and where the greatest tissue laxity is found. A combination of smooth and barbed threads usually gives a better result.

with 1 to 2% lidocaine mixed with epinephrine (1:200,000). Smooth suture entry sites are usually covered with topical anesthetic cream.

The smooth threads are placed before the barbed sutures as this is a quick relatively pain-free procedure. Once the mesh is created, the Cog sutures are placed. A hole is created in the entry vector point with an 18-gauge needle. The cannula containing the Cog thread is placed perpendicular to the skin in the created hole and advanced until the subcutaneous plane is reached. At this point the cannula is redirected in a subcutaneous plane following the previously drawn vector line until the endpoint is reached. The cannula is then carefully taken out making sure the skin is advanced and the cogs are fitted in place with the nondominant hand. If the cannula is placed in the proper plane, this is a relatively painless procedure.

Once the procedure is ended, the patient's face is cleaned and covered with ice packs, which are left in place at least for 30 minutes before the patient leaves the office. This will help minimize bruising and swelling. Patients are encouraged to sleep in a supine position the first week. Sports, gum chewing, laughing, yawning excessively, rubbing the treated area, or performing any facial massages are not recommended the first 2 to 3 weeks after the procedure. All patients are discharged with written recommendations and clear instructions on how to proceed if any complication arises (►Fig. 5).

Complications

Complications with thread lifting procedures are few. The most frequent complaints are bruising, swelling, facial asymmetries, skin dimpling, and, in some reports, infection.^{6,8,11} Most of the reported complications are not severe and usually do not require additional interventions.¹² Patient dissatisfaction is common in patients with thread lifts. Even though the frequency has not been clearly identified, when present it can be a problem. The best way to prevent this is with appropriate patient selection and by giving patients clear information on the real limitations of the procedure. Being properly trained and feeling comfortable with the facial anatomy are a big advantage for the specialist and for the patient as results can be improved. Thread lifting in no way can really be a replacement of a facelifting procedure.

Discussion

Patients are constantly seeking alternatives for facial rejuvenation that hopefully will not mean a surgical procedure. The interest in using thread lifting techniques as an alternative or as part of a facial rejuvenation procedure is not new and has been reported since late 1990s.^{1,2} Initially the procedure was performed with nonabsorbable sutures, but the complication

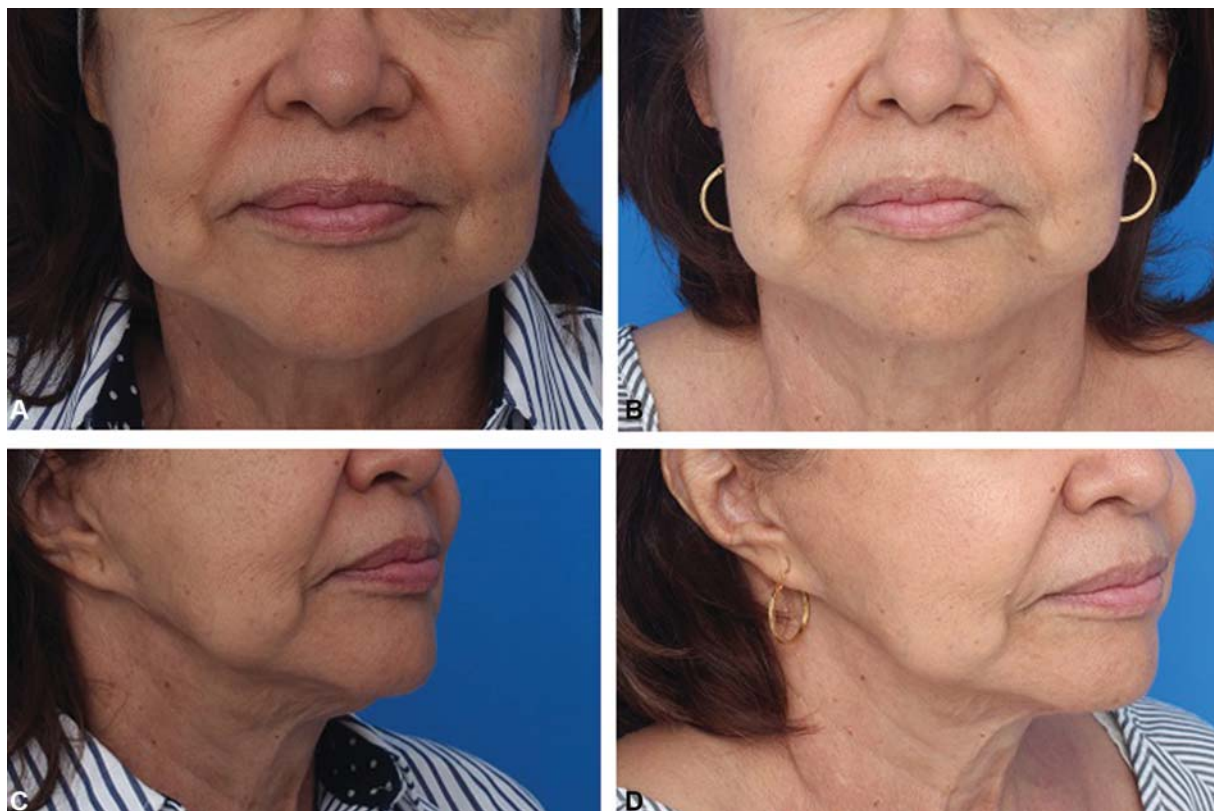

Fig. 5 (A, C) Images showing marked skin laxitude in the jowl area with prominent nasolabial folds. (B, D) Images showing 1 year postprocedure result. Note the improvement in quality of skin and slight reduction of laxitude tissue in the jowl area.

rate was high, and the removal of the permanent barbed sutures was difficult, time consuming, and frequently impossible to remove completely leaving fragments of foreign body material in the face.^{11,13,14}

Nonabsorbable sutures have changed the perception of thread lifting dramatically. Patients are able to obtain good cosmetic results with very low morbidity and little, if any, downtime from work. PDO sutures are degraded in the body at approximately 4 to 6 months and during this process stimulate collagen production and result in positive skin changes.¹⁵

The big problem with this type of techniques is that most studies do not report long-term results. Additionally, it is also hard to evaluate patient satisfaction objectively although there are studies showing a good acceptance rate of the procedure.^{8,16–18} Suspension sutures with barbed threads can be effective techniques if patients are chosen carefully. It is the author's perception that having a deep knowledge of the facial anatomy and understanding facial vectors, fixing points, and pulling mechanisms will help improve results for the benefit of the patient.

Conclusion

Aesthetic procedures using absorbable PDO threads are an interesting alternative for facial rejuvenation. Different types of threads and techniques can be used depending on the patient's needs. The great advantages of these techniques are the low morbidity and the low downtime from work. Proper

training and knowledge of the different thread lifting techniques as well as adequate patient selection is crucial to be able to obtain good cosmetic results. Although patient satisfaction initially can be satisfactory and the complication rate low, more studies showing long-term results are necessary. It is an excellent office-based procedure that, when used properly, can enhance the armamentarium of nonsurgical facial rejuvenation techniques.

Conflict of Interest

None.

References

- 1 Sulamanidze MA, Paikidze TG, Sulamanidze GM, Neigel JM. Facial lifting with "APTOS" threads: featherlift. *Otolaryngol Clin North Am* 2005;38(05):1109–1117
- 2 Sulamanidze MA, Fournier PF, Paikidze TG, Sulamanidze GM. Removal of facial soft tissue ptosis with special threads. *Dermatol Surg* 2002;28(05):367–371
- 3 Kaminer M-S, Bogart M, Choi C, Wee SA. Long-term efficacy of anchored barbed sutures in the face and neck. *Dermatol Surg* 2008;34(08):1041–1047
- 4 Villa M-T, White L-E, Alam M, Yoo SS, Walton RL. Barbed sutures: a review of the literature. *Plast Reconstr Surg* 2008;121(03):102e–108e
- 5 Wong V, Rafiq N, Kalyan R, et al. Hanging by a thread: choosing the right thread for the right patient. *J Dermat Cosmetol*. 2017;1(04): 86–88
- 6 Fukaya M. Long-term effect of the insoluble thread-lifting technique. *Clin Cosmet Investig Dermatol* 2017;10:483–491
- 7 Kim B, Oh S, Jung W, eds. *Understanding PDO*. In: *The Art and Science of Thread Lifting*. Singapore: Springer; 2019:69–70

- 8 Suh DH, Jang HW, Lee SJ, Lee WS, Ryu HJ. Outcomes of polydioxanone knotless thread lifting for facial rejuvenation. *Dermatol Surg* 2015;41(06):720–725
- 9 Fukaya M. Two mechanisms of rejuvenation using thread lifting. *Plast Reconstr Surg Glob Open* 2018;6(12):e2068
- 10 Panprapa Y, Punyaphat S, Pakjira S. Thread lift: classification, technique, and how to approach to the patient. *Int J Med Health Sci* 2016;10(12):547–555
- 11 Tong LX, Rieder EA. Thread-lifts: a double-edged suture? A comprehensive review of the literature. *Dermatol Surg* 2019;45(07):931–940
- 12 Yeo SH, Lee YB, Han DG. Early complications from absorbable anchoring suture following thread-lift for facial rejuvenation. *Arch Aesthetic Plast Surg* 2017;23(01):11–16
- 13 Yoo KH, Kim WS, Hong CK, Kim BJ. Chronic inflammatory reaction after thread lifting: delayed unusual complication of nonabsorbable thread. *Dermatol Surg* 2015;41(04):510–513
- 14 Shin JJ, Park JH, Lee JM, Ryu HJ. Mycobacterium massiliense infection after thread-lift insertion. *Dermatol Surg* 2016;42(10):1219–1222
- 15 Kim J, Zheng Z, Kim H, Nam KA, Chung KY. Investigation on the cutaneous change induced by face-lifting monodirectional barbed polydioxanone thread. *Dermatol Surg* 2017;43(01):74–80
- 16 Kim J, Kim HS, Seo JM, Nam KA, Chung KY. Evaluation of a novel thread-lift for the improvement of nasolabial folds and cheek laxity. *J Eur Acad Dermatol Venereol* 2017;31(03):e136–e179
- 17 Kang SH, Byun EJ, Kim HS. Vertical lifting: a new optimal thread lifting technique for Asians. *Dermatol Surg* 2017;43(10):1263–1270
- 18 Lee H, Yoon K, Lee M. Outcome of facial rejuvenation with polydioxanone thread for Asians. *J Cosmet Laser Ther* 2018;20(03):189–192