

Transoral Neurosurgery during COVID-19 Pandemic

Siddharth Chavali^{1,✉} Vanitha Rajagopalan^{2,✉} Kanwaljeet Garg³ Girija P. Rath^{2,✉}

¹Department of Neurosciences, Aditya Birla Memorial Hospital, Pune, Maharashtra, India

²Department of Neuroanaesthesiology and Critical Care, Neurosciences Centre, All India Institute of Medical Sciences, New Delhi, India

³Department of Neurosurgery, All India Institute of Medical Sciences, New Delhi, India

Address for correspondence Girija P. Rath, MD, DM, Department of Neuroanaesthesiology and Critical Care, Neurosciences Centre, All India Institute of Medical Sciences, Ansari Nagar, New Delhi 110029, India (e-mail: girijarath@aiims.edu).

J Neuroanaesthesiol Crit Care:2020;7:170–171

The novel coronavirus (SARS-CoV-2) is a highly transmissible respiratory pathogen that causes coronavirus disease 2019 (COVID-19); recently, it has grown into a global pandemic.¹ During this period, patients requiring emergent as well as elective surgeries for craniovertebral junction (CVJ) pathologies present a unique challenge to the treating team, as they provide the potential to spread the infection to the health care workers (HCWs). The majority of patients infected with the virus are asymptomatic, and viral load has been seen to be greatest in the nasal cavity, nasopharynx, oropharynx, and lower respiratory tract even in asymptomatic patients.²

Approach to CVJ lesions is determined by the nature of compression (►Fig. 1). When dynamic radiological imaging shows the presence of reducible atlantoaxial dislocation, posterior instrumentation alone after reduction of dislocation may be adequate. Some cases of irreducible atlantoaxial dislocation can be dealt with the DCER technique, which involves distraction, compression, extension, and reduction. It is a posterior-only single-stage approach and may be considered as an alternative method.³ However, a considerable number of these patients will still require anterior decompression in the form of transoral odontoidectomy. Indications of transoral odontoidectomy in today's era include patients who have failed posterior fixation, pathologies with irreducible anterior compression along with compression of the cervicomedullary spinal cord, and patients with significantly deformed joints.

Transoral odontoidectomy involves exposure of the CVJ through the oropharynx and the use of high-speed drills through the oropharyngeal exposure. Both these steps may expose HCWs to an increased risk of aerosol and droplet contamination.⁴ Virus particles may remain airborne for over 3 hours, and such surgeries are considered high-risk procedures. These patients should be screened with

questionnaires, chest X-rays, and test for COVID-19 regardless of risk status prior to admission and surgery, with the aim of minimizing length of hospital stay in patients who tested negative. Surgery should be deferred until patients test negative for COVID-19 if feasible since such surgeries are usually elective in nature, and patients who require urgent surgery should be considered COVID-19-positive until proven otherwise. For these patients, full personal protective equipment (PPE) should be donned by the operating team, given the increasing community prevalence of asymptomatic patients. The use of power drills should be minimized as far as possible to decrease aerosol generation. Generous irrigation may be helpful in mitigating aerosol generation to some extent, which results from the use of power drills, but should be performed carefully so as to avoid spilling of the saline outside the patient's oral cavity. Irrigation of the surgical site with a diluted solution of povidone-iodine may also be considered since such solutions have been previously shown to rapidly inactivate coronaviruses.⁵ Use of an operating microscope can be of help as the distance between the surgeon and the oropharynx increases considerably. The use of an endoscope may let the surgeon use a face shield while operating, which is not possible while using an operating microscope.

Considerations for the anesthesia team include management of a potentially difficult airway, minimizing neck movement to prevent spinal cord compression, and minimizing exposure to aerosols during procedures such as intubation. Awake fiberoptic bronchoscopy is considered to be the gold standard for airway management in such patients; however, this procedure entails the risk of patient coughing and may be considered a high-risk procedure. Awake fiberoptic intubation should be avoided unless considered absolutely essential, and operators should don full PPE while minimizing the number of people in the operating theater

DOI <https://doi.org/10.1055/s-0040-1714927>
ISSN 2348-0548.

© 2020. Indian Society of Neuroanaesthesiology and Critical Care. This is an open access article published by Thieme under the terms of the Creative Commons Attribution-NonDerivative-NonCommercial-License, permitting copying and reproduction so long as the original work is given appropriate credit. Contents may not be used for commercial purposes, or adapted, remixed, transformed or built upon. (<https://creativecommons.org/licenses/by-nc-nd/4.0/>). Thieme Medical and Scientific Publishers Pvt. Ltd., A-12, 2nd Floor, Sector 2, Noida-201301 UP, India

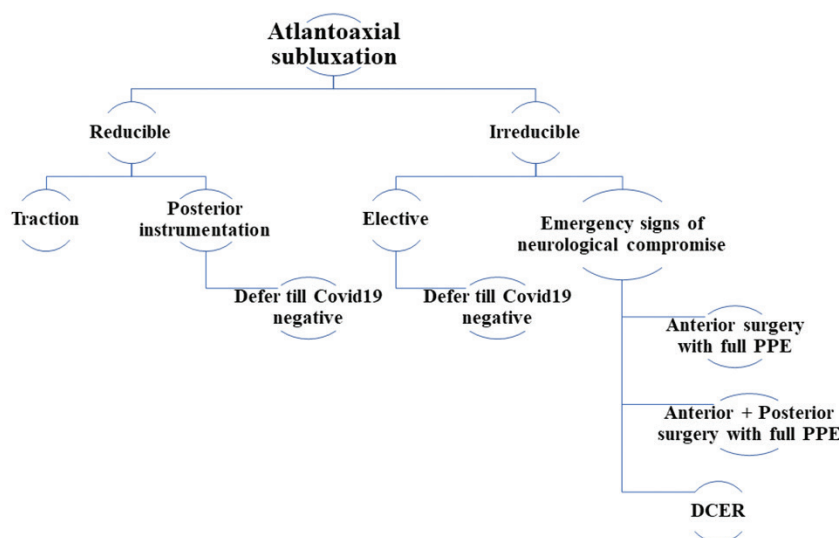


Fig. 1 Approach to the transoral odontoidectomy during COVID-19 (coronavirus disease 2019) pandemic.

during the procedure. Videolaryngoscopy under anesthesia may be favored to increase the distance between the airway operator and the patient and may optimize the chance of first-pass success, and application of manual in-line stabilization may help minimize excessive movement and cord compression during airway instrumentation.⁶ Periprocedural briefings including a clearly communicated plan might help improve procedural safety. Management of the difficult airway requires expert operators, and protocolized approaches to preparation, procedures, and debriefings to minimize confusion and cognitive loading during a stressful situation. Postoperatively, such patients are usually ventilated electively since there is a significant degree of airway edema due to mucosal trauma following surgery. Care needs to be taken to ensure resolution of airway edema prior to extubation, and the cuff leak test may be inappropriate in patients who are confirmed COVID-19-positive. Appropriate PPE should be donned prior to extubation, and staff exposure should be minimized, ensuring that adequate steps are taken to minimize coughing and spread of aerosol droplets.

Conflict of Interest

None declared.

References

- 1 Phelan AL, Katz R, Gostin LO. The novel coronavirus originating in Wuhan, China: challenges for global health governance. *JAMA* 2020;323(8):709–710
- 2 Wang W, Xu Y, Gao R, et al. Detection of SARS-CoV-2 in different types of clinical specimens. *JAMA* 2020;323(18):1843–1844
- 3 Chandra PS, Prabhu M, Goyal N, Garg A, Chauhan A, Sharma BS. Distraction, compression, extension, and reduction combined with joint remodeling and extra-articular distraction: description of 2 new modifications for its application in basilar invagination and atlantoaxial dislocation: prospective study in 79 cases. *Neurosurgery* 2015;77(1):67–80
- 4 Workman W, Welling DB, Carter BS, et al. Endonasal instrumentation and aerosolization risk in the era of COVID-19: simulation, literature review, and proposed mitigation strategies. *Int Forum Allergy Rhinol* 2020. Doi:10.1002/alr.22577
- 5 Eggers M, Koburger-Janssen T, Eickmann M, Zorn J. In vitro bactericidal and virucidal efficacy of povidone-iodine gargle/mouthwash against respiratory and oral tract pathogens. *Infect Dis Ther* 2018;7(2):249–259
- 6 Luo M, Cao S, Wei L, et al. Precautions for intubating patients with COVID-19. *Anesthesiology* 2020;132(6):1616–1618