

Atypical Spontaneous Hematomas in a Patient with Severe Coronavirus Disease 2019 (COVID-19)

Massimo Mattioli, MD¹  Devis Benfaremo, MD² Elisa Fustini, MD¹ Silvia Gennarini, MD¹

¹UOC Emergency Department, Azienda Ospedaliera “Ospedali Riuniti Marche Nord,” Pesaro, Italy

²Dipartimento di Scienze Cliniche e Molecolari, Università Politecnica delle Marche, Ancona, Italy

Address for correspondence Massimo Mattioli, MD, UOC Emergency Department, Azienda Ospedaliera “Ospedali Riuniti Marche Nord,” Piazzale Cinelli, 4 Pesaro 61121, Italy (e-mail: massimo.mattioli@ospedalimarchenord.it).

Semin Thromb Hemost 2020;46:856–858.

We greatly appreciated the recent narrative commentary by Dorgalaleh reflecting on potential bleeding complications in coronavirus disease 2019 (COVID-19).¹ This issue is probably underestimated, perhaps considering that most experts focused on the prothrombotic risks of COVID-19. Nevertheless, the potential development of thrombocytopenia and the widespread use of clinical anticoagulants, sometimes given in higher doses, now require the additional attention of treating clinicians. One potential bleeding issue—not clearly mentioned by the author—is an infrequent type of overt bleeding represented by spontaneous soft tissue hematomas, which may be diagnosed late in the course of COVID-19, especially in sedated, sleeping, or unconscious patients. A prompt detection of such conditions has relevance in therapeutic decisions, including the need for any interventional radiological procedure and also for the prognosis, considering the development of acute compartmental syndrome.² Here, we wish to describe the case of a patient with severe COVID-19 pneumonia, who developed subsequent multiple spontaneous muscular hematomas.

On March 28, 2020, an 84-year-old Caucasian man with a history of chronic obstructive pulmonary disease, hypertension, and ischemic heart disease presented to the Emergency Department complaining of shortness of breath and chills, symptoms that started 10 days earlier. On admission, he was mildly tachypneic, confused, dehydrated, febrile, and hypoxic. Results of blood tests taken at that time and subsequently are shown in ▶Table 1. Real-time polymerase chain reaction analysis of a nasopharyngeal swab sample confirmed SARS-CoV-2 (severe acute respiratory syndrome coronavirus 2) infection (intrafamilial transmission) and high-resolution computed tomography (CT) detected bilateral subpleural ground-glass areas suggestive of viral interstitial pneumonia. Along with his usual therapy (pantoprazole, fluticasone

furoate/vilanterol, simvastatin, and acetylsalicylic acid [aspirin] 100 mg once daily), hydroxychloroquine 200 mg twice daily and piperacillin/tazobactam 4.5 g every 8 hours were prescribed. After the resolution of the mild acute kidney injury with proper rehydration, 40 mg once daily of low molecular weight heparin (LMWH) was administered, but this was ceased early (on April 3) due to the development of mild thrombocytopenia (70×10^9 platelet/L at nadir). Supportive therapy with continuous positive airway pressure with an orofacial mask was needed for the initial days, until the amelioration of pO₂ allowed oxygen delivery at lower flows through nasal prongs. On the morning of April 8, a bilateral neck and upper chest subcutaneous hematoma appeared with mild painful swelling (▶Fig. 1A). A contrast CT scan of the chest and neck region detected bilateral and asymmetric hematoma (left > right) of the sternocleidomastoid muscles (▶Fig. 1B); no signs of pulmonary or deep venous thrombosis were present. No central venous access positioning had been previously attempted, and no trauma had occurred. After a few hours, the patient complained of worsening pain in the left inguinal region, and a deep muscular hematoma was also found within adductors muscles (▶Fig. 1C), without pathological findings in the abdomen. Given that only moderate grade anemia gradually developed in the subsequent days and thrombocytopenia completely resolved (▶Table 1), a conservative approach was taken and two units of red packed cells were transfused, with subsequent stable hemoglobin values. Aspirin was withdrawn. Hematomas were monitored daily with bedside color Doppler ultrasonography and remained stable. The patient was discharged in a postacute care facility nine days after the onset of bleeding following resolution of the hematomas, without any recurrence reported within 30-day follow-up visit; no further CT exam was performed because of clinical

published online
September 2, 2020

Issue Theme Maintaining Hemostasis and Preventing Thrombosis in COVID-19—Part I; Guest Editors: Emmanuel J. Favaloro, PhD, FFSc (RCPA), and Giuseppe Lippi, MD.

Copyright © 2020 by Thieme Medical Publishers, Inc., 333 Seventh Avenue, New York, NY 10001, USA.
Tel: +1(212) 760-0888.

DOI <https://doi.org/10.1055/s-0040-1715092>
ISSN 0094-6176.

Table 1 Blood tests collected during the hospitalization

	March 28	April 2	April 8	April 12
Arterial blood gas				
pH	7.43	7.41	7.37	NA
PaO ₂ (mmHg)	61	73	73	NA
PaCO ₂ (mmHg)	32	40	44	NA
Oxygen saturation of hemoglobin (%)	93	98	96	NA
PaO ₂ /FiO ₂	290	228	317	NA
Laboratory				
Hemoglobin (g/L)	156	148	143	92
Platelet count (×10 ⁹ /L)	101	70	126	168
White cell count (×10 ⁹ /L)	4.81	4.23	5.81	8.72
Total lymphocytes (×10 ⁹ /L)	0.5	0.8	1.2	1.8
International normalized ratio	1.1	1.4	1.4	1.4
Activated partial thromboplastin time (seconds)	29	34	32	30
Fibrinogen (g/L)	4.16	4.75	3.10	NA
D-dimer (mg/L) ^a	1.02	NA	0.72	0.91
C-reactive protein (mg/L)	27.3	63.5	16.0	61.0
Procalcitonin (ng/L)	NA	0.28	0.07	0.23
Creatinine (mmol/L)	2.07	1.34	1.26	0.89
eGFR (mL/minute/1.73m ²) ^b	30	50	54	>60
Alanine aminotransferase (U/L)	16	12	24	31
Aspartate aminotransferase (U/L)	28	29	33	35

Abbreviations: eGFR, estimated glomerular filtration rate; NA, not available.

^aD-dimer HS 500 - Instrumentation Laboratory/Werfen (turbidimetric immunoassay; fibrinogen equivalent units).

^bEstimated with MDRD-4 (Modification of Diet in Renal Disease 4 variables equation).

improvement and stable hemoglobin level (refer to ►**Fig. 2** for a complete timeline).

A recent report has described a longer hospitalization of patients with delayed-phase thrombocytopenia associated with older age and lymphopenia,³ as appears to have happened in this case. Many conditions might explain the appearance of these complications. First, an overt disseminated intravascular coagulation (DIC) can determine transient thrombocytopenia in the course of COVID-19 infection⁴; however, the DIC score (2001 International Society on Thrombosis and Hemostasis [ISTH] Guidelines) in our patient was < 5; therefore, DIC was unlikely. Moreover, we considered concomitant medications, in particular LMWH and aspirin, as potential contributors to the hematoma development. Heparin-induced thrombocytopenia, for example, could be an explanation for the platelet count reduction, but the patient had low proba-

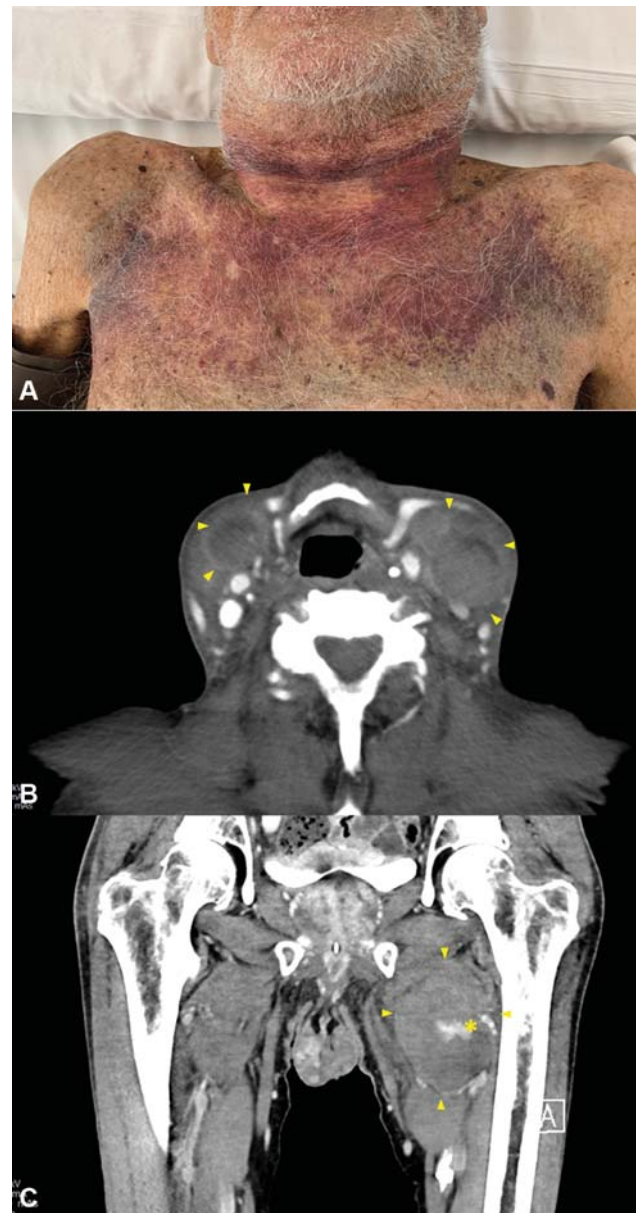


Fig. 1 (A) Photo showing the extension of subcutaneous hematomas. Contrast-enhanced CT (computed tomography) images showing hemorrhagic infarction (arrowheads) and tissue distortion of both sternocleidomastoid muscles, more prominent on the left one, in the cervical region (B) and the hematoma of the left abductors district (C) with minor intraslesional contrast extravasation (asterisk).

bility (only 3) in 4Ts score⁵; therefore, according to our hospital's protocol, serum antibodies against heparin-PF4 complexes were not assessed. Naturally, failure to perform HIT testing could be seen as a potential study limitation, as conclusive exclusion of HIT could not be attained. However, thrombosis, not bleeding, is the usual clinical presentation of HIT. As an additional study limitation, antifactor Xa testing is not available in our laboratory; therefore, plasma heparin levels were unknown. In any case, the thrombocytopenia quickly resolved. Upon review of the patient's past history, it was identified that he had started aspirin 12 years earlier, without any prior development of anemia or any other bleeding event. Nevertheless, aspirin has a well-established

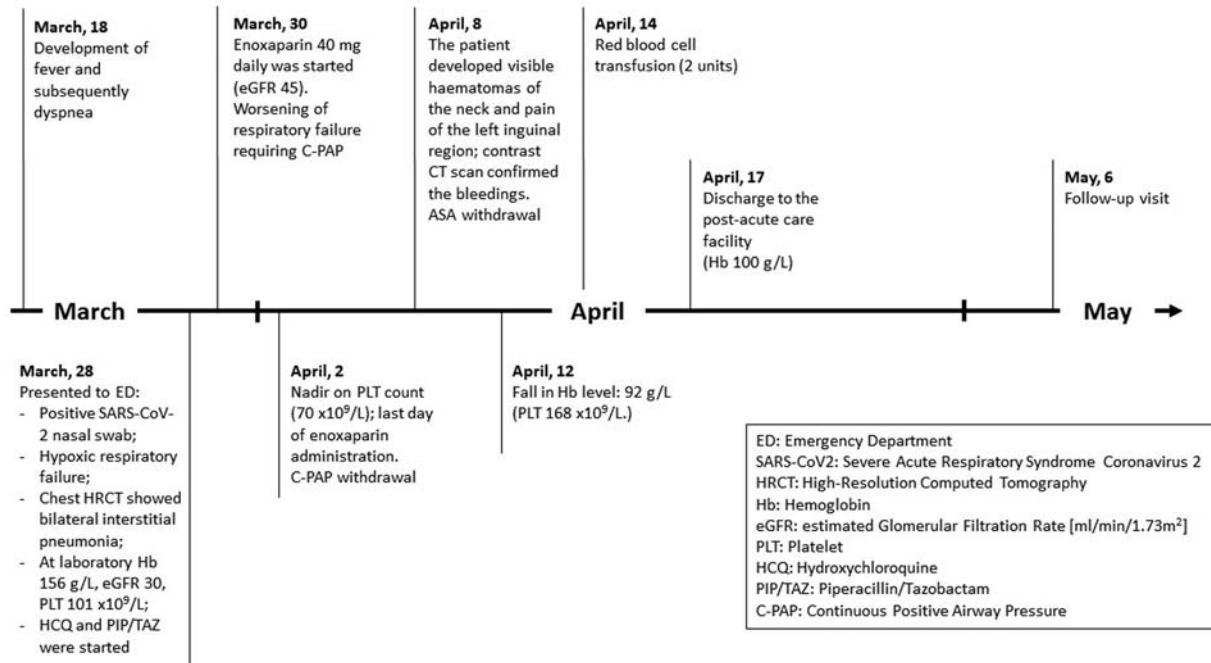


Fig. 2 A timeline of the clinical course and key laboratory features of the described case.

hemorrhagic potential.⁶ Another key clinical question was whether the moderate kidney failure was indirectly responsible for the bleeding state, potentially by increasing plasma levels of LMWH, which we could not ascertain. However, we feel this is unlikely since the temporary worsening of the renal function was already resolved when the hemorrhage occurred. Finally, factor inhibitors may lead to hematoma development; although not assessed in our patient, these are unlikely given coagulation test results never became abnormal.

In conclusion, the real burden of hemorrhagic complications resulting from COVID-19 is unknown and further studies are needed, also assessing the safety of anticoagulant therapies. As a conclusive recommendation, we also advocate assessing a patient's tailored bleeding risk with strong clinical surveillance, mostly in patients who develop thrombocytopenia.

Contribution

All the authors contributed equally to this work.

Funding

None.

Conflict of Interest

The authors declare that they have no conflict of interest.

References

- Dorgalaleh A. Bleeding and Bleeding Risk in COVID-19. *Semin Thromb Hemost* 2020 (e-pub ahead of print) . Doi: 10.1055/s-0040-1713434
- Dohan A, Darnige L, Sapoval M, Pellerin O. Spontaneous soft tissue hematomas. *Diagn Interv Imaging* 2015;96(7-8):789–796
- Chen W, Li Z, Yang B, et al. Delayed-phase thrombocytopenia in patients of coronavirus disease 2019 (COVID-19). *Br J Haematol* 2020 (e-pub ahead of print) . Doi: 10.1111/bjh.16885
- Al-Samkari H, Karp Leaf RS, Dzik WH, et al. COVID and coagulation: bleeding and thrombotic manifestations of SARS-CoV2 infection. *Blood* 2020 (e-pub ahead of print) . Doi: 10.1182/blood.2020006520
- Lo GK, Juhl D, Warkentin TE, Sigouin CS, Eichler P, Greinacher A. Evaluation of pretest clinical score (4 T's) for the diagnosis of heparin-induced thrombocytopenia in two clinical settings. *J Thromb Haemost* 2006;4(04):759–765
- McNeil JJ, Wolfe R, Woods RL, et al; ASPREE Investigator Group. Effect of aspirin on cardiovascular events and bleeding in the healthy elderly. *N Engl J Med* 2018;379(16):1509–1518