



# Anesthetic Management of a Child with $\beta$ -Thalassemia Major and Cortical Venous Thrombosis

Mayank Tyagi<sup>1</sup> Surya K. Dube<sup>1,✉</sup> Vanitha Rajagopalan<sup>1,✉</sup> Gyaninder P. Singh<sup>1,✉</sup>

<sup>1</sup>Department of Neuroanaesthesiology and Critical Care, All India Institute of Medical Sciences, New Delhi, India

**Address for correspondence** Surya K. Dube, MD, DM, Department of Neuroanaesthesiology and Critical Care, 7th Floor, Neurosciences Center, All India Institute of Medical Sciences, New Delhi 110029, India (e-mail: surya.dube@yahoo.co.in).

J Neuroanaesthesiol Crit Care

## Abstract

$\beta$ -thalassemia are a group of inherited blood disorders with reduced hemoglobin levels.  $\beta$ -thalassemia major is the severe form of disease, and the patients often display an array of associated organ dysfunction which thus increase the risk associated with surgery and anesthesia. Patients with  $\beta$ -thalassemia major can have multiple pathological defects that may lead to thromboembolic events. Here, we report such a case who was complicated by occurrence of cerebral sinus thrombosis and presented for decompressive hemicraniectomy under general anesthesia. The anesthetic challenges during in such scenario have been discussed.

## Keywords

- ▶ beta-thalassemia major
- ▶ cortical venous thrombosis
- ▶ decompressive hemicraniectomy

## Introduction

Patients with  $\beta$ -thalassemia major have a chronic hypercoagulable state with increased incidence of thromboembolic episodes. There are multiple pathological defects that lead to thromboembolic events, which may be life threatening. Cortical venous thrombosis with raised intracranial pressure presenting for emergency decompressive hemicraniectomy is one such condition. We report here a case of  $\beta$ -thalassemia major complicated by cerebral sinus thrombosis, who presented for decompressive hemicraniectomy under general anesthesia. We have discussed the anesthetic concerns in management of this patient. In addition to highlighting the anesthetic challenges this report also emphasizes the importance of increased vigilance in the clinical management of this vulnerable group of patients.

## Case Report

A 13-year-old (weight: 45 kg and height: 150 cm) female child presented to us with multiple episodes of seizures with altered consciousness (Glasgow Coma Scale [GCS] E<sub>1</sub>V<sub>2</sub>M<sub>3</sub>).

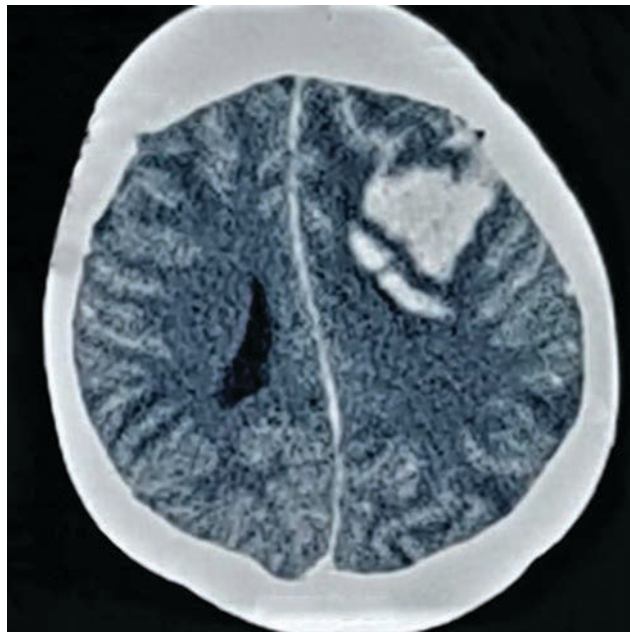
The seizure lasted more than 3 minutes without regaining consciousness in between and was managed initially by intravenous midazolam 3 mg followed by levetiracetam 10 mg/kg given over a period of 30 minutes. Her heart rate, noninvasive blood pressure, respiratory rate, and room air oxygen saturation were 121/min, 136/78 mm Hg, 22/min, and 88% respectively. She was pale, mildly icteric, and had hepatosplenomegaly. Ultrasonography revealed portal vein hypertension, cholelithiasis, and solitary right kidney. Her partial pressure of oxygen was 64 mm Hg, and the remarkable blood parameters were serum sodium of 125 mEq/L, hemoglobin of 7.9 g/dL, platelet count of 80,000/cm<sup>3</sup>, and prothrombin time (international normalized ratio [INR]) of 1.28. Her electrocardiogram showed prolonged QT interval, and two-dimensional echocardiography revealed an ejection fraction of 55%, grade 2 diastolic dysfunction, and right ventricular enlargement. Her facial features included frontal bossing, malar prominence, and depressed nasal bridge. Airway assessment showed buck teeth and a normal range of neck movement. The patient was a case of  $\beta$ -thalassemia major (BTM) and was receiving two units of washed red blood cell units every third week along with deferoxamine mesylate. Computed

DOI <https://doi.org/10.1055/s-0040-1715357>  
ISSN 2348-0548.

© 2020. Indian Society of Neuroanaesthesiology and Critical Care. This is an open access article published by Thieme under the terms of the Creative Commons Attribution-NonDerivative-NonCommercial-License, permitting copying and reproduction so long as the original work is given appropriate credit. Contents may not be used for commercial purposes, or adapted, remixed, transformed or built upon. (<https://creativecommons.org/licenses/by-nc-nd/4.0/>)  
Thieme Medical and Scientific Publishers Pvt. Ltd., A-12, 2nd Floor, Sector 2, Noida-201301 UP, India

tomography (CT) head revealed intracerebral hematoma in the left frontoparietal region with perilesional edema and midline shift (►Fig. 1). She was diagnosed to have cortical venous thrombosis (CVT) with midline shift and was scheduled for emergency decompressive hemicraniectomy.

In view of low GCS and seizures, we intubated the patient's trachea with a video laryngoscope (Cormack–Lehane grade 3b), and optimized the patient with packed red cell and platelet transfusion along with electrolyte correction. Initially, mask ventilation seemed difficult due to poor mask fit, but improved after the insertion of an oropharyngeal airway. Anesthesia was induced with titrated doses of propofol and fentanyl and tracheal intubation facilitated with rocuronium. Anesthesia was maintained with total intravenous anesthesia (using propofol and fentanyl) with 50% oxygen with a target bispectral index of 40 to 60. We used invasive blood pressure, central venous pressure, noninvasive cardiac output monitoring (FloTrac, Edwards Lifesciences, Irvine, California, United States) and rotational thromboelastometry analysis intraoperatively. Hypertonic saline (3% NaCl) was administered to reduce intracranial pressure. The duration of surgery was 4 hours and 30 minutes, which was uneventful; the total blood loss was 700 mL, and she received two units of packed red cells intraoperatively. Postoperatively, her trachea was extubated after 16 hours and injection phenytoin,



**Fig. 1** Intracerebral hematoma in the left frontoparietal region with perilesional edema and midline shift.

deferoxamine mesylate and paracetamol were commenced. For anticoagulation prophylaxis, she received enoxaparin (40 mg) subcutaneously twice daily for 7 days. Warfarin 2.5 mg daily was overlapped during the last 4 days of therapy with the target INR of 2.0 to 3.0. She had a smooth postoperative course (seizures free with no neurological deficit) and was discharged subsequently on a postoperative day 10 with GCS of E<sub>4</sub>V<sub>5</sub>M<sub>6</sub> and intact neurological state.

## Discussion

Beta-thalassemia disease is one of the most common congenital hemolytic anemia. BTM is a severe form of disease with extramedullary hematopoiesis, hepatosplenomegaly, intravascular hemolysis, and growth retardation.<sup>1,2</sup> They often display an array of associated organ dysfunction that affects the risk of surgery and anesthesia, and most perioperative deaths occur due to cardiac complications.<sup>1,2</sup> They are also at increased risk of thromboembolic events that may be life-threatening at times. CVT is a neurological condition linked to hypercoagulable states. Patients with BTM can present with CVT and literature available on the anesthetic management of a thalassemia major patient undergoing decompressive hemicraniectomy for CVT is scarce.

Different anesthetic considerations while managing a patient of BTM with CVT are summarized in ►Table 1. CVT accounts for ~0.5 to 1% of all strokes, while the reported incidence of pediatric CVT is 0.67 per 100 000 children per year.<sup>3</sup> In patients with BTM with suspected CVT, screening for potential prothrombotic conditions is recommended, and early follow-up with CT venography/magnetic resonance imaging/magnetic resonance venography/transcranial Doppler is required to know about the extent of intracerebral insults.<sup>3</sup> Supportive measures include appropriate hydration, antibiotics, control of seizure and elevated intracranial pressure, and its complications along with periodic assessments of the visual fields and visual acuity.<sup>3</sup> The mainstay of treatment in CVT is anticoagulation (adjusted-dose unfractionated heparin or weight-based low molecular weight heparin, and warfarin) followed by vitamin K antagonists.<sup>3-5</sup> Steroid medications are not recommended.<sup>3</sup> Agents such as decitabine and hydroxycarbamide and transfusion therapy have been suggested to prevent the complications in CVT.<sup>6</sup> The side effects of different medications used in the treatment of CVT and BTM are summarized in ►Table 2. In patients with neurological deterioration (severe mass effect or intracranial hemorrhage causing intractable intracranial hypertension/herniation) despite medical treatment, decompressive

**Table 1** Systemic manifestations and their anesthetic implications of the  $\beta$ -thalassemia major and cortical venous thrombosis<sup>1-3,5,7-9</sup>

Disease	Organ system	Problem	Pathophysiological mechanisms	Anesthetic considerations
Beta-thalassemia major	Cardiac	Cardiomegaly, Congestive cardiac failure, hypertension, electrophysiological abnormalities	High output state due to chronic anemia	Cardiac output monitoring, acid-base assessment, avoid factors increasing pulmonary vascular resistance (hypoxia, hypercarbia, acidosis, N <sub>2</sub> O, and sympathetic stimulation), two-dimensional echo to detect pulmonary hypertension Maintain stable hemodynamics
	Respiratory	Restrictive lung disease, pulmonary hypertension	Spinal and thoracic cage deformities	Preoperative pulmonary function test, chest X-ray, comprehensive systemic organs examination
	Muscle	Decreased weight gain, poor muscle development (leading to growth retardation)	Increased metabolic demand/decreased supply	Choose drugs with low hepatorenal metabolism (to avoid longer recovery)
	Skeletal	Craniofacial deformities, pathological fractures, compression of neural structures	Ineffective extramedullary erythroid tissue expansion, osteopenia and osteomalacia	Optimal positioning, adequate padding of pressure points
	Hematology	Hypercoagulable state (increased risk of thrombosis), intraoperative systemic hypertension, Hemolysis/anemia, abnormalities in platelet count, reduced tolerance to bleeding, increased transfusional risk	Reduced nitric oxide, multiple blood transfusion, platelet and endothelial activation, decreased protein C and S level, disrupted membrane phospholipids	Thromboelastometry study (for identifying the cause of coagulopathy and guiding administration of coagulation products) and coagulation tests, avoidance of hypoxemia Consider blood salvage Consider risks of neuraxial anesthesia Prophylactic measures for deep vein thrombosis/thromboembolic events
	Immunology	Immunosuppression, risk of transmission of blood-borne infections	Iron overload, chronic anemia, frequent blood transfusion	Impaired hemostasis and operative bleeding Avoid exposure to blood and body fluids
	Hepatic	Liver failure/fibrosis leading to cirrhosis, increased risk of hepatocellular carcinoma and gall stones, altered drug metabolism	Chronic hemolysis, drugs (delayed clearance, increased volume of distribution and prolonged half-life)	Consider drug metabolism and pharmacokinetics Avoid drugs undergoing extensive hepatic metabolism (choose short-acting drugs, e.g., propofol, fentanyl, and cis-atracurium)
	Neurology	Cognitive defects, neuropsychological impairment	Chronicity of disease with emotional and psychosocial issues	Diminished quality of life, increased mortality, and poor recovery postsurgery
	Airway	Craniofacial bone deformity (maxillary hypertrophy, narrowing of the submental space, high-arched palate, prominent zygomatic bones, nasal bridge depression)	Extramedullary hematopoiesis	Careful airway assessment (bedside predictive tests) Drafting a backup plan, preparation for difficult airway management, presence of personnel with expertise
Cortical venous thrombosis	Cardiorespiratory	Pulmonary embolism, cardiac arrest	Thrombi in the microvasculature of lungs	Low lung capacity, hypoxemia, pulmonary hypertension, and diffusion defects with associated right heart failure (Keep fraction of inspired oxygen 50% or above to avoid any V/Q mismatch and pulmonary complications)
	Neurology	Headache, scalp vein distension, and visual disturbances, intracranial hemorrhage, focal brain injury, hemiparesis and aphasia, increased intracranial pressure, seizures	Thrombi in the microvasculature of brain, impaired venous drainage, venous infarction/ischemia or hemorrhage	Raised intracranial pressure (laryngoscopy/ intubation/ adequate depth of anesthesia), appropriate anesthetic technique Brain bulge and Seizure management

**Table 2** Side effect of iron chelating agents and drugs used in the treatment of cortical venous thrombosis<sup>6,10</sup>

Drug	Side effects
Decitabine	Neutropenia, thrombocytopenia, anemia, fatigue, pyrexia, nausea, cough, petechiae, constipation, diarrhea, and hyperglycemia
Hydroxycarbamide	Increased risk of infection, breathlessness, bruising, bleeding gums or nosebleeds, fever, fatigue
Desferrioxime	Ocular and retinal toxicity, growth impairment, ototoxicity, thrombocytopenia, abdominal pain, diarrhea, nausea, vomiting and hypotension, increased risk of infection

hemicraniectomy is considered.<sup>5</sup> Endovascular therapy (balloon-assisted thrombectomy or direct catheter thrombolysis) may be considered in patients with failure of initial anticoagulant therapy or in cases having absolute contraindications for anticoagulation therapy. Patients on anticoagulation therapy requiring urgent surgical intervention require a thorough consideration of risk for perioperative intracranial hemorrhage.

## Conclusion

Thalassemia major patient with CVT presents with highly variable clinical spectra and clinically challenging circumstances. Its management needs understanding and optimization of the physiological derangements, intentional search for co-existing systemic abnormalities, anticipating difficult airway and meticulously planned anesthetic techniques. This case reiterates the importance of the multidisciplinary approach and increased vigilance in the clinical management of this vulnerable group of patients.

## Conflict of Interest

None declared.

## References

- 1 Kallenbach T. Anaesthesia for a patient with beta thalassaemia major. *South African J Anaesth Analg* [Internet] 2015;21(5):21–24
- 2 Staikou C, Stavroulakis E, Karmaniolou I. A narrative review of peri-operative management of patients with thalassaemia. *Anaesthesia* 2014;69(5):494–510
- 3 Saposnik G, Barinagarrementeria F, Brown RD Jr, et al; American Heart Association Stroke Council and the Council on Epidemiology and Prevention. Diagnosis and management of cerebral venous thrombosis: a statement for healthcare professionals from the American Heart Association/American Stroke Association. *Stroke* 2011;42(4):1158–1192
- 4 Yasmin A, O'Keefe YA, Kranz PG, Dombrowski KE, Kolls BJ, James ML. Cerebral venous thrombosis: reviewing pathophysiology, diagnosis, and treatment strategies. *J Neuroanaesth Crit Care* 2019;06:140–144
- 5 Keller E, Pangalu A, Fandino J, Könü D, Yonekawa Y. Decompressive craniectomy in severe cerebral venous and dural sinus thrombosis. *Acta Neurochir Suppl (Wien)* 2005;94(94):177–183
- 6 Kalantri SA, Ray R, Chattopadhyay A, Bhattacharjee S, Biswas A, Bhattacharyya M. Efficacy of decitabine as hemoglobin F inducer in HbE/ $\beta$ -thalassemia. *Ann Hematol* 2018;97(9):1689–1694
- 7 Succar J, Musallam KM, Taher AT. Thalassemia and venous thromboembolism. *Mediterr J Hematol Infect Dis* 2011;3(1):e2011025
- 8 Bharti N, Devrajan J. Difficult airway management in a case of thalassaemia major. *Indian J Anaesth* 2008;52(1):87–89
- 9 Eldor A, Rachmilewitz EA. The hypercoagulable state in thalassaemia. *Blood* 2002;99(1):36–43
- 10 Mobarra N, Shanaki M, Ehteram H, et al. A review on iron chelators in treatment of iron overload syndromes. *Int J Hematol Oncol Stem Cell Res* 2016;10(4):239–247