



# Decompression and Neurolysis of the Lateral Femoral Cutaneous Nerve in the Surgical Treatment of Meralgia Paresthetica and the Results

Kenan Kibici<sup>1,✉</sup> Berrin Erok<sup>2,✉</sup> Ali Önder Atca<sup>3,✉</sup>

<sup>1</sup>Department of Neurosurgery, Altınbaş University School of Medicine Bahçelievler Medical Park Hospital, İstanbul, Turkey

<sup>2</sup>Department of Radiology, Cihanbeyli State Hospital, Konya, Turkey

<sup>3</sup>Department of Radiology, Altınbaş University School of Medicine Bahçelievler Medical Park Hospital, İstanbul, Turkey

**Address for correspondence** Berrin Erok, MD, Department of Radiology, Cihanbeyli State Hospital, Cihanbeyli, Konya, Turkey (e-mail: drberrinerok@hotmail.com).

Indian J Neurosurg 2021;1:13–19.

## Abstract

Meralgia paresthetica (MP), also known as Bernhardt–Roth syndrome, is a peripheral neuropathy of the primary sensory lateral femoral cutaneous nerve (LFCN). Its diagnosis is challenging, because it can mimic other clinical conditions particularly associated with upper lumbar spine or pelvis. Patients present with pain and paresthesia over the anterolateral thigh. Diagnosis is usually based on clinical examination and is supported by sensory nerve conduction (SNC) studies. The initial treatment is always conservative. In limited number of patients who are refractory to conservative managements, surgical treatment via decompression/neurolysis or neurectomy is concerned. There is still no consensus on which surgical technique is the best and the first choice. We retrospectively analyzed the surgical outcomes of 12 nonobese patients who underwent decompression /neurolysis between the years 2013 and 2018. Bilateral SNC studies were performed in all cases which supported the diagnosis. We applied conservative treatments for 3 months in addition to the treatments previously applied in other centers. Surgery was recommended for the patients who were refractory to these treatments. Preoperative and postoperative pain levels during follow-up visits were evaluated with visual analogue scale (VAS). A retrospective analysis was performed on preoperative and postoperative 6th month VAS scores. The mean preoperative VAS value was  $8.75 \pm 0.62$  and the postoperative VAS value at the sixth month was  $1.17 \pm 0.72$ . A significant reduction in the pain was shown ( $p < 0.05$ ). Our surgical results showed that decompression/neurolysis of the LFCN should be concerned as the primary surgical approach to avoid negative outcomes of resection surgeries.

## Keywords

- ▶ meralgia paresthetica
- ▶ lateral femoral cutaneous nerve
- ▶ decompression and neurolysis

## Introduction

Meralgia paresthetica (MP), also known as Bernhardt–Roth syndrome, is a peripheral neuropathy of the primary sensory lateral femoral cutaneous nerve (LFCN). It was first described by Hager in 1885 and more extensively by Bernhardt and Roth

in 1895.<sup>1,2</sup> The LFCN is a purely sensory nerve having no motor function. It is a part of the lumbar plexus, originating from the posterior divisions of the anterior rami of L2 and L3 spinal nerves. Along with some variations in its course, it travels downward lateral to the psoas muscle and obliquely descends along the iliacus muscle by passing under, through or above

**DOI** <https://doi.org/10.1055/s-0040-1715785>  
**ISSN** 2277-954X.

© 2020. Neurological Surgeons' Society of India.

This is an open access article published by Thieme under the terms of the Creative Commons Attribution-NonDerivative-NonCommercial-License, permitting copying and reproduction so long as the original work is given appropriate credit. Contents may not be used for commercial purposes, or adapted, remixed, transformed or built upon. (<https://creativecommons.org/licenses/by-nc-nd/4.0/>)

Thieme Medical and Scientific Publishers Pvt. Ltd., A-12, 2nd Floor, Sector 2, Noida-201301 UP, India

the inguinal ligament, and medially crosses the anterior superior iliac spine (ASIS) at a distance of approximately 1 cm.<sup>3,4</sup> Then, it branches into anterior and posterior divisions that supply the anterior femoral region and lateral femoral region, respectively.<sup>5</sup> This anatomical position explains why MP is frequent in the surgical operations performed around the ASIS. It is a relatively common condition, but diagnosis may be difficult due to poorly localized and vague clinical presentations. Patients present with pain and paresthesia over the anterolateral thigh. The diagnosis is based on medical history and clinical examination findings, which is supported by sensory nerve conduction (SNC) studies.<sup>6</sup> Radiological imaging is especially important to rule out other lumbar or pelvic pathologies. In addition, direct visualization of the LFCN can be made by ultrasonography (US) and magnetic resonance imaging (MRI), particularly magnetic resonance neurography (MRN).<sup>7</sup> The initial treatment is always conservative and most of the patients respond well. In limited number of patients who are refractory to conservative managements, surgical treatment via decompression/neurolysis or neurectomy is concerned. It is still controversial that which surgical technique is superior to the other. The aim of our study is to discuss the results of surgical decompression/neurolysis in our patients with MP, who were refractory to conservative managements.

## Method

In this study, the surgical outcomes of 12 nonobese patients who underwent decompression and neurolysis between the years 2013 and 2018 were retrospectively analyzed (►Table 1). In the diagnosis, pelvic compression test (PCT) and Tinel's sign testing were performed during the course of the physical examination. Direct radiographies of lumbosacral and pelvic region and MRI of lumbar spine were performed to exclude other neurogenic and nonneurogenic causes of pain. Bilateral SNC studies were made in all cases. We applied conservative treatments including nonsteroidal anti-inflammatory drugs (NSAIDs), medications for neuropathic pain like gabapentin, injection of local anesthetic (lidocaine) and corticosteroids and physical therapy for 3 months in addition to the treatments previously applied in other centers. Patients who were candidates for surgical treatment were established by the presence of the following two criteria:

- (a) clinical symptoms lasting more than 3 months despite conservative treatments (permanent pain or paresthesia)
- (b) pathological SNC study

In these patients, nerve blockade test was applied with US-guided injection of the local anesthetic (1% lidocaine, 5–10 mL) at approximately 1 cm inferomedial to the ASIS to confirm the presumed diagnosis of MP. These cases were scheduled for surgical treatment.

## Surgical Method

Surgery was performed in supine position either under general or spinal anesthesia. A vertically oriented 3 cm

skin incision was made below the ASIS over the course of the inguinal ligament and performed down to the fascia lata, which was incised in the same direction. The nerve was exposed, followed proximally to its point of exit from the pelvis and moved medially by incising the ventral layers of the inguinal ligament to decompress the nerve (►Figs. 1 and 2). After achieving complete decompression (►Fig. 3), the subcutaneous tissue was closed with 3–0 vicryl, and skin wound was closed subcutaneously with tekmo poli (glikolid-ko-kaprolakton) suture. All the interventions were performed by the same neurosurgeon. The patients were discharged on the first postoperative day after wound dressing, which was completely removed on the second postoperative day. Mobilization was restricted in the first week. At the end of this time, 30- to 45-minute walks and thigh flexion exercises were allowed for 1 month. Preoperative and postoperative pain levels during follow-up visits from the first to sixth months were evaluated with visual analogue scale (VAS). The existing pain was graded between the end points of "0" (no pain at all) and "10" (pain as bad as it could be) and recorded. A retrospective analysis was performed on preoperative and postoperative sixth month VAS scores. Statistical analysis was made by using the SPSS statistical software version 17.0. In the evaluation of the VAS scores, the paired *t*-test was used. A value of  $p < 0.05$  was considered as statistically significant.

## Results

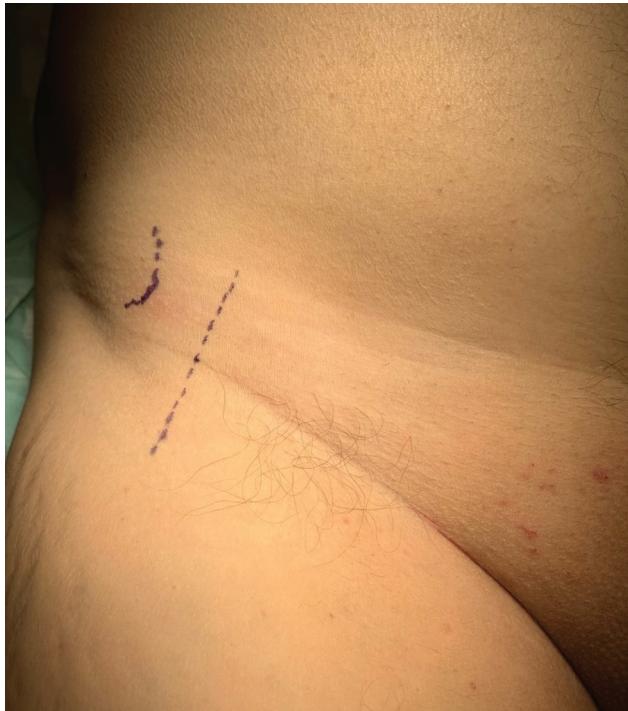A total of 12 surgical decompression/neurolysis of LFCN were performed in 12 nonobese patients with MP who did not respond to conservative approaches. The average age was 39.16 years (range: 25–75 years). There were three females and nine males. The right LFCN was affected in seven (58%) cases and the left LFCN in five (42%) cases. The mean duration of the symptoms was 7.3 months. In their past surgical history, a urological operation, an intracranial operation for traumatic epidural hemorrhage, a lumbar disc herniation surgery, and a lumbar stabilization surgery were present. Severe scoliosis and stress fracture of femoral head on the other side was present in one patient (►Fig. 4). The comorbidities of the patients were hypothyroidism (three cases), Sjogren's syndrome (one case), hypertension (one case), hypercholesterolemia (one case), and epilepsy (one case) (►Table 1). On physical examination, there was hyperalgesia and hypoesthesia accompanying the pain in all of the patients. PCT was positive in 10 cases (83.3%) and Tinel's sign was positive in 11 cases (91.6%). Vasomotor, sudomotor, pilomotor, and trophic changes were not detected. Lasegue and FABER tests were negative. No pathology was observed in deep tendon reflexes of the lower extremity. Subsequent SNC studies were performed with prediagnosis of MP and revealed prolonged LFCN sensory latency and low amplitude, which supported the diagnosis. After decompression and neurolysis, pain recurrence occurred in only one patient in the 4th postoperative month. The complaints were recovered in one month with conservative treatment (Case 4). While six patients (cases 1, 2, 3, 4, 9 and 10) in the 3rd postoperative month and two patients (cases 4 and 10)

**Table 1** Demographic features, physical examination findings, and VAS scores of the patients

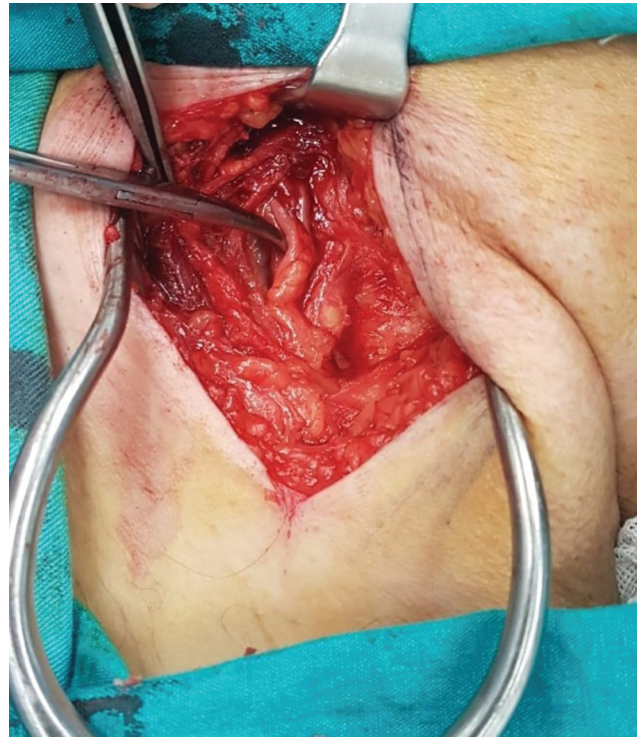Case no	Sex	Age	Side	Symptom duration (month)	Profession	Comorbidity	Sensory loss	Pain	Nerve blockade test	Pelvic compression test	Tinel's sign	VAS (preoperative/ 6th month postoperatively)
1	M	29	R	7	Teacher	Lumbar disc hernia	+	+	+	+	+	10/2
2	M	27	R	8	Self-employed	Epilepsy Thyroid disease	+	+	+	+	+	8/1
3	F	34	R	12	Housewife	Thyroid disease	+	+	+	+	+	9/2
4	F	29	R	6	Flight attendant	Sjogren syndrome	+	+	+	+	+	9/1
5	M	75	L	6	Self-employed	Hypertension and operation for lumbar stabilization	+	+	+	+	+	8/0
6	M	37	L	5	Self-employed	-	+	+	+	+	+	8/0
7	M	58	R	6	Self-employed	Femoral head stress fracture, scoliosis, and hypertension	+	+	+	-	-	9/1
8	M	40	L	12	Self-employed	Operation for traumatic EDH	+	+	+	+	+	9/1
9	M	29	L	8	Self-employed	Hypercholesterolemia	+	+	+	+	+	9/1
10	F	68	R	10	Housewife	Thyroid disease	+	+	+	+	+	9/2
11	M	25	L	4	Self-employed	-	+	+	+	-	+	9/2
12	M	31	R	4	Self-employed	Urological operation	+	+	+	+	+	8/1

Abbreviations: EDH, epidural hematoma; VAS, visual analogue scale.

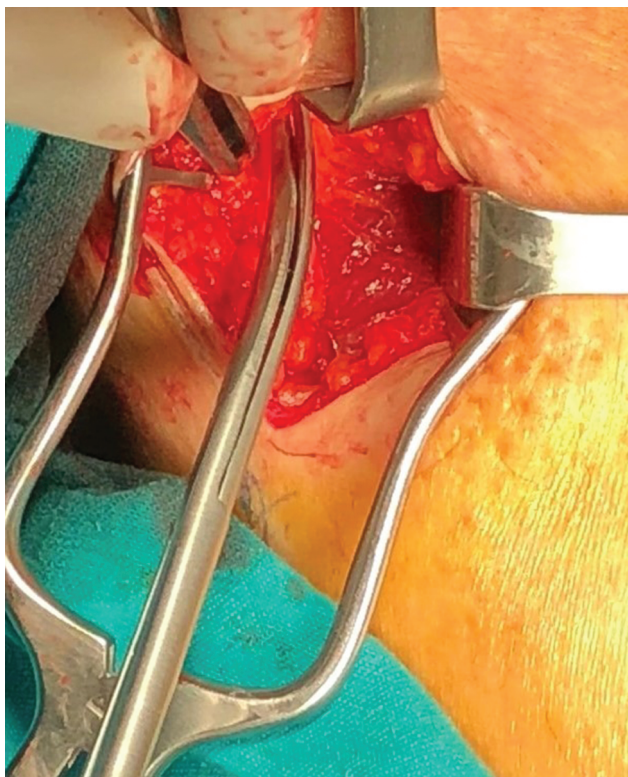




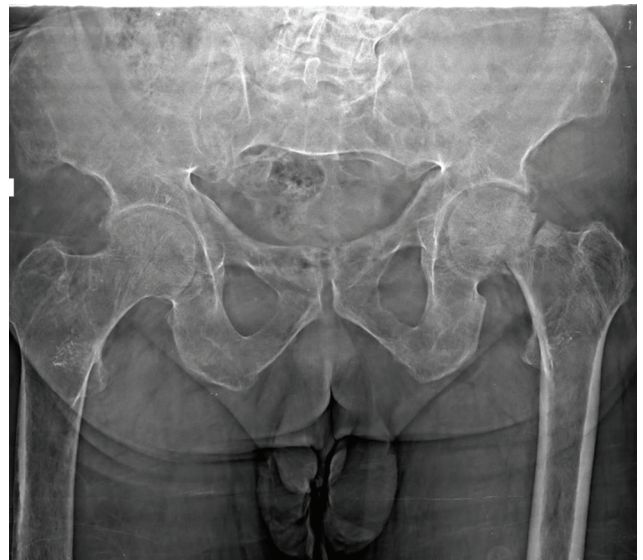**Fig. 1** The skin incision.



**Fig. 3** Decompression of the lateral femoral cutaneous nerve.



**Fig. 2** The incision of the inguinal ligament.



**Fig. 4** The stress fracture of the left femoral head of Case 7.

in the 6th postoperative months had paresthesia, no sensory abnormality or pain was observed until the 12-month follow-up in any patient. The mean preoperative VAS score was  $8.75 \pm 0.62$ , and the postoperative VAS score at the sixth month was  $1.17 \pm 0.72$ . Statistical analysis of the 6th

preoperative and postoperative month VAS scores showed a significant reduction of the pain ( $p < 0.05$ ).

## Discussion

Peripheral entrapment neuropathies occur due to acute or chronic injury to peripheral nerves anywhere along their course but at some regions the risk is greater. In case of MP, the most common scenario is the compression or entrapment of the LFCN as it passes under or through the inguinal ligament.<sup>8</sup> Grossman et al divided MP into two main classifications as



idiopathic or iatrogenic, with a subclassification of idiopathic as mechanical or metabolic.<sup>9</sup> Mechanical factors that may cause MP include obesity (body mass index [BMI]  $\geq 30$ ), pregnancy, tight clothing such as jeans, seat belts and corsets, direct trauma, scoliosis, and leg length differences.<sup>10,11</sup> In one patient of ours, scoliosis and leg shortness were present due to the femoral head stress fracture (Case 7). Traumatic injuries may occur related with acetabular fractures or avulsion fractures of the ASIS. Specific limb positioning such as prolonged sitting or standing may also cause mechanical nerve injury.<sup>12</sup> The sartorius muscle may compress the nerve in dancers when the leg is in the turned out position.<sup>8</sup> Metabolic factors that may be associated with neuropathy like diabetes mellitus, alcoholism, hypothyroidism, and lead poisoning can also be responsible from the situation.<sup>9,11</sup> Iatrogenic MP may occur following spine surgeries as well as hip joint replacement.<sup>13-15</sup> Moreover, bilateral MP may occur as an early postoperative complication in relation with prone positioning following various surgeries.<sup>9</sup> It has also been reported in association with obstetric and gynecological operations, open and laparoscopic appendectomy, and anterior iliac bone harvesting.<sup>16-18</sup> Patients with entrapment neuropathies are expected to present with predictable symptoms related to the injured nerve. In cases of MP, since the LFCN is a pure sensory nerve, there is no motor dysfunction. It manifests with pain and paresthesia in the anterolateral aspect of the thigh, and aggravated on walking, standing and extending the hips. However, indistinct and poorly localized symptoms, sometimes due to variable anatomy of the nerve, may cause confusing clinical presentations that can be difficult to differentiate from other conditions like upper lumbar disc herniation or pelvic pathologies. Detailed medical history and clinical examination is very important, because missed or delayed diagnosis of MP can lead to significant disability. To make differential diagnosis, PCT and Tinel's sign testing are performed in physical examination. In the PCT, the LFCN is compressed by the inguinal ligament and a downward force to the pelvic bones relaxes the ligament, relieving the symptoms temporarily. Its sensitivity and specificity has been found to be 95% and 93.3%, respectively.<sup>19</sup> In our cases, the PCT was positive in 10 (83.3%) patients. The Tinel's sign testing reveals tenderness at the lateral part of the inguinal ligament over the LFCN. Parmer reported that symptoms can be reproduced by administering the Tinel's sign testing over the LFCN in some patients.<sup>20</sup> In our cases, it was positive in 11 (91.6%) patients. In addition, a nerve blockade test (using 1% Lidocaine) can be applied to confirm the diagnosis. The approximate site of injection is 1 cm inferomedial to the ASIS. US guidance is important to prevent potential complications of intervention such as nerve damage, intraneural or intravascular injections.<sup>21</sup> The immediate relief of the pain, which lasts approximately 30 minutes after the injection, confirms the diagnosis.<sup>22</sup> We used the nerve blockade test for diagnostic purpose in all of our patients who were surgical candidates. In addition, SNC studies are frequently used in the diagnosis. However, it is important to note that, like most studies, there are some limitations to perform nerve conduction studies. First, these tests are operator-dependent and are difficult to perform in overweight patients. In all of our patients, prolonged LFCN sensory latency and low-amplitude were established by SNC study.

Radiological imaging of lumbar spine and pelvis with plain radiographs and MRI are used to rule out hip pathologies like osteoarthritis and upper lumbar spine pathologies like disc diseases. In our patients, scoliosis in one case and postoperative findings of previous spine surgeries in two cases were present. Other than these, there was no pelvic or spine pathology that can be described as double crush syndrome. In addition, in the direct visualization of the nerve and assessment of the likely underlying cause of injury, US and MRI, particularly MRN, can also be used. However, detection of direct signs of injury is challenging due to the small size of the nerve. In the initial treatment of MP, preventive measures like avoiding tight clothing and compression activities are recommended. Conservative therapies alleviate the symptoms in most of the patients and include NSAIDs, medications for neuropathic pain like gabapentin, repeated injection of local anesthetic (lidocaine) and corticosteroids, and physical therapy. In the entrapment neuropathies, injections of local anesthetic and corticosteroids may be used to confirm the presumed diagnosis, in order to reduce the acute pain and decrease the use of analgesics. We applied conservative treatments at preoperative period in all of our patients for 3 months in addition to the previous nonsurgical treatments applied in other centers. Persistence or worsening of the complaints causing serious discomfort despite these conservative approaches requires surgical treatment. Several surgical interventions have been developed but the most commonly performed techniques are decompression/neurolysis or neurectomy of the LFCN. Currently, there is no overall consensus on which procedure is the best and both procedures are still under research.<sup>23</sup> Many authors believe that neurectomy is superior to decompression/neurolysis due to better surgical outcomes with no recurrence.<sup>24-26,27,28,29</sup> In neurectomy, complete resolution of symptoms are provided by the resection of LFCN, but there is a risk of denervation pain, and it leaves behind an anesthetic area associated with permanent numbness in the anterolateral thigh.<sup>9,23</sup> In addition, in neurectomy procedure, important aberrant pathways of this nerve may cause difficulty in the surgical localization, and femoral nerve can be dissected incorrectly by assuming LFCN. Neurolysis surgery, on the other hand, is a physiological procedure which maintains the integrity of the nerve. The most important advantage of decompression/neurolysis is the avoidance of the sensory denervation of the anterolateral thigh but it has a higher probability of recurrence.<sup>29</sup> Different studies are present with controversial results on surgical outcomes of neurolysis performed for MP. Some authors believe that neurolysis has a poor long-term outcome and high-recurrence rate.<sup>31</sup> The reason for unsuccessful neurolysis may be inadequate decompression due to anatomical variations. However, many other studies have reported very good results and high-levels of patient satisfaction.<sup>26,28,30-33</sup> Schwaiger et al reported decompression/neurolysis as the primary surgical procedure of choice for the treatment of MP, if the conservative treatment fails.<sup>33</sup> Siu and Chandran reported a series of 45 cases undergoing surgical treatment of MP. They observed complete recovery in 73% of the cases and partial recovery in 20% of the cases among 42 cases of neurolysis that were followed-up for 4.1 years.<sup>32</sup> Our results were also compatible with these studies. In our patients any complication has not

occurred following decompression/neurolysis, and complete relief of symptoms has been achieved at mean 7.3 month post-operatively. We observed only one case of pain recurrence after decompression/neurolysis (1/12, 8.3%). This patient was recovered completely by conservative treatment. Therefore, we believe that neurolysis should be considered at first line as a surgical procedure of choice to prevent negative outcomes of neurectomy, if the nerve has not been severely damaged, in which case neurectomy is concerned. Resection surgery should be considered in the patients whose symptoms do not improve despite long-term follow-up after decompression/neurolysis. In conclusion, MP is a relatively frequent condition but missed or misdiagnosis is more common due to poorly localized and vague clinical presentations. It can mimic more common pathologies particularly associated with upper lumbar spine; therefore, its diagnosis is challenging. The initial treatment should be conservative, but in refractory cases, surgical treatment is needed. There are limited number of studies on surgical treatment of MP and there is no consensus on which surgical method is the best and the first choice. Our surgical results showed that decompression/neurolysis of the LFCN is sufficient as a primary surgical approach. In the patients who did not respond to conservative treatments, decompression/neurolysis should be the primary procedure of choice to avoid negative outcomes of resection surgeries. The most important advantage of decompression is the avoidance of permanent numbness in the sensory areas of the LFCN due to sensory denervation.

#### Funding

None.

#### Conflict of Interest

None declared.

#### References

- Hager W. Neuralgia femoris. Resection des Nerv. cutan. femoris anterior externus. Heilung. Dtsch Med Wochenschr 1885;11:218–219
- Bernhardt M. Ueber Isolirt im Gebiete des N. cutaneous femoris externus vorkommende Parasthesien. Neurol Centrabl 1895;14:242–244
- Dias Filho LC, Valença MM, Guimarães Filho FA, et al. Lateral femoral cutaneous neuralgia: an anatomical insight. Clin Anat 2003;16(4):309–316
- Lee SH, Shin KJ, Gil YC, Ha TJ, Koh KS, Song WC. Anatomy of the lateral femoral cutaneous nerve relevant to clinical findings in meralgia paresthetica. Muscle Nerve 2017;55(5):646–650
- Natsis K, Paraskevas G, Tzika M, Papatheanasiou E. Variable origin and ramification pattern of the lateral femoral cutaneous nerve: a case report and neurosurgical considerations. Turk Neurosurg 2013;23(6):840–843
- Carai A, Fenu G, Sechi E, Crotti FM, Montella A. Anatomical variability of the lateral femoral cutaneous nerve: findings from a surgical series. Clin Anat 2009;22(3):365–370
- Chhabra A, Del Grande F, Soldatos T, et al. Meralgia paresthetica: 3-Tesla magnetic resonance neurography. Skeletal Radiol 2013;42(6):803–808
- Petchprapa CN, Rosenberg ZS, Sconfienza LM, Cavalcanti CF, Vieira RL, Zember JS. MR imaging of entrapment neuropathies of the lower extremity. Part 1. The pelvis and hip. Radiographics 2010;30(4):983–1000
- Grossman MG, Ducey SA, Nadler SS, Levy AS. Meralgia paresthetica: diagnosis and treatment. J Am Acad Orthop Surg 2001;9(5):336–344
- Blake SM, Treble NJ. Meralgia paraesthetica—an addition to 'seatbelt syndrome' Ann R Coll Surg Engl 2004;86(6):W6-7
- Parisi TJ, Mandrekar J, Dyck PJ, Klein CJ. Meralgia paresthetica: relation to obesity, advanced age, and diabetes mellitus. Neurology 2011;77(16):1538–1542
- Donovan A, Rosenberg ZS, Cavalcanti CF. MR imaging of entrapment neuropathies of the lower extremity. Part 2. The knee, leg, ankle, and foot. Radiographics 2010;30(4):1001–1019
- Goulding K, Beaulé PE, Kim PR, Fazekas A. Incidence of lateral femoral cutaneous nerve neuropraxia after anterior approach hip arthroplasty. Clin Orthop Relat Res 2010;468(9):2397–2404
- Gupta A, Muzumdar D, Ramani PS. Meralgia paraesthetica following lumbar spine surgery: a study in 110 consecutive surgically treated cases. Neurol India 2004;52(1):64–66
- Yang SH, Wu CC, Chen PQ. Postoperative meralgia paresthetica after posterior spine surgery: incidence, risk factors and clinical outcomes. Spine 2005;30:47–50
- Yamamoto T, Nagira K, Kurosaka M. Meralgia paresthetica occurring 40 years after iliac bone graft harvesting: case report. Neurosurgery 2001;49(6):1455–1457
- Peters G, Larner AJ. Meralgia paresthetica following gynecologic and obstetric surgery. Int J Gynaecol Obstet 2006;95(1):42–43
- Cheatham SW, Kolber MJ, Salamh PA. Meralgia paresthetica: a review of the literature. Int J Sports Phys Ther 2013;8(6):883–893
- Nouraei SA, Anand B, Spink G, O'Neill KS. A novel approach to the diagnosis and management of meralgia paresthetica. Neurosurgery 2007;60(4):696–700, discussion 700
- Parmar MS. Hiphuggers' tingly thighs. CMAJ 2003;168(1):16
- Aras, B, Adiguzel, E, Tok, F. Lateral femoral cutaneous nerve blockage. Turkj Neurol 2019;25:54–57
- Haim A, Pritsch T, Ben-Galim P, Dekel S. Meralgia paresthetica: A retrospective analysis of 79 patients evaluated and treated according to a standard algorithm. Acta Orthop 2006;77(3):482–486
- de Ruiter GC, Wurzer JA, Kloet A. Decision making in the surgical treatment of meralgia paresthetica: neurolysis versus neurectomy. Acta Neurochir (Wien) 2012;154(10):1765–1772
- Payne R, Seaman S, Sieg E, Langan S, Harbaugh K, Rizk E. Evaluating the evidence: is neurolysis or neurectomy a better treatment for meralgia paresthetica? Acta Neurochir (Wien) 2017;159(5):931–936
- de Ruiter GC, Kloet A. Comparison of effectiveness of different surgical treatments for meralgia paresthetica: Results of a prospective observational study and protocol for a randomized controlled trial. Clin Neurol Neurosurg 2015;134:7–11
- Emamhadi M. Surgery for meralgia paresthetica: neurolysis versus nerve resection. Turk Neurosurg 2012;22(6):758–762
- Holanda MM, Meira UM, Magalhaes FN, da Silva JA. Surgical treatment of meralgia paresthetica: a case report. Arq Neuropsiquiatr 2003;18:132–135
- Ataizi ZS, Ertlav K, Ercan S. Surgical options for meralgia paresthetica: long-term outcomes in 13 cases. Br J Neurosurg 2019;33(2):188–191
- van Eerten PV, Polder TW, Broere CA. Operative treatment of meralgia paresthetica: transection versus neurolysis. Neurosurgery 1995;37(1):63–65
- Ducic I, Dellon AL, Taylor NS. Decompression of the lateral femoral cutaneous nerve in the treatment of meralgia paresthetica. J Reconstr Microsurg 2006;22(2):113–118

- 31 Nahabedian MY, Dellon AL. Meralgia paresthetica: etiology, diagnosis, and outcome of surgical decompression. *Ann Plast Surg* 1995;35(6):590–594
- 32 Siu TL, Chandran KN. Neurolysis for meralgia paresthetica: an operative series of 45 cases. *Surg Neurol* 2005;63(1):19–23, discussion 23
- 33 Schwaiger K, Panzenbeck P, Purschke M, et al. Surgical decompression of the lateral femoral cutaneous nerve (LFCN) for Meralgia paresthetica treatment: Experimental or state of the art? A single-center outcome analysis. *Medicine (Baltimore)* 2018;97(33):e11914