

# Arrowhead Injury of Central Nervous System: Three Rare Cases from Rural India

Viraat Harsh<sup>1\*</sup> Hemant Alda<sup>1\*</sup> Shashwat Singh<sup>1</sup> Jayendra Kumar<sup>2</sup> Chandra B. Sahay<sup>1</sup> Anil Kumar<sup>1</sup>

<sup>1</sup>Department of Neurosurgery, Rajendra Institute of Medical Sciences, Ranchi, Jharkhand, India

<sup>2</sup>Department of Neurosurgery, Anugrah Narayan Magadh Medical College, Gaya, Bihar India

**Address for correspondence** Anil Kumar, MBBS, MS, MCh, Department of Neurosurgery, Rajendra Institute of Medical Sciences, Ranchi, Jharkhand 834009, India (e-mail: dr.anilkumarranchi@gmail.com).

Indian J Neurotrauma

## Abstract

A penetrating central nervous system (CNS) injury on account of an arrowhead is a rarity in the modern era. When managing such cases surgically, special care is taken to prevent injury to the neurovascular structures lying in the vicinity of the wound. Fired arrows are categorized as low-velocity missiles, but the size, shape and aerodynamic stability of the missile are also important factors in establishing the complexity of the wound. We present three such cases of penetrating injury of the CNS by fired arrows, two injuring the head and the third injuring the spinal cord. The arrowheads were successfully retrieved without any complications. Salient features to be taken care of while managing such patients have also been discussed.

## Keywords

- ▶ arrow injury
- ▶ penetrating injury
- ▶ missile injury

## Introduction

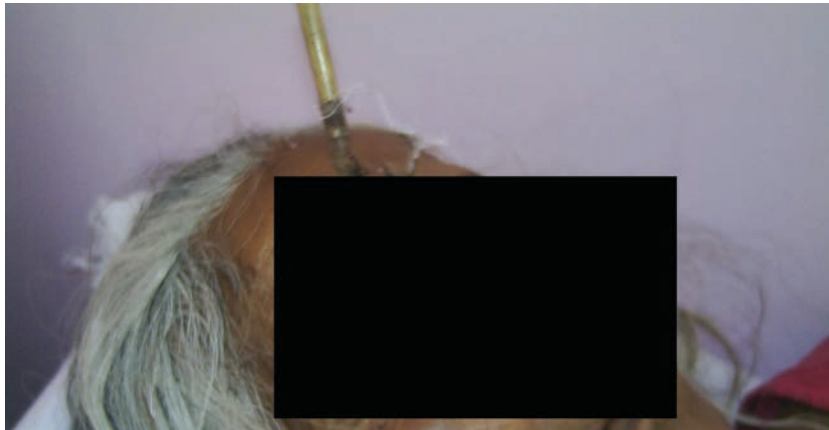
Since the advent of modern era weapons and artillery, penetrating injuries by old world missiles, such as arrows, lances and spears have only been rarely reported in the medical literature, especially in the Western world. Few cases of arrowhead injuries have however been reported from the Indian subcontinent, especially from the tribal areas. Very few of these cases describe central nervous system (CNS) injuries caused by fired arrows. Arrowhead injuries depend on the type of bow and arrow used. An important determinant of severity of injury caused by an arrow, as of any other missile injury, is the velocity of the missile. The average velocity of a bow-fired arrow is approximately 60 to 90 m/s.<sup>1</sup> The extent of injury and soft and bony tissue destruction also depend on the size, shape and aerodynamic stability of the arrow. We report three cases of arrowhead injury of the head and spine and discuss their management.

## Case 1

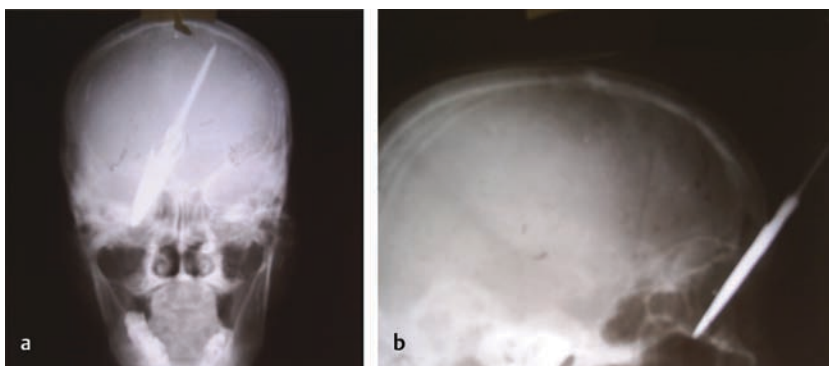
A 65-year-old female presented to our emergency room following penetrating trauma to her head by an arrow fired

by her psychotic son. She complained of pain at the site of injury and nasal bleeding. There was no history of loss of consciousness, vomiting or convulsions. On initial examination, she was conscious with a Glasgow coma scale (GCS) score of E4V5M6 and stable vitals. An arrowhead was impacted on the forehead 5 cm above the nasion, lateral to the midline on the right, with the direction of impact being downward, laterally and toward the posterior (▶**Fig. 1**). Ophthalmological examination and complete neurological assessment were unremarkable. An emergency bedside X-ray of the skull revealed the orientation and trajectory of the foreign body sparing the brain parenchyma (▶**Fig. 2**), which was later confirmed on a CT scan of the head. Surgery was offered to the patient and her family, to which they agreed. A regional craniectomy was performed around the site of penetration to permit the arrow free from the bone and facilitate its gentle extraction in the line of its trajectory, following which the wound was inspected under direct vision for any bleeding or cerebrospinal fluid (CSF) leak. Extended craniectomy revealed a breached dura. Duroplasty was performed with autologous tensor fascia lata graft, and the wound was closed in layers after securing hemostasis. The postoperative period was uneventful. The patient received broad-spectrum antibiotics and was discharged on the ninth day postoperatively. At 6 months follow-up after surgery, the patient was asymptomatic and clinically normal.

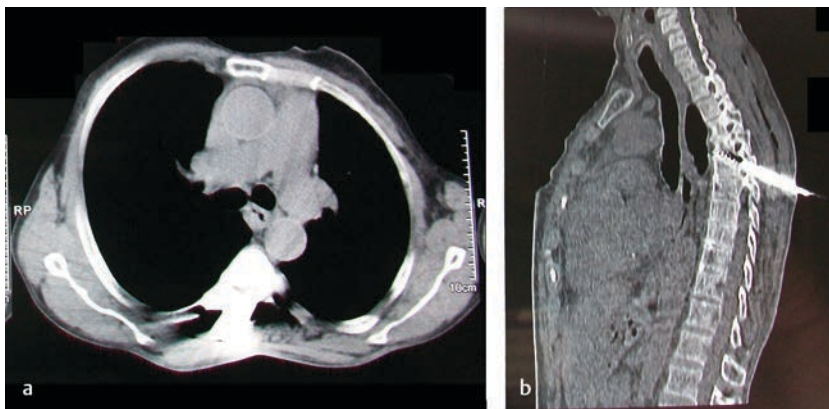
\* These authors contributed equally to this work.



**Fig. 1** Figure showing arrow injury of the forehead.



**Fig. 2** X-rays showing arrow injury and its trajectory in the head. (a) AP view. (b) Lateral view.

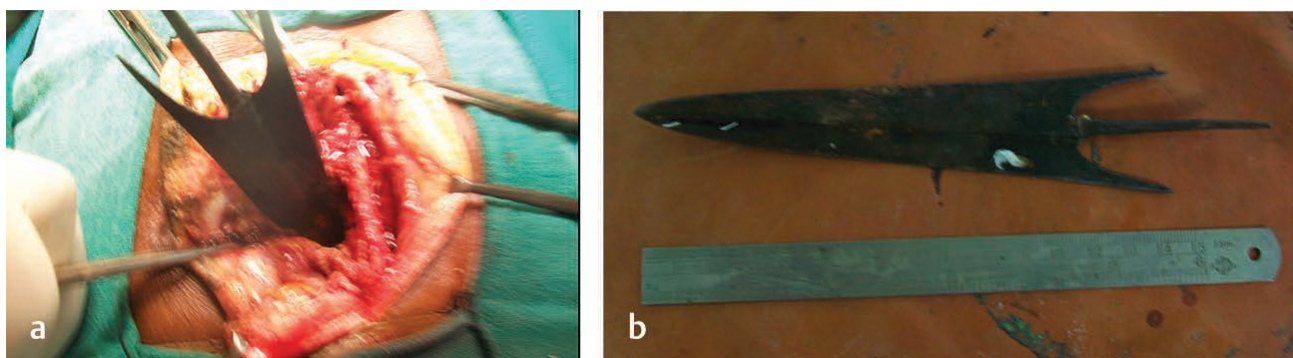


**Fig. 3** CT scan showing arrow injury and its trajectory in the back. (a) Axial view. (b) Sagittal view.

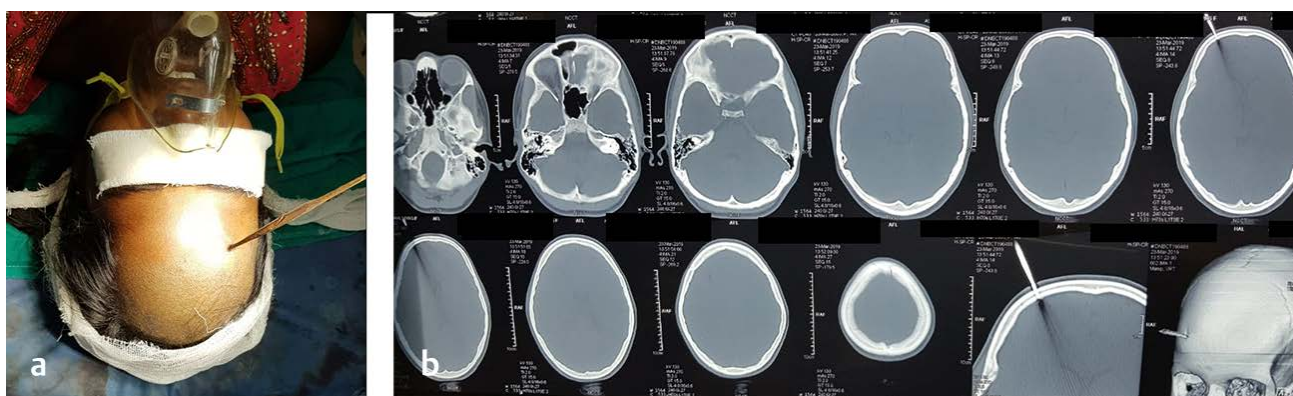## Case 2

A 70-year-old male came to our emergency room following penetrating trauma to the upper back by an arrow that was fired by his relative over a family dispute. On examination, the patient was conscious (GCS E4V5M6) with stable vitals. An arrowhead was seen impacted on the upper back, 3 cm from the midline, on the right side, and at the level of D4–D5 vertebrae, with the direction of the impact being medially and anteriorly toward the cord. On examination, power in both lower limbs was Grade 0/5, tone was increased, all

reflexes in lower limb were exaggerated, and plantar bilaterally upgoing. Sensation below the xiphisternum was absent bilaterally. Position and vibration sense in lower limbs were absent. Bladder and bowel incontinence were present. CT scan of thoracic spine (►Fig. 3) demonstrated the trajectory of foreign body and the extent of trauma to the spinal cord. With consent of the patient and his family members, he was taken up for immediate removal of the offending arrow. Following a midline skin incision at the back from D2–D6 (►Fig. 4a), paraspinal muscles were separated and the arrowhead was visualized to be impacting the bony lamina



**Fig. 4** (a) Figure showing intraoperative photograph of spine arrow injury. (b) Figure showing extracted arrowhead.



**Fig. 5** (a) Figure showing photograph of arrowhead injury over the forehead. (b) CT scan showing arrow injury piercing the right frontal bone.

at the level of D4–D5, subsequent to which laminectomy was performed to make it free from the bone for gentle extraction of the arrowhead in its line of trajectory (► **Fig. 4b**). The wound was inspected under direct vision. Dura and underlying spinal cord were found to be damaged with no active bleeding; however, CSF was seen leaking through the compromised dura. After thorough irrigation with normal saline, the dura was repaired in water-tight fashion and the wound was closed in layers. The postoperative period was uncomplicated, and the patient was discharged with Foley's catheter in situ on the 11th postoperative day with Grade ½ power in both lower limbs and hyperesthesia. Follow-up after 6 months showed improved power to Grade ¾ in both lower limbs, but bladder and bowel incontinence persisted.

### Case 3

A 14-year-old female came to our emergency room following penetrating trauma by an arrow fired during play (► **Fig. 5a**). She was conscious (GCS E4V5M6). There was no history of loss of consciousness or seizures. The patient, however, had vomited twice after the injury. On examination, the arrow was seen penetrating the skull over the right frontal region. CT scan of the brain showed that the arrow was in the right frontal bone not piercing the dura (► **Fig. 5b**). The brain parenchyma was normal. The patient was taken to the operating room for removal of the arrow. Under local anesthesia and sedation, the arrowhead was pulled out through

a narrow craniectomy. The wound was cleaned with hydrogen peroxide and betadine, and the skin was closed in layers. The postoperative period was uneventful, and the patient was discharged the following day. The patient was conscious at the time of discharge and without any neurodeficit. The patient came for follow-up for 6 months.

### Discussion

Arrow injuries are an extinct mode of injury in the Western world but off and on it is encountered in the tribal areas of India, sometimes unintentional while hunting, and quite often charged on purpose, but also merely while playing, as was seen in one of our cases. A rare case of suicide by arrowhead has also been reported.<sup>2</sup> Most of the arrow injuries involve the thorax and abdomen.<sup>3</sup> Arrow injuries to head are rare and mostly involve the face.<sup>1,4</sup> However, those involving the CNS are fairly uncommon, although a few cases have been reported.<sup>5-7</sup>

The mechanism of injury caused by fired arrow is similar to injuries caused by low-velocity missiles. Arrows have a considerable penetrating capacity in soft tissue and flat bones. Arrow injuries are usually less destructive than those caused by high-velocity missiles because of their lower velocity and energy. Barbed arrows are an exception because of the risk of extensive damage to major structures when retrieved.<sup>8</sup> An arrow injury to the brain may be considered intermediate between a gunshot wound and stab wound. Size, shape,

aerodynamic stability, and velocity of the missile are important factors which decide the severity of injuries by arrows. The size of the arrow in the second case was 17 cm and it had penetrated the spinal cord to a depth of 10 cm (► Fig. 4b). In the first case, 6 cm of the arrowhead had penetrated the skin. In the third case, the arrow had penetrated the frontal bone but had not crossed the inner table.

Radiography of the skull is helpful in demonstrating the intracranial course of metallic materials, but the radiodensity of wood is nearly the same as that of soft tissue and the brain, so it can be difficult to detect.<sup>9</sup> CT is valuable for detecting wooden foreign bodies as hypodense mass.<sup>10</sup> Wooden bodies also appear hypodense on T1- and T2-weighted MR imaging.<sup>11</sup> However, it has also been observed that the CT and MR imaging properties of a wooden foreign body can change in vivo after a long period of intraparenchymal retention.<sup>12</sup> However, in most cases, a CT scan would provide valuable information about the course of injury and the depth of penetration of the arrowhead. There is a report about an unusual head trauma in an adult due to an accidental pressure cooker explosion, where the patient did not have any focal neurological deficit but had experienced debilitating headache and multiple episodes of vomiting.<sup>13</sup> A pneumocephalus was seen on CT, and the consequent raised intracranial tension was deemed responsible for the presenting symptoms, which subsided over 2 days along with the resolution of the air pocket as confirmed by a repeat CT. Such complications might also accompany a penetrating injury of the brain, and their presence on a CT could provide an answer for the accompanying symptoms of headache and/or vomiting.

CT angiography of brain helps to evaluate the extent of cerebrovascular trauma. Injuries such as arterial dissection, pseudoaneurysm, arterial or venous thrombosis and arteriovenous fistula can be successfully identified and repaired.<sup>14</sup> If vascular injury is suspected, a CT angiography will be life-saving. An arrow should never be removed from a patient, irrespective of stability, unless injury to major vessels has been ruled out.<sup>15</sup> It may be emphasized that arrow removal is not suggested unless in an emergency trauma care facility. Prompt extraction is advised only under direct vision, keeping in mind the tamponade effect which may be encountered by the major vessels that may then subsequently bleed.

Management of arrow injury to the CNS should aim at prevention of infection, exploration for potential dural tears, and subsequent CSF loss, leading to intracranial hypotension and minimizing the secondary injuries that may be caused by the missile. The patient should be immobilized well before and during the transfer to a hospital, especially if the arrow is unstable. Another important strategy is early extraction of arrowhead to minimize neurological deficits but should be removed only at a center where adequate facilities to control hemorrhage are available.<sup>6</sup> Arrow injuries are reported to have 1.4% infection rate.<sup>3</sup> Broad-spectrum antibiotic coverage is instituted to prevent infection.

Another complication of penetrating brain injury is the occurrence of posttraumatic seizures. The incidence of posttraumatic seizure is higher in penetrating brain injuries than

with closed brain injuries and occurs in over 50% penetrating trauma cases over a follow-up period of 15 years.<sup>16</sup> Hence, patients must be informed about the possibility, and a proper plan for regular follow-up should be discussed with them.

Speech problems may also occur as a part of penetrating brain injuries. There was a case which consisted of a man presenting with an arrow lying in the brain at the left parieto-occipital region through the right frontal lobe accompanied with intraparenchymal hematoma<sup>7</sup>. He had motor aphasia at presentation which persisted after the surgical removal of the arrow. Once intracranial vascular injuries were ruled out by MR angiography, he was discharged on the second week of the event with severe motor aphasia. With the help of intensive speech therapy, he had begun to talk in the first month by using simple words. So, a consultation with a speech therapist can be considered to treat any difficulty with speech the patient might experience postoperatively.

Pediatric age group patients are more prone to secondary brain insult, requiring better attention and timely intervention. They are more susceptible to the secondary insult of brain from low-oxygen saturation, fluid imbalances, electrolyte disturbances, fever, and seizures requiring special care.<sup>17</sup> Factors affecting the good outcome are amount of contamination, presence of dural breach, trauma-surgery time gap, quality of wound debridement, and appropriate and timely antibiotic and antiepileptic medication.<sup>18-20</sup>

#### Authors' Contributions

V.H. and J.K. conceptualized the article. V.H., S.S., H.A., and J.K. gathered the data. All the authors revised the article and approved the final draft of the article that was submitted. C.B.S. and A.K. provided guidance toward the completion of the article.

#### Funding

None.

#### Conflict of Interest

None declared.

#### References

- O'Neill OR, Gilliland G, Delashaw JB, Purtzer TJ. Transorbital penetrating head injury with a hunting arrow: case report. *Surg Neurol* 1994;42(6):494-497
- Řehulka H, Čechová E, Mottlová J, Valenta M, Mareška Z. [Fatal head injury caused by a crossbow arrow with unusually preserved posttraumatic volitional activity - case report]. *Soud Lek* 2016;61(1):2-4
- Madhok BM, Roy DD, Yeluri S. Penetrating arrow injuries in Western India. *Injury* 2005;36(9):1045-1050
- Jha AK, Kumar J, Harsh V, Kumar A. Penetrating injury of the posterior cranial fossa by a stone. *Neurol India* 2016;64(5):1081-1082
- Paramhans D, Shukla S, Batra A, Mathur RK. Successful removal of an impacted metallic arrowhead penetrating up to the brainstem. *J Emerg Trauma Shock* 2010;3(3):303
- Geissinger G, Magid GA, McMahon RC. Arrow trauma to cervical spine. *WMJ* 2009;108(4):197-199
- Kurt G, Börcek AO, Kardeş O, Aydıncak O, Ceviker N. Transcranial arrow injury: a case report. *Ulus Travma Acil Cerrahi Derg* 2007;13(3):241-243

- 8 Jacob OJ. Penetrating thoracoabdominal injuries with arrows: experience with 63 patients. *Aust N Z J Surg* 1995;65(6): 394–397
- 9 Ginsberg LE, Williams DW, III, Mathews VP. CT in penetrating craniocervical injury by wooden foreign bodies: reminder of a pitfall. *AJNR Am J Neuroradiol* 1993;14(4):892–895
- 10 Hansen JE, Gudeman SK, Holgate RC, Saunders RA. Penetrating intracranial wood wounds: clinical limitations of computerized tomography. *J Neurosurg* 1988;68(5):752–756
- 11 Ho VT, McGuckin JF Jr, Smergel EM. Intraorbital wooden foreign body: CT and MR appearance. *AJNR Am J Neuroradiol* 1996;17(1):134–136
- 12 Ishikawa E, Meguro K, Yanaka K, et al. Intracerebellar penetrating injury and abscess due to a wooden foreign body—case report. *Neurol Med Chir (Tokyo)* 2000;40(9):458–462
- 13 Kumar M, Harsh V, Jha S, Prakash A, Kumar A, Sahay CB. An unusual case of head injury by pressure cooker explosion. *Int J Med Sci Innovat Res* 2018;3(2):152–154
- 14 Bula WI, Loe DJ. Trauma to the cerebrovascular system. *Neuroimaging Clin N Am* 1996;6:607–624
- 15 Peloponissios N, Halkic N, Moeschler O, Schnyder P, Vuilleumier H. Penetrating thoracic trauma in arrow injuries. *Ann Thorac Surg* 2001;71(3):1019–1021
- 16 Temkin NR, Dikmen SS, Winn HR. Post traumatic seizures. *Neurosurg Clin N Am* 1991;2:425–435
- 17 Kumar J, Prakash A, Harsh V, Kumar A. Elevated fracture of skull in pediatric age group: A series of five patients with review of literature. *Asian J Neurosurg* 2016;11(1):75
- 18 Harsh V, Prakash A, Gupta U, Kumar J, Kumar A. Depressed fracture of the skull – an institutional experience of 453 patients. *Asian J Neurosurg* 2018; 13:222–6
- 19 Harsh V, Vohra V, Kumar P, Kumar J, Sahay CB, Kumar A. Elevated skull fractures- too rare to care for, yet too common to ignore. *Asian J Neurosurg* 2019; 14:237–9.
- 20 Harsh V, Besra SK, Kumar J, Kumar A. A curious case of spontaneously resolving closed 'jigsaw' depressed skull fracture in an adolescent. *Asian J Neurosurg* 2016; 11:109–10