Modified Continuous Irrigation Suction System as A Tool in Limb Salvage with Impending Implant Exposure and Eschar

Rajan Ganapathy Bhagavathi[1] Jijo Joseph[1] Harikrishna Muram Reddy[1] S. Raja Sabapathy,[2] Mayil Vahanan Natarajan[3] Smriti Nathani[1]

[1]Department of Plastic Surgery, Apollo Cancer Speciality Hospitals, Teynampet, Chennai, India
[2]Division of Plastic Surgery, Hand Surgery, Reconstructive Microsurgery and Burns, Ganga Hospital, Coimbatore, India
[3]No. 4, Lakshmi Street, Kilpauk, Chennai, Tamil Nadu, India

Address for correspondence Dr. G. B. Rajan M.S. (Gen.), DNB (Plastic Surgery), Senior Consultant, Department of Plastic Surgery, C Block, Second floor, Apollo Cancer Speciality Hospitals, Teynampet, Chennai- 35, India (e-mail: rajangb@gmail.com).

Indian J Plast Surg:2020;53:313–314

We report a successful limb salvage using a modified continuous irrigation system (CIS) to maintain an infection-free interval of 3 months for an exposed implant. Multiple attempts of primary cover had failed before the successful cover was achieved.

A 10-year-old girl with osteosarcoma of the left tibia, following neoadjuvant chemotherapy, underwent wide resection of osteosarcoma of the knee joint, tibia, ankle joint, and middle third of fibula. For limb salvage procedure, a titanium custom megaprosthesis (CMP) for the tibia, and soft-tissue cover with pedicled medial gastrosoleus muscle flap cover and skin closure were done. Unfortunately, the patient developed skin necrosis, causing exposure of the implant. (►**Fig. 1 a**). This was debrided and covered with a large microvascular (ALT) anterolateral thigh myocutaneous flap at the end of 3 weeks. A concurrent CIS system was applied based on stream flow (SF) theory, in that if the local environment of any wound is irrigated continuously and the excess drained off, the risk of infection can be mitigated significantly. Three days later, a 30 cm^2 area of the distal end of the flap also became nonviable (►**Fig. 1 b**). This was debrided and covered with a superiorly based lateral malleolar flap after an interval delay. The business end of this, too, turned nonviable but was retained as a biological dressing (►**Fig. 1c**).

The problem of frequent blockages of the 16G drain tube, due to the vacuum drying of the exudate particles in the setting of long duration of the CIS system, was solved by introducing a third (Flushing) 7 size tube into the mouth of the 16G (Suction) tube of the CIS system from a direction diagonally opposite, with a 3 cm lumen-to-lumen overlap and through a separate percutaneous incision (►**Fig. 2**). This was based on the principle that a blocked drain tube cannot be unblocked by any further amount of suction pressure nor should it be flushed from outside for fear of introducing infection. This tube was flushed with 20 mL of saline every 48 hours under aseptic precautions.

Finally, successful skin cover for the implant was achieved by a "cross-leg flap" executed in three stages of delay, transfer, and division for the residual defect (►**Figs. 3 a, b**). The patient was discharged with the ability to ambulate with a walker frame and do partial weight-bearing in 3 months. During this protracted course, there was no obvious discharge from the wound and infection. Periodic wound cultures did not show any growth. We attribute this to the administration of the modified CIS system as an interim measure until flap cover

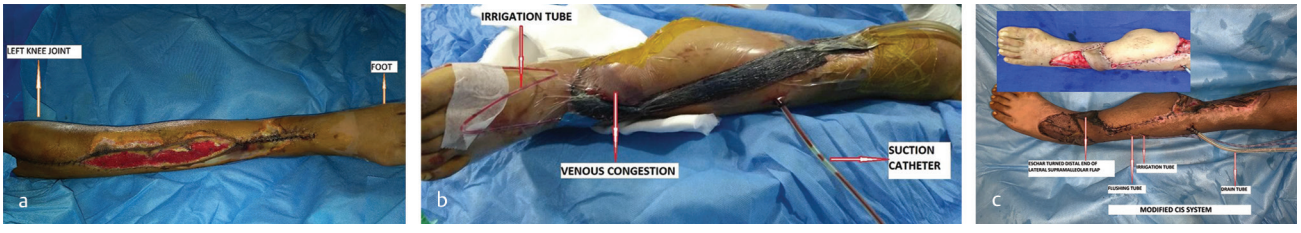

Fig. 1 (**a**) Marginal necrosis along suture line. (**b**) Venous congestion of distal end of anterolateral thigh (ALT) flap. Irrigation and suction tubes can be noted. (**c**) Eschar turned distal end of lateral supramalleolar flap. Irrigation, suction, and flushing tubes can be noted

published online
August 29, 2020

DOI https://doi.org/10.1055/s-0040-1716441
ISSN 0970-0358.

©2020 Association of Plastic Surgeons of India

License terms

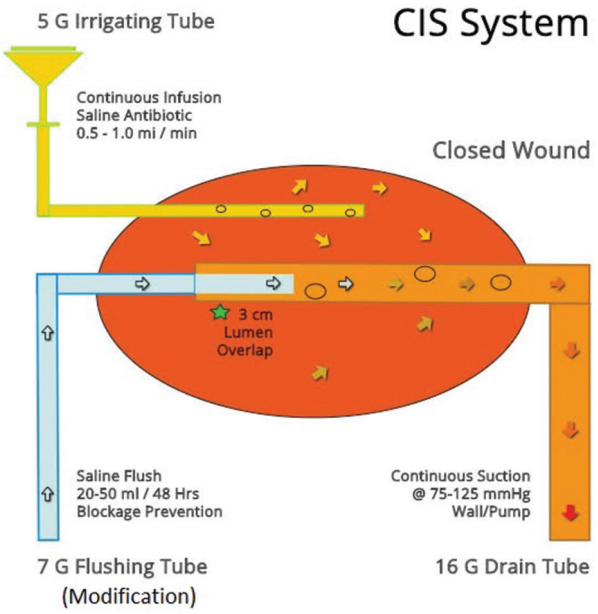

Fig. 2 Schematic diagram of modified continuous irrigation suction (CIS) system.

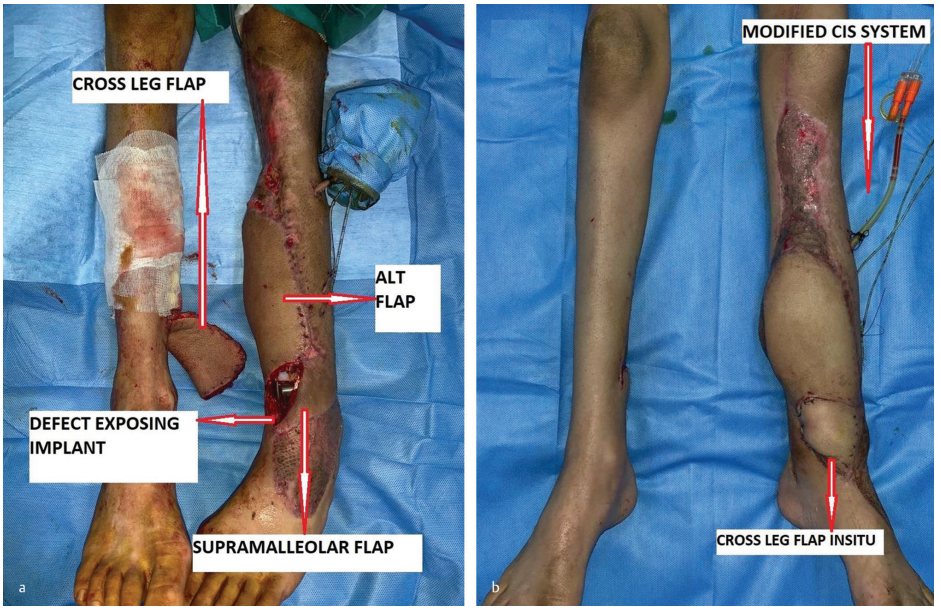

Fig. 3 (**a**) Cross-leg flap before inset. Note the defect exposing the implant. (**b**) Final appearance after division of cross-leg flap with the modified continuous irrigation suction (CIS) in situ.

was finalized. A similar concept has been used in managing abdominal abscess.[1]

It is our opinion that a wound environment can be maintained infection-free for a prolonged period by the inclusion of an interim modified CIS system in the treatment protocol, even in a scenario of an impending implant exposure or the presence of eschar in its vicinity. This study conforms to the Declaration of Helsinki.

Conflict of Interest

None declared.

Reference

1. Tribble DE. An improved sump drain-irrigation device of simple construction. Arch Surg 1972; 105(3):511–513 PubMed