

Z-POEM as a Treatment Option for Zenker's Diverticulum: Our Experience at a Tertiary Care Centre in India

Pankaj N. Desai¹ Mayank V. Kabrawala¹ Chintan N. Patel¹ Rajiv M. Mehta²
Subhash K. Nandwani² Ritesh Prajapati² Nisharg Patel² Krishna K. Parekh³

¹Department of Endoscopy and Endosonography, Surat Institute of Digestive Sciences (SIDS), Surat, Gujarat, India

²Department of Gastroenterology, Surat Institute of Digestive Sciences (SIDS), Surat, Gujarat, India

³Department of Clinical Research, Surat Institute of Digestive Sciences (SIDS), Surat, Gujarat, India

Address for correspondence Pankaj Desai, MS, FASGE, FAIGE, Department of Endoscopy and Endosonography, Surat Institute of Digestive Sciences (SIDS), Majura Gate, Ring Road, Surat 395002, Gujarat, India (e-mail: drp_desai@hotmail.com).

J Digest Endosc:2020;11:209–214

Abstract

Background This study was aimed to evaluate efficacy and safety of Z-peroral endoscopic myotomy (Z-POEM; submucosal tunneling endoscopic myotomy) for Zenker's diverticulum (ZD).

Methods This is a retrospective study at a single tertiary care center in India. The Z-POEM technique was performed using principles of submucosal tunneling endoscopy with prior experience from POEM technique for achalasia cardia

Results Sixteen patients (male, 62.5%; mean age, 73.2 ± 5.2 years) were included with a mean Charleson's comorbidity index of 4.32. The mean size of ZD was 34.8 ± 10.0 mm. The technical success rate was 100%. Clinical success was achieved in 100% (16/16) with a decrease in mean dysphagia score from 2.9 to 0.2 ($p < 0.0001$). The mean procedure time was 47 ± 7.9 minutes and mean length of septotomy was 31.9 ± 9.4 mm. The mean length of hospital stay was 1.2 ± 0.4 days. No major adverse events were noted. Capnomediastinum was noted in two cases on follow-up Gastrografin study after 24 hours (12.5%). This did not merit any treatment. One patient had intraprocedural bleed which was controlled easily. At the 18-month follow-up, two (12.5%) patients reported dysphagia recurrence (Dakkak and Bennett score 1) but did not require repeat intervention.

Conclusion Endoscopic management of ZD using the POEM technique is a promising technique with improved efficacy and safety. However, long-term follow-up is needed to ensure the durability of response.

Keywords

- ▶ septotomy
- ▶ submucosal tunneling endoscopy
- ▶ Zenker's diverticulum
- ▶ Z-POEM

Introduction

Zenker's diverticulum (ZD) is a sac-like outpouching of the mucosa and submucosa through Killian's triangle, an area of muscular weakness between the transverse fibers of the cricopharyngeus muscle and the oblique fibers of the lower inferior constrictor (i.e., thyropharyngeus) muscle. ZD is actually a "false" diverticulum or a pseudodiverticulum.

The reported prevalence of ZD is between 0.01 and 0.11%.^{1,2} However, this is likely an underestimate as patients with diverticulum may be asymptomatic. Symptomatic ZD is male predominant (ratio = 1:5) and typically seen in middle-aged adults and older adults in their seventh or eighth decade of life.^{2,3} Small diverticulum can be asymptomatic. Transient oropharyngeal dysphagia in patients with ZD may be noted early in the course.



With large diverticulum, the patient may complain of dysphagia, halitosis, gurgling in the throat, appearance of a mass in the neck, or regurgitation of food into the mouth. Marked weight loss and malnourishment can occur in patients with longstanding dysphagia.^{2,4} Patients with ZD are normally diagnosed on gastroscopy or a barium swallow study because of the symptoms.⁵ Treatment options include open surgery or transoral rigid or flexible endoscopy and are aimed at eliminating the functional outflow obstruction and restore continuity at the pharyngoesophageal junction through septotomy with or without resection of the diverticulum.^{5,6} Standard endoscopic septotomy is highly successful with symptom recurrence in 11 to 30%. ZD can be treated with peroral endoscopic myotomy (Z-POEM) with data showing a feasibility of 87.5% and clinical improvement of 100%. Potential advantages over standard endoscopic septotomy is complete septum division, decreasing the risk of symptom recurrence.^{7,8,9,10}

Methods

This is a single-operator, single-center retrospective study. All patients from February 2017 to January 2020, who diagnosed as having symptoms due to ZD and consented for Z-POEM procedure, were included in this study. The diagnosis was based on oral contrast barium bolus study or contrast-enhanced computed tomography (CECT) scan and confirmed by esophagogastroduodenoscopy. After an informed consent and preoperative assessment, the patients were admitted for Z-POEM procedure. Dakkak and Bennet dysphagia score was used to quantify dysphagia. (0, no dysphagia; 1, dysphagia to solids; 2, dysphagia to semisolids; 3, dysphagia to liquids; and 4, complete dysphagia).¹¹

The following characteristics were noted: demographics; size of the diverticula; symptoms; Charleson's comorbidity index (CCI),¹² prior surgical interventions; technical success; procedure time; length of hospital stay (LOS); number of repeat procedures; clinical success; symptom recurrence at 3, 6, 12, and 18 months; need for surgery; and adverse events graded according to the American Society for Gastrointestinal Endoscopy (ASGE) lexicon¹³ (► **Table 1**).

Procedure Technique

All procedures were done under general anesthesia with endotracheal intubation. Patients were placed in the supine or left lateral position depending on the septum coming vertical. A high-definition flexible upper gastrointestinal endoscope (GIF-HQ 190, Olympus, Japan) with magnification capabilities, fitted with a clear cap was used in all patients. The flexible endoscope was carefully advanced across the narrow and thin hypopharynx and into the esophagus. The entire esophagus was examined. After the initial examination, a thorough cleaning of the diverticulum was performed, if required using sterile 0.9% saline. Intravenous antibiotics were administered to all the patients as per protocol. We used a third-generation cephalosporin in all cases. Carbon dioxide (CO₂) on low flow setting was used during all procedures.

Table 1 Characteristics of study population

Characteristics	n = 16
Age (y)	73.2 ± 5.2
Male (n)	10 (62.5)
Mean size of Zenker's diverticula (mm)	34.8 ± 10.0
Mean length of septotomy (mm)	31.9 ± 9.4
Mean procedure time (min)	47.4 ± 7.9
Clinical success (n)	16 (100)
Complete resolution of the diverticulum on Gastrografin study	12 (75)
Adverse events	2 (12.5%)
Mean hospital stay (d)	1.2 ± 0.4

Abbreviation: SD, standard deviation.

Notes: Patient's characteristics.

Values presented as mean ± SD or n (column %).

The length of the septum was measured using the following technique. The proximal extent of the septum was marked with a tape on the scope at the level of the mouth-piece. The scope was then passed to the distalmost end of the diverticulum and another tape applied on the scope at that level and the length measured between the two marks. The length of the septotomy was planned to reach till the proximally marked tape, and we could achieve septotomy almost till the base of the diverticulum. We could have done away with the tape and a visual confirmation was usually good enough to see that we had reached the base of the diverticulum. The tape just provided us additional accuracy in measurement for the study.

A mucosal bleb is created 2-cm proximal to the septum using 5 to 10 mL of a mixed solution of 1% indigo carmine and normal saline. We used an estimate of 10 drops indigo carmine in 50 mL 0.9% normal saline. The mucosal bleb was created in line of the septum trying to avoid going on the sides, as there is always a chance to get lost in the tunnel once we are inside. A 1.5-cm mucosal incision is performed along the long axis of the septum with a triangular tip endoscopic submucosal dissection knife (KD 640 L, Olympus) using Endo-Cut Q current, effect 2, cut duration 3, and cut interval 3 (ERBE VIO 300 D, Tubingen, Germany). The submucosal space is entered by undermining the margins of the incision creating space for the cap to fit in. Submucosal tunneling is then performed with the same knife using forced coagulation, effect 2. The tunneling is advanced to reach the septum. Sometimes it is possible to get lost in the tunnel and to deviate away from the septum. To avoid this, we usually come out of the tunnel, identify the septum, and direct the tunneling to the correct side. Once the septum is reached, tunneling is extended on both sides of the septum, that is, the diverticular side and the esophageal side. We use repeated liberal injection of indigo carmine mixed saline. At the completion of the tunneling, the septum is exposed. The depth reached is confirmed by the previous markings we have done on the scope. Then, an ESD (endoscopic submucosal dissection) knife with insulated tip knife (IT 2, KD 611 L, Olympus) is used to perform the septotomy with forced coagulation,

effect 2. We prefer the IT 2 Knife as it has an insulated tip and cuts at the base and shaft only. Thus, there is less chance of injuring the mucosa. Septotomy is extended to the base of the septum until the longitudinal muscle fibers of the esophagus proper are exposed, delineating the completion of septum dissection. Completion of the septotomy is also confirmed by the external mark placed on the scope coinciding with the base of the diverticulum. Complete hemostasis is achieved. The mucosotomy is securely closed using through-the-scope (TTS) clips. Our preference of clips for closure is any clip with a short stub after release, as a longer stub would cause more irritation and discomfort and sometimes pain. Closure involves applying the first clip just at the distal margin of the incision to evert both the margins upward. The subsequent clips are applied while coming proximal to ensure a complete closure (► Fig. 1).

Postprocedure, all patients were routinely admitted overnight for observation and kept nil orally. Intravenous prophylactic antiemetics and broad-spectrum antibiotics as described previously were prescribed as per protocol. An oral Gastrografin study was routinely obtained after 24 hours to see for any leak and ease of swallow. Liquids were commenced if no leak was present. Patients were provided with routine oral broad-spectrum antibiotics for 5 to 7 days and

remained on soft diet for 1 to 2 weeks, followed by commencement of normal diet. Patients were followed after 4 weeks to assess clinical response and delayed postprocedure complications.

Outcomes

The primary endpoint was clinical success, defined as complete or near-complete resolution of dysphagia (Dakkak and Bennett score of 0 or 1), without the need for repeat endoscopic or surgical intervention during follow-up. Secondary endpoints included the resolution of diverticulum on Gastrografin study, the length of the septotomy, duration of the procedure, length of the hospital stay, adverse events with severity graded per the ASGE lexicon, and dysphagia recurrence.

Statistical Analysis

Continuous data were reported as the mean and standard deviation and categorical data were presented as frequency and percentage. Comparison of continuous variables was done using Student's independent *t*-test. For categorical variables, Chi-square test was applied. A *p*-value of <0.05 was considered statistically significant. All statistical analyses were performed using the SPSS v 16.0 software (SPSS Inc., Chicago, Illinois, United States).

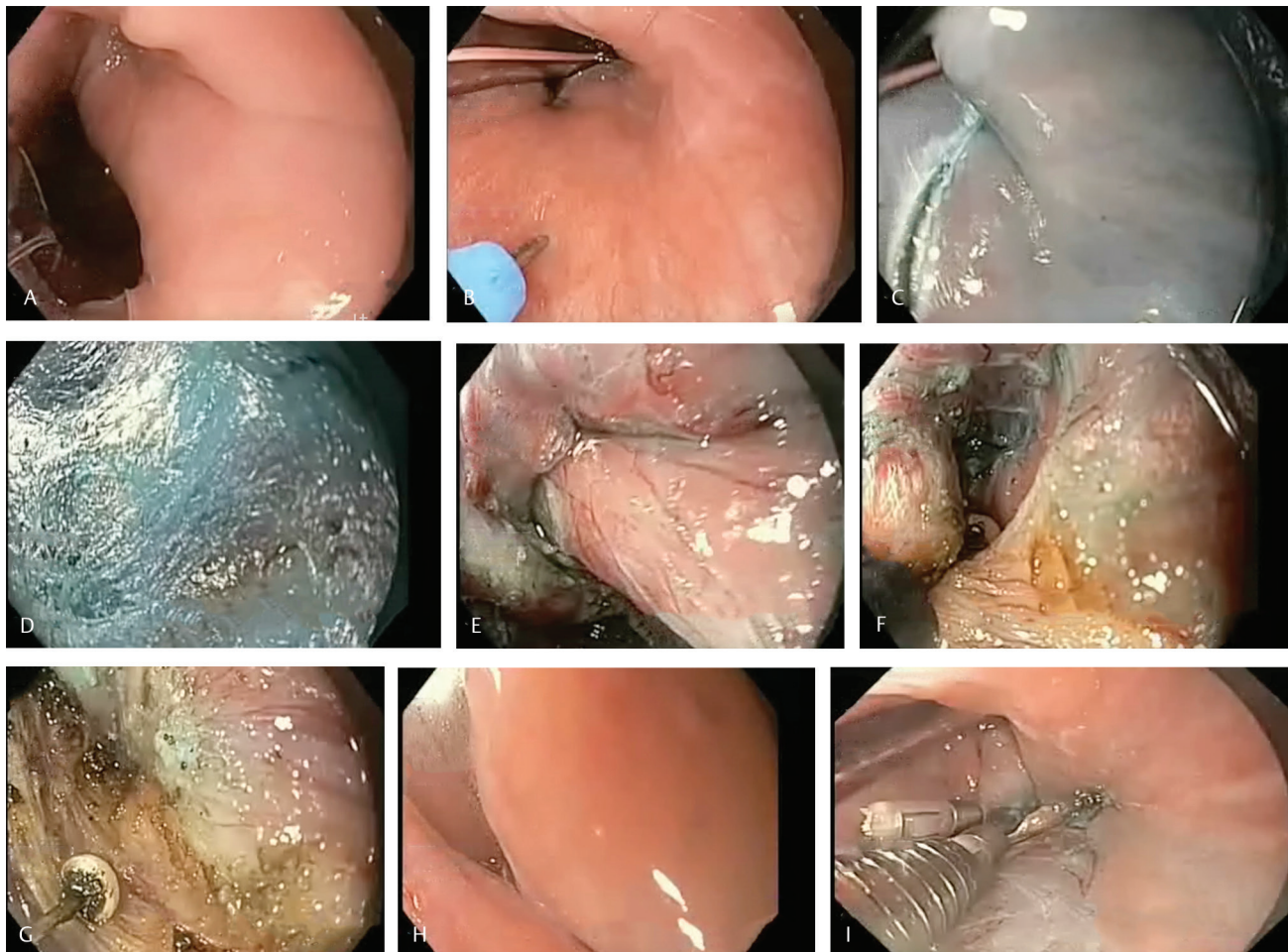


Fig. 1 Steps of Z-POEM: (A) Zenker's diverticulum, (B) mucosal injection, (C) mucosal incision, (D) submucosal dissection, (E) septum exposed, (F) septotomy IT knife, (G) end of septotomy, (H) free esophageal entry, and (I) clip closure. POEM, peroral endoscopic myotomy.

Results

A total of 16 patients were included in the study, who had ZD and underwent Z-POEM procedure (male, 62.5%; mean age, 73.2 ± 5.2 years) with an average CCI of 4.32. All patients had dysphagia, and two patients (13%) had history of regurgitation in addition to dysphagia. None of the patients had any prior intervention for the ZD. Mean size of the diverticulum at presentation was 34.8 ± 10 mm. Technical success, defined as completing the entire procedure, was achieved in all patients (100%). The mean length of septotomy was 31.9 ± 9.4 mm. We could achieve a complete septotomy reaching the base of the diverticulum in all cases. The mean procedure time was 47 ± 7.9 minutes. Clinical success, defined as reduction of dysphagia score, was achieved in all patients with a score of 0 (score of Dakkak and Bennett) in all patients. Score of 1 was noted in 33.3% in the initial first week probably due to edema and residual mucosal pouch. Then all

had a score of 0 at 3 months of follow-up. The mean dysphagia score decreased from 2.9 to 0.2 ($p < 0.0001$; ► **Table 2**; ► **Fig. 2**). Postprocedure of Gastrografin study revealed complete resolution of the diverticulum in 12 patients (75%), only though all patients had symptomatic improvement. Mean length of stay in the hospital was 1.2 ± 0.4 days. No major adverse events was noted. Capnomediastinum was noted in two cases on follow-up Gastrografin study after 24 hours (12.5%). This did not merit any treatment. In all cases except this one, we had only minor or no bleeding while performing septotomy. In this one case, we had an arterial spurt during septotomy which we had not encountered in other cases and was controlled with a coagulation grasper.¹⁰ Hemostasis was achieved by endoscopic measures and did not require blood transfusion (► **Table 3**). After a follow-up of 18 months, 87.5% had no symptom recurrence. Two patients had recurrence of dysphagia with score (Dakkak and Bennett) of 1 in both the patients. None of the patients required repeat intervention.

Table 2 Assessment of dysphagia: before Z-POEM and during follow-up

Durations	Dysphagia score				
	0 = no dysphagia	1 = dysphagia to some solid	2 = dysphagia to semisolid	3 = dysphagia to liquid	4 = total dysphagia
Before Z-POEM	0 (0)	0 (0)	4 (25)	9 (56)	3 (19)
After Z-POEM (at 1 week)	12 (75)	4 (25)	0 (0)	0 (0)	0 (0)
3 months	16 (100)	0 (0)	0 (0)	0 (0)	0 (0)
6 months	16 (100)	0 (0)	0 (0)	0 (0)	0 (0)
12 months	15 (94)	1 (6)	0 (0)	0 (0)	0 (0)
18 months	14 (87.5)	2 (12.5)	0 (0)	0 (0)	0 (0)

Abbreviation: POEM, peroral endoscopic myotomy.

Note: Values presented as *n* (column %).

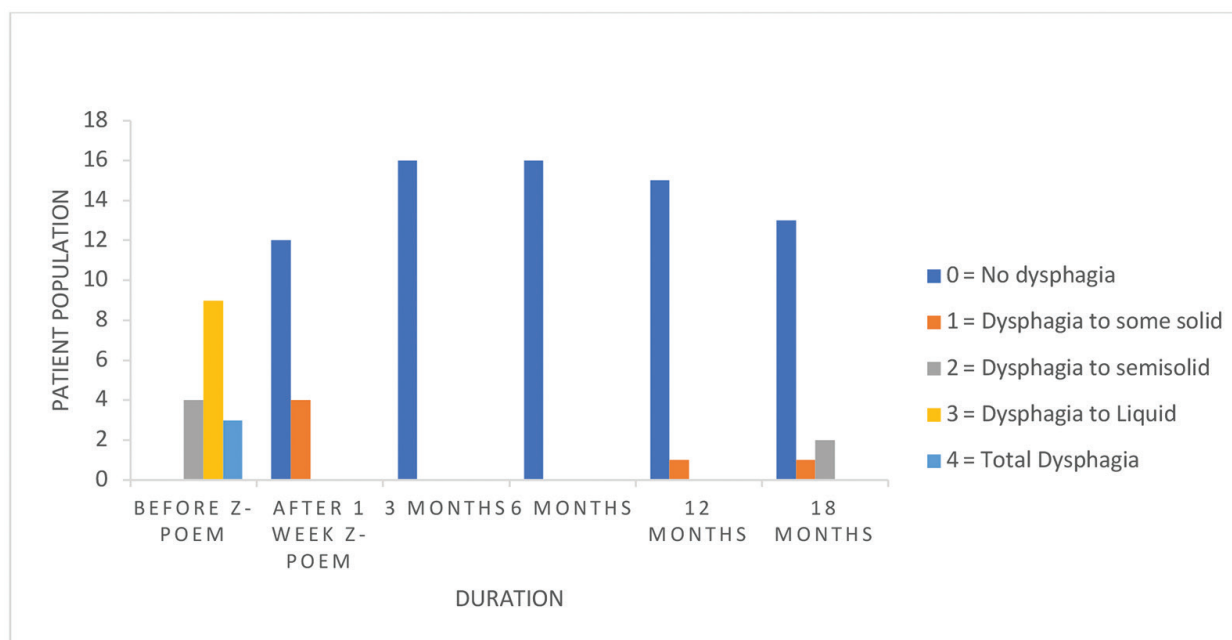


Fig. 2 Assessment of dysphagia: before Z-POEM and during follow-up. POEM, peroral endoscopic myotomy.

Table 3 Adverse events

Bleeding (mild) intra-procedural	1
Infection	None
Perforation	None
Pain (mild)	None
Capnomediastinum (mild)	2

Discussion

The Z-POEM technique for the treatment of ZD has been reported as case reports and small case series.^{10,14,15,16,17} The current study is the first study from India to report on the use of the Z-POEM technique for the treatment of symptomatic ZD. Maydeo et al reported a series of diverticular POEM (D POEM) wherein outcomes of all types of esophageal diverticuli including epiphrenic and ZD were reported.¹⁸ A recently published multicentric, retrospective study also suggests excellent efficacy and safety of Z-POEM in ZD.¹⁹ The concept of utilizing the submucosal tunneling technique has been derived from the experience of doing the POEM procedure for achalasia cardia and STER for submucosal lesions in the esophagus. This technique is unique in that, by creating a submucosal tunnel, the cricopharyngeus muscle or the diverticular septum can be directly visualized and exposed, allowing for careful and a complete septotomy under direct endoscopic visualization.²⁰ This overcomes the major difficulty of doing an incomplete septotomy using direct septotomy methods and increased rate of recurrence of symptoms.²¹ An important secondary outcome in our series is the length of septotomy that we achieved. Using the technique described of measuring the length and identifying the esophageal fibers in the base, we could achieve a complete division of the septum which has given very good relief from dysphagia to our patients.

We know that symptomatic ZD usually presents in middle- and old-age groups. Our study suggests that Z-POEM is safe and feasible, even in elderly patients with preexisting comorbid conditions. Technical and clinical success rates were achieved in all patients. Adverse events were rare. Capnomediastinum observed in two cases, 12.5%, and is really not a complication. It is usually a part and parcel of any procedure which requires creating a tunnel in the esophagus. There was no associated mortality. One patient had intra-procedural bleed but that too was not significant and was controlled easily with a coagulation grasper. Two patients had recurrence of mild symptoms, (dysphagia score 1, Dakkak and Bennet) over an 18-month follow-up period on an average, however, did not merit repeat intervention.

There is always a question of pain or foreign body sensation in these patients due to clips in the pharyngeal region. But as we preferred small-stub clips in all cases, none of the patients had pain or any significant irritation due to the clips.

Our observation is that on Gastrografin done after 24 hours, we saw resolution of the diverticula in 75% cases. There was evidence of a small pouch left in the rest of the cases. This is a left over mucosal bridge that usually disappears during

follow-up. But none of the patient had dysphagia and the Gastrografin spilled off immediately into the esophagus. So, resolution of the diverticulum is not mandatory for clinical success in Z-POEM.

Limitations

However, this study has certain limitations. This is a retrospective study, which has its inherent limitations. The follow-up is available for an average of 18 months and we feel that patients need to be followed-up longer to assess long-term symptomatic recurrence, and these patients should have repeat upper gastrointestinal endoscopy or a contrast study for objective documentation. This is a single-center study and the results may not be generalized for other centers who have less experience in third-space endoscopy.

Conclusion

Endoscopic management of ZD using a POEM-type technique is promising with high technical and clinical success rates with very minimal and mild complications which are a part of the procedure and managed without any interventions.

Conflict of Interest

None declared.

Acknowledgment

We acknowledge Neha D. Sheth as statistician.

References

- Bizzotto A, Iacopini F, Landi R, et al. Zenker's diverticulum: exploring treatment options. *Acta Otorhinolaryngol Ital* 2013;33:219
- Ferreira LE, Simmons DT, Baron TH. Zenker's diverticula: pathophysiology, clinical presentation, and flexible endoscopic management. *Dis Esophagus* 2008;21(1):1-8
- Bergeron JL, Long JL, Chhetri DK. Dysphagia characteristics in Zenker's diverticulum. *Otolaryngol Head Neck Surg* 2013; 148(2):223-228
- Siddiq MA, Sood S, Strachan D. Pharyngeal pouch (Zenker's diverticulum) *Postgrad Med J* 2001;77(910):506-511
- Herbella FA, Patti MG. Modern pathophysiology and treatment of esophageal diverticula. *Langenbecks Arch Surg* 2012;397(1):29-35
- van Overbeek JJ. Pathogenesis and methods of treatment of Zenker's diverticulum. *Ann Otol Rhinol Laryngol* 2003;112(7):583-593
- Law R, Baron TH. Flexible endoscopic approaches and novel therapy for zenker diverticulum. *Management of Zenker and Hypopharyngeal Diverticula*. Springer 2018;x:93-100
- Verdonck J, Morton RP. Systematic review on treatment of Zenker's diverticulum. *Eur Arch Otorhinolaryngol* 2015; 272(11):3095-3107
- Case DJ, Baron TH. Flexible endoscopic management of Zenker diverticulum: the mayo clinic experience. *Mayo Clinic Proceedings* 2010;85(8):719-722
- Yang J, Zeng X, Yuan X, et al. An international study on the use of per-oral endoscopic myotomy (POEM) in the management of esophageal diverticula: the first multicenter D-POEM experience. *Multicenter Study* 2019;51(4):346-349

- 11 Dakkak M, Bennett JR. A new dysphagia score with objective validation. *J Clin Gastroenterol* 1992;14(2):99–100
- 12 Charlson ME, Pompei P, Ales KL, et al. A new method of classifying prognostic comorbidity in longitudinal studies: development and validation. *J Chronic Dis* 1987;40:373–383
- 13 Cotton PB, Eisen GM, Aabakken L, et al. A lexicon for endoscopic adverse events: report of an ASGE workshop. *Gastrointest Endosc* 2010;71:446–454
- 14 Li Q-L, Chen W-F, Zhang X-C, et al. Submucosal tunneling endoscopic septum division: a novel technique for treating Zenker's diverticulum. *Gastroenterology* 2016;151:1071–1074
- 15 Mou Y, Zeng H, Wang Q, et al. Giant mid-esophageal diverticula successfully treated by per-oral endoscopic myotomy. *Surg Endosc* 2016;30:335–338
- 16 Demeter M, Bánovčín P Jr., Ďuriček M, et al. Peroral endoscopic myotomy in achalasia and large epiphrenic diverticulum. *Dig Endosc* 2018;30:260–262
- 17 Hernández Mondragón OV, Solórzano Pineda MO, Blancas Valencia JM. Zenker's diverticulum: submucosal tunneling endoscopic septum division (Z-POEM) *Dig Endosc* 2018;30(1):124
- 18 Maydeo A, Patil GK, Dalal A. Operative technical tricks and 12-month outcomes of diverticular peroral endoscopic myotomy (D-POEM) in patients with symptomatic esophageal diverticula. *Endoscopy* 2019;51(12):1136–1140
- 19 Yang J, Novak S, Ujiki M, et al. An international study on the use of peroral endoscopic myotomy in the management of Zenker's diverticulum. *Gastrointest Endosc* 2020;91(1):163–168
- 20 Brewer Gutierrez OI, Ichkhanian Y, Spadaccini M, Vosoughi K, Repici A, Khashab MA. Zenker's diverticulum peroral endoscopic myotomy techniques: changing paradigms. *Gastroenterology* 2019;156(8):2134–2135
- 21 Huberty V, El Bacha S, Blero D, Le Moine O, Hassid S, Devière J. Endoscopic treatment for Zenker's diverticulum: long-term results (with video) *Gastrointest Endosc* 2013;77(5):701–707