



Free Non-vascularized Toe Phalangeal Transfers in Symbrachydactyly: Outcome Analysis

Transferencia no vascularizada y libre de falanges del pie en simbraquidactilia: Análisis de resultados

Rita Sapage¹ João Rosa¹ Eva Campos Pereira¹ Marta Santos Silva¹ Alexandre Pereira¹ César Silva¹

¹ Orthopedics and Traumatology Service, Centro Hospitalar Universitário do Porto, Porto, Portugal

Rev Iberam Cir Mano 2020;48:87–92.

Address for correspondence Ana Rita da Cunha Sapage, MD, Serviço de Ortopedia e Traumatologia, Centro Hospitalar Universitário do Porto, Largo Prof. Abel Salazar, 4099-001, Porto, Portugal (e-mail: rita.sapage@hotmail.com).

Abstract

Introduction Free nonvascularized toe phalangeal transfer is an established surgical option for the reconstruction of hypoplastic digits. The purpose of the present study was to evaluate our experience with this procedure and to assess bone growth and digit function as well foot morbidity.

Material and Methods We retrospectively evaluated the clinical records for all children with symbrachydactyly submitted to free nonvascularized toe phalangeal transfer between 2002 and 2017. A total of 8 patients were included. We summoned the patients to an appointment to clinically assess the range of motion, the stability, and the alignment of the neo-joint. We radiographically measured the final length and the expected percentage of growth of the transferred phalanx. We also evaluated the foot for comorbidities.

Results The mean age at the time of the first surgery was 19 months (range: 8–42 months). A total of 20 phalanges were harvested: 16 total proximal phalanges, 2 middle phalanges, 1 subtotal proximal phalanx, and 1 accessory thumb phalanx. The distal part of one proximal phalanx was trimmed because the skin pocket was too tight. Two patients underwent a secondary procedure to release the syndactyly. One transfer required revision surgery due to distal tip necrosis and exposition of the transferred phalanx. In the present series, the overall clinical and radiographic outcomes were compatible to those reported in other studies.

Discussion The main limitation of the nonvascularized toe phalanx transfer is the preexisting soft tissue envelope of the finger and the limited growth potential of the transferred bone.

Conclusion Irrespective of the amount of growth achieved in the transferred phalanx, the actual transfer and growth attained should not be viewed as the end result, but rather as a means of providing a stable and functional joint.

Keywords

- digital hypoplasia
- reconstruction
- symbrachydactyly
- toe phalanges

Resumen

Introducción La transferencia no vascularizada y libre de la falange del pie es una opción quirúrgica establecida para la reconstrucción de dedos hipoplásicos. El objetivo de este estudio fue analizar nuestra experiencia con este procedimiento y evaluar el crecimiento óseo y la función digital, así como la morbilidad del pie.

received
April 6, 2020
accepted
July 27, 2020

DOI <https://doi.org/10.1055/s-0040-1718456>.
ISSN 1698-8396.

Copyright © 2020 Thieme Revinter
Publicações Ltda, Rio de Janeiro, Brazil

License terms



Palabras clave

- hipoplasia digital
- reconstrucción
- simbraquidactilia
- falanges del dedo del pie

Material y Métodos Analizamos retrospectivamente el proceso clínico de los niños ($n = 8$) con simbraquidactilia que se sometieron a una transferencia no vascularizada y libre de la falange del pie entre 2002 y 2017. Hicimos una consulta para evaluar clínicamente el rango de movilidad, la estabilidad, y la alineación de la nueva articulación. Medimos la longitud final y el porcentaje de crecimiento esperado de la falange transferida. Evaluamos el pie para la comorbilidad.

Resultados La edad media al momento de la cirugía fue de 19 meses (rango: 8–42 meses). Se recogieron un total de 20 falanges: 16 falanges proximales totales, 2 falanges medianas, 1 falange proximal subtotal, y 1 falange accesoria del pulgar. La parte distal de una falange proximal se sacrificó porque la envoltura de la piel estaba demasiado apretada. Dos pacientes se sometieron a un procedimiento secundario por la liberación de sindactilia. Una transferencia requirió revisión debido a la necrosis de la porción distal y la exposición de la falange transferida. En la presente serie, los resultados clínicos y radiográficos generales fueron compatibles con los descritos por otros estudios.

Discusión Las principales limitaciones de la transferencia no vascularizada y libre de las falanges del pie son la envoltura preexistente de tejidos blandos y el potencial de crecimiento limitado del hueso transferido.

Conclusión Independientemente del crecimiento obtenido con la transferencia de la falange, esto no debe verse como el resultado final, sino como un medio para mejorar la estabilidad y la funcionalidad de la nueva articulación.

Introduction

Free nonvascularized toe phalangeal transfer is an established surgical option for the reconstruction of hypoplastic digits.^{1,2} Functional hand deficiencies with absent or shortened digits are indications for this technique.³ Symbrachydactyly is a unilateral hand malformation characterized by failure of formation of fingers and presence of rudimentary nubbins. Typically, the central digits are absent and the border digits are relatively spared, and syndactyly may be present.⁴

The best candidate for this procedure seems to be a patient with an adequate skin envelope to accommodate the transferred phalanx, good metacarpal development, and intact flexor and extensor tendons, as evidenced by retractile digital nubbins when these are gently distracted.⁵ The primary goal is the improvement of digital length to enhance mechanical advantage and prehension.³ In comparison to free vascularized toe transfer, for the parents this surgery is viewed as a less morbid procedure, and for the surgeons, it is a relatively straightforward technique.¹ Nonetheless, it has an intensive postoperative period; thus, a noncompliant family is an important contraindication. Less severe functional impairment, including an isolated short digit excluding the thumb, and appearance only are relative indications.^{3,6}

Surgery is ideally recommended at an early age (varying from 6 to 18 months), as it appears to enhance the growth of the transferred phalanx and to retain the aperture of the epiphysis. Neural plasticity also seems to be at its greatest at this age, which enables an optimal functional incorporation.^{2,5,6} However, surgery may be considered later based on the age of the child at presentation.²

Several surgical techniques have been described since it was first performed by Wolff in 1910.^{1,2,7} It can be part of a staged treatment in combination with syndactyly release, with local flaps or full-thickness skin graft and lengthening of the phalangeal distraction.⁵ Various reports have confirmed the importance of the intact periosteum and physal plate.³ However, transferred phalangeal growth, epiphysis closure, functional results of the reconstructed metacarpophalangeal joint, and donor-site morbidity are incompletely understood.⁸

The purpose of the present study was to evaluate our experience with nonvascularized toe phalanx transfers in patients with symbrachydactyly. We aimed to assess bone growth and digit function as well foot morbidity.

Material and Methods

We reviewed all children with symbrachydactyly submitted to free nonvascularized toe phalangeal transfer between 2002 and 2017. We retrospectively examined the clinical records of every patient. A total of 8 patients were included (3 boys and 5 girls). The right and left hands were equally affected, and all patients had unilateral hand deformity. All surgical procedures and associated complications were recorded.

We summoned every patient to an appointment to clinically assess the range of motion, the stability, and the alignment of the neo-joint. According to a scale previously used by Kawabata and Tamura,⁸ the range of motion was divided into 3 categories: good (active extension greater than 0°, and active flexion greater than 45°), fair (active extension

between 0° and -30°, and active flexion between 30° and 45°), and poor (extension lag greater than 30°, or active flexion lower than 30°, or total active motion lower than 30°). Lateral instability and malalignment were graded as good if they were lower than 10°, fair if between 10° and 30°, and poor if greater than 30°. As Garagnani et al.,¹ we also evaluated the foot for shortening (measured by toe length compared with the contralateral side), deviation (lateral shifting of the longitudinal axis), crossing (the laterally-shifted longitudinal axis of one toe intersects the axis of a neighboring toe), overriding (angular deformity with hyperextension or dorsal dislocation of the donor toe at the level of the metatarsophalangeal joint) and malrotation (abnormal pronation or supination of the toe). Three children didn't attend the follow-up clinical reevaluation.

In this appointment, we assessed the patients for growth or resorption of the transferred phalanx on plain anteroposterior radiographs. We measured the initial and final length of the transferred phalanx (gain in length) and the percentage of growth compared with the nontransferred phalanx in the contralateral foot. We also evaluated the presence and growth of the remnant native phalanx.

The clinical and radiologic parameters were measured by two authors to control for inter- and intra-examiner error.

All surgeries were performed by the senior author according to the following technique. Dissection is performed with the patient under general anesthesia with a tourniquet first on the thigh and then on the arm. A central dorsal incision is made over the proximal or middle phalanx of the toe, and the extensor tendon is split longitudinally. The phalanx is harvested extraperiosteally along with the joint capsule, the collateral ligaments, and the volar plate. The extensor tendon is repaired with an absorbable suture, followed by skin closure. The phalanx is then transferred to the hand and sutured to the recipient periosteum and adjacent soft tissue. A 1-mm Kirschner wire is inserted longitudinally from the harvested phalanx to the receptor metacarpal or remnant phalanx to hold it in a straight position. A sterile well-padded

dressing is applied with a splint which is maintained for 4–6 weeks.

The protocol of the present study was approved by the hospital ethics review board.

Results

Besides the diagnosis of symbrachydactyly, one patient was also diagnosed with preaxial polydactyly type II on the contralateral hand, and another patient had Poland syndrome. Amniotic band syndrome or other diseases were not diagnosed.

The mean age at the time of the first surgery was 19 months (range: 8–42 months). A total of 20 phalanges were harvested: 16 total proximal phalanges (80%), 2 middle phalanges (10%), 1 subtotal proximal phalanx (5%), and 1 accessory thumb phalanx (5%). The distal part of one proximal phalanx was trimmed because the skin pocket was too tight. A mean of 2.5 transfers per patient were performed (►Fig. 1). Only 1 patient was submitted to phalanx transfers in 2 different procedures (36 months apart). All other transfers were performed simultaneously during the same procedure. The thumb was the recipient in 2 patients (10%), the second digit, in 5 patients (25%), the third digit, in 7 patients (35%), the fourth digit, in 4 patients (20%), and the fifth digit, in 2 patients (10%). The second toe was the donor in 4 patients (20%), the third toe, in 8 patients (40%), the fourth toe, in 5 patients (25%), and the fifth, in 2 patients (10%).

Three patients underwent a secondary procedure for the release of the syndactyly in an average of 24 months (range: 9–39 months) after the transfer surgery.

One transfer required revision surgery for distal tip necrosis and exposure of the transferred phalanx four days after the initial surgery. As this patient missed his recent appointment, we cannot provide the current clinical and radiologic evaluations. No other surgery-related complications were reported.

The active motion of the metacarpophalangeal joint was rated as good in 7 (50%), fair in 4 (29%), and poor in 3 (21%)

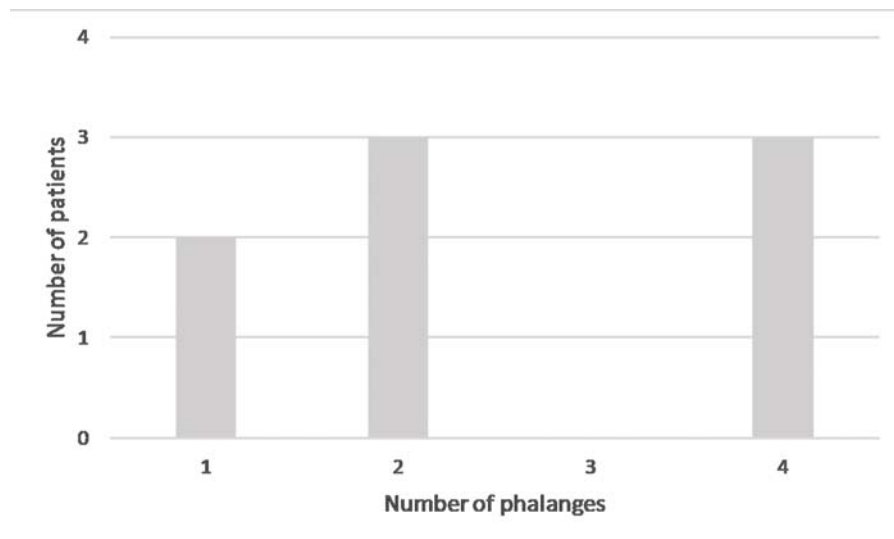


Fig. 1 Number of phalanges harvested per patient ($n = 8$).

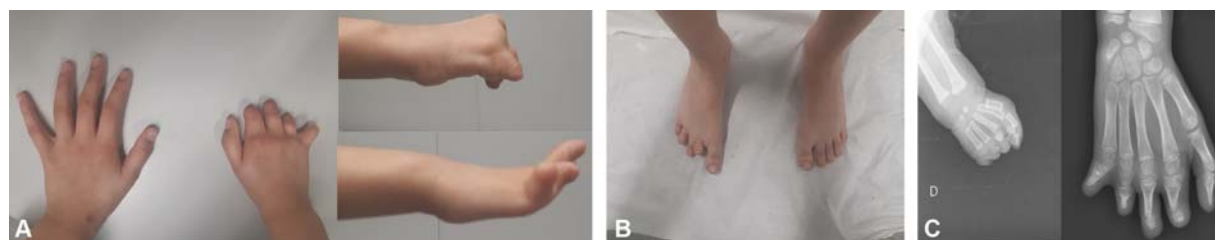


Fig. 2 A girl with symbrachydactyly. The proximal phalanges were harvested from the second, fourth and fifth right toes and the middle phalanx was harvested from the third right toe at the age of 9 months. Clinical appearance of the hand (A) and foot (B) at the age of 8 years. Anteroposterior radiographs at 5 months and 8 years of age (C).

Table 1 Donor-toe deformities identified upon clinical reevaluation (patients $n = 6$, phalanges $n = 14$)

	Good	Fair	Poor
Active motion	7	4	3
Stability	13	1	–
Alignment	5	7	2

Table 2 Donor-toe deformities identified upon clinical reevaluation (patients $n = 6$, toes $n = 14$)

Toe	Second ($n = 3$)	Third ($n = 6$)	Fourth ($n = 4$)	Fifth ($n = 1$)
Shortening	100%	83%	75%	100%
Deviation	–	17%	25%	100%
Crossing	–	–	–	–
Overriding	33%	33%	–	–
Malrotation	–	17%	50%	100%

transfers (►Fig. 2A). The average active motion was of 11° in extension (range: –30–45°) and of 54° in flexion (range: 10–90°). The stability was rated as good in 13, and fair in 1 transfer. The alignment was rated as good in 5 (36%), fair in 7 (50%), and poor in 2 (14%) transfers (►Table 1). Regarding the clinical evaluation of the donor toes, 12 (60%) had shortening, 3 (15%), deviation, 3 (15%), overriding, 4 (20%), malrotation, and none had crossing (►Table 2) (►Fig. 2B). Of the 14 donor toes evaluated, only 2 (14%) did not show any abnormality.

Radiographically, the transferred phalanx showed growth in 12 transfers, resorption in 1 transfer, and no alteration in growth in 1 transfer (►Fig. 2C). The mean gain in length of the transferred phalanx was of 4.5 mm in total (range: –5 mm–12 mm). The mean gain in length in children with less or more than 18 months of follow-up was of 2 mm and 7 mm respectively ($p = 0.068$). The percentage of growth of the transferred phalanx compared with the nontransferred phalanx in the contralateral foot was of 77% (range: 16%–117%). The length of the transferred phalanx was 74% of what was expected in children with less than 4 years of follow-up, and of 81% in children with more than 4 years of follow-up ($p = 0.623$).

Concerning age, there was a trend towards better results related to active motion (mean flexion: 56° versus 50°,

Table 3 Clinical and radiologic evaluation according to the age at the transfer ($n = 14$). The results are shown as means

		≤ 18 months	> 18 months	p
Active motion (°)	Flexion	56	50	0.767
	Extension	13	3	0.583
Gain in length (mm)		5	3	0.616
Percentage of expected length (%)		92	73	0.249

$p = 0.767$; and mean extension: 13° versus 3°, $p = 0.583$), gain in length (5 mm versus 3 mm, $p = 0.616$) and percentage of expected length (92% versus 73%, $p = 0.249$) in patients submitted to transfer at the age of 18 months or younger, although it was not statistically significant (►Table 3).

There was a remnant of the native proximal phalanx in the finger of 13 transfers (65%), while no remnant was present in the other 7 transfers (35%). The mean difference in length of the remnant phalanx was of 1.3 mm (range: –0.7 mm–4.1 mm). In total, 16 transfers (80%) had a normal metacarpal, 3 (15%) had a hypoplastic metacarpal, and 1 (5%) had an absent metacarpal. The presence of a phalangeal remnant or a complete metacarpal did not seem to be associated with different results for each of the evaluated parameters ($p = 0.845$ and $p = 0.713$).

The clinical and radiologic outcomes in the transfer of the middle phalanges and the subtotal trimmed proximal phalanx were not statistically different in comparison to those of the transfers of the proximal phalanges ($p = 0.213$ and $p = 0.483$).

The mean follow-up was of 66 months (range: 18–216 months) after the first surgery. Two children (five transfers) missed a recent reevaluation appointment; therefore, their clinical and radiographic parameters were not assessed.

Discussion

The main limitation of the nonvascularized toe phalanx transfer is the preexisting soft tissue envelope of the finger and the limited growth potential of the transferred bone.^{8,9} That is, the best candidates for this technique are those who have adequate soft tissue and are young enough to retain the growth potential

of the transferred toe phalanx. Concerning age, the ideal age seems to be up to 18 months, as it appears to be related to the largest phalangeal growth.^{6,7,10} Even so, most authors perform it up to the age of 4.^{6,11} Earlier transfer also stimulates soft-tissue growth of the nubbins, which adapt their size to receive the phalanx.¹² Besides age, extraperiosteal dissection of the transferred phalanx is stated to be crucial in order for the physes to remain open and for growth.^{3,9,10} Some authors report a 90% physal survival and 90% of the expected growth when the physes remained open at 3.4 years of mean follow-up, or similar.^{7,10,13} Kawabata and Tamura⁸ reported that the final phalangeal length was of 71% of that of the control bone. In the present study, we achieved nearly the same result, with an expected percentage of growth of the transferred phalanx of 77%. Physal patency and phalangeal growth reports differ in the literature; however the latest series state a positive growth in transverse dimension, strengthening and stability of the digits.¹⁰

We only had to trim one proximal phalanx to adjust it to the recipient soft-tissue envelope. This case presents a short follow-up, and it is not possible to evaluate if our trimming technique influenced the growth rate of the phalanx. Even so, the literature suggests that excessive trimming is associated with poor growth.⁸ This can also be related to loss in the integrity of the periosteum and gradual resorption of the bone.¹

In the present study, we found no difference in gain in length between proximal or middle transferred phalanges. However, some studies suggest that proximal phalangeal transfer produces a better gain in length to the recipient finger than middle phalangeal transfer.^{1,11}

We experienced one case of distal transferred phalanx necrosis. As previously described in the literature, this is a common complication which can significantly compromise growth.^{8,10} As this patient missed his recent appointment, we cannot provide his current clinical and radiologic evaluation.

The hand function of most of the congenital hand deformities can be improved by digit lengthening.⁶ We achieved a positive gain in length and percentage of expected growth compared with the contralateral nontransferred phalanx in the contralateral foot. However, the actual growth achieved with a phalangeal transfer should not be regarded as the end result, but rather as a means of providing a stable and mobile finger.⁵ More so, the patients' ability to handle objects and perform daily activities is more significant than the separate evaluation of the range of motion.⁶ In the present series, the overall clinical outcome concerning the range of motion, the stability, and the alignment was compatible to that of other studies.⁸ Non-vascularized free toe phalangeal transfer seems to provide reconstructed digits that are sensitive, capable of performing pinching movements, and able to tolerate heavy use.^{6,10}

Apart from the clinical issues, it is of extreme importance to also consider the children's social well-being and adjustment to the hand deformity, which can deteriorate as they grow older. On that account, improvement of the esthetic appearance can be considered, although it cannot be restored to normal in most cases of aphalangia.^{6,10,11}

Kawabata and Tamura⁸ hypothesized that the remnant of the proximal phalanx provides better support to the epiphysis of the transferred toe phalanx and might help physal viability. Although the presence of a phalangeal remnant correlated with a good active range of motion and appeared to improve function, it did not influence physal closure.⁸ In our study, the presence of a phalangeal remnant or a complete metacarpal did not seem to be associated with different results regarding the clinical and radiologic outcomes.

Donor-site morbidity for free toe phalangeal transfer is one of the greatest parental concerns.⁸ The literature reports are highly variable concerning the dissatisfaction of the patients and parents, the cosmetic appearance, the footwear and the physical problems.^{6,8} Raizman et al.,² in a recent study, found almost no measurable lower extremity morbidity or dysfunction over the mid- to long-term after follow-up after toe-phalanx harvest. Even so, donor-site morbidity for free toe phalangeal transfer could be greater than documented, as reported by Garagnani et al.¹ regarding the clinical and radiographic features. Long-term follow-up of the donor site is essential to accurately assess the results, as donor-site defect can worsen over time. This should be considered during the surgical decision-making and preoperative counseling.¹ We found evident deformities in almost all of the donor toes. We didn't assess the radiographic measurements or the functional repercussion for the donor site, which could have added information to the clinical evaluation.¹

Further lengthening can be achieved by secondary procedures using distraction and intercalary bone graft techniques.^{5,10} No other surgical technique was used in the present study. Still, a combination of nonvascularized multiple toe phalangeal transfers, web space deepening, and distraction lengthening may provide excellent function in children with symbrachydactyly.⁵

There are several limitations to the present study. We can mention its small sample size and retrospective nature, as well as the different periods of follow-up of the evaluated children. Enhancing the function of the hand is the primary goal of non-vascularized free toe phalangeal transfer. Still, we assessed the function of each isolated finger, and improvement in the full function of the hand was not studied.

Conclusion

Nonvascularized toe-phalanx transfer offers a relatively simple method to lengthen short digits and to provide satisfactory function in patients diagnosed with symbrachydactyly. Irrespective of the amount of growth achieved in the transferred phalanx, the actual transfer and growth attained should not be viewed as the end result, but rather as a means of providing a stable and functional joint. A thorough screening of the patient and family are crucial to ensure compliance with this complicated postoperative care.

Conflict of Interests

The authors have no conflict of interests to declare.

References

- Garagnani L, Gibson M, Smith PJ, Smith GD. Long-term donor site morbidity after free nonvascularized toe phalangeal transfer. *J Hand Surg Am* 2012;37(04):764–774
- Raizman NM, Reid JA, Meisel AF, Seitz WH Jr. Long-Term Donor-Site Morbidity After Free, Nonvascularized Toe Phalanx Transfer for Congenital Differences of the Hand. *J Hand Surg Am* 2019
- Patterson RW, Seitz WH Jr. Nonvascularized toe phalangeal transfer and distraction lengthening for symbrachydactyly. *J Hand Surg Am* 2010;35(04):652–658
- Goodell PB, Bauer AS, Sierra FJ, James MA. Symbrachydactyly. *Hand (N Y)* 2016;11(03):262–270
- Netscher DT, Lewis EV. Technique of nonvascularized toe phalangeal transfer and distraction lengthening in the treatment of multiple digit symbrachydactyly. *Tech Hand Up Extrem Surg* 2008;12(02):114–120
- Unglaub F, Lanz U, Hahn P. Outcome analysis, including patient and parental satisfaction, regarding nonvascularized free toe phalanx transfer in congenital hand deformities. *Ann Plast Surg* 2006;56(01):87–92
- Buck-Gramcko D. The role of nonvascularized toe phalanx transplantation. *Hand Clin* 1990;6(04):643–659
- Kawabata H, Tamura D. Five- and 10-Year Follow-Up of Nonvascularized Toe Phalanx Transfers. *J Hand Surg Am* 2018;43(05):485.e1–485.e5
- Cavallo AV, Smith PJ, Morley S, Morsi AW. Non-vascularized free toe phalanx transfers in congenital hand deformities—the Great Ormond Street experience. *J Hand Surg [Br]* 2003;28(06):520–527
- Gohla T, Metz Ch, Lanz U. Non-vascularized free toe phalanx transplantation in the treatment of symbrachydactyly and constriction ring syndrome. *J Hand Surg [Br]* 2005;30(05):446–451
- Naran S, Imbriglia JE. Case Report: 35-Year Follow-up for Nonvascularized Toe Phalangeal Transfer for Multiple Digit Symbrachydactyly. *Hand (N Y)* 2016;11(04):NP38–NP40
- Tonkin MA, Deva AK, Filan SL. Long term follow-up of composite non-vascularized toe phalanx transfers for aphalangia. *J Hand Surg [Br]* 2005;30(05):452–458
- Goldberg NH, Watson HK. Composite toe (phalanx and epiphysis) transfers in the reconstruction of the aphalangic hand. *J Hand Surg Am* 1982;7(05):454–459