

Introducing the “SOAC Wrist”: Scaphotrapeziotrapezoid Osteoarthritis Advanced Collapse

Presentación de la “muñeca SOAC”: Colapso avanzado por artrosis escafotrapeziotrapezoidea

Ricardo Kaempf de Oliveira¹ Márcio Aita² João Brunelli³ Vicente Carratalá⁴ Pedro J Delgado⁵

¹ Santa Casa de Misericórdia, Porto Alegre, RS, Brazil

² Universidade Federal do ABC, Santo André, SP, Brazil

³ Department of Orthopedics and Traumatology, Cirurgia de Mão e Microcirurgia, Santa Casa de Misericórdia, São Paulo, SP, Brazil

⁴ Traumatology Service, Unión de Mutuas y Hospital Quirónsalud Valencia, Valencia, Spain

⁵ Hospital Universitario HM Montepríncipe, Universidad CEU San Pablo, Boadilla del Monte, Madrid, Spain

Address for correspondence Ricardo Kaempf de Oliveira, Rua Leopoldo Bier, 825/301, Porto Alegre, RS, 90620-100, Brazil (e-mail: ricardokaempf@gmail.com).

Rev Iberam Cir Mano 2020;48:93–100.

Abstract

Despite being the second most common osteoarthritis of the wrist, little is known about scaphotrapeziotrapezoid osteoarthritis. Not all patients with this type of osteoarthritis have symptoms, and, even in those symptomatic patients, the intensity of the complaint is not proportional to the severity of the degeneration. In symptomatic patients, when the conservative treatment fails, grading classifications to help define the surgical treatment are solely based on the joint characteristics, and fail to assess the rest of the carpus.

In general, most carpal degenerative processes show the same evolution pattern, which varies according to the initial injury, along with the type of deformity and the inherent instabilities. Thus, we hypothesize that the degenerative evolution due to primary osteoarthritis of the scaphotrapeziotrapezoid joint also follows a logical evolutionary sequence, similar to the one that occurs in cases of scapholunate advanced collapse (SLAC), scaphoid nonunion advanced collapse (SNAC), scaphoid malunion advanced collapse (SMAC), and scaphoid chondrocalcinosis advanced collapse (SCAC), thus resulting in scaphotrapeziotrapezoid osteoarthritis advanced collapse (SOAC). We have divided the SOAC into three groups, and considered that their treatment shall be guided by the evolutionary stage of the disease, and not by the surgeon's preferred technique.

Keywords

- ▶ Scaphotrapeziotrapezoid(STT) joint
- ▶ arthritis
- ▶ classification
- ▶ arthroscopy/use

Resumen

A pesar de constituir la segunda causa más común de artrosis de la muñeca, poco se conoce sobre la artrosis escafotrapeziotrapezoidea. No todos los pacientes con este tipo de artrosis presentan síntomas y, incluso en los pacientes sintomáticos, la intensidad de las quejas no es proporcional a la gravedad de la degeneración. En los pacientes sintomáticos, cuando fracasa el tratamiento conservador, las clasificaciones

received
July 27, 2020
accepted
September 22, 2020

DOI <https://doi.org/10.1055/s-0040-1721045>.
ISSN 1698-8396.

Copyright © 2020 Thieme Revinter Publicações Ltda, Rio de Janeiro, Brazil

License terms



Palabras clave

- ▶ articulación escafo-trapecio-trapezoidea (ETT)
- ▶ artritis
- ▶ clasificación
- ▶ artroscopia/uso

de los grados para ayudar a definir el tratamiento quirúrgico se basan únicamente en las características de la articulación y no evalúan el resto del carpo.

En general, la mayoría de los procesos degenerativos carpianos muestra el mismo patrón de evolución, el cual varía de acuerdo con la lesión inicial junto con el tipo de deformidad y las inestabilidades inherentes. Por lo tanto, nuestra hipótesis es la de que la evolución degenerativa debida a la artrosis primaria de la articulación escafo-trapecio-trapezoidea también obedece a una secuencia evolutiva lógica, similar a la que ocurre en el colapso avanzado escafolunar (SLAC), el colapso avanzado por pseudoartrosis del escafoides (SNAC), el colapso avanzado por consolidación defectuosa del escafoides (SMAC) y el colapso avanzado por condrocalcinosis del escafoides (SCAC), dando como resultado, por lo tanto, el colapso avanzado por artrosis escafo-trapecio-trapezoidea (SOAC). Hemos dividido al SOAC en tres grupos, y consideramos que su tratamiento deberá estar guiado por la etapa evolutiva de la enfermedad, y no por la técnica preferida por el cirujano.

Introduction

Primary osteoarthritis (OA) is an uncommon degenerative pathology of the wrist as compared with pathologies of other loading joints. The carpal scaphotrapeziotrapezoid (STT) is the second most affected joint by OA,¹⁻³ and it is present in 16% of wrist radiographs,⁴⁻⁶ in 39% of cadaver dissections,² and in 83% of people older than 84 years of age.¹ The joint is located between the distal scaphoid and trapezium, and between the scaphoid and trapezoid bones. The joint between the trapezium and trapezoid bones is flat and scarcely mobile; therefore, it is not affected by degeneration.¹

Most patients with STT-OA have no symptoms; as a result, they are not diagnosed, which leads to an underestimation of the exact prevalence.⁷ In addition, STT-OA can produce diffuse symptoms, such as pain at the base of the thumb and on the thenar eminence, along with loss of strength and mobility, and patients often cannot clearly explain their complaints, thus making the diagnosis difficult.⁸

The role of the STT joint in wrist biomechanics has not been fully understood, especially in cases in which it is affected by OA⁷ (→ Fig. 1). Until recently, STT-OA was thought to occur only as a final evolutionary phase of rhizarthrosis,⁹ a fact that has not yet been proven.

It is noted in the literature that the treatment for STT-OA gets little attention when compared with that of rhizarthrosis. In addition, the management varies according to the author's preference and understanding of the pathology, ranging from conservative care to STT arthrodesis, synovectomy, resection of the distal scaphoid with or without stabilization, and arthroplasty.^{3,10} Little is said about adapting the type of treatment to the evolutionary phase of the degenerative process and to the patient's features.

We consider that there is a primary STT-OA as a specific pathology, not directly related to rhizarthrosis, and that this lesion has a standardized and sequential evolution, similar to that of other carpal degenerative processes, such as the scapholunate advanced collapse (SLAC),⁶ the scaphoid non-union advanced collapse (SNAC)^{11,12} and the scaphoid mal-

union advanced collapse (SMAC).¹³ We aim to describe this degenerative progression, which we call the wrist with scaphotrapeziotrapezoid osteoarthritis advanced collapse (SOAC), and to detail each phase. In addition, we consider that such standardization of the pathology may open the door to specific treatment strategies directly related to each individual patient depending on their evolutionary phase.

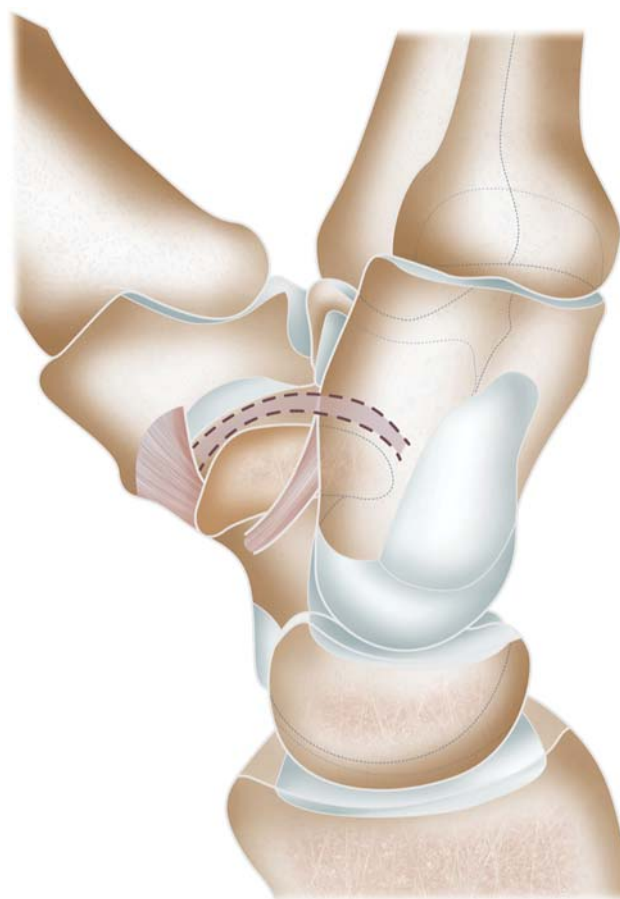


Fig. 1 “C” shaped (dotted lines) scaphotrapeziotrapezoid (STT) joint and correlations with the surrounding joints.

Evolution of STT-OA – The “SOAC Wrist”

Type-I SOAC is defined as an isolated OA at the STT joint with no changes in other carpal joints (► **Fig. 2**). This phase is characterized by a decrease in joint space with subchondral bone sclerosis, osteophytes, subchondral cysts, but no joint subluxation, as the scaphoid remains blocked in neutral or slightly extended position. All those manifestations may be present to a greater or lesser degree, either in isolation or association.

Type-II SOAC features the same STT joint changes as type I, but associated with scapholunate (SL) ligament injury, and dorsal intercalated segment instability (DISI) deformity of the proximal row (► **Fig. 3**). This is because STT-OA causes scaphoid bone blockage and results SL joint overloading. Over time, the SL ligament ruptures by repeated microtrauma, and not necessarily due to a high-energy injury. Contrary to what might be expected, even with SL ligament injury, scaphoid flexion and pronation (rotational instability) do not occur, since it is distally fixed by the degenerative process, blocked onto the trapezium and trapezoid bones. The consequent DISI deformity occurs mainly due to lunate extension, changing the radiolunate and lunocapitate angles, albeit SL angulation may remain within the normal range. With no flexion and rotational instability of the scaphoid, the radiocarpal joint does not undergo degeneration, and remains unchanged in all phases of SOAC, as well as the scaphocapitate (SC) joint. Anteroposterior radiographs of the wrist will show a variable degree of dissociation and enlargement of the SL space as, once there

is no scaphoid displacement in flexion, there will not be shortening of the scaphoid and the ring sign. All distancing will occur at the expense of the extension of the proximal row (lunate and triquetrum).

Type-III SOAC shows degenerative changes of the STT joint, which are typical of type I, and the SL ligament injury of Type II; however, fixed positioning in extension of the lunate and carpal DISI instability are observed (► **Fig. 4**). In this stage, degenerative changes progress and reach the lunocapitate (midcarpal) joint.

Discussion

Primary wrist OA is rare when compared with OA of other synovial joints, such as the knee, hip and spine, and it occurs more frequently after inflammatory diseases and trauma. Little is known about the pathology, despite STT-OA being the second most frequent osteoarthritis of the wrist.⁷ As with rhizarthrosis, not all STT-OA patients have symptoms. Even in those with symptoms, the intensity of the complaint is not proportional to the degree of degeneration.^{7,14} It is known that women after menopause are the most affected, although the diagnosis is occasionally difficult to achieve. Nonspecific symptoms of diffuse pain at the base of the thumb and at the dorsoradial wrist, swelling, loss of pinch strength, and restriction of thumb opposition and abduction are common complaints and also hamper the diagnosis.⁸ Additionally, physical examination of the STT joint is not easy due to restricted mobility, especially when affected by OA, and is

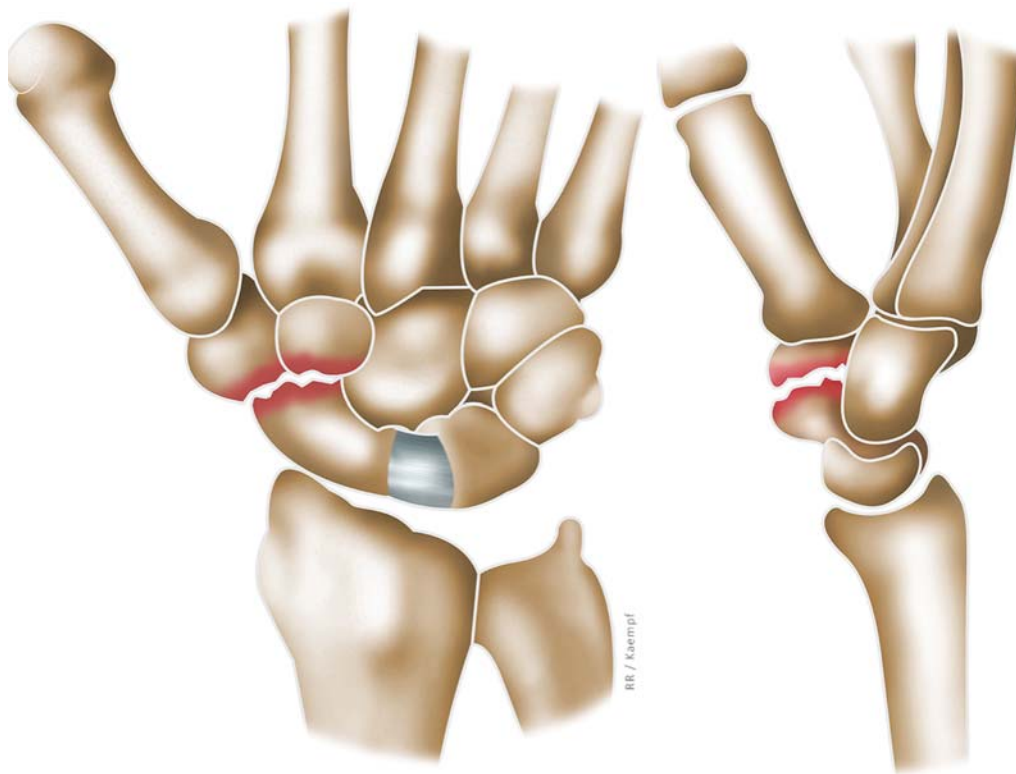


Fig. 2 Type-I scaphotrapeziotrapezoid osteoarthritis advanced collapse (SOAC). Osteoarthritis is isolated at the STT joint without any change in other carpal joints. This stage features joint space reduction, subchondral bone sclerosis, osteophytes, and subchondral cysts with no joint subluxation, as the scaphoid remains in neutral position or slightly extended (lateral view).

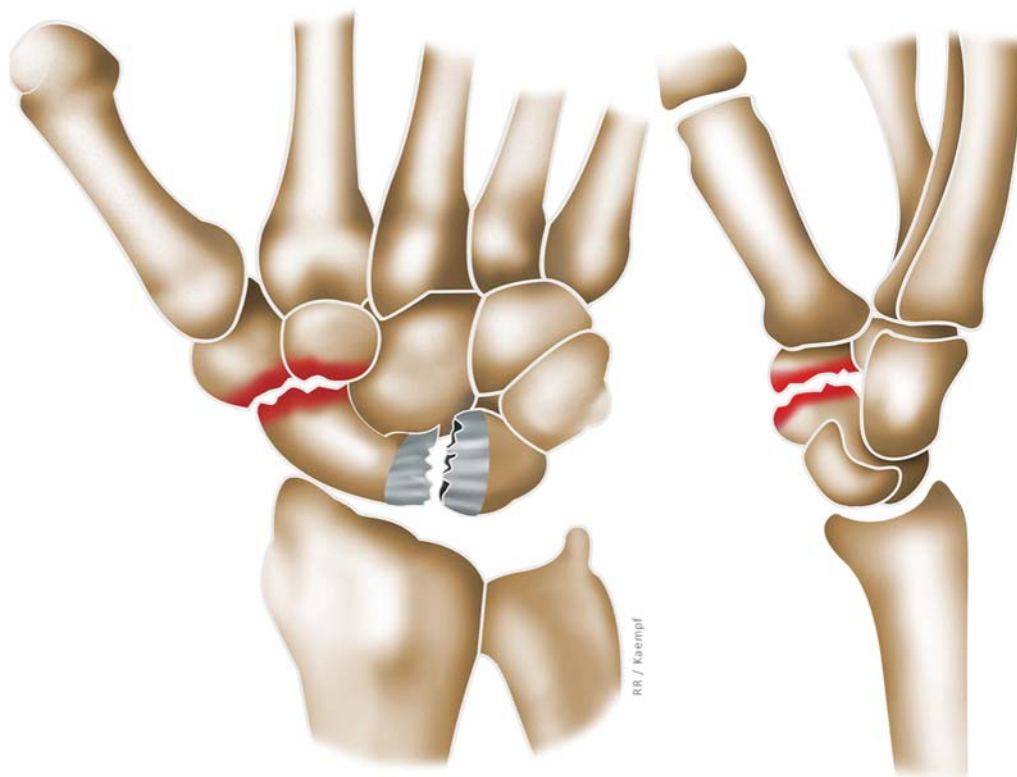


Fig. 3 Type-II SOAC, which features the same changes as type I in the STT joint, but associated with scapholunate (SL) ligament injury and dorsal intercalated segment instability (DISI) deformity of the proximal row.

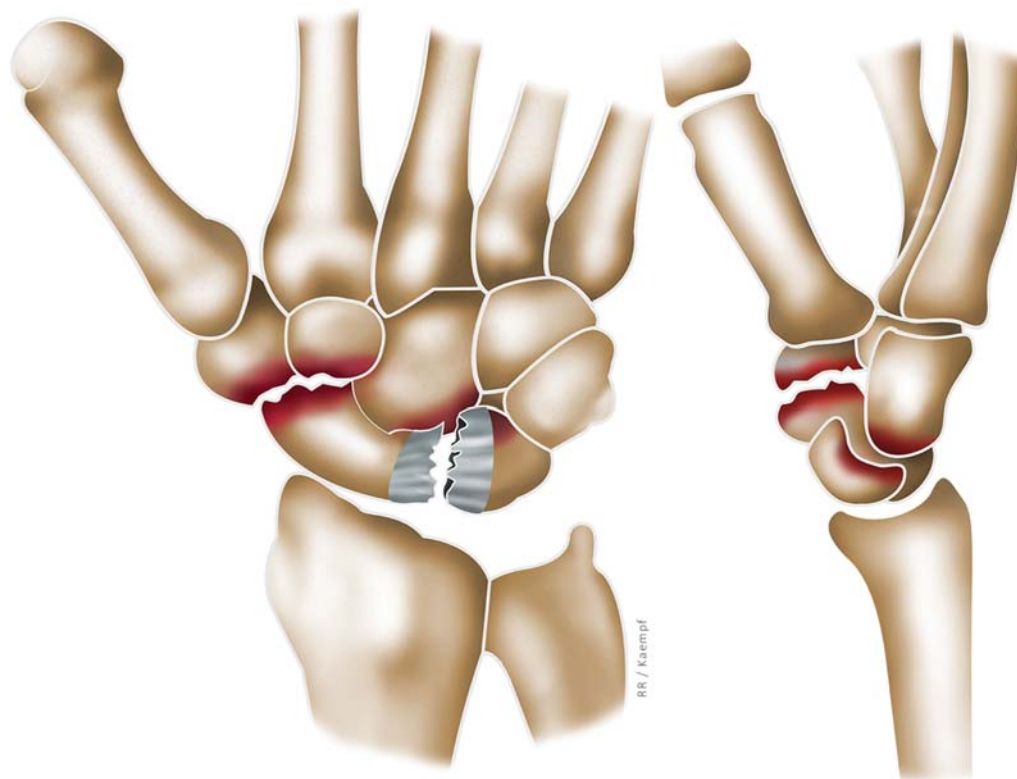


Fig. 4 Type-III SOAC. The degenerative changes in the STT joint, typical of type I, and SL ligament injury of type II remain; however, fixed lunate positioning in extension and carpal DISI instability occurs, and degenerative changes evolve to the lunocarpal (midcarpal) joint.

difficult to palpate, since there is the prominent thenar eminence at the palmar aspect; moreover, the STT joint is deeply located beneath the tendons of the first extensor compartment and the anatomical snuffbox.⁷

The cause of STT-OA is ill-defined, let alone its evolution pattern.¹⁴ Eaton et al.⁹ initially advocated that STT-OA would be a final stage of rhizarthrosis. Other authors,¹⁵ however, have already shown that, even though there may be an association with rhizarthrosis, STT-OA is primary and symptomatic in 11% of patients, and in 70% of those it is bilateral. Moritomo et al.² have regarded the degree of trapezotrapezoid joint tilting and STT ligament hypoplasia as possible causes of primary OA. They state that due to those anatomical features, the degeneration initially affects the ulnar edge of the distal scaphoid and the central portion of the trapezoid. Other authors have attributed its appearance to a traumatic injury to the STT joint ligaments;¹⁶ to joint instability;¹⁷ and to variations in lunate shape.^{5,18}

The classifications employed to date to grade STT-OA are based exclusively on the analysis of joint features, such as the presence of sclerosis and irregularity of joint margins, decreased joint space, cysts and osteophytes.^{1,4,19,20} Differently from their standard classification of rhizarthrosis, the classification proposed by Eaton et al.⁹ for STT-OA does not include the evolution of the degenerative process of other carpal regions. We believe that carpal analysis is an extremely relevant factor when grading the evolution of STT-OA and, consequently, to define its treatment.

The evolutionary sequence of several wrist degenerative pathologies has already been described. They vary according to the location of the initial injury, the cause (either traumatic or degenerative), and the type of ensuing carpal instability, thus resulting in several acronyms. In 1984, Watson and Ballet⁶ described the SLAC injury type, which is the degenerative sequence of the wrist after SL ligament injury and DISI instability. Subsequently came the description of the SNAC type of lesion,^{11,12} a degenerative pattern after scaphoid pseudoarthrosis; the SMAC¹³ was described

in 1998, due to malunion of the scaphoid bone; and in 1990, the SCAC, due to chondrocalcinosis or joint deposition of calcium pyrophosphate, was described.^{21–25}

As a rule, most carpal collapses show the same evolutionary pattern. The lesion begins with a change in stability in the proximal row, and, over time, also depending on the injury and the deformity that ensues, it evolves to degeneration of the overloaded areas. Thus, we think that the evolution of the degeneration due to primary STT-OA also follows a logical evolving sequence, similar to that of the SLAC, SNAC, SMAC, and SCAC, resulting in the SOAC (► Fig. 5).

In the SLAC, the DISI deformity causes flexion and pronation of the scaphoid (rotational instability) and extension of the lunate and the rest of the carpal proximal row, creating an OA that advances from the radial styloid toward the scaphoid fossa and to the scaphocapitate joint, to finally reach the lunocapitate joint.⁶ In the SNAC, the OA reaches the radial styloid, which is in close contact with the portion of the scaphoid distal to the flexed pseudoarthrosis. The articular part of the proximal scaphoid that is linked to the extended lunate is therefore spared.^{12,26} This leads us to conclude that the rotational instability of the scaphoid that positions the bone in flexion and pronation would be the causative factor of overloading onto the dorsoradial portion of distal radius, thus ensuing OA. When we compare the evolution of the SLAC and SNAC with STT-OA and SOAC, we observe that in the SOAC there is no scaphoid flexion, as the bone remains blocked in a neutral position due to the OA. As such, there will be no radioscapoid degeneration in any of the evolutionary stages. This has already been shown by some authors,^{7,27,28} who have proposed the inverse relationship between the presence of STT and radiocarpal OA, with no explanation for that fact.

Other authors^{6,22,28–30} have reported the relationship of STT-OA with ligament injury and SL dissociation. Wadhvani et al.²⁸ assessed 618 radiographs of patients with wrist pain, 43 (7%) of which presented SL ligament injury, with SL space widening greater than 4 mm. Of those, 6 presented STT-OA

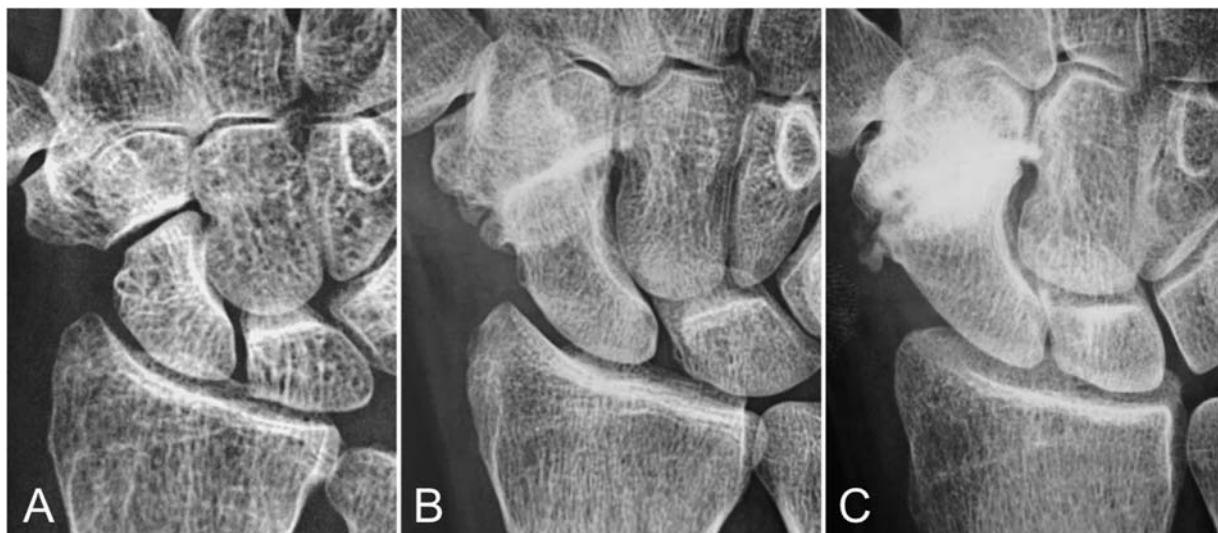

Fig. 5 Lateral radiographs that display the evolution of STT joint degenerative process. SOAC Type I (A); Type II (B); Type III (C).

(1% of the initial sample and 14% of patients with SL lesion). They concluded that, on rare occasions, the SL lesion, instead of causing scaphoid flexion and the consequent ring sign, creates impingement of the distal scaphoid at the proximal trapezium and trapezoid bones, generating an STT-OA secondary to the SL lesion. They also showed that, in the advanced stages of STT-OA, there is an enlargement of the SL space and a decrease in the lunocapitate joint space, with local OA, but sparing the radiocarpal joint, a fact that, according to those authors,²⁸ warrants a study in the future. In a cadaveric study, Viegas et al.²⁹ showed that STT-OA is present in 45% of wrists with SL lesion, and in 14% of wrists without such injury, suggesting that the SL lesion may change scaphoid mechanics and be a cause of STT-OA.

Higgison et al.¹⁹ assessed 1,711 patients older than 30 years of age who sought medical attention due to wrist pain after trauma. They found 16 patients with STT-OA, including 8 symptomatic patients and 2 patients with SL lesion – the latter with worse function and more symptoms. They reached the conclusion that the absence of SL lesion in most patients with STT-OA is not the main cause for its development. Scordino et al.⁴ assessed 700 radiographs from patients with varying degrees of wrist pain. They found a prevalence of 111 patients with STT-OA, and highest associated risk factors included advanced age, female gender, SL joint space widening of more than 3 mm, and the presence of rhizarthrosis. Of 700 radiographs, 30 showed SL dissociation, including 16 with STT-OA and 14 without such finding. That fact shows it is more common for STT arthrosis to exist in association with an SL lesion than in isolation.⁴

Other authors^{3,5,18-20,27,31,32} have highlighted an association between STT-OA and the DISI pattern of deformity, albeit with an absence of dissociation or SL space widening. Therefore, the instability would be purely at the expense of lunate extension and increased radiolunate angle, with the SL angle remaining within the normal range. Wadhvani et al.³¹ reviewed radiographs of 697 wrists, and 63 (9%) presented STT-OA; of those, 16 (2.3% overall) had DISI. The prevalence of DISI in STT-OA was of 25%. They concluded that there is a strong relationship between those diagnoses, and that the degenerative process may precede the instability of the proximal row. Crosby et al.²⁰ demonstrated that patients with advanced stages of STT-OA exhibit lunate extension, which was present in 22 of the 45 cases of STT-OA that were assessed. Pinto et al.¹⁷ reported a patient with bilateral STT-OA and DISI, proposing that the STT lesion is caused by carpal instability. Tay et al.³² found DISI in 16 patients out of a total number of 36 with STT-OA, and that association was more common in postmenopausal women; half of those patients had bilateral changes. They stressed that STT-OA is associated with DISI deformity with neither SL space widening nor SL ligament injury, and named that a non-dissociative instability, without ligament injury within the same carpal row.

Unlike those authors, we consider that STT-OA is indeed associated with SL lesion and the absence of SL widening is due to the fixed scaphoid positioning, which does not move away from the lunate. Nonetheless, in most patients with STT-OA, although no evident SL widening (more than 4 mm)

is diagnosed, the space is increased when compared with the LT space, proving the existence of some degree of ligament injury, thus pointing to a carpal dissociative instability.

Tay et al.²⁷ also highlighted the association of STT-OA and midcarpal OA (50%), even though with no radiocarpal arthrosis. Furthermore, they showed that a history of trauma did not appear to be a causal factor, as a midcarpal degenerative lesion prior to treatment may be the cause of persistent symptoms in patients who have undergone operations due to STT-OA.^{27,33} We fully agree with this conclusion, and consider that midcarpal OA is a consequence of SL injury, and regard the DISI-type carpal instability as an evolutionary form of STT-OA.

In 1984, Watson and Ballet⁶ described the SLAC pattern of wrist degeneration as caused by carpal instability secondary to SL ligament traumatic injury. However, just as affirmed by us regarding the evolution of STT-OA (SOAC), other authors have already shown that SL ligament injury may occur without a high-energy trauma, which may be due to congenital ligament hyperlaxity, repetition microtrauma, chondrocalcinosis, or changes in wrist biomechanics. Those causes are more commonly observed in patients with bilateral wrist changes.^{28,34-36} Hollevoet³⁴ analyzed radiographs from both wrists of 1,000 people with no recent trauma, and found 67 of those cases of bilateral and 51 of unilateral SL space widening.³⁴ There were signs of SLAC in 26 wrists, and, of those, 9 were bilateral. Most patients did not recall any traumatic event. Picha et al.³⁵ reported that only 36% of patients with SL widening have a history of trauma, and that not all patients with SL space widening have OA, which may be explained by the short time of evolution. Higgison et al.¹⁹ emphasized that SL ligament injury after a low-energy trauma may sometimes be the trigger for a patient to become symptomatic.

Patients with STT-OA have intermittent symptoms, with painful bouts due to trauma, overactivity, and worsening during winter. The conservative treatment is often effective, and it should start with local measures such as ice packs, partial rest with or without the use of orthoses, oral anti-inflammatory drugs, and corticosteroid infiltration.¹⁸

When the conservative treatment fails, surgery is the next option. However, there is no consensus on the technique to be employed, and the indication ends up being a personal choice. We believe that it is impossible for a single technique to be employed for all different patient profiles or for all evolutionary stages of STT degenerative disease.

Scaphotrapeziotrapezoid arthrodesis, which has historically been considered the solution for this pathology, has shown to yield a high rate of complications that may result in up to 29% of nonunions.^{3,8,10,37-39} Watson et al.⁴⁰ reviewed 800 STT arthrodeses that were performed to treat different pathologies, and revealed that 13.5% of the patients had complications. Because of this, such technique has gradually fallen into oblivion. In addition, STT-OA may increase the burden on adjacent joints, and may not alleviate the symptoms of the patient. In our experience, despite treating the local inflammatory process, STT arthrodesis does not improve – and may even worsen – the symptoms in patients

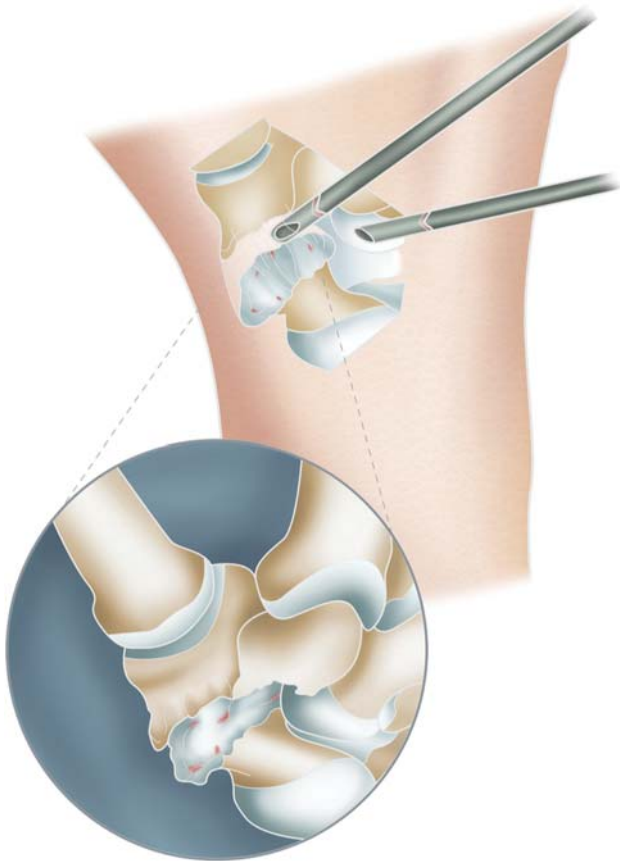


Fig. 6 the use of STT arthroscopy is important to define the correct stage of the SOAC.

with SOAC II and III, whose complaints also arise from carpal instability (DISI) and midcarpal OA. Therefore, arthrodesis is definitely not the solution for all patients with STT-OA.

Other procedures have also been proposed in an attempt to improve STT joint motion by reducing the local inflammatory process created by OA and the overloading of adjacent joints.^{3,10,30} Isolated arthroscopic debridement with synovectomy and osteophyte resection has demonstrated good results in the short term, with 90% of satisfaction in 3 years, but its long-term evolution and the use in advanced stages of the disease are not known.⁴¹

Another treatment option, as proposed by Garcia-Elias et al.,^{42–44} is the resection of the distal pole of the scaphoid. It requires less immobilization time and has fewer complications than arthrodesis, but can create midcarpal instability and DISI deformity, or even worsen such problems if already existent.^{30,45–47}

Most authors nowadays recommend the association of some type of carpal stabilization to the distal scaphoid resection.^{10,42–44} Some authors propose the use of metal interposition arthroplasties for such a purpose.^{15,18,48,49} Other authors have shown good results with distal resection of the scaphoid by arthroscopy. However, as with the open surgical modality, they have pointed out that it is not possible to remove more than 3 mm from the distal scaphoid due to the risk of causing DISI.^{8,30,41,48,50} Iida et al.⁵¹ assessed 16 patients treated with such technique, all of them without

previous DISI, and reported that out of 4 patients with a resection of more than 3 mm, 2 evolved to DISI. No one developed DISI in cases when less than 3 mm were resected.

We believe that the treatment for STT-OA should be guided by the stage of the disease. However, as in rhizarthrosis and other primary wrist arthroses, there is no direct correlation between the grade of STT-OA degeneration and symptom intensity or the degree of disability of the patient.

We acknowledge the problem of differentiating by means of simple radiographs, even when splitting STT-OA into three large groups. Just as Badia et al. did for rhizarthrosis, we believe that in the future, carpal arthroscopic staging will still be used to define the degree of evolution of a degenerative process under direct visualization and dynamic ligament testing (► Fig. 6).

The present article is the initial presentation of a theory. We have put together some pieces of this complex puzzle that is carpal functional anatomy and the STT-OA. Many of the ideas presented here are not original, since they were already available in the literature. We have so far tried to organize those ideas in a logical way. Currently, there are ongoing statistical studies to reveal the prevalence of each stage of STT-OA in the population, and to develop specific treatment protocols for each degenerative stage.

Conflict of Interests

The authors have no conflict of interests to declare.

References

- White L, Clavijo J, Gilula LA, Wollstein R. Classification system for isolated arthritis of the scaphotrapezotrapezoidal joint. *Scand J Plast Reconstr Surg Hand Surg* 2010;44(02):112–117
- Moritomo H, Viegas SF, Nakamura K, Dasilva MF, Patterson RM. The scaphotrapezio-trapezoidal joint. Part 1: An anatomic and radiographic study. *J Hand Surg Am* 2000;25(05):899–910
- Wolf JM. Treatment of scaphotrapezio-trapezoid arthritis. *Hand Clin* 2008;24(03):301–306, vii. Doi: 10.1016/j.hcl.2008.03.002
- Scordino LE, Bernstein J, Nakashian M, et al. Radiographic prevalence of scaphotrapezotrapezoid osteoarthritis. *J Hand Surg Am* 2014;39(09):1677–1682
- McLean JM, Turner PC, Bain GI, Rezaian N, Field J, Fogg Q. An association between lunate morphology and scaphoid-trapezium-trapezoid arthritis. *J Hand Surg Eur Vol* 2009;34(06):778–782. Doi: 10.1177/1753193409345201
- Watson HK, Ballet FL. The SLAC wrist: scapholunate advanced collapse pattern of degenerative arthritis. *J Hand Surg Am* 1984;9(03):358–365. Doi: 10.1016/s0363-5023(84)80223-3
- Wollstein R, Clavijo J, Gilula LA. Osteoarthritis of the Wrist STT Joint and Radiocarpal Joint. *Arthritis (Egypt)* 2012;2012:242159
- Pegoli L, Pozzi A. Arthroscopic Management of Scaphoid-Trapezium-Trapezoid Joint Arthritis. *Hand Clin* 2017;33(04):813–817. Doi: 10.1016/j.hcl.2017.07.017
- Eaton RG, Lane LB, Littler JW, Keyser JJ. Ligament reconstruction for the painful thumb carpometacarpal joint: a long-term assessment. *J Hand Surg Am* 1984;9(05):692–699. Doi: 10.1016/s0363-5023(84)80015-5
- Deans VM, Naqui Z, Muir LT. Scaphotrapezotrapezoidal Joint Osteoarthritis: A Systematic Review of Surgical Treatment. *J Hand Surg Asian Pac Vol* 2017;22(01):1–9. Doi: 10.1142/S0218810417300017
- Vender MI, Watson HK, Wiener BD, Black DM. Degenerative change in symptomatic scaphoid nonunion. *J Hand Surg Am* 1987;12(04):514–519. Doi: 10.1016/s0363-5023(87)80198-3

- 12 Krakauer JD, Bishop AT, Cooney WP. Surgical treatment of scapholunate advanced collapse. *J Hand Surg Am* 1994;19(05):751-759. Doi: 10.1016/0363-5023(94)90178-3
- 13 Lluch A. Concepto de muñeca SNAC: Scaphoid Non-union Advanced Collapse. *Rev Ortop Traumatol (B Aires)* 1998;42(Suppl 1):33-38
- 14 Davey PA, Belcher HR. Scapho-trapezio-trapezoidal joint osteoarthritis. *Hand Surgery. VOLUME* 2001;15(03):220-228. Doi: 10.1054/cuor.2001.0189
- 15 Humada Álvarez G, Simón Pérez C, García Medrano B, et al. Tratamiento de la artrosis escafotrapeziotrapezoidea aislada con artroplastia de recubrimiento con anclaje escafoideo. *Rev Esp Cir Ortop Traumatol* 2017;61(06):412-418. Doi: 10.1016/j.recot.2017.05.004
- 16 Sicre G, Laulan J, Rouleau B. Scaphotrapeziotrapezoid osteoarthritis after scaphotrapezial ligament injury. *J Hand Surg [Br]* 1997;22(02):189-190. Doi: 10.1016/s0266-7681(97)80059-9
- 17 Pinto CH, Obermann WR, Deijkers RL. Nontraumatic multidirectional instability of the scaphotrapeziotrapezoid joint: a cause of scaphotrapeziotrapezoid osteoarthritis and static distal intercalated segment instability. *J Hand Surg Am* 2003;28(05):744-750. Doi: 10.1016/s0363-5023(03)00302-2
- 18 Kapoutsis DV, Dardas A, Day CS. Carpometacarpal and scaphotrapeziotrapezoid arthritis: arthroscopy, arthroplasty, and arthrodesis. *J Hand Surg Am* 2011;36(02):354-366. Doi: 10.1016/j.jhsa.2010.11.047
- 19 Higginson AP, Braybrook J, Williams S, Finlay D. Isolated scaphotrapeziotrapezoid osteoarthritis: prevalence, symptomatology and associated scapholunate ligament disruption in a population presenting to an accident and emergency department with acute wrist injuries. *Clin Radiol* 2001;56(05):372-374
- 20 Crosby EB, Linscheid RL, Dobyns JH. Scaphotrapezial trapezoidal arthrosis. *J Hand Surg Am* 1978;3(03):223-234. Doi: 10.1016/s0363-5023(78)80086-0
- 21 Chen C, Chandnani VP, Kang HS, Resnick D, Sartoris DJ, Haller J. Scapholunate advanced collapse: a common wrist abnormality in calcium pyrophosphate dihydrate crystal deposition disease. *Radiology* 1990;177(02):459-461. Doi: 10.1148/radiology.177.2.2217785
- 22 Resnick D, Niwayama G, Goergen TG, et al. Clinical, radiographic and pathologic abnormalities in calcium pyrophosphate dihydrate deposition disease (CPPD): pseudogout. *Radiology* 1977;122(01):1-15. Doi: 10.1148/122.1.1
- 23 Resnick D. SLAC wrist. *J Hand Surg Am* 1985;10(01):154-155. Doi: 10.1016/s0363-5023(85)80271-9
- 24 Romano S. [Non-traumatic osteoarthritis of the wrist: chondrocalcinosis]. *Chir Main* 2003;22(06):285-292. Doi: 10.1016/j.main.2003.09.012
- 25 Saffar P. Chondrocalcinosis of the wrist. *J Hand Surg [Br]* 2004;29(05):486-493. Doi: 10.1016/j.jhsb.2004.02.013
- 26 Moritomo H, Tada K, Yoshida T, Masatomi T. The relationship between the site of nonunion of the scaphoid and scaphoid nonunion advanced collapse (SNAC). *J Bone Joint Surg Br* 1999;81(05):871-876. Doi: 10.1302/0301-620x.81b5.9333
- 27 Tay SC, Moran SL, Shin AY, Linscheid RL. The clinical implications of scaphotrapezium-trapezoidal arthritis with associated carpal instability. *J Hand Surg Am* 2007;32(01):47-54
- 28 Wadhvani A, Carey J, Propeck T, Hentzen P, Eustace S. Isolated scaphotrapeziotrapezoid osteoarthritis: a possible radiographic marker of chronic scapholunate ligament disruption. *Clin Radiol* 1998;53(05):376-378
- 29 Viegas SF, Patterson RM, Hokanson JA, Davis J. Wrist anatomy: incidence, distribution, and correlation of anatomic variations, tears, and arthrosis. *J Hand Surg Am* 1993;18(03):463-475. Doi: 10.1016/0363-5023(93)90094-J
- 30 Casañas Sintés J. Resección artroscópica del polo distal del escafoideo en la artrosis escafo-trapezio-trapezoidea. *Rev Iberoam Cir Mano* 2013;41(01):57-62. Doi: 10.1055/s-0037-1607087
- 31 Ferris BD, Dunnett W, Lavelle JR. An association between scaphotrapezio-trapezoid osteoarthritis and static dorsal intercalated segment instability. *J Hand Surg [Br]* 1994;19(03):338-339. Doi: 10.1016/0266-7681(94)90084-1
- 32 Gilula LA. Dorsal intercalated segment instability (DISI) and scaphotrapezio-trapezoid (STT) osteoarthritis. *J Hand Surg [Br]* 1995;20(02):264. Doi: 10.1016/s0266-7681(05)80072-5
- 33 Katzel EB, Bielicka D, Shakir S, Fowler J, Buterbaugh GA, Imbriglia JE. Midcarpal and Scaphotrapeziotrapezoid Arthritis in Patients with Carpometacarpal Arthritis. *Plast Reconstr Surg* 2016;137(06):1793-1798. Doi: 10.1097/PRS.0000000000002160
- 34 Hollevoet N. Bilateral scapholunate widening may have a nontraumatic aetiology and progress to carpal instability and osteoarthritis with advancing age. *J Hand Surg Eur Vol* 2019;44(06):566-571
- 35 Picha BM, Konstantakos EK, Gordon DA. Incidence of bilateral scapholunate dissociation in symptomatic and asymptomatic wrists. *J Hand Surg Am* 2012;37(06):1130-1135
- 36 Pollock J, Giachino AA, Rakhra K, et al. SLAC wrist in the absence of recognised trauma and CPPD. *Hand Surg* 2010;15(03):193-201. Doi: 10.1142/S0218810410004837
- 37 Srinivasan VB, Matthews JP. Results of scaphotrapeziotrapezoid fusion for isolated idiopathic arthritis. *J Hand Surg [Br]* 1996;21(03):378-380. Doi: 10.1016/s0266-7681(05)80208-6
- 38 Houvet P. Intercarpal fusions: indications, treatment options and techniques. *EFORT Open Rev* 2017;1(02):45-51. Doi: 10.1302/2058-5241.1.000019
- 39 Weiss KE, Rodner CM. Osteoarthritis of the wrist. *J Hand Surg Am* 2007;32(05):725-746. Doi: 10.1016/j.jhsa.2007.02.003
- 40 Watson HK, Wollstein R, Joseph E, Manzo R, Weinzweig J, Ashmead D IV. Scaphotrapeziotrapezoid arthrodesis: a follow-up study. *J Hand Surg Am* 2003;28(03):397-404. Doi: 10.1053/jhsu.2003.50072
- 41 Ashwood N, Bain GI, Fogg Q. Results of arthroscopic debridement for isolated scaphotrapeziotrapezoid arthritis. *J Hand Surg Am* 2003;28(05):729-732
- 42 Garcia-Elias M. Excisional arthroplasty for scaphotrapeziotrapezoidal osteoarthritis. *J Hand Surg Am* 2011;36(03):516-520
- 43 Garcia-Elias M, Lluch AL, Farreres A, Castillo F, Saffar P. Resection of the distal scaphoid for scaphotrapeziotrapezoid osteoarthritis. *J Hand Surg [Br]* 1999;24(04):448-452. Doi: 10.1054/jhsb.1999.0169
- 44 Garcia-Elias M, Lluch A, Saffar P. Distal scaphoid excision in scaphoid-trapezium-trapezoid arthritis. *Tech Hand Up Extrem Surg* 1999;3(03):169-173. Doi: 10.1097/00130911-199909000-00004
- 45 Luchetti R, Atzei A, Cozzolino R. Arthroscopic Distal Scaphoid Resection for Scapho-Trapezium-Trapezoid Arthritis. *Hand (N Y)* 2019;1558944719864451:1558944719864451. Doi: 10.1177/1558944719864451
- 46 Berkhout MJ, Bachour Y, Wessing D, Ritt MJPF. Distal Pole Resection of the Scaphoid for the Treatment of Scaphotrapeziotrapezoid Osteoarthritis. *Hand (N Y)* 2019;14(02):230-235. Doi: 10.1177/1558944717735939
- 47 Langenhan R, Hohendorff B, Probst A. Trapeziectomy and ligament reconstruction tendon interposition for isolated scaphotrapeziotrapezoid osteoarthritis of the wrist. *J Hand Surg Eur Vol* 2014;39(08):833-837. Doi: 10.1177/1753193413514500
- 48 Mathoulin C, Darin F. Arthroscopic treatment of scaphotrapeziotrapezoid osteoarthritis. *Hand Clin* 2011;27(03):319-322. Doi: 10.1016/j.hcl.2011.05.001
- 49 Gauthier E, Truffandier MV, Gaisne E, Bellemère P. Treatment of scaphotrapeziotrapezoid osteoarthritis with the Pyrocardan® implant: Results with a minimum follow-up of 2 years. *Hand Surg Rehabil* 2017;36(02):113-121. Doi: 10.1016/j.hansur.2017.01.003
- 50 Cobb T, Sterbank P, Lemke J. Arthroscopic resection arthroplasty for treatment of combined carpometacarpal and scaphotrapeziotrapezoid (pantrapezial) arthritis. *J Hand Surg Am* 2011;36(03):413-419
- 51 Iida A, Omokawa S, Kawamura K, Shimizu T, Onishi T, Tanaka Y. Arthroscopic Distal Scaphoid Resection for Isolated Scaphotrapeziotrapezoid Osteoarthritis. *J Hand Surg Am* 2019;44(04):337.e1-337.e5