Article published online: 2020-12-28

A Novel Method to Prevent Migration of Gastric Stent

Vikas Singla[1] Shivam Khare[1] Anil Arora[1] Shrihari Anil Anikhindi[1]

[1]Institute of Liver, Gastroenterology and Pancreaticobiliary Sciences, Sir Ganga Ram Hospital, New Delhi, India

Address for correspondence Vikas Singla, DM, Institute of Liver, Gastroenterology and Pancreaticobiliary Sciences, Sir Ganga Ram Hospital, Rajinder Nagar, New Delhi 110060, India (e-mail: singlavikas1979@gmail.com).

J Digest Endosc 2021;12:177–178.

Abstract

Self expandable metal stent (SEMS) are widely used in patients with gastric outlet obstruction. Stent migration can occur in these patients, and is an important issue, which needs to be addressed. We used a novel technique for prevention of migration of gastric stent in an 80 year old female. Patient presented with recurrent vomiting due to gastric outlet obstruction by a growth in the antrum. SEMS was placed for palliation of symptoms. A nylon thread multiloop and through the scope clips were used to fix the SEMS with the gastric wall. The technique was used successfully to prevent the migration of SEMS.

Keywords
- gastric outlet obstruction
- migration
- self-expandable metal stent

Self-expandable metal stents (SEMS) has been widely used for palliation of symptoms in patients with malignant gastric outlet obstruction. Stent migration has been reported in 19% and 6% of patients with covered and uncovered stent respectively[1] and can lead to serious complications. We have used a novel method for the prevention of migration of pyloric stent. An 80-year-old female presented with a history of vomiting for the last 3 months. Upper gastrointestinal endoscopy revealed growth with partial narrowing in antrum, narrowed segment measured 2 cm in length, and 9.2 mm scope was passable with maneuvering. Histopathology revealed poorly differentiated adenocarcinoma. A 22 mm, 9 cm uncovered SEMS with proximal flange of 27 mm (Wallflex, Boston Scientific Corp, Massachusetts, United States) was placed (►**Fig. 1A**) for palliation of symptoms. As the narrowing was partial, endoscopic fixation of stent was planned to prevent migration. We used multiloop and clips to fix the stent to the gastric wall. Multiloop technique has been used previously for assistance in endoscopic submucosal dissection.[2] Loops of nylon thread were prepared over 2 mL syringe, and multiple knots were applied at each of the three loops. (►**Fig. 1B**). Hemoclip (EZ clip, Olympus Medical System, Gurugram, India) was passed through the accessory channel of endoscope, and the loop was grasped (►**Fig. 2A**) and partially withdrawn inside the channel. Gastroscope was passed till the proximal flange of the stent, 1 clip was used on stent and 3 on the loops. (►**Fig. 2B**). Stent and clips are still in the same position at 4 weeks of follow-up, and patient is able to take semisolid diet.

Various techniques such as double layered stents,[3] big funnel stents with large flare,[4] and fixation with clips[5] have been used previously for the prevention of migration of the stent. In the present case, we have tried to fix the pyloric stent with the easily available accessories without significant addition of the cost to the procedure. The technique may be particularly useful in conditions where risk of migration is predicted to be high, such as placement of covered stent for benign indication, in patients with partial narrowing of lumen, or previous history of stent migration.

Authors Contribution

Vikas Singla wrote the manuscript. Shivam Khare collected all the images and wrote the manuscript. Anil Arora designed the work and wrote the manuscript. Shrihari Anil Anikhindi wrote the manuscript.

DOI https://doi.org/10.1055/s-0040-1721222
ISSN 0976-5042.

© 2020. Society of Gastrointestinal Endoscopy of India.
This is an open access article published by Thieme under the terms of the Creative Commons Attribution-NonDerivative-NonCommercial-License, permitting copying and reproduction so long as the original work is given appropriate credit. Contents may not be used for commercial purposes, or adapted, remixed, transformed or built upon. (https://creativecommons.org/licenses/by-nc-nd/4.0/)
Thieme Medical and Scientific Publishers Pvt. Ltd., A-12, 2nd Floor, Sector 2, Noida-201301 UP, India

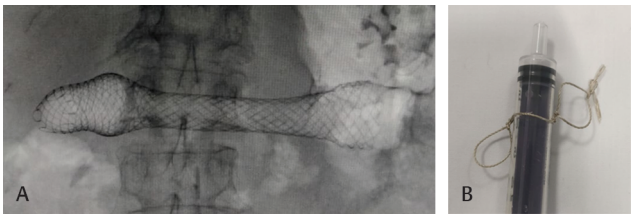

Fig. 1 (**A**) Self-expandable metal stent placed across the pylorus. (**B**) Preparation of multiloop over the 2 mL syringe.

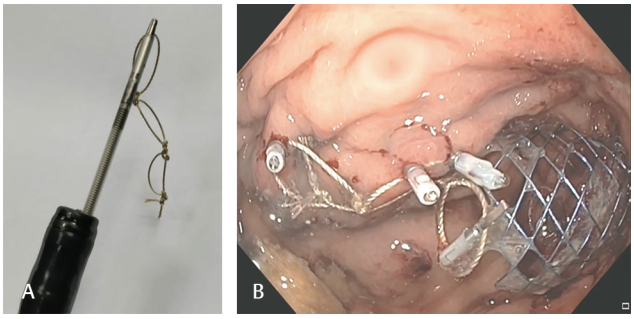

Fig. 2 (**A**) Passage of Hemoclip through the accessory channel of the scope, and grasping of multiloop. (**B**) Fixation of self-expandable metal stent to the gastric wall.

Conflict of Interest

All the authors declared no conflict of interest.

References

1 Jeurnink SM, van Eijck CH, Steyerberg EW, Kuipers EJ, Siersema PD. Stent versus gastrojejunostomy for the palliation of gastric outlet obstruction: a systematic review. BMC Gastroenterol 2007;7:18
2 Suzuki Y, Tanuma T, Nojima M, et al. Multiloop as a novel traction method in accelerating colorectal endoscopic submucosal dissection. Gastrointest Endosc 2020;91(1):185–190
3 Lee SM, Kang DH, Kim GH, Park WI, Kim HW, Park JH. Self-expanding metallic stents for gastric outlet obstruction resulting from stomach cancer: a preliminary study with a newly designed double-layered pyloric stent. Gastrointest Endosc 2007;66(6):1206–1210
4 Shi D, Bao YS, Liu YP. Individualization of metal stents for management of gastric outlet obstruction caused by distal stomach cancer: a prospective study. Gastrointest Endosc 2013; 78(2):277–284
5 Kim ID, Kang DH, Choi CW, et al. Prevention of covered enteral stent migration in patients with malignant gastric outlet obstruction: a pilot study of anchoring with endoscopic clips. Scand J Gastroenterol 2010;45(1):100–105

 © 2020. Society of Gastrointestinal Endoscopy of India.