









Pediatric Patient with Lemierre Syndrome of the External Jugular Vein: Case Report and Literature Review

Yehuda Schwarz¹  Nadeem Habashi¹  Noa Rosenfeld-Yehoshua²  Eugene Soikher³ 
Tal Marom¹  Sharon Ovnat Tamir¹ 

¹ Department of Otolaryngology Head and Neck Surgery, Samson Assuta Ashdod University Hospital, Faculty of Health Sciences, Ben Gurion University of the Negev, Ashdod, Israel

² Department of Pediatric Intensive Care Unit, Samson Assuta Ashdod University Hospital, Faculty of Health Sciences, Ben Gurion University of the Negev, Ashdod, Israel

³ Department of Radiology, Samson Assuta Ashdod University Hospital, Faculty of Health Sciences, Ben Gurion University of the Negev, Ashdod, Israel

Address for correspondence Yehuda Schwarz, MD, Department of Otolaryngology- Head and Neck Surgery, Samson Assuta Ashdod University Hospital, 7, Ha'Refua Street, 7747629, Ashdod, Israel (e-mail: yehuda.schwarz@yahoo.com).

Int Arch Otorhinolaryngol 2021;25(4):e633–e640.

Abstract

Introduction Lemierre syndrome (LS) involving the external jugular vein (EJV) is rare, and only a few cases have been reported in the literature.

Objectives To report a case of LS involving the external jugular vein as well as to make a review of the literature regarding both diagnosis and management strategies.

Data Synthesis We describe a case of LS involving the EJV and review the literature of previously published articles to search for additional cases. A PubMed, Embase, Scopus, and Web of science-based search was performed to determine the scope of coverage in well-reported articles in English. Twenty-one papers were retrieved and documented for age, incidence, pathogen, presenting symptoms, imaging, treatment, and outcome, which were noted for each of these cases. In our literature review of 21 papers, there were 16 patients (61%) in their 2nd and 3rd decades of life. Lemierre syndrome was shown to affect females and males equally. The presenting symptoms were a sore throat and fever. Treatment requires intravenous antibiotics, and there is no consensus regarding treatment with anticoagulation.

Conclusions The present case report and review of the literature emphasize the importance of history taking as well as physical examination in what seems to be a case of simple tonsillitis.

Keywords

- ▶ Lemierre syndrome
- ▶ external jugular vein
- ▶ pharyngitis
- ▶ thrombosis

Introduction

>A common complaint in the pediatric population is a “sore throat.” Physicians should be aware that, in rare cases, this common symptom may develop into a potentially life-

threatening disease called Lemierre syndrome (LS). Lemierre syndrome is a disease characterized with the evolution of septic thrombophlebitis of the internal jugular vein (IJV) secondary to local spread of infection, usually

received
April 16, 2020
accepted
October 2, 2020
published online
February 19, 2021

DOI <https://doi.org/10.1055/s-0040-1721337>.
ISSN 1809-9777.

© 2021. Fundação Otorrinolaringologia. All rights reserved.
This is an open access article published by Thieme under the terms of the Creative Commons Attribution-NonDerivative-NonCommercial-License, permitting copying and reproduction so long as the original work is given appropriate credit. Contents may not be used for commercial purposes, or adapted, remixed, transformed or built upon. (<https://creativecommons.org/licenses/by-nc-nd/4.0/>)
Thieme Revinter Publicações Ltda., Rua do Matoso 170, Rio de Janeiro, RJ, CEP 20270-135, Brazil

Table 1 Characteristics of the literature review

Title	Year	Age (years)	Sex	Side	Presentation	Pathogen	Thrombosis	Treatment	Outcome
Lemierre's syndrome: Acute oropharyngeal infection leading to septic thrombophlebitis of the internal jugular vein with pulmonary septic emboli	2019	12	Male	Left	Fever, sore throat, and neck swelling	<i>Streptococcus constellatus</i>	Ext jugular + Int jugular	Antibiotics	Completely recovered
Fissuration of vertebral artery mycotic aneurysm due to Lemierre syndrome	2018	26	Female	Left	Shortness of breath, weakness, hypokinesia on the right arm	N/A	Ext jugular Right vertebral artery septic false aneurysm	Antibiotics Surgery Embolization	N/A
Lemierre Syndrome: A Retrospective Study of the Role of Anticoagulation and Thrombolysis Outcomes	2017	16 18 32 42	Female Male Male Male	Right Left Left Left	N/A N/A N/A N/A	N/A N/A N/A N/A	Ext jugular + Int jugular Ext jugular Ext jugular Ext jugular	Antibiotics Antibiotics Anticoagulation Antibiotics Anticoagulation	Partial response Complete response Complete response
Lemierre's Syndrome Variant with External Jugular Vein Thrombosis	2017	51	Female	Left	Fever Sore throat Jaw pain	Group C streptococcus	Ext jugular	Antibiotics	Completely recovered
To anticoagulate? Controversy in the management of thrombotic complications of head & neck infections	2016	17	Male	N/A	Peritonsillar abscess	Unknown	Ext jugular + Int jugular	Antibiotics Anticoagulation	Residual VII palsy
MRSA-Associated Lemierre's Syndrome in an Intravenous Drug User	2015	24	Female	Right	Odontogenic Fever, neck pain Odynophagia	<i>Fusobacterium necrophorum</i> Methicillin-resistant <i>Staphylococcus aureus</i> (MRSA)	Ext jugular + Int jugular Ext jugular + Int jugular	Antibiotics Anticoagulation Abscess drainage	Completely recovered Completely recovered
Lemierre syndrome involving external jugular vein	2014	74	Female	Left	Pharyngeal pain Cold symptoms	<i>Fusobacterium nucleatum</i>	Ext jugular	Antibiotics Anticoagulation	Completely recovered
Lemierre's syndrome secondary to community-acquired methicillin-resistant <i>Staphylococcus aureus</i> infection presenting with	2014	45	Female	Left	Sore throat and mild fever	Methicillin-resistant <i>Staphylococcus aureus</i> (MRSA)	Ext jugular + Int jugular Subclavian and axillary veins	Antibiotics Anticoagulation	Completely recovered

Table 1 (Continued)

Title	Year	Age (years)	Sex	Side	Presentation	Pathogen	Thrombosis	Treatment	Outcome
cardiac tamponade, a rare disease with a life-threatening presentation: a case report									
Lemierre syndrome: a pediatric case series and review of literature	2010	16	Male	Right	Fever, sore throat, right neck pain, right facial swelling, and right eye	<i>Fusobacterium necrophorum</i>	Ext jugular +Int jugular	Antibiotics Anticoagulation	Completely recovered
An unusual case of Lemierre's syndrome due to methicillin-resistant <i>Staphylococcus aureus</i>	2010	33	Female	Bilateral	Face and neck swelling Dyspnea Hoarseness	Methicillin-resistant <i>Staphylococcus aureus</i> (MRSA)	Ex jugular +Int jugular	Antibiotics	Completely recovered
A teenager with sore throat and neck pain	2010	15	Female	Right	Fever, joint pain, shortness of breath	<i>Fusobacterium necrophorum</i>	Ex jugular	Antibiotics Anticoagulation	Completely recovered
Lemierre Syndrome Following Oropharyngeal Infection: A Case Series	2009	19	Female	Right	Sore throat, low-grade fever, and malaise	<i>Fusobacterium necrophorum</i>	Ex jugular	Antibiotics	Completely recovered
Lemierre's syndrome with fourth nerve palsy	2009	3	Male	Left	Fever, sore throat, and intermittent headache	<i>Streptococcus viridians</i> , <i>Streptococcus salivarius</i>	Ex jugular +Int jugular	Antibiotics Anticoagulation	IV nerve palsy
A Lemierre syndrome variant caused by <i>Staphylococcus aureus</i>	2008	22	Female	Right	Oropharyngeal infection Facial cellulitis	<i>Staphylococcus aureus</i>	Ext jugular +Int jugular	Antibiotics Anticoagulation Surgery	Completely recovered
Case 2: An unusual presentation of an unusual condition (Case Presentation)	2008	14	Female	Left	Sore throat	Unknown	Ex jugular	Antibiotics Anticoagulation Surgery	Completely recovered
Lemierre's syndrome: three cases and a review	2005	28	Female	Right	Sore throat Fever	<i>Fusobacterium necrophorum</i>	Ext jugular +Int jugular	Antibiotics	Completely recovered
Cerebral infarctions and brain abscess due to Lemierre syndrome	2005	59	Male	Left	Temporal pain Dentoalveolitis Right maxillary abscess	Unknown	Ext jugular	Antibiotics Anticoagulation	Improved
Unusual presentation of Lemierre's syndrome due to <i>Fusobacterium nucleatum</i>	2003	19	Male	Right	Fever, rigors, sore throat, pleuritic chest pain, and productive cough	<i>Fusobacterium nucleatum</i>	Ext jugular	Antibiotics Anticoagulation	Completely recovered

(Continued)

Table 1 (Continued)

Title	Year	Age (years)	Sex	Side	Presentation	Pathogen	Thrombosis	Treatment	Outcome
Postanginal septicaemia with external jugular venous thrombosis: case report	1999	49	Male	Right	with blood-tinged sputum Anterior gingiva trauma	<i>Klebsiella pneumoniae</i>	Ext jugular	Antibiotics Anticoagulation	Completely recovered
Lemierre syndrome: forgotten but not extinct—report of four cases	1999	22	Male	Right	Fever, cough, mild sore throat, weight loss	Enterococcus species	Ext jugular + Int jugular	Antibiotics	Completely recovered
A case of Lemierre syndrome	1998	30	Male	Left	Cold symptoms Lockjaw, facial pain	Unknown	Ext jugular	Antibiotics Anticoagulation	Completely recovered
Present study	2019	17	Female	Left	Sore throat Fever	Unknown	Ext jugular	Antibiotics Anticoagulation	Completely recovered

originating in the oropharyngeal cavity. It may be complicated by disseminated infections with more distal emboli, most frequently to the lungs. Presenting symptoms include pharyngotonsillitis or peritonsillar abscess, followed by ipsilateral painful swelling of the neck, fever, odynophagia, dysphagia, trismus, and other systemic symptoms. Lemierre syndrome typically involves the IJV, but the involvement of the external jugular vein (EJV) has rarely been reported.

We present a unique case of LS involving the EJV following an episode of tonsillitis and review the literature regarding LS involving the EJV.

Case Report

The ethics committee of our institution waived the need for ethics approval and the need to obtain consent for this report. We present a unique case of LS involving the EJV followed by a literature review (►Table 1).

We present the case of an otherwise healthy 17-year-old girl who arrived at the pediatric emergency department (PED) presenting with lymphadenitis, pleuritic chest pain, and fever. She was diagnosed with tonsillitis a week prior to admission and was started on oral antibiotics. Due to a negative throat culture, she received only 3 doses of oral antibiotics that were discontinued. Three days prior to her arrival, she began suffering from left submandibular lymphadenitis, tenderness, and trismus. On the morning of her arrival she complained of chest pain and dyspnea.

On arrival, she was alert and oriented and had a temperature of 38.3 Celsius, tachycardia of 116 beats/min, and a normal blood pressure. On physical examination, there was swelling with extreme tenderness on palpation over the left cheek and neck (►Fig. 1). Throat examination revealed a swollen left tonsil covered with exudates, and multiple left lymphadenopathies of the Jugulodigastric region were palpated. Laboratory analysis revealed an elevated white blood count of 14.2×10^6 cells/L (norm 4.0–11.0), elevated C-reactive protein of 57 mg/L (norm ≤ 5), and all other laboratory examinations were unremarkable. Blood cultures were negative.

A Doppler ultrasound study was performed revealing enlarged cervical lymph nodes with small areas of necrosis and thrombosis of the left EJV. Due to this finding, the patient was referred for a neck contrast-enhanced computed tomography (CT) scan that demonstrated signs of extensive deep neck infection with lymphadenopathy and EJV and facial vein thrombosis (►Fig. 2A&B). An anatomical variant was noted, with anomalous facial vein drainage into the EJV (►Fig. 3). The lung apices demonstrated 2 small nodular ground glass opacities that, in the context of the EJV infective thrombophlebitis, may be suggestive of a metastatic infection. The patient's respiratory symptoms improved, and her chest X-ray was normal, so we decided not to perform a lung CT scan.

The patient was hospitalized in the pediatric intensive care unit (PICU) and treated with broad spectrum intravenous antibiotics (amoxicillin-clavulanic acid), which was switched to ceftriaxone and metronidazole as well as

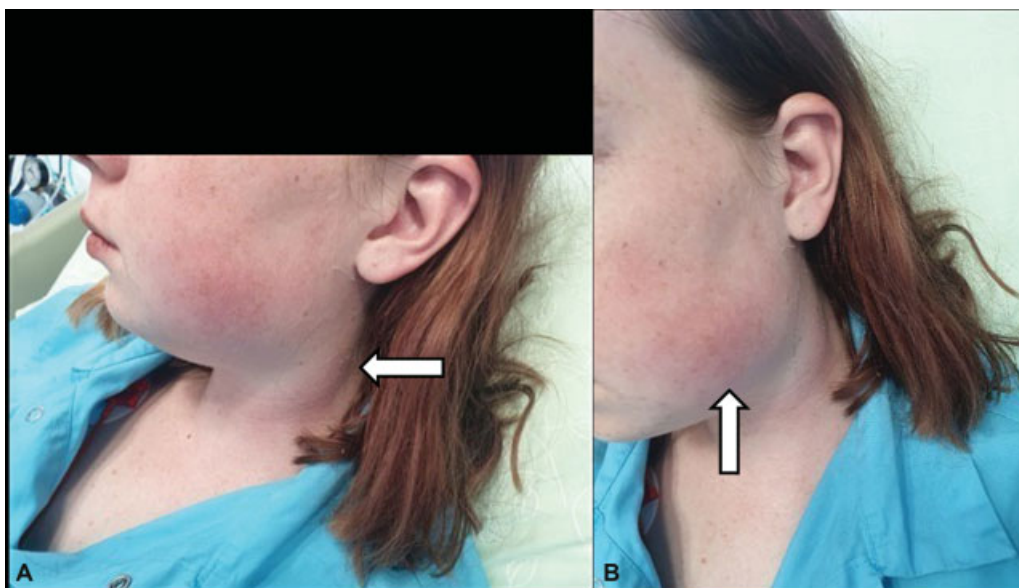

Fig. 1 (A) Hyperemia and edema of the left neck along the sternocleidomastoid muscle (arrow) (B) Hyperemia and edema of the left cheek and mandibular region (arrow).

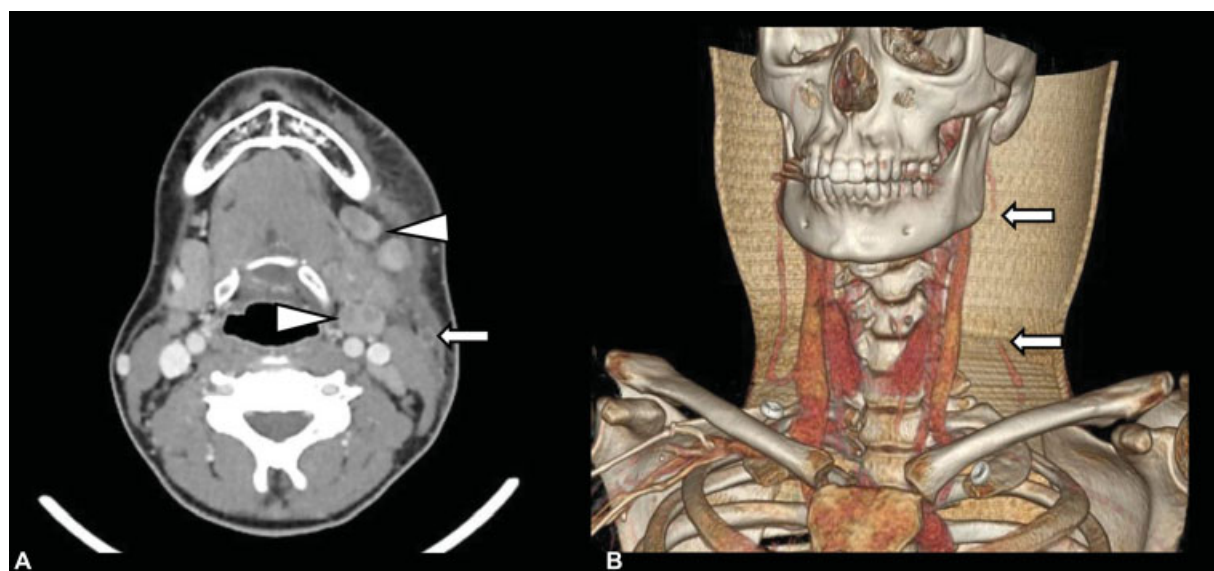


Fig. 2 Contrast-enhanced computed tomography (A) Axial view demonstrating extensive soft tissue swelling in the upper neck with necrotic lymph nodes in both levels 1 and 2 (arrowheads) and thrombosis of the external jugular vein with vessel wall enhancement (arrow) (B) 3D reconstruction showing no filling of contrast material in the middle third of the external jugular vein (between arrows).

anticoagulation therapy (enoxaparin) following the diagnosis of LS. Her hospitalization and follow-up were uneventful.

Review of the Literature

Methods

We identified studies published in English language by searching electronic databases. The search was performed on multiple databases, which included: PubMed, Embase, Scopus, and Web of Science. Our search for the following medical subject headings (MESH) terms: *suppurative thrombophlebitis* OR *septic thrombophlebitis* OR *Lemierre syndrome* AND *external jugular* revealed 21 relevant articles.

Inclusion and Exclusion Criteria

Inclusion Criteria

Studies detailing the findings of patients with LS and EJV thrombosis were included. We also included retrospective studies and case reports. Only studies in English language were included. Letters, commentaries, and abstracts were eligible for evaluation.

Exclusion Criteria

Studies not specifying external jugular thrombosis in the patients. Papers without radiological evidence of thrombophlebitis were also excluded.

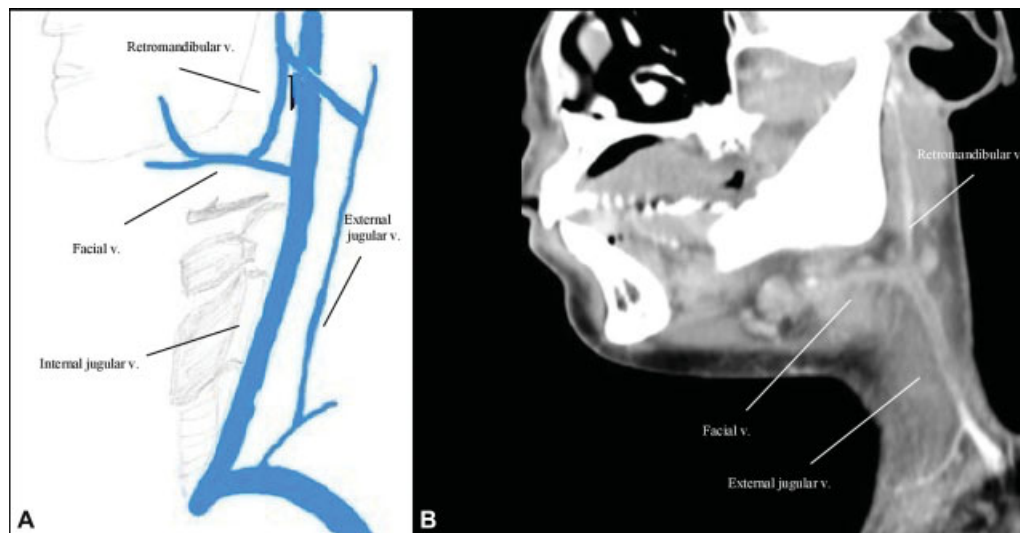


Fig. 3 (A) Normal vascular anatomy of the neck (B) Contrast enhanced computed tomography (curved multiplanar reformation reconstruction) displaying the thrombus of the external jugular and facial veins.

Data Extraction

The extracted data included anatomical considerations, age and incidence, sex, pathogens, presenting symptoms, imaging, management, and outcomes.

Discussion

The classical description of LS was published in 1936 as thrombophlebitis of the tonsillar or peritonsillar veins that can spread to the internal jugular vein (IJV).¹ The variant of LS involving the EJV is rare. In the patient discussed in the present article, LS involved the EJV and not the IJV.

Anatomical Considerations

The anatomy of tonsillar venous drainage is via the peritonsillar plexus, which drains into the lingual and pharyngeal veins, which, in turn, drain into the IJV. The EJV is formed by the connection of the posterior division of the retromandibular vein with the posterior auricular vein (→ Fig. 3A). To explain the formation of a thrombus in the EJV, an anatomical variant should be considered. The facial vein, which is part of the tonsillar drainage, may have a variant. In our case, the facial vein drained directly into the EJV and not into the IJV (→ Fig. 3B). This anatomical variant is not rare and is found in 9% of the population.² In 12 patients described in our review of the literature, the thrombosis involved the EJV and IJV. This could be explained by the inflammation ascending in a retrograde manner into the EJV or by the anatomical variation of the cervical venous drainage.² Another explanation for the involvement of the IJV is by septic emboli of this infection through the mucosa. This is followed by local invasion of the lateral pharyngeal space and IJV septic thrombophlebitis. A primary infection, such as Epstein-Barr virus (EBV), may facilitate the penetration of the mucosa.³ This local involvement may eventually progress to involve the EJV.

Age and Incidence

Lemierre syndrome occurs mostly in the 2nd and 3rd decades of life. In our review, there were 16 patients (61%) in their 2nd

and 3rd decades of life.^{4–15} A review by Karkos et al. revealed 51% incidence rate in the 2nd decade.¹⁶ Although this is mainly a young age group disease, in our review, LS was also found to be present in the 5th to 8th decades of life.^{6,17–21} Males are more commonly affected,⁴ although for EJV thrombosis, there is an equal gender distribution.

The annual incidence of LS is reported to be 3.6 per million persons/year. In the young age group (14 – 24 years of age), in which LS has been found to occur more frequently, the annual incidence is 14.4 cases/million.²² Due to the paucity of reports regarding LS involving the EJV, we estimate that the incidence is even lower.

Pathogen

The pathogen most commonly isolated in LS is *Fusobacterium necrophorum*, which is an anaerobic, gram negative bacteria. In our case, the culture was negative, similar to 4 of the reviewed cases.^{5,10,20,23} In 10 to 15% of the cases, no organism was identified.²⁴ Other bacteria that might cause LS include group C streptococcus, *Klebsiella pneumoniae* and Enterococcus species. An interesting finding is that methicillin-resistant *Staphylococcus aureus* (MRSA) was found in 3 cases,^{13,21,25} and polymicrobial infections were found in 10 to 30% of cases.³

Presenting Symptoms

Our patient was diagnosed with tonsillitis, which then progressed to left submandibular lymphadenitis, cheek and neck tenderness upon palpation, trismus, and dyspnea. It is notable that LS is diagnosed clinically, and should be taken into consideration, when respiratory symptoms or neck swelling occur a week following a throat infection. Righini et al. described LS as developing in 2 clinical phases; the primary phase, which corresponds to an oropharyngeal infection of the mucosa, with or without signs of peritonsillar abscess, fever, and cervical lymphadenopathy and the secondary phase, with the spreading of infection to the parapharyngeal space with thrombophlebitis of the IJV and

sepsis. During the 2nd stage, clinical examination reveals painful skin induration and inflammation anterior to the sternocleidomastoid muscle ipsilateral to oropharyngeal infection.²⁶ In our case, as well as in the reviewed literature cases involving the EJV, the presenting symptoms were sore throat and fever.^{3,4,7,8,12,14,18,21,27} These symptoms, usually indicate involvement of the peri(tonsillar) area. As for the side involving thrombophlebitis of the EJV, the left side was more often involved.

Imaging

In our case, the diagnosis of LS was made by ultrasonography (US). This was followed by a contrast-enhanced CT scan to enable better assessment of the blood vessels, to evaluate the extent of the inflammatory process and to rule out potential complications.

There are 3 imaging modalities that can yield the diagnosis of LS. Doppler US is an available tool that can detect JV thrombosis; however, it is operator-dependent and may be less sensitive in the area deep to clavicle or below the mandible.

Magnetic resonance imaging (MRI) is an excellent modality to assess anatomic structures and to demonstrate venous thrombosis; however, it is expensive, not readily available, and requires either sedation or general anesthesia in younger patients.

Computed tomography with contrast material has been shown to be the modality of choice for the diagnosis of LS.^{28,29} It is cheaper and is available in most hospital settings, though it involves radiation exposure. It can accurately demonstrate signs of infection and detect thrombosis of cervical veins. Furthermore, CT is the modality of choice for the diagnosis of regional or distant complications, such as abscesses, metastatic pulmonary or systemic infection.

Treatment

There is no consensus regarding the treatment of LS. The treatment requires antibiotics, occasionally anticoagulation, and, infrequently, surgery. In our case, we decided to treat conservatively with antibiotics and anticoagulation. In a review performed by Rebelo et al. regarding pediatric patients with LS, 11 patients were started on anticoagulation with low molecular weight heparin (LMWH) within a median of 2 days from diagnosis. Ten patients (90.9%) had thrombus improvement or resolution within a median of 3.4 months. There were no adverse effects from anticoagulation therapy. The review of the literature revealed the use of anticoagulation in 63.7% of pediatric LS cases.⁵ Even though we have seen a high rate of anticoagulation therapy among LS patients, in our review the routine use of anticoagulation in LS cases cannot be recommended because of limited data. Furthermore, the use of anticoagulation may not affect thrombus resolution.⁶ Other authors recommend using anticoagulation therapy in specific cases such as the potential for retrograde progression to the cavernous sinus or extensive thrombosis.²⁸ In our review, when there was EJV involvement, there was no consensus regarding the need for treatment with anticoagulation therapy.

Ligation or resection of the IJV was proposed in uncontrolled sepsis or ongoing emboli.²⁸ Although accessibility to the EJV is easier than the IJV, ligation or resection are rarely recommended today.

Outcome

Following discharge, the patient's follow-up was uneventful. In the review of the literature performed, all 26 patients with involvement of the EJV had a favorable outcome, except for 3 subjects. The 1st patient was a 17-year-old with a peritonsillar abscess, which deteriorated into LS with a residual VII nerve palsy.⁵ The authors state that the patient was non-compliant with anticoagulation therapy.⁵ The 2nd patient, with partial response, which was defined as an improvement of the thrombi with a decrease in size or partial recanalization, was not given anticoagulation treatment.⁶ The 3rd patient developed trochlear nerve palsy and was treated with antibiotics and anticoagulation.²⁷

Final Comments

Lemierre syndrome is a life-threatening complication of a common clinical condition seen by the general physician. Lemierre syndrome involving the EJV is extremely rare, which may be attributed to an anatomical variant in our patient. Diagnosing LS still requires thorough history taking and clinical examination as well as awareness of the connection between current acute medical illness and a recent pharyngeal infection. This case has a significant educational value, which teaches us not to underestimate even a "simple" tonsillitis.

Conflict of Interests

The authors have no conflict of interests to declare.

References

- Lemierre A. On certain septicemias due to anaerobic organisms. *Lancet* 1936;1:701–703
- Gupta V, Tuli A, Choudhry R, Agarwal S, Mangal A. Facial vein draining into external jugular vein in humans: its variations, phylogenetic retention and clinical relevance. *Surg Radiol Anat* 2003;25(01):36–41
- Dool H, Soetekouw R, van Zanten M, Grooters E. Lemierre's syndrome: three cases and a review. *Eur Arch Otorhinolaryngol* 2005;262(08):651–654
- Ridgway JM, Parikh DA, Wright R, et al. Lemierre syndrome: a pediatric case series and review of literature. *Am J Otolaryngol* 2010;31(01):38–45
- Rebelo J, Nayan S, Choong K, Fulford M, Chan A, Sommer DD. To anticoagulate? Controversy in the management of thrombotic complications of head & neck infections. *Int J Pediatr Otorhinolaryngol* 2016;88:129–135
- Cupit-Link MC, Nageswara Rao A, Warad DM, Rodriguez V. Lemierre Syndrome: A Retrospective Study of the Role of Anticoagulation and Thrombosis Outcomes. *Acta Haematol* 2017;137(02):59–65
- Lu MD, Vasavada Z, Tanner C. Lemierre syndrome following oropharyngeal infection: a case series. *J Am Board Fam Med* 2009;22(01):79–83
- Screaton NJ, Ravenel JG, Lehner PJ, Heitzman ER, Flower CD. Lemierre syndrome: forgotten but not extinct—report of four cases. *Radiology* 1999;213(02):369–374

- 9 Puymirat E, Biais M, Camou F, Lefèvre J, Guisset O, Gabinski C. A Lemierre syndrome variant caused by *Staphylococcus aureus*. *Am J Emerg Med* 2008;26(03):380.e5–380.e7
- 10 Judd O, Medcalf M, Malik T. Case 2: An unusual presentation of an unusual condition (Case Presentation). *Acta Paediatr* 2008;97(06):694
- 11 Çıvıgın E, Toprak U, Parlak S, Özer H. Fissuration of vertebral artery mycotic aneurysm due to Lemierre syndrome. *Diagn Interv Imaging* 2018;99(01):43–45
- 12 David R, Hansberry, Michael D'Angelo, Arpan V.Prabhu, et al. Lemierre's syndrome: Acute oropharyngeal infection leading to septic thrombophlebitis of the internal jugular vein with pulmonary septic emboli. *Interdiscip Neurosurg* 2020;19:100573
- 13 Kidambi TD, Lee C, Kohlwes RJ. MRSA-Associated Lemierre's Syndrome in an Intravenous Drug User. *J Gen Intern Med* 2015;30(12):1886–1887
- 14 Williams MD, Kerber CA, Tergin HF. Unusual presentation of Lemierre's syndrome due to *Fusobacterium nucleatum*. *J Clin Microbiol* 2003;41(07):3445–3448
- 15 Young BJ, Steele RW. A teenager with sore throat and neck pain. *Clin Pediatr (Phila)* 2011;50(04):355–356
- 16 Karkos PD, Asrani S, Karkos CD, et al. Lemierre's syndrome: A systematic review. *Laryngoscope* 2009;119(08):1552–1559
- 17 Schwartz HC, Nguyen DC. Postanginal septicaemia with external jugular venous thrombosis: case report. *Br J Oral Maxillofac Surg* 1999;37(02):144–146
- 18 Takiguchi J, Sakamoto H, Inoue N. Lemierre's Syndrome Variant with External Jugular Vein Thrombosis. *Intern Med* 2017;56(10):1271–1272
- 19 Hagiya H, Haruki Y, Otsuka F. Lemierre syndrome involving external jugular vein. *Acute Med Surg* 2014;2(01):64–68
- 20 Shibasaki Warabi Y, Yoshikawa H, Idezuka J, Yamazaki M, Onishi Y. Cerebral infarctions and brain abscess due to Lemierre syndrome. *Intern Med* 2005;44(06):653–656
- 21 Gunatilake SS, Yapa LG, Gallala M, Gamlath R, Rodrigo C, Wimalaratna H. Lemierre's syndrome secondary to community-acquired methicillin-resistant *Staphylococcus aureus* infection presenting with cardiac tamponade, a rare disease with a life-threatening presentation: a case report. *Int J Emerg Med* 2014;7:39
- 22 Hagelskjaer Kristensen L, Prag J. Lemierre's syndrome and other disseminated *Fusobacterium necrophorum* infections in Denmark: a prospective epidemiological and clinical survey. *Eur J Clin Microbiol Infect Dis* 2008;27(09):779–789
- 23 Abe H, Kisara A, Yagishita Y. A case of Lemierre syndrome. *Intensive Care Unit* 1998;22:281–285
- 24 Chirinos JA, Lichtstein DM, Garcia J, Tamariz LJ. The evolution of Lemierre syndrome: report of 2 cases and review of the literature. *Medicine (Baltimore)* 2002;81(06):458–465
- 25 Herek PA, Lewis T, Bailitz JM. An unusual case of Lemierre's syndrome due to methicillin-resistant *Staphylococcus aureus*. *J Emerg Med* 2010;39(05):644–646
- 26 Righini CA, Karkas A, Tourniaire R, et al. Lemierre syndrome: study of 11 cases and literature review. *Head Neck* 2014;36(07):1044–1051
- 27 Lee S, Rutar T, Velez FG, Rosenbaum AL. Lemierre's syndrome with fourth nerve palsy. *J AAPOS* 2009;13(01):107–108
- 28 Kuppalli K, Livorsi D, Talati NJ, Osborn M. Lemierre's syndrome due to *Fusobacterium necrophorum*. *Lancet Infect Dis* 2012;12(10):808–815
- 29 Johannesen KM, Bodtger U. Lemierre's syndrome: current perspectives on diagnosis and management. *Infect Drug Resist* 2016;9:221–227