



# Screw Fixation of Posterior Cruciate Ligament Tibial Avulsion Fractures: A Clinical and Radiographic Study

## *Fracturas avulsivas tibiales del ligamento cruzado posterior fijadas con tornillos: Un estudio clínico y radiológico*

Andrés Schmidt-Hebbel<sup>1</sup> José Tomás Reyes<sup>2,3</sup> Luis O'Connell<sup>3</sup> Juan José Valderrama<sup>3</sup>   
María Jesús Tuca<sup>3</sup> Xavier Carredano<sup>3</sup> Gonzalo Espinoza<sup>1,3</sup>

<sup>1</sup>Traumatology and Orthopedics Department, Clínica Alemana de Santiago, Universidad del Desarrollo, Santiago, Chile

<sup>2</sup>Traumatology and Orthopedics Department, Hospital San José, Santiago, Chile

<sup>3</sup>Traumatology and Orthopedics Department, Hospital Clínico Mutual de Seguridad CCHC, Santiago, Chile

Address for correspondence José Tomás Reyes Pérez, MD, Departamento de Traumatología y Ortopedia, Hospital Clínico Mutual de Seguridad CCHC, Alameda Bernardo O'Higgins 4.848, Estación Central, Región Metropolitana, Santiago, Chile (e-mail: josetomasreyes@gmail.com).

Rev Chil Ortop Traumatol 2021;62:11–18.

### Abstract

**Objective** To report mid-term clinical, radiographic, and functional outcomes following open reduction and fixation of posterior cruciate ligament tibial avulsion fractures (PCLTAFs) with cannulated screws.

**Methods** This is a retrospective analysis of patients with PCLTAF operated on from August 2010 to April 2017. Patients with acute fractures, with more than 2 mm of displacement and grade III on the posterior drawer test, combined or not to knee injuries, were included. Patients older than 65 years of age, with bilateral avulsion fractures, intrasubstance posterior cruciate ligament (PCL) lesions, stable grade-I to -II on the posterior drawer test, concomitant neurovascular injuries, mid-substance tears, open fractures, and less than 12 months of follow-up were excluded. Primary outcomes: the clinical stability was assessed using the posterior drawer test and a single comparative knee stress radiograph. Secondary outcomes: radiographic consolidation, complications, Lysholm score, and Tegner activity score.

**Results** In total, 20 patients with a mean age of 41 years (range: 32 to 61 years) were included. The mean follow-up was of 33.9 months (range: 12 to 82 months). Clinical stability (grade 0 or I on the posterior drawer test) was observed in 93% of the patients. The mean difference in contralateral posterior displacement was of 2.6 mm (range: 0.1 mm to 6.8 mm) on a single comparative knee stress radiograph. All fractures presented radiological consolidation. Seven patients developed complications. The mean Lysholm score at the last follow-up visit was of 85.17. The postoperative Tegner activity scores did not vary significantly compared to the preinjury scores.

### Keywords

- ▶ posterior cruciate ligament
- ▶ tibial avulsion fracture
- ▶ cannulated screws

received  
January 28, 2020  
accepted  
October 10, 2020

DOI <https://doi.org/10.1055/s-0040-1721370>.  
ISSN 0716-4548.

© 2021. Sociedad Chilena de Ortopedia y Traumatología. All rights reserved.

This is an open access article published by Thieme under the terms of the Creative Commons Attribution-NonDerivative-NonCommercial-License, permitting copying and reproduction so long as the original work is given appropriate credit. Contents may not be used for commercial purposes, or adapted, remixed, transformed or built upon. (<https://creativecommons.org/licenses/by-nc-nd/4.0/>)

Thieme Revinter Publicações Ltda., Rua do Matoso 170, Rio de Janeiro, RJ, CEP 20270-135, Brazil

**Conclusions** Cannulated screw fixation of a displaced PCLTAF through a posterior approach restores clinical and radiographic stability and has excellent union rates. The mid-term functional outcomes are good despite the high rates of combined knee lesions and postoperative complications.

Level of evidence IV.

## Resumen

**Objetivo** Realizar la evaluación clínica, imagenológica y funcional de pacientes con fracturas avulsivas tibiales del ligamento cruzado posterior (FTALCPs) fijadas con tornillos canulados con técnica abierta.

**Métodos** Los pacientes con FTALCP operados entre 2010 y 2017 fueron revisados retrospectivamente. Criterios de inclusión: fracturas agudas, desplazadas, test de cajón posterior grado III, lesiones combinadas de rodilla, seguimiento > 12 meses. Se excluyeron pacientes > 65 años, con FTALCPs bilaterales, lesiones del ligamento cruzado posterior (LCP) intrasustancia, test de cajón posterior grados I-II, fracturas expuestas, lesiones neurovasculares, y seguimientos < 12 meses. Objetivo primario: medir la estabilidad clínica mediante test de cajón posterior y radiografía de estrés arrodillada comparativa. Objetivos secundarios: evaluar la consolidación en radiografías, complicaciones y funcionalidad con las escalas de Lysholm y Tegner.

**Resultados** Se incluyeron 20 pacientes, con edad media de 41 años (rango: 32 a 61 años). El seguimiento promedio fue de 33,9 meses (rango: 12 a 82 meses). La estabilidad clínica mejoró en 93% (cajón posterior postoperatorio grados 0 y I) de los pacientes. La radiografía de estrés arrodillada mostró una diferencia promedio de 2,6 mm (rango: 0,1 mm a 6,8 mm) de traslación posterior al comparar con el lado sano. Todas las fracturas consolidaron. Siete pacientes presentaron complicaciones. El puntaje promedio de la escala de Lysholm al final del seguimiento fue de 85,17. El promedio preoperatorio del puntaje en la escala de Tegner no varió significativamente en comparación con el postoperatorio.

**Conclusiones** La fijación de fracturas avulsivas tibiales del LCP con tornillos canulados con técnica abierta es efectiva en restaurar la estabilidad posterior y lograr la consolidación ósea. La funcionalidad clínica a mediano plazo es buena, a pesar del alto número de complicaciones y lesiones concomitantes.

Nivel de evidencia tipo IV.

## Palabras clave

- ▶ ligamento cruzado posterior
- ▶ fracturas avulsivas tibiales
- ▶ tornillos canulados

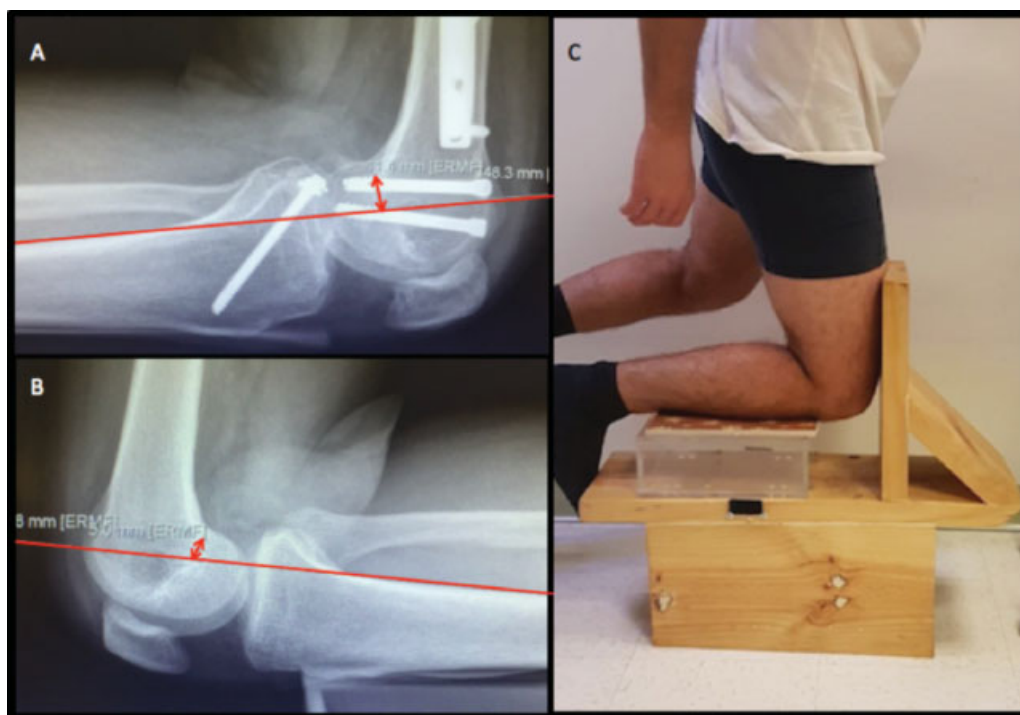
## Introduction

The posterior cruciate ligament (PCL) is twice as strong as the anterior cruciate ligament. It is the main restrictor to the posterior translation of the flexed knee.<sup>1,2</sup> Posterior cruciate ligament tibial avulsion fractures (PCLTAFs) are rare injuries, usually caused by high-energy mechanisms and accompanied by other injuries.<sup>3</sup> The conservative treatment for displaced PCLTAFs does not result in anatomical consolidation. The consequent chronic knee instability can lead to chronic pain, knee stiffness, and progressive patellofemoral chondral damage.<sup>4-7</sup> As such, there is a consensus in the literature that the treatment of choice for displaced PCLTAF is surgical therapy.<sup>8,9</sup> Open reduction and internal fixation is the most frequently used and reported treatment. However, series<sup>8,10,11</sup> with an arthroscopic technique have also been described, resulting in comparable outcomes.

The posterior drawer test enables a subjective assessment of the degree of posterior knee instability on the physical

examination. Its reported<sup>12,13</sup> that sensitivity ranges from 22% to 98%, with 98% of specificity and a high interobserver variability. Several radiological techniques have been described to determine posterior stability, quantifying the posterior translation of the tibia in relation to the femur. Among them, Telos-type (Telos Medical, Millersville, MD, US) radiography and the comparative knee stress radiography are deemed the most reliable;<sup>14-16</sup> in addition, the latter is the most accessible and cost-effective method<sup>14</sup> (► **Figure 1**).

The present study aims to perform a clinical, imaging, and functional evaluation of patients with PCLTAF stabilized with open reduction and fixation of cannulated screws. The primary objective is to determine the anteroposterior stability by measuring the posterior translation of the tibia through knee stress radiographs of the operated limb compared to the healthy contralateral limb, in addition to a subjective measurement with the posterior drawer test. The secondary objectives are to record the percentage of radiographic



**Fig. 1** (A and B) Measurement of tibial posterior translation. The most posterior point in the Blumensaat line is indicated. A line tangent to the posterior cortex of the tibia is drawn. A line perpendicular to the one connecting those two references is the distance, which is then compared with the healthy contralateral side.<sup>8</sup> (C) Position of the knee for comparative radiographs.

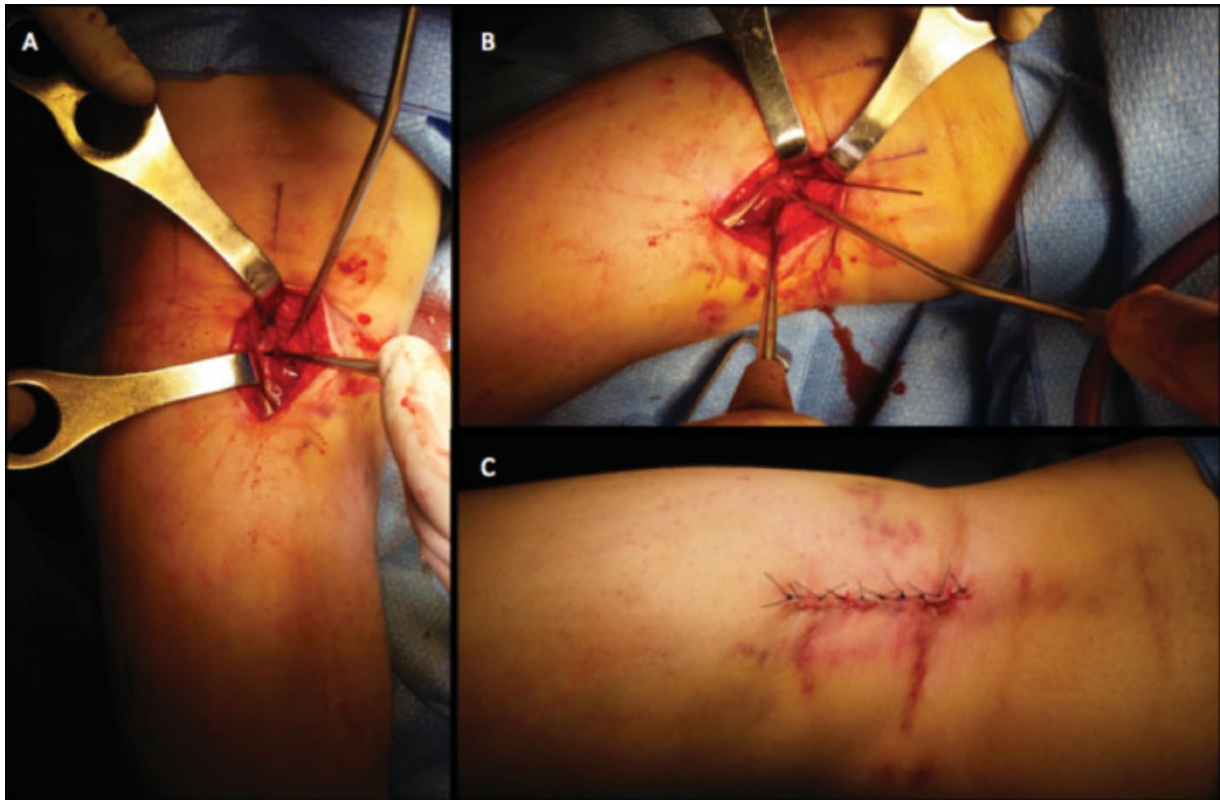
consolidation, to assess functionality using the Lysholm and Tegner scores, and to report the postoperative complications.

## Materials and Methods

The present is a descriptive, retrospective study of 26 patients with PCLTAF operated on from August 2010 to September 2017 by the same surgeon (EG) and surgical team at a level-1 trauma center. The following inclusion criteria were applied: avulsed fragment displacement greater than 2 mm on radiographs, computed tomography (CT), or magnetic resonance imaging (MRI) scans with no intrasubstance injury, surgery within 4 weeks after the trauma, with grade-III of clinical instability on the posterior drawer test ( $> 10$  mm in posterior translation), combined knee injuries (meniscal or ligament injuries, periarticular fractures) and a minimum follow-up of 12 months. Patients with bilateral injuries, nondisplaced avulsion fractures, with more than 4 weeks of evolution, grades I ( $< 5$  mm) and II (5 to 10 mm) of clinical instability on the posterior drawer test, open fractures, vascular injuries, older than 65 years of age, with a follow-up period shorter than 12 months, and those lost to follow-up were excluded from the study.

All patients were operated on in prone position, and three different approaches were used in the study. The traditional posterior approach described by Trickey,<sup>17</sup> with a sinusoidal (“S”-shaped) incision in line with the popliteal fossa fold, was used in the first six patients. Due to technical evolutions and the surgeon’s preference, two patients were operated on with a posterior “L” approach modified from Burks and Schaffer,<sup>18</sup> in which the posterior joint capsule is approached

in an intermuscular plane between the semimembranosus muscle and the medial gastrocnemius muscle, laterally reflecting the neurovascular structures. The last 12 patients were operated on using the minimally-invasive approach described by Frosch et al.<sup>19</sup> In contrast to the approach by Burks and Schaffer,<sup>18</sup> the skin is incised longitudinally 3 cm to 4 cm from the muscular belly of the medial gastrocnemius, and vertically at the level of the joint line (→Figure 2). Intraoperative ischemia was used in 11 out of 20 patients according to surgeon’s preference (→Table 1). All PCLTAFs were fixed with one 4.5-mm cannulated screw with washer. Postoperatively, all patients received low-molecular-weight heparin and wore anti-embolism stockings for 14 days. The rehabilitation protocol consisted of immobilization in extension for 3 weeks, followed by progressive flexion in increments of 30° per week until the 6th week. From the sixth week onwards, full ranges of motion and loading were allowed as tolerated. At the most recent evaluation, clinical stability was recorded using the posterior drawer test, which was performed by a traumatologist from our knee team with five years of experience in this subspecialty (AS-H), in addition to a more objective stability assessment using comparative knee stress radiography. As secondary endpoints, radiographic consolidation of the avulsed fragment (assessed by anteroposterior and lateral knee radiographs, and reported by a musculoskeletal radiologist from our hospital), range of motion of the knee, complications, and functionality were evaluated using the Lysholm and Tegner scores. The Shapiro-Wilk test analyzed the normality of the distribution of the variables studied. Hypothesis tests were performed accordingly (the Student



**Fig. 2** Minimally-invasive approach described by Frosch et al.<sup>19</sup> (A) Reduction of posterior cruciate ligament tibial avulsion fracture. (B) Fixation with cannulated screw. (C) Postoperative wound.

*t*-test for the parametric variables, and the Wilcoxon-Mann-Whitney test for the non-parametric variables). For the descriptive statistical analysis, the Stata (StataCorp, LLC, College Station, TX, US) software, version 12.0, as well as the Wilcoxon-Mann-Whitney test and the Student *t*-test were used. The present research was approved by the institutional ethics committee.

## Results

In total, 26 patients underwent surgery, and 20 (19 men and 1 woman) were included in the final sample (► **Figure 3**). The mean age of these patients was 41 years (range: 32 to 61 years). The trauma mechanism involved high energy in 94% of the cases, and 53% of the subjects had at least 1 associated injury in the same knee (► **Table 1**). The mean follow-up was of 33.6 months (range: 12 to 82 months). The subjective evaluation with the drawer test after the physical examination showed greater clinical stability in 93% of the patients (grades 0 and I on the posterior drawer test). The comparative knee stress radiographs revealed an average difference of 2.6 mm (range: 0.1 mm to 6.8 mm). All fractures presented radiographic consolidation. The mean range of motion of the knee at the end of the follow-up period was of 1° to 118°. Of the 20 patients, 7 had complications: 4 patients suffered deep vein thrombosis (DVT), and 3 presented knee stiffness that required mobilization under anesthesia (► **Table 2**). The mean preoperative (postinjury) Lysholm score was of 29.06 (standard deviation [SD]: 11.4), which increased to 85.17 (SD: 7.6) at

the end of the follow-up period, with a statistically significant difference ( $p < 0.0001$ ) on the Wilcoxon-Mann-Whitney test. The average preinjury Tegner score was of 4.2 (SD: 1), which decreased to 4 (SD: 0.7) at the end of the follow-up period, with no statistically significant difference on the Student *t*-test (► **Table 3**).

## Discussion

In patients with displaced PCLTAF, open reduction and internal fixation with cannulated screws can restore clinical and radiological stability in the medium term. In the present clinical series, three types of approach were used. The wide posterior approach described by Trickey<sup>17</sup> was used in the first six patients, and it requires an extensive dissection, in which the proximal belly of the medial gastrocnemius muscle is completely released for excellent exposure and direct visualization of neurovascular structures. Some authors<sup>20</sup> still use it. However, the longer surgical time, muscle weakness, and flexion contractures due to excessive scarring are some major disadvantages, and we decided to use less extensive approaches instead. Burks and Schaffer<sup>18</sup> described a medial “L”-shaped approach, which was used in two patients in our series. This approach is difficult in obese and muscular patients; in addition, since the exposure of the lateral base of the PCL is limited, insertion of the screw perpendicular to the fracture line is not always feasible, because it may compromise the stability of the fixation. Most authors<sup>10,21-23</sup> prefer this incision over the former because it is less invasive

**Table 1** Demographic data

N	Gender	Age	Knee-associated injuries	Side	Injury mechanism	Time from injury to surgery (days)	Incision	Ischemia
1	M	43	ACL, MCL, PLC	Left	Crushing	13	Traditional, posterior	yes
2	M	51	MCL	Left	BF	7	Traditional, posterior	yes
3	M	58	TP Fx, IM	Left	MF	17	Traditional, posterior	yes
4	M	45	EM root	Right	MF	3	Traditional, posterior	no
5	M	37	Hoffa, patella, TP Fx	Left	MF	11	Traditional, posterior	no
6	M	32	PMC	Left	BF	9	Traditional, posterior	no
7	M	58	MCL, EM	Right	Fall from height	9	Posterior in "L"	no
8	M	37	no	Right	MF	18	Posterior in "L"	no
9	M	34	no	Left	MF	8	MIS	no
10	M	35	no	Left	MF	5	MIS	yes
11	M	33	no	Right	Fall from height	18	MIS	no
12	M	42	no	Left	MF	1	MIS	no
13	F	32	Patella, TP, distal femur Fx	Right	Car accident	11	MIS	no
14	M	34	no	Right	MF	5	MIS	yes
15	M	44	no	Right	Car accident	21	MIS	yes
16	M	52	no	Left	MF	12	MIS	yes
17	M	61	no	Left	MF	5	MIS	yes
18	M	46	no	Right	MF	20	MIS	yes
19	M	32	no	Right	MF	7	MIS	yes
20	M	55	no	Left	BF	13	MIS	yes

Abbreviations: ACL, anterior cruciate ligament; BF, bicycle fall; EM, external meniscus; Fx, fracture; IM, internal meniscus; M, male; MCL, medial collateral ligament; MF, motorcycle fall; MIS, minimally-invasive approach; PLC, posterolateral corner; PMC, posteromedial corner; TP, tibial plateau.

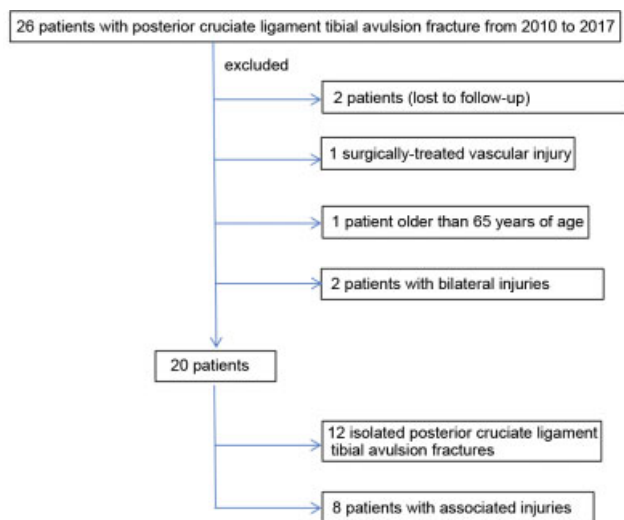
and it does not expose the neurovascular structures. We used the minimally-invasive approach described by Frosch et al.<sup>19</sup> for the last 12 patients in our series. This approach is described as simpler and faster, with better cosmetic outcomes and fewer soft-tissue complications. When evaluating the functional outcomes and complications from our series and comparing them according to the type of approach, there is a slight trend for better results among the group submitted to the traditional posterior approach, but with no statistical significance (**► Table 2**). Further studies with larger samples are required to determine the safest approach with the lowest rate of complications. In an attempt to gather a larger sample of patients, our team is currently using the minimally-invasive approach described by Frosch.<sup>19</sup> However, the traditional posterior approach must be considered in obese and muscular patients, as well as in those previously operated, because less invasive procedures are technically more difficult in these cases.

There is a wide range of fixation methods for PCLTAF, from sutures and the placement of buttons in arthroscopic techniques to antegrade and retrograde screw fixation in open procedures. There is no consensus in the literature demonstrating a clear superiority of one osteosynthesis method over another.<sup>8,24</sup> A biomechanical study assessed stiffness, elongation, and maximum load resistance in different fixation methods. It revealed the biomechanical superiority of antegrade screws with washer over the sutures, and the equivalent

efficiency of retrograde screws and high-resistance sutures with cortical fixation buttons.<sup>25</sup> All fractures in our series were treated with cannulated, full-thread screws with washers, achieving excellent fixation to the proximal metaphyseal bone of the tibia. We consider that this osteosynthesis method is sufficient because all patients presented radiographic consolidation during the first 6 months of follow-up, with no need for revision due to nonunion (**► Table 2**).

When evaluating subjective stability using the posterior drawer test, our findings were consistent with those described in the literature with a longer follow-up time. In our study, 12 patients presented grade 0, 7 patients were classified as grade I, and 1 patient presented grade II on the drawer test (**► Table 2**). Sabat et al.<sup>10</sup> reported 20 patients with grade I, and 7 patients with grade II on the posterior drawer test after 1 year of follow-up. The Lamichhane and Mahara<sup>23</sup> series describes 10 cases with a negative posterior drawer test, 1 case with grade I instability and 1 case with grade II. In the study by Abdallah and Arafa,<sup>22</sup> 81.5% of the patients had a negative posterior drawer test, 14.8% were grade I, and 3.7%, grade II after 1 year of follow-up.

The main strength of the present study is the objective evaluation of the postoperative stability using comparative knee stress radiographs, an easily reproducible and accessible technique which is also more cost-effective than the Telos method.<sup>14,15</sup> Schulz et al.<sup>26</sup> evaluated the stability in more than one thousand patients with PCL lesions with



**Fig. 3** Flowchart of the patient selection.

Telos stress radiography. An absolute posterior translation higher than 8 mm indicates a complete PCL tear, and values higher than 12 mm suggest an additional injury to the posteromedial or posterolateral corners of the knee. In the present study, the mean difference in posterior translation compared to that of the healthy side was of 2.6 mm (range:

0.1 mm to 6.8 mm). In total, 11 patients had normal stability (less than 2 mm of compared posterior translation), 4 presented grade-I instability (2 mm to 5 mm), and 5, grade-II instability (5 mm to 10 mm), but none presented a comparative difference in posterior translation higher than 6.8 mm (► **Tables 2** and **3**). To our knowledge, two studies<sup>27,28</sup> objectively measured the posterior translation of the tibia after the surgical treatment for PCLTAF, and neither of them used knee stress radiographs. Khatri et al.<sup>27</sup> reported 20 patients with grade-I instability and 7 with grade-II using lateral radiographs with posterior stress through the active hamstring flexion test. Pardiwala et al.<sup>28</sup> conducted a randomized clinical study comparing the arthroscopic technique and the open technique for the treatment of PCLTAF with a minimum follow-up period of 2 years. These authors did not describe the stress radiography method they used; from the total sample, they found 18 patients with normal stability, 5 with grade-I posterior instability, and two with grade-II posterior instability.

Arthrofibrosis was observed in 3 out of 20 patients (15%), including 2 subjects with isolated injuries and 1 patient with combined knee lesions. This percentage is consistent with those of other series, which reported values of up to 25% with the open technique.<sup>20,21,28,29</sup> This figure was of 36% in a series<sup>8</sup> using the arthroscopic technique. In our institution,

**Table 2** Clinical and functional outcomes

N	Follow-up (months)	Range of motion	Consolidation	Positive drawer test (0, +1, +2, +3)	Comparative knee stress radiography (difference in mm)	Preop Lysholm	Postop Lysholm	Preop Tegner	Postop Tegner	Complication
1	82	0–120°	yes	1	2.5	27	94	6	5	no
2	70	0–115°	yes	0	6.8	14	73	5	4	DVT
3	58	0–130	yes	0	5	21	93	4	4	no
4	55	0–130°	yes	1	1.2	37	90	5	5	no
5	79	15–90°	yes	0	6.4	17	79	3	3	arthrofibrosis
6	50	0–130°	yes	1	5.7	26	94	5	5	no
7	45	0–115°	yes	1	0.1	22	83	5	4	DVT
8	30	0–110°	yes	0	1	32	84	5	5	arthrofibrosis
9	14	0–115°	yes	2	1	39	69	5	4	DVT
10	12	0–130°	yes	0	1.5	29	90	4	4	no
11	18	0–130°	yes	0	0.2	24	78	4	3	no
12	13	0–130°	yes	1	3	64	87	5	4	no
13	15	0–90°	yes	0	1.7	31	79	3	3	arthrofibrosis
14	17	0–120°	yes	0	2	31	84	4	4	no
15	12	0–130°	yes	0	5.1	27	89	2	2	DVT
16	34	0–130°	yes	1	0.7	27	95	5	5	no
17	22	0–115°	yes	0	0.8	24	87	3	3	no
18	13	0–115°	yes	0	1.0	40	87	5	4	no
19	17	0–110°	yes	1	5.2	32	90	5	5	no
20	23	0–110°	yes	0	4	26	94	3	3	no

Abbreviations: DVT, deep vein thrombosis; preop, preoperative; postop, postoperative.

**Table 3** Summary of functional and radiological outcomes

	Patients (n= 20)
<b>Lysholm score, mean +/- standard deviation</b>	
Preoperative	29.20 ± 11.8
Postoperative	84.27 ± 7.57 (95%CI: -62.48 to -47.65)
p-value	< 0.0001
<b>Tegner activity score</b>	
Preoperative	4.25 ± 1.06
Postoperative	3.94 ± 0.77 (95%CI: -0.36 to 0.98)
p-value	0.3494
<b>Posterior tibial translation on comparative knee stress radiography (in mm)</b>	
< 2 mm	11
2 to 5 mm	4
5 to 10 mm	5

Abbreviation: 95%CI, 95% confidence interval.

arthrofibrosis is diagnosed when there is no extension at 0° and/or flexion higher than 90° after 6 weeks, and the patient is submitted to mobilization under anesthesia. Although the mean range of motion was good in the present series (1° to 118°), 2 out of the 3 patients requiring mobilization under anesthesia did not achieve more than 90° of flexion at the end of the follow-up period (►Table 2). In the present series, 4 out of 20 patients (20%) had DVT, a high number compared to those of other studies. All patients received postoperative prophylaxis for thromboembolic disease with low-molecular-weight heparin and anti-embolism stockings for up to 14 days. No association was found between DVT and the time from injury to surgery, the number of associated injuries, the type of approach, the surgical time, the ischemia time, or smoking. As the present is a small series, we believe that the high percentage of complications may be due to chance, and an increased sample size could balance this bias.

The functional evaluation, carried out for an average follow-up period of almost three years, demonstrated satisfactory outcomes in most patients. The improvement in the Lysholm scores after surgery was statistically significant. However, this improvement is limited because it considers patients with multiple associated lesions, in whom a very low Lysholm score is expected in the acute setting, which is not necessarily explained by the PCLTAF. Even so, an average score of 85 points at the end of the follow-up is consistent with the scores of other studies.<sup>22,27</sup> Most injuries occurred in high-energy accidents, which is also consistent with the literature. In total, 8 out of the 20 patients had combined injuries in the same knee (►Table 1). These 8 patients required additional surgeries for PCLTAF fixation, but their functional outcomes were not inferior to those observed in 14 patients with isolated lesions (Lysholm scores of 85.4 and

86.1 respectively). Another important aspect to consider is that all the patients in the present study could take paid leaves from work, potentially influencing their outcomes and recovery times.<sup>30</sup> We did not find statistically significant differences between Tegner scores prior to injury and after treatment, revealing that patients usually returned to their baseline status and resumed their usual activities (►Table 3). This finding is particularly relevant when considering that this is a young, active population, in which all patients were involved in construction work and could take paid leaves. The return to work observed here supports the indication of fixation in this population.

Like most papers on PCLTAF,<sup>8</sup> the main limitations of the present study are its retrospective, non-comparative design, and small sample size. Furthermore, since this is a rare diagnosis usually associated with concomitant injuries, it is very difficult to analyze PCLTAFs as isolated lesions. When evaluating functional outcomes and complications, multiple variables that cannot be isolated in a clinical series must be considered. Even so, in patients with severe associated injuries, the functional outcomes at the end of the follow-up period were not inferior to those observed in patients with isolated injuries (►Tables 1 and 2). Prospective studies with larger sample sizes are required to compare open and arthroscopic techniques with long-term follow-up periods to evaluate functional outcomes, radiographic stability, and complications to determine the ideal treatment for these lesions.

## Conclusions

The fixation of PCLTAFs with full-thread screws and washers is effective in restoring the posterior stability of the knee, as revealed by comparative stress radiographs and clinical posterior drawer tests. Clinical functionality is good despite the high number of complications and concomitant injuries.

### Conflict of Interests

The authors have no conflict of interests to declare.

## References

- Kannus P, Bergfeld J, Järvinen M, et al. Injuries to the posterior cruciate ligament of the knee. *Sports Med* 1991;12(02):110–131
- Chandrasekaran S, Ma D, Scarvell JM, Woods KR, Smith PN. A review of the anatomical, biomechanical and kinematic findings of posterior cruciate ligament injury with respect to non-operative management. *Knee* 2012;19(06):738–745
- Bali K, Prabhakar S, Saini U, Dhillion MS. Open reduction and internal fixation of isolated PCL fossa avulsion fractures. *Knee Surg Sports Traumatol Arthrosc* 2012;20(02):315–321
- Montgomery SR, Johnson JS, McAllister DR, Petrigliano FA. Surgical management of PCL injuries: indications, techniques, and outcomes. *Curr Rev Musculoskelet Med* 2013;6(02):115–123
- Stäubli HU, Jakob RP. Posterior instability of the knee near extension. A clinical and stress radiographic analysis of acute injuries of the posterior cruciate ligament. *J Bone Joint Surg Br* 1990;72(02):225–230
- Barros MA, Cervone Gde F, Costa ALS. Surgical treatment of avulsion fractures at the tibial insertion of the posterior cruciate ligament: functional result. *Rev Bras Ortop* 2015;50(06):631–637 (English Edition)

- 7 Strobel MJ, Weiler A, Schulz MS, Russe K, Eichhorn HJ. Arthroscopic evaluation of articular cartilage lesions in posterior-cruciate-ligament-deficient knees. *Arthroscopy* 2003;19(03):262–268
- 8 Hooper PO III, Silko C, Malcolm TL, Farrow LD. Management of posterior cruciate ligament tibial avulsion injuries: a systematic review. *Am J Sports Med* 2018;46(03):734–742
- 9 White EA, Patel DB, Matcuk GR, et al. Cruciate ligament avulsion fractures: anatomy, biomechanics, injury patterns, and approach to management. *Emerg Radiol* 2013;20(05):429–440
- 10 Sabat D, Jain A, Kumar V. Displaced posterior cruciate ligament avulsion fractures: A retrospective comparative study between open posterior approach and arthroscopic single-tunnel suture fixation. *Arthroscopy* 2016;32(01):44–53
- 11 Shino K, Nakata K, Mae T, Yamada Y, Shiozaki Y, Toritsuka Y. Arthroscopic fixation of tibial bony avulsion of the posterior cruciate ligament. *Arthroscopy* 2003;19(02):E12
- 12 LaPrade CM, Civitaresse DM, Rasmussen MT, LaPrade RF. Emerging updates on the posterior cruciate ligament. *Am J Sports Med* 2015;43(12):3077–3092
- 13 Kopkow C, Freiberg A, Kirschner S, Seidler A, Schmitt J. Physical examination tests for the diagnosis of posterior cruciate ligament rupture: a systematic review. *J Orthop Sports Phys Ther* 2013;43(11):804–813
- 14 Jung TM, Reinhardt C, Scheffler SU, Weiler A. Stress radiography to measure posterior cruciate ligament insufficiency: a comparison of five different techniques. *Knee Surg Sports Traumatol Arthrosc* 2006;14(11):1116–1121
- 15 Jackman T, LaPrade RF, Pontinen T, Lender PA. Intraobserver and interobserver reliability of the kneeling technique of stress radiography for the evaluation of posterior knee laxity. *Am J Sports Med* 2008;36(08):1571–1576
- 16 Schulz MS, Russe K, Lampakis G, Strobel MJ. Reliability of stress radiography for evaluation of posterior knee laxity. *Am J Sports Med* 2005;33(04):502–506
- 17 Trickey EL. Injuries to the posterior cruciate ligament: diagnosis and treatment of early injuries and reconstruction of late instability. *Clin Orthop Relat Res* 1980;(147):76–81
- 18 Burks RT, Schaffer JJ. A simplified approach to the tibial attachment of the posterior cruciate ligament. *Clin Orthop Relat Res* 1990;(254):216–219
- 19 Frosch K, Proksch N, Preiss A, Giannakos A. [Treatment of bony avulsions of the posterior cruciate ligament (PCL) by a minimally invasive dorsal approach]. *Oper Orthop Traumatol* 2012;24(4-5):348–353
- 20 Nicandri GT, Klineberg EO, Wahl CJ, Mills WJ. Treatment of posterior cruciate ligament tibial avulsion fractures through a modified open posterior approach: operative technique and 12- to 48-month outcomes. *J Orthop Trauma* 2008;22(05):317–324
- 21 Joshi S, Bhatia C, Gondane A, Rai A, Singh S, Gupta S. Open Reduction and Internal Fixation of Isolated Posterior Cruciate Ligament Avulsion Fractures: Clinical and Functional Outcome. *Knee Surg Relat Res* 2017;29(03):210–216
- 22 Abdallah AA, Arafa MS. Treatment of posterior cruciate ligament tibial avulsion by a minimally-invasive open posterior approach. *Injury* 2017;48(07):1644–1649
- 23 Lamichhane A, Mahara DP. Management of posterior cruciate ligament avulsion by cannulated screw fixation. *J Inst Med* 2012;34(03):28–31
- 24 Frings J, Akoto R, Müller G, Frosch KH. Bony avulsions of the posterior cruciate ligament: Arthroscopic or minimally invasive? *Arthroscopie* 2018;31(01):52–58
- 25 Domnick C, Kösters C, Franke F, et al. Biomechanical Properties of Different Fixation Techniques for Posterior Cruciate Ligament Avulsion Fractures. *Arthroscopy* 2016;32(06):1065–1071
- 26 Schulz MS, Steenlage ES, Russe K, Strobel MJ. Distribution of posterior tibial displacement in knees with posterior cruciate ligament tears. *J Bone Joint Surg Am* 2007;89(02):332–338
- 27 Khatri K, Sharma V, Lakhota D, Bhalla R, Farooque K. Posterior cruciate ligament tibial avulsion treated with open reduction and internal fixation through the Burks and Schaffer approach. *Malays Orthop J* 2015;9(02):2–8
- 28 Pardiwala DN, Agrawal D, Patil V, Saini U, Dhawal P. Paper 133: Comparison of Open Versus Arthroscopic Fixation for Isolated PCL Tibial Bony Avulsions: A Prospective Randomized Study with Minimum 2 Year Follow-up. *Arthroscopy* 2012;28(09):
- 29 Chen CH, Chen WJ, Shih CH. Fixation of small tibial avulsion fracture of the posterior cruciate ligament using the double bundles pull-through suture method. *J Trauma* 1999;46(06):1036–1038
- 30 Fan JK, McLeod CB, Koehoorn M. Sociodemographic, clinical, and work characteristics associated with return-to-work outcomes following surgery for work-related knee injury. *Scand J Work Environ Health* 2010;36(04):332–338