




Challenges of Diagnosing Hyponatremic Syndromes in Pulmonary and Extra Pulmonary Tuberculosis

Atana U. Ewa¹  Ernest A. Ochang² Keneth O. Inaku³ Emmanuel B. Adams⁴ Kingsley C. Anachuna⁴
Echeng J. Imoke⁴ Antigha I. Cobham⁴ Ekaete S. Brown⁴

¹ Department of Paediatrics, University of Calabar/Teaching Hospital, Calabar, Nigeria

² Department of Medical Microbiology and Parasitology, University of Calabar/Teaching Hospital, Calabar, Nigeria

³ Department of Chemical Pathology, University of Calabar/Teaching Hospital, Calabar, Nigeria

⁴ Department of Paediatrics, University of Calabar/Teaching Hospital, Calabar, Nigeria

Address for correspondence Atana U. Ewa, MBCh, FWACP, Department of Paediatrics, University of Calabar/Teaching Hospital, Unical Hotel, Road, P.M.B. 1278, Calabar, Nigeria (e-mail: atanaewa@yahoo.com).

J Child Sci 2021;11:e14–e17.

Abstract

Introduction Pulmonary tuberculosis (PTB) is one of the rare pulmonary infections causing hyponatremia (serum sodium <135 mmol/L) and severe hyponatremia (serum sodium <125 mmol/L). Although the major cause of hyponatremia in TB patients is syndrome of inappropriate antidiuretic hormone (SIADH) secretion, cerebral salt wasting syndrome (CSWS) can occur and requires evidence of inappropriate urinary salt losses and reduced arterial blood volume. Adrenal insufficiency (AI) is rare in TB with scanty literature describing it. The two reported cases highlight three possible causes of severe symptomatic hyponatremia in TB pleural effusion and disseminated TB, their treatment modalities, and the need to increase the index of suspicion to diagnose TB hyponatremia in children.

Case Report Case 1: a 10-year-old girl with TB pleural effusion who developed recurrent hyponatremia in the first few weeks of anti-TB treatment which was responsive to sodium correction. Case 2: an 8-year-old girl presenting to our facility with presumptive TB. She deteriorated over several months and progressed to disseminated TB with AI.

Discussion Early diagnosis and prompt and correct treatment of TB hyponatremia cannot be overemphasized, as AI, SIADH secretion, and CSWS, each require different therapeutic regimens, most especially AI on its own poses a huge clinical challenge.

Conclusion A high index of suspicion, with intensified case finding at all levels of care, is necessary to identify and manage children with TB hyponatremia because early diagnosis and prompt treatment is lifesaving.

Keywords

- tuberculosis
- hyponatremia
- SIADH
- CSWS
- adrenal insufficiency

Introduction

Pulmonary tuberculosis (PTB) is one of the rare pulmonary infections causing hyponatremia.^{1,2} It is usually mild to moderate, asymptomatic, self-limiting, and reversible with anti-TB therapy.^{1,2} Hyponatremia is the reduction in serum sodium <135 mmol/L^{3,4} and severe hyponatremia occurs when levels

are <125 mmol/L.³ It is one of the commonest electrolyte disturbances^{4,5} with prevalence of 1 to 4% in severe forms^{1,3} and 15 to 30% in nonsevere forms among hospitalized adults and children.^{1,4} Hyponatremia occurs in active TB in 11 to 51%^{1,6} of cases and thus its screening is of paramount importance.⁵ TB causes hyponatremia by affecting the adrenal glands, hypothalamus, pituitary gland, meninges, or lungs through

received

September 11, 2020

accepted after revision

November 10, 2020

DOI <https://doi.org/>

10.1055/s-0040-1721786.

ISSN 2474-5871.

© 2021. The Author(s).

This is an open access article published by Thieme under the terms of the Creative Commons Attribution License, permitting unrestricted use, distribution, and reproduction so long as the original work is properly cited. (<https://creativecommons.org/licenses/by/4.0/>)

Georg Thieme Verlag KG, Rüdigerstraße 14, 70469 Stuttgart, Germany

adrenal insufficiency (AI), as well as inappropriate antidiuretic hormone (ADH) secretion. The main causes of hyponatremia are AI, syndrome of inappropriate ADH (SIADH), and cerebral salt wasting syndrome (CSWS).^{1,2} SIADH secretion should be considered in cases of hyponatremia with low serum osmolality, normal acid–base balance, urine osmolality >100 mOsm/L, and urine sodium >40 meq/L.⁶ It is poorly understood but believed to be due to hypoxia and reduced vascular volume.^{2,7} CSWS involves renal salt loss causing hyponatremia and extracellular fluid volume reduction, while SIADH is physiologically inappropriate secretion of ADH or increased renal sensitivity of ADH causing renal conservation of water and euvoletic hyponatremia.⁸ Conversely, increased serum ADH does not exclude CSWS as it may increase physiologically in response to hypovolemia.⁸ The different pathophysiological mechanisms between SIADH and CSW make early differentiation mandatory for correct treatment since both require diverse therapeutic regimens.⁹ Debates continue to trail CSWS, leaving it as an interesting academic controversy, and until more studies are done, CSWS should be considered a rare cause of hyponatremia compared with SIADH secretion.¹⁰

AI is now rare in children¹¹ with scanty literature describing it but TB remains its most common cause in the developing countries¹²; it has been proposed that more than 90% of the adrenal gland should be affected by TB before insufficiency appears.¹³ Hyponatremia in AI is due to sodium wasting with secondary antidiuresis due to aldosterone deficiency¹⁰ and is associated with hyperkalemia and increased urinary potassium.² The treatment of choice is steroid replacement.^{14,15} This report highlights the occurrence of severe symptomatic hyponatremia in TB pleural effusion, as well as disseminated TB with AI, which may be confused with TB treatment failure. Diagnosing AI is a clinical challenge that requires suspicion in a background of active TB.¹⁵ A high index of suspicion is therefore needed for both the diagnosis of childhood TB and early diagnosis with prompt treatment of hyponatremia because SIADH, CSWS, and AI, all require different therapeutic approaches.^{2,9}

Case Reports

Case 1: a 10-year-old girl with 4 months' history of cough, fever, weight loss, 1 week's vomiting, and 5 days' diarrhea. Her father had TB 3 years earlier. Vital signs on admission were temperature, 39.8°C ; respiratory rate (RR), 46 cycles/minute; pulse, 148/minute; blood pressure (BP), 110/70 mm/Hg; and SPO_2 91% in room air. Her weight was 23 kg (10th percentile), while her height was 140 cm (>50 th percentile). Salient findings were dyspnea, tachypnea, tracheal deviation to the right, reduced chest expansion with stony dullness, and Bronchial breath sounds (BBS) left hemithorax. Diagnosis was PTB with left pleural effusion. Chest X-ray showed massive left-sided pleural effusion (\rightarrow Fig. 1).

Xpert MTB/RIF of pleural fluid detected rifampicin sensitive MTB. Pleural fluid glucose, 6 mmol/L; lactate dehydrogenase (LDH), 553.2 IU/L; and protein, 317 mg/dL. Urine sodium was <50 mmol/L, serum osmolality was 287 mOsm/kg, and urine osmolality was 243 mOsm/kg. Abdominal ultrasound scan

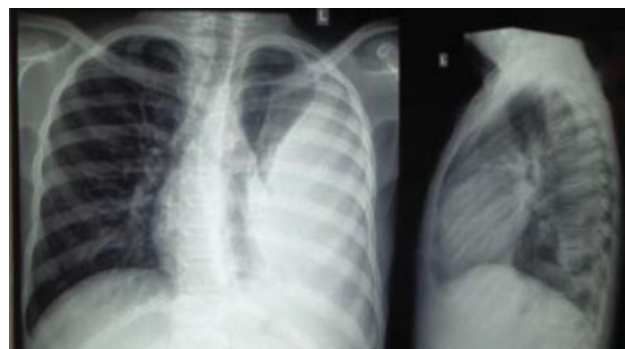

Fig. 1 Left-sided tuberculous pleural effusion of case 1.

(USS) showed grade-4 renal parenchymal disease. She responded to anti-TB drugs but developed convulsion and coma after 10 days of therapy with serum sodium of 114 mmol/L. This recurred in subsequent weeks with sodium levels ranging from 114 to 124 mmol/L but each episode responded to sodium correction with/without corticosteroids and anti-TB drugs were continued. She stabilized after 10 weeks and was eventually discharged home. Follow-up was satisfactory.

Case 2: an 8-year-old girl presented with fever, cough, neck swellings of 10 months, weight loss of 6 months, and abdominal and leg swelling of 3 months' duration. She lived with her grandmother who had TB. She had lymph node incisional biopsy and antibiotics before presentation, with temporary relief but deteriorated over several months with weight loss and increasing abdominal and leg swelling and eventually presented with generalized body swelling, nausea, vomiting, and weakness 10 months later. She was chronically ill looking, wasted, moderately pale, with bilateral cervical lymphadenopathies in anterior and posterior cervical, submandibular and axillary regions ranging from $2\text{ cm} \times 3\text{ cm}$ to $4\text{ cm} \times 6\text{ cm}$ and had an 8-cm incisional scar in the anterior part of the neck with bilateral pitting pedal edema up to the vulva. Her weight was 27 kg (>50 th percentile). Salient features were reduced tactile and vocal fremitus posteriorly with dull percussion notes upper zones anteriorly and stony dull percussion notes in the lower zones laterally and posteriorly, Pulse, 120/min; BP, 110/70 mm/Hg; distended abdomen with moderate ascites; 10-cm hepatomegaly; 4-cm splenomegaly; neck stiffness; and meningeal signs. A diagnosis of disseminated TB involving the lymph nodes, lungs, pleura, abdomen, and probably meninges was made. Chest X-ray showed right apical lobe opacities with pleural effusion. Abdominal USS revealed hepatosplenomegaly with matted mesenteric lymphadenitis, copious intraperitoneal echo-rich fluid collection, suggestive of abdominal TB. Full blood count (FBC) was white blood cell (WBC), $17.5 \times 10^3/\mu\text{L}$; packed cell volume (PCV), 28.9%; neutrophil, 93.8%; and lymphocyte, 3.1%. Erythrocyte sedimentation rate (ESR), 13 mm/h; red blood cell (RBC), Random blood sugar (RBS), 6.7 mmol/L; and Na, 127 mmol/L. She was to commence anti-TB drugs but developed worsening body weakness, cold extremities, nausea, and vomiting. Radial pulse was not palpable but brachial pulse was 130/min and BP dropped to 90/60 mm Hg. SPO_2 was 63% in room air and oxygen, normal saline infusion, intravenous hydrocortisone of 200 mg were given.

She improved and stabilized for a few hours and then had another episode of persistent vomiting with cold extremities, weak thready pulse, gasping respiration, and a blood pressure of 80/50 mm Hg and couldn't be resuscitated.

Discussion

Severe hyponatremia of 114 mmol/L in case 1, came as a surprise of 10-day anti-TB treatment and was announced by convulsion and coma. Severe hyponatremia occurs less commonly^{1,3} than mild forms,^{1,4,16} and so this case is a rarity. A rapid reduction of serum sodium to 110 to 120 mmol/L is usually associated with cerebral edema and possible brain herniation.³ She, however, responded to sodium correction, steroids, and anti-TB medications. Reports have shown treatment modalities of water restriction in SIADH secretion and salt and water infusion in Renal Salt Wasting (RSW),¹⁷ and it is important to differentiate CSWS from SIADH secretion since their treatments differ.⁹ Our patient had normal urine sodium, serum osmolality and urine osmolality. It is believed that urine sodium is raised in CSWS and reduced in SIADH secretion but a report showed the opposite.¹⁰ She developed tender hepatomegaly and renal parenchymal disease, raising the possibility of adrenal involvement and again, her episodes of coma were always associated with severe hyponatremia. Reports document RSW in 38% of patients in general hospital wards, with 21 of 24 lacking cerebral disease,¹⁷ and hence the proposals for a name change to RSW were made.¹⁷

The initial presentations of case 2 with fever, cough, neck swellings, and positive TB contact constituted the first missed opportunity for diagnosis. She later developed disseminated TB after several months and presented very late in our facility with generalized body swelling, nausea/vomiting, hypotension, shock, and collapse. Common clinical features of AI have been identified as fatigue/weakness, nausea/vomiting, hypotension/dizziness, altered sensorium, and seizures,¹⁵ and she had all these. AI is known to be life-threatening in children with 1 of 200 crises leading to death¹⁵ and was the direct cause of her death with the generalized body swelling, severe persistent vomiting, and hyponatremia in this background of TB. One constant limitation of various studies of AI is lack of availability of assays used to measure adrenocorticotrophic hormone (ACTH) and cortisol levels,¹⁴ like in case 2. The diagnostic consensus is an initial screening test of early morning cortisol level and adrenal stimulation test with exogenous ACTH creating a subnormal response.¹⁸ She had hyponatremia, recurrent hypotension, and collapsed while on admission and each time was revived by intravenous hydrocortisone until demise. The importance of early identification and prompt treatment with hydrocortisone cannot be over-emphasized.^{14,15} Hydrocortisone, which is preferred in children over other steroids,¹⁹ should be given and hypovolemia should be corrected with 20 mL/kg of isotonic saline,¹⁵ even if a blood sample cannot be collected. Interestingly, both cases had chest/abdominal findings diagnosed by chest X-ray/USS. USS has been found to be very useful in diagnosing extra PTB (EPTB) in both HIV-positive and HIV-negative children and

adults in resource poor settings.^{20,21} The focused assessment with sonography for HIV-associated tuberculosis (FASH) protocol is a simple, noninvasive and fast technique able to detect abnormal USS findings suggestive of EPTB in 27% of cases.²⁰ Similarly, the point of care USS (POCUS) identifies one-third of such cases.²¹

Conclusion

Childhood TB is still underdiagnosed with missed opportunities prevalent in health facilities, and thus there is an urgent need to raise the index of suspicion at all levels of care to identify these children. Early diagnosis and prompt treatment of TB hyponatremia is lifesaving because SIADH secretion, CSWS, and AI all require different regimens.

Specific Disclosure

Some of the results of these studies have been previously reported in the form of a published conference abstract (ATS 2019 Dallas, Texas).²²

Authors' Contributions

Conception and design, or acquisition, or analysis and interpretation of data: A.U.E., E.A.O., and K.O.I.

Drafting the article or revising it critically for important intellectual content: A.U.E.

Final approval of the version to be published: E.A.O., A.I.C., and K.O.I.

Agreement to be accountable for all aspects of the work to ensure that questions related to the accuracy or integrity of any part of the work are appropriately investigated and resolved: A.U.E., A.I.C., E.B.A., K.C.A., E.J.I., and E.S.B.

Funding

None.

Conflicts of Interest

None declared.

Acknowledgment

The authors wish to acknowledge all the pediatric resident doctors who took calls to keep case 1 alive by monitoring serum electrolytes and giving saline infusions according to the unit's protocol during her critical period and also acknowledge their efforts to save case 2 even though we lost her.

References

- Jonaidi Jafari N, Izadi M, Sarrafzadeh F, Heidari A, Ranjbar R, Saburi A. Hyponatremia due to pulmonary tuberculosis: review of 200 cases. *Nephrourol Mon* 2013;5(01):687–691
- Vinnard C, Blumberg EA. Endocrine and metabolic aspects of tuberculosis. *Microbiol Spectr* 2017;5(01):1–19
- Park SJ, Shin JI. Inflammation and hyponatremia: an underrecognized condition? *Korean J Pediatr* 2013;56(12):519–522
- Oh JY, Shin JI. Syndrome of inappropriate antidiuretic hormone secretion and cerebral/renal salt wasting syndrome: similarities and differences. *Front Pediatr* 2015;2:146

- 5 Jayakumar B, Sambasivam E. Clinical profile, etiology, management and outcome of serum sodium disturbances in children admitted in PICU. *Int J Res Med Sci* 2017;5(06):2546–2551
- 6 Kinjo T, Higuchi D, Oshiro Y, et al. Addison's disease due to tuberculosis that required differentiation from SIADH. *J Infect Chemother* 2009;15(04):239–242
- 7 Lee P, Ho KK. Hyponatremia in pulmonary TB: evidence of ectopic antidiuretic hormone production. *Chest* 2010;137(01):207–208
- 8 Camous L, Valin N, Zaragoza JL, et al. Hyponatraemic syndrome in a patient with tuberculosis—always the adrenals? *Nephrol Dial Transplant* 2008;23(01):393–395
- 9 Bosnak M, Özdoğan H, Yel S, Bosnak V, Haspolat K. Hyponatremia in a child with tuberculosis meningitis in PICU: cerebral salt wasting syndrome. *Dicle Med J* 2009;36(03):200–202
- 10 Verbalis JG. The curious story of cerebral salt wasting: fact or fiction? *Clin J Am Soc Nephrol* 2020;15(11):1666–1668
- 11 Friedman E. Tuberculosis of the adrenal glands in a child of twelve, with necropsy. *Am J Dis Child* 1936;51(01):113–117
- 12 Barnes DJ, Naraqi S, Temu P, Turtle JR. Adrenal function in patients with active tuberculosis. *Thorax* 1989;44(05):422–424
- 13 Al-Mamari A, Balkhair A, Gujjar A, et al. A case of disseminated tuberculosis with adrenal insufficiency. *Sultan Qaboos Univ Med J* 2009;9(03):324–327
- 14 Upadhyay J, Sudhindra P, Abraham G, Trivedi N. Tuberculosis of the adrenal gland: a case report and review of the literature of infections of the adrenal gland. *Int J Endocrinol* 2014;2014:876037
- 15 Miller BS, Spencer SP, Geffner ME, et al. Emergency management of adrenal insufficiency in children: advocating for treatment options in outpatient and field settings. *J Investig Med* 2020;68(01):16–25
- 16 Poddighe D. Common finding of mild hyponatremia in children evaluated at the Emergency Department and its correlation with plasma C-reactive protein values. *Minerva Pediatr* 2016;68(03):173–176
- 17 Maesaka JK, Imbriano LJ, Miyawaki N. Evolution and evolving resolution of controversy over existence and prevalence of cerebral/renal salt wasting. *Curr Opin Nephrol Hypertens* 2020;29(02):213–220
- 18 Auron M, Raissouni N. Adrenal insufficiency. *Pediatr Rev* 2015;36(03):92–102, quiz 103, 129
- 19 Bowden SA, Henry R. Pediatric adrenal insufficiency: diagnosis, management, and new therapies. *Int J Pediatr* 2018;2018:1739831
- 20 Bobbio F, Di Gennaro F, Marotta C, et al. Focused ultrasound to diagnose HIV-associated tuberculosis (FASH) in the extremely resource-limited setting of South Sudan: a cross-sectional study. *BMJ Open* 2019;9(04):e027179
- 21 B  lard S, Heuvelings CC, Banderker E, et al. Utility of point-of-care ultrasound in children with pulmonary tuberculosis. *Pediatr Infect Dis J* 2018;37(07):637–642
- 22 Ewa AU, Ochang EA, Inaku KO, Anachuna KC, Imoke EJ. Recurrent hyponatremia in tuberculous pleural effusion—who is the enemy within? *Am J Respir Crit Care Med* 2019;199:A4974