



## SPECIAL ARTICLE COVID-19

# Auditive and Vestibular Changes Related to the Use of Hydroxychloroquine and Chloroquine: An Integrative Review\*

Diana Babini Lapa de Albuquerque Britto<sup>1</sup> Mônia Ferreira Borges Rocha<sup>2</sup>   
 Jéssica Dayane da Silva<sup>2</sup> Natália dos Santos Pinheiro<sup>2</sup> Lidiane Kelvin da Silva<sup>3</sup>   
 Karina Paes Advíncula<sup>1</sup>

<sup>1</sup> Speech Therapy Department, Universidade Federal de Pernambuco (UFPE), Recife, PE, Brazil

<sup>2</sup> Graduate Program on Health of Human Communication, Health Sciences Center, Universidade Federal de Pernambuco (UFPE), Recife, PE, Brazil

<sup>3</sup> Multiprofessional Residency Program on Interiorization of Health Care, Graduate Department, Universidade Federal de Pernambuco (UFPE), Vitória de Santo Antão, PE, Brazil

Address for correspondence Diana Babini Lapa de Albuquerque Britto, Rua Professor Arthur de Sá, s/n°, Cidade Universitária, Recife, PE, 50740-520, Brazil (e-mail: diana.babini@gmail.com).

Int Arch Otorhinolaryngol 2021;25(2):e309–e317.

## Abstract

**Introduction** The use of hydroxychloroquine and chloroquine is formally indicated in cases of chronic autoimmune diseases. However, the use of these medications has already been associated with possible transitory or definitive alterations in hearing function and/or vestibular function in humans, when administered in the short and long terms. **Objective** To describe, through a literature analysis, the functional vestibular and/or hearing alterations, caused by the use of hydroxychloroquine and chloroquine in youths and adults.

**Data Synthesis** In total, 2,481 studies were identified in the initial search: out of these 32 were selected for a full-text reading, and 9 were selected after the exclusion of those which did not meet the eligibility criteria. Of these, four articles pointed to the presence of vestibular and auditory-associated alterations, three indicated only auditory pathologies, and two, vestibular disorders. Regarding the auditory alterations, tinnitus was the most frequent symptom, and bilateral sensorineural hearing loss was described in most studies, varying in degree from mild to severe. As for the vestibular alterations, vertigo was the most reported symptom.

**Conclusion** Knowledge of the auditory and vestibular effects after the use of these substances can help in the decision regarding the best treatment, enabling the consideration of other available therapies for patients at risk of suffering those alterations, reducing the risk of auditory and vestibular disorders.

## Keywords

- hearing
- hearing loss
- vestibular alterations
- chloroquine
- hydroxychloroquine

\* Work performed at the Speech Therapy Department, Universidade Federal de Pernambuco (UFPE), Recife, PE, Brazil.

received  
August 22, 2020  
accepted  
November 8, 2020  
published online  
March 29, 2021

DOI <https://doi.org/10.1055/s-0040-1722292>.  
ISSN 1809-9777.

© 2021. Fundação Otorrinolaringologia. All rights reserved.  
This is an open access article published by Thieme under the terms of the Creative Commons Attribution-NonDerivative-NonCommercial-License, permitting copying and reproduction so long as the original work is given appropriate credit. Contents may not be used for commercial purposes, or adapted, remixed, transformed or built upon. (<https://creativecommons.org/licenses/by-nc-nd/4.0/>)  
Thieme Revinter Publicações Ltda., Rua do Matoso 170, Rio de Janeiro, RJ, CEP 20270-135, Brazil

## Introduction

In December 2019, an increasing number of cases of acute respiratory disease in the province of Wuhan, China, was being related to a new  $\beta$ -coronavirus, temporarily named 2019-nCoV.<sup>1</sup> On February 11th, 2020, the World Health Organization (WHO) officially named the pathogen SARS-CoV-2 and the infectious disease caused by it, COVID-19.<sup>2</sup> In the following month, the entity recognized the occurrence of the infection with great geographic distribution, and declared a state of pandemic.<sup>3</sup> Brazil is one of the countries with community transmission of COVID-19, presenting 438,238 cases and 26,754 deaths by the disease confirmed until May 30th, 2020.<sup>4</sup>

The most common symptoms of COVID-19 are fever, fatigue, and dry cough, and some patients can present myalgia, runny nose, sore throat, and diarrhea, those being normally considered light symptoms. However, some patients can develop more serious symptoms, such as dyspnea and severe acute respiratory syndrome (SARS), with the need for intensive therapy and the use of mechanical ventilation; in these cases, the disease may be fatal.<sup>5,6</sup>

COVID-19 infects people of all ages; some cases are asymptomatic, and the factors that determine the clinical manifestation of the disease are still unknown. Yet, shreds of evidence until now suggest that elderly people or those with underlying medical issues are under higher risk of developing the severe symptoms of the pathology.<sup>3</sup>

Considering the rapid advance of the disease, and the development of quick diagnostic tests with good accuracy, researchers have also been able to test therapeutic options to the treatment and prevention of this disease and its complications. Thus, based on preliminary studies, Chinese and South Korean health authorities have recommended the off-label use of hydroxychloroquine (HQ) and chloroquine (CQ) in cases of COVID-19 to prevent or treat one of the most severe symptoms of the disease: acute respiratory infection.<sup>7-9</sup>

The use of HQ and CQ is formally indicated in cases of chronic autoimmune disease, such as systemic lupus erythematosus, rheumatoid arthritis, photosensitive diseases, and malaria; despite the absence of recommendations from the Brazilian National Health Surveillance Agency (Agência Nacional de Vigilância Sanitária, Anvisa, in Portuguese), the off-label use of these drugs to treat COVID-19 has already spread in Brazil and worldwide.<sup>10</sup>

Antiviral drugs are being urgently administrated to COVID-19 patients, such as favipiravir, remdesivir, CQ, HQ, lopinavir, ritonavir and interferon PEGylated with ribavirin.<sup>11</sup> However, the drugs considered to have a high potential in the treatment of COVID-19 are CQ and HQ.<sup>12</sup>

Chloroquine and HQ have different chemical structures, but belong to the same aromatic 4-aminoquinoline group, and are fully absorbed in the gastrointestinal tract. These substances achieve peak plasmatic concentrations in 2 to 8 hours; they are slowly eliminated by the kidneys (in 3 to 6 months), and can accumulate in the liver, spleen, lungs, kidneys, eyes, skin, adrenal glands and the pituitary gland, and they remain in the body for years after the discontinuation of its use.<sup>13</sup>

Despite being cited as a potentially promising antiviral drug for the treatment of COVID-19,<sup>11,12</sup> CQ and HQ, known as antimalarial drugs, have been associated with possible transitory or definite alterations in the auditory and/or vestibular functions in humans, when administered in the short or long terms.<sup>14</sup>

Pioneer studies on the use of these drugs on humans report that such substances have a selective affinity to melanin-carrying cells, which are also found in the inner ear; therefore, these cells can suffer from alterations in their function.<sup>15</sup>

It is presumed that these temporary and/or permanent auditory alterations and vestibular dysfunctions are caused by the toxicity of those substances.

The limited knowledge on these side effects makes the review of the matter necessary. Thus, the present integrative review has the objective of describing auditory and/or vestibular functional alterations related to the short- or long-term use of HQ and CQ in patients aged between 18 and 55 years.

## Review of the Literature

Between March and April, 2020, we conducted a search on the following databases: PubMed; Web of Science; Scientific Electronic Library Online (SciELO); Latin American and Caribbean Health Sciences Literature (LILACS); Scopus; Science Direct; and the Cochrane Library. As for the gray literature, we consulted the following databases: OpenGrey; DissOnline; and OALster, without restrictions regarding language or publishing date. The search was conducted using the following Medical Subject Headings (MeSH): *hydroxychloroquine AND hearing OR hearing loss OR hearing disease; chloroquine AND hearing OR hearing loss OR hearing disease; hydroxychloroquine AND vestibular diseases OR labyrinth diseases; and chloroquine AND vestibular diseases OR labyrinth diseases.*

## Selection of Studies and Data Extraction

Following the inclusion criteria, two independent reviewers initially selected the articles through a review of the titles and abstracts; the studies that seemed to fill the inclusion criteria had their full texts read, and the following data was extracted from them: title, authors, publishing date, country, design and objective of the study, sample size and age range, drugs used, duration of the therapy, auditory and vestibular alterations, conclusions, and evidence level. Discrepancies related to the selection and extraction of data were discussed between the reviewers at the end of each step to reach a consensus, and, in the absence of agreement, a third reviewer was consulted. The data was compiled in tables for systematization.

## Inclusion Criteria

The inclusion criteria were as follows: studies with human patients with ages ranging between 18 and 55 years, who had used CQ and/or HQ, and were subjected to any type of auditory exam and/or self-report questionnaire related to the auditory and vestibular functions, with hypotheses or evidence of pathophysiology of compromised hearing associated with the use of these drugs.

We excluded literature reviews, book chapters, and studies with individuals with previous auditory and/or vestibular functional alterations.

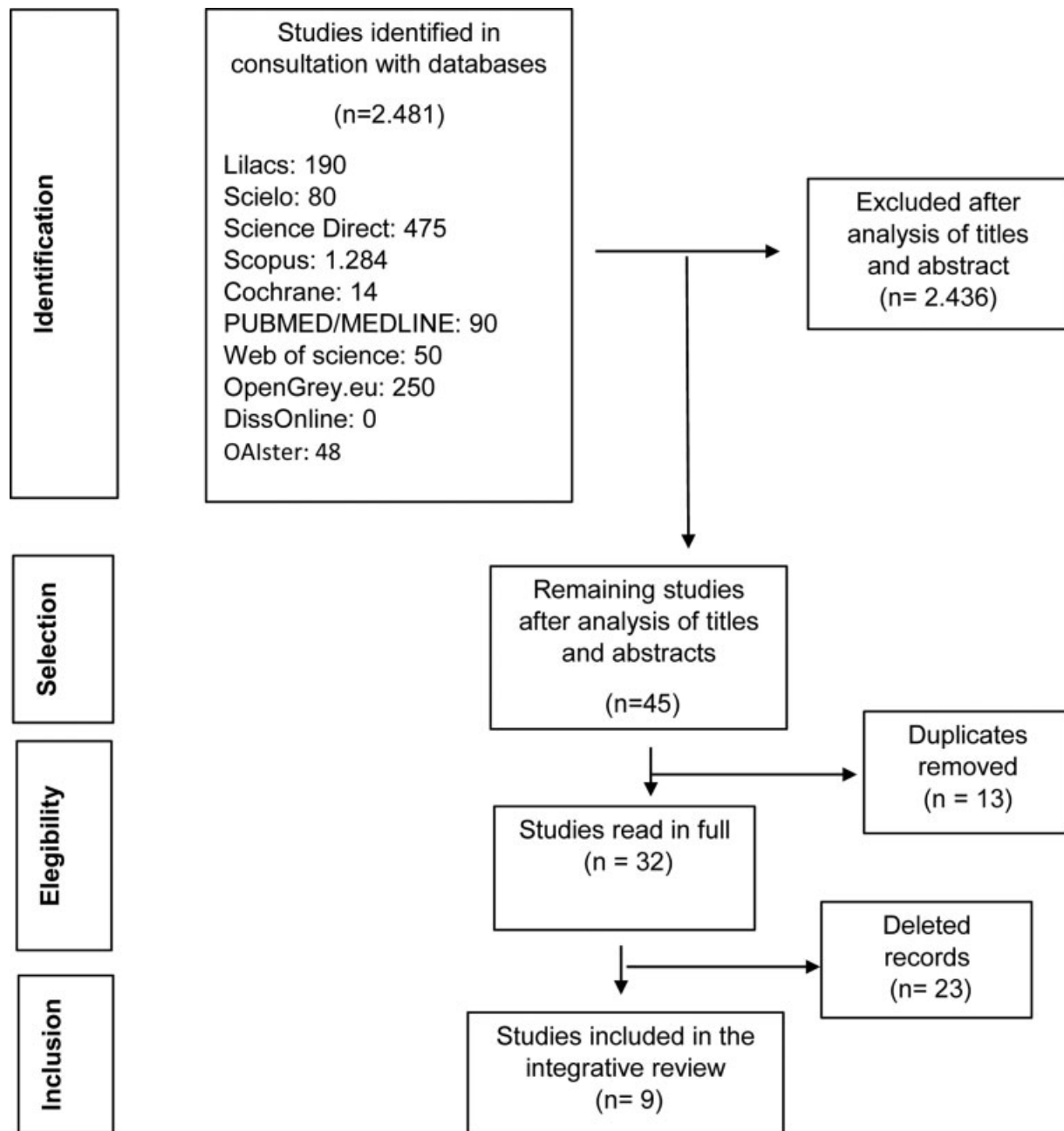
## Results of the Integrative Review

In the initial search, 2,481 studies were identified, and 32 of them had their full texts read; then, 9 were selected after the exclusion of those which did not meet the eligibility criteria. The other 23 articles were excluded because: they were literature reviews (8); the auditory and/or vestibular alterations were associated with the base disease and not the drugs used (5); they were studies involving animals (3); the sample was out of the age range defined by the present

review (5); they described preexisting auditory and/or vestibular alterations (1); and they made use of another kind of medication (1).

The included studies were: 6 case studies (level of evidence: 5),<sup>15–20</sup> 1 non-randomized clinical trial (level of evidence: 3),<sup>21</sup> 1 case-control study (level of evidence: 4),<sup>22</sup> and 1 cross-sectional observational study (level of evidence: 4) (► Fig. 1).<sup>23,24</sup>

A flowchart of the process of selection of articles is presented in ► Fig. 1. The selected studies were published between 1975 and 2018 in Europe,<sup>17,19,23</sup> South America,<sup>16</sup> North America,<sup>20,22</sup> Asia,<sup>15,18</sup> and Africa.<sup>21</sup> The age of the patients ranged from 18 to 57 years, and they had diseases like rheumatoid arthritis,<sup>18–20,22,23</sup> malaria,<sup>15,19</sup> systemic lupus erythematosus,<sup>17,19</sup> chronic cutaneous lupus erythematosus,<sup>16</sup>



**Fig. 1** Flowchart of the selection of studies for the review.

Sjogren syndrome,<sup>19</sup> and human immunodeficiency virus (HIV) (► **Table 1**).<sup>18,22</sup>

► **Table 2** presents the data extracted from the results and conclusion of the studies selected for the present review, and three of them had as targets individuals medicated with CQ,<sup>15,21,22</sup> five, with HQ,<sup>16–19,23</sup> and one described a patient to whom both drugs were administered.<sup>20</sup> The oral doses administrated were of 400 mg/day in all of the studies that

presented this information, and only one study involved intravenous administration.<sup>21</sup>

In total, four articles reported an association of vestibular and auditory alterations,<sup>17,19,22</sup> three indicated only hearing pathologies,<sup>16,18,23</sup> and two, vestibular disorders.<sup>20,21</sup> The results of the auditory exams were described in eight studies,<sup>15–18,20–23</sup> and a vestibular evaluation was only performed in three of them (► **Table 2**).<sup>15,17,22</sup>

**Table 1** Description of the studies included in the integrative literature review

Author, year	Title	Country	Objective	Study design	Age of the patient/ age range of the sample	Sample
Prince and Hardin, <sup>20</sup> 1975	Hydroxychloroquine-induced vertigo	United States	To report the treatment of a patient with rheumatoid arthritis.	Case report	54 years old	1
Dwivedi and Mehra, <sup>15</sup> 1978	Ototoxicity of chloroquine phosphate. A case report	India	To report the case of a patient with bilateral sensorineural deafness after ingesting chloroquine.	Case report	54 years old	1
Gustafsson et al., <sup>21</sup> 1983	Disposition of chloroquine in man after single intravenous and oral doses	Nigeria	To assess the basics pharmacokinetics of chloroquine in healthy subjects.	Non-randomized clinical trial	20 to 36 years old	11
Bernard, <sup>22</sup> 1985	Alterations of auditory evoked potentials during the course of chloroquine treatment	Canada	To test the hearing of patients undergoing chloroquine therapy.	Case-control study	18 to 50 years old	74
Seçkin et al., <sup>23</sup> 2000	Hydroxychloroquine ototoxicity in a patient with rheumatoid arthritis	Turkey	To present the case of treatment for rheumatoid arthritis with hydroxychloroquine.	Case report	34 years old	1
Jourde-Chiche et al., <sup>19</sup> 2012	Antimalarial ototoxicity: An underdiagnosed complication? A study of spontaneous reports to the French Pharmacovigilance Network	France	To evaluate the side effects in patients treated with antimalarials.	Cross-sectional observational study	—	57
Khalili et al., <sup>18</sup> 2014	A case report of hearing loss post use of hydroxychloroquine in a HIV-infected patient	Iran	To describe a case of reversible symmetrical sensorineural hearing loss after using hydroxychloroquine.	Case report	57 years old	1
Chatelet et al., <sup>17</sup> 2017	Hydroxychloroquine-induced hearing loss: First case of positive rechallenge and analysis of the French pharmacovigilance database	France	To report a case of hearing loss induced by hydroxychloroquine.	Case report	33 years old	1
Fernandes et al., <sup>18</sup> 2018	Hydroxychloroquine ototoxicity in a patient with systemic lupus erythematosus	Brazil	To alert about the potential ototoxic risk posed by anti-malarials and to suggest that patients should be carefully warned	Case report	51 years old	1

**Table 2** Type of treatment, duration, outcomes and main conclusions of the selected studies

Author, year	Condition	Dose and type of drug	Duration of the treatment	Audiological changes	Balance changes	Main conclusions
Dwivedi and Mehra, <sup>15</sup> 1978	Malaria	Four tablets containing 25 mg of chloroquine each.	—	Report of bilateral hearing loss and tinnitus. The hearing tests showed: pure tone audiometry with missing thresholds in all frequencies in the left ear. In the right ear, the thresholds were present only at 500 Hz, 750 Hz, and 2,000 Hz with maximum intensity (100 dB). Impedance and the tympanogram were normal. Stapedial reflexes were recorded in both ears at 500 Hz, but only at 125 dB.	Reports of vertigo and blurred vision one hour after ingestion. The vertigo gradually decreased. The vestibular exams showed: the absence of spontaneous or positional nystagmus, and the fistula test was negative. The Kobrac caloric test with ice water did not show any response in either ear.	They suggest that, in the patient described, chloroquine had been deposited on melanin pigments, such as the tissues of the inner ear, causing immediate severe bilateral sensorineural deafness.
Gustafsson et al., <sup>21</sup> 1983	Healthy individuals	Three intravenous doses of 300 mg of chloroquine	Intervals between doses greater than 56 days.	No changes were found in routine audiometry before and after drug administration. In the high-frequency curves, greater variations in the threshold were found, but without a significant increase.	Reports of dizziness, diplopia, and difficulty in locomotion up to 45 minutes after the infusion.	They point out the absence of conclusive signs of ototoxicity in conventional and high-frequency audiometry. In two cases, there were statistically significant changes in the high-frequency recordings. The high affinity of the drug to minor components, such as melanin, which are contained in sensory organs can be of great importance regarding the side effects. However, they may not be significant for the general kinetics of the drug.
Bernard, <sup>22</sup> 1985	Rheumatoid arthritis positive serum and lupus systemic erythematosus.	—	Initial assessment in the first three weeks of treatment.	Changes in the brainstem auditory-evoked potential of 13 patients, starting from the eighth month of treatment, with an increase in the absolute values of the latencies of waves III and V and interpeaks I-III and III-V. Reports of tinnitus.	Report of imbalance. One patient needed to continue with the treatment and presented constant disorientation, with repeated attacks of acute vertigo, slightly reduced labyrinthine excitability, and greater hearing impairment.	They found that the long-term use of chloroquine generated changes in the brainstem auditory-evoked potential in 13 of the 74 patients. The interruption of the treatment favors the reversion of the changes. Patients who needed to continue the treatment have progressed with the hearing abnormalities, which generated permanent hearing loss.
Prince and Hardin, <sup>20</sup> 1975	Rheumatoid arthritis	400 mg/day of chloroquine	—	No audiological changes were observed.	Blurred vision, unsteady gait, severe nausea, and positional vertigo were observed. The nausea and vertigo were aggravated by the slightest movement of the head, and the treatment was interrupted. After drug reintroduction, the vertigo and headache came back: the therapy was discontinued. All symptoms disappeared in 36 hours.	They suggest that transient dizziness and mild headache are only reported after long-term or high-dose chloroquine and hydroxychloroquine therapy. The patient described received less than 1 g orally before toxic reactions were observed.
	Rheumatoid arthritis		Three Months		—	

(Continued)

Table 2 (Continued)

Author, year	Condition	Dose and type of drug	Duration of the treatment	Audiological changes	Balance changes	Main conclusions
Seçkin et al., <sup>23</sup> 2000		400 mg/day of hydroxychloroquine		Report of hearing loss and tinnitus. The audiometry indicated bilateral sensorineural hearing loss.		They consider the ototoxicity induced by the treatment with hydroxychloroquine to be a rare event, remissive after the interruption of the treatment.
Khalili et al., <sup>18</sup> 2014	Positive human immunodeficiency virus-associated with rheumatoid arthritis	400 mg/day of hydroxychloroquine	One month	The hearing tests showed: pure tone audiometry and speech with moderate to severe sensorineural hearing loss and reduced speech recognition in both ears. Acoustic reflex present.	—	They concluded that hydroxychloroquine-induced hearing loss may appear after a short period of administration, especially in patients with underlying viral infections. The auditory alterations can disappear after the interruption of the treatment with the drug and the introduction of corticosteroid therapy.
Chatelet et al., <sup>17</sup> 2017	Systemic lupus	400 mg/day of hydroxychloroquine	—	Sudden bilateral hearing loss in the first treatment and improvement reported after its interruption. After the reintroduction of the drug, bilateral hearing loss was observed at a frequency of 1,000 Hz.	Vestibular syndrome in the first treatment, which improved after the interruption of hydroxychloroquine. With the resumption of the treatment, peripheral vestibular syndrome was reported, but it was not identified in the cochleovestibular evaluation.	They suggest that the auditory and vestibular alterations that are reactive to the use of hydroxychloroquine are iatrogenic and another part of the pre-existing disease. However, they point out that the improvement during the withdrawal of the drug and the worsening of the disorders after its reintroduction point to its etiological responsibility. They emphasize the need to alert the prescribers of the medication, to avoid irreversible sequelae.
Fernandes et al., <sup>18</sup> 2018	Chronic cutaneous lupus erythematosus	400 mg/day of hydroxychloroquine	Three Years	Report of tinnitus and bilateral hearing loss. Pure tone audiometry showed moderate sensorineural hearing loss in the left ear, and mild to moderate in the right ear.	—	They suggest an audiological evaluation in patients who use antimalarials regularly and for a prolonged period, so that the ototoxic changes are checked early, avoiding possible irreversible damage.
Jourde-Chiche et al., <sup>19</sup> 2012	Lupus, rheumatoid arthritis, Sjogren syndrome, malaria, and undetermined pathologies	—	Reports of symptom onset after 24 hours. The rest of the symptoms appeared after a month of use.	Reports of hearing loss and tinnitus.	Reports of vertigo.	They point out that the ototoxicity of hydroxy and chloroquinehydroxychloroquine is rare, but can be irreversible. There was no determination of the period of use for the onset of symptoms. They suggest that therapists inform the risks at the beginning of the treatment, as well as monitor the auditory pathways.



**Table 3** Description of the auditory and vestibular alterations caused by the ingestion of hydroxychloroquine and chloroquine

Medication	Hearing disorders	Vestibular disorders
Hydroxychloroquine	- Tinnitus - Hearing loss	- Blurred vision - Unstable gait - Nausea - Vertigo (posture)
Chloroquine	- Tinnitus - Hearing loss - Absent stapedial reflex	- Vertigo - Diplopia - Labyrinthine excitability

► **Table 3** presents a summary of the auditory and vestibular alterations described in the selected studies; tinnitus<sup>15,16,19,22,23</sup> was the most commonly described symptom, and many studies<sup>15–17,23</sup> reported mild to severe bilateral sensorineural hearing loss (HL). As for the vestibular alterations, positional or non-positional vertigo,<sup>15,19,20,22</sup> was the most reported symptom (► **Table 3**).

## Discussion

To have a greater understanding of the different audiological and vestibular findings after the ingestion of the two medications in the studies herein analyzed, the following two sections describe their findings.

### Auditory and Vestibular Disorders after the Ingestion of Hydroxychloroquine (HQ)

Hydroxychloroquine is used to treat different pathologies. In the included studies, it was possible to observe its oral administration in patients with lupus systemic erythematosus,<sup>16,17</sup> rheumatoid arthritis,<sup>15,18,19</sup> and human immunodeficiency virus.<sup>18</sup>

In these surveys, the authors associate changes in the cochlear-vestibular system with the use of HQ, excluding the relationship with the underlying disease by verifying negative results for antiphospholipid antibodies,<sup>16</sup> the association of the medication with these changes using the Naranjo scale,<sup>17,18</sup> the onset of symptoms through drug ingestion,<sup>19</sup> and complaints other than the clinical manifestation of the studied pathology.<sup>15,17</sup>

The authors pointed out that signs and symptoms of auditory and vestibular disorders appear with the short-term exposure, either in the period of days<sup>19</sup> or months.<sup>15,16,18</sup>

Only one of the studies indicated the onset of complaints after years of ingestion of HQ.<sup>17</sup> It is not possible to generalize the symptoms found after using the drug, since few individuals are investigated and different clinical manifestations are reported in the studies.

The audiological complaints reported by the patients were tinnitus<sup>15,16</sup> and bilateral HL,<sup>15,16</sup> which may appear suddenly<sup>17</sup> or progressively slow.<sup>18</sup> None of the studies show results of vestibular exams, but vestibular syndrome<sup>17</sup> and the presence of nausea and vertigo worsened by head

movement, in addition to the observation of nystagmoid eye movements in lateral view.<sup>19</sup>

As for the audiological evaluations, there is a predominance of bilateral sensorineural HL,<sup>15,16,18</sup> ranging from mild to profound, in addition to an indication of a reduction in speech recognition thresholds.<sup>18</sup> Among the articles that demonstrate hearing complaints, only one did not perform audiological tests.<sup>17</sup>

The drug therapy was discontinued in all studies. Only one patient remained on prednisolone,<sup>18</sup> which was used in combination with HQ, and another one<sup>17</sup> was treated with 3 doses of 1,000 mg of intravenous methylprednisolone. The researches showed the remission of the auditory and vestibular symptoms after the discontinuation of the HQ,<sup>15,19</sup> and two of them showed only improvements in the audiograms, with the patients remaining with mild HL<sup>17,18</sup> and changes in speech intelligibility.<sup>18</sup> However, even after four months without the use of the medication, the patient with speech intelligibility<sup>18</sup> remained with HL and tinnitus.<sup>16</sup>

After remission of the auditory and vestibular symptoms, two patients from different studies<sup>17,19</sup> were once again submitted to HQ therapy. In one of the studies,<sup>19</sup> the drug was reintroduced days after the disappearance of the vestibular manifestations, and the patient reported the reappearance of headache and vertigo 48 hours after ingestion; the medication was discontinued again, therapy with prednisolone was started, and the symptoms disappeared after 36 hours, and did not recur in the following twelve months. In the other study,<sup>17</sup> the medication was also reintroduced, and the patient once again had peripheral vestibular syndrome, and was diagnosed with neuritis. Four months after the last interruption, the individual had no vestibular symptoms; however, bilateral HL was identified at a frequency of 1 KHz.

The ototoxicity of HQ is a serious complication that interferes with the quality of life and functional activities of individuals,<sup>16</sup> and it may appear in a short time and with low doses in the treatment of different pathologies.<sup>16,18</sup> Despite the possibility of changing to corticosteroid therapy,<sup>18</sup> interruption of the drug does not always lead to the disappearance of symptoms.<sup>17</sup>

Although cases of HQ ototoxicity are rare,<sup>16,17</sup> the authors of the analyzed studies point out the need for prescribers to know about possible side effects and report the risks to the patients before starting the therapy.<sup>16,17</sup> They also highlight the need to periodically evaluate these patients, especially those who have been using the drug for prolonged periods of time, observing the appearance of any signs or symptoms.<sup>16</sup>

### Auditory and Vestibular Disorders after the Ingestion of Chloroquine (CQ)

In studies that aimed to report the side effects of CQ, the use of the drug was investigated in healthy individuals,<sup>20</sup> and in individuals with malaria,<sup>21,22</sup> rheumatoid arthritis,<sup>22,23</sup> lupus erythematosus,<sup>22,23</sup> and Sjogren syndrome.<sup>22</sup>

The authors point out that auditory and vestibular symptoms can appear immediately or in the short term, such as one hour after taking the drug,<sup>20,21</sup> one day, or even one month after using it.<sup>22</sup> The most commonly reported hearing symptoms

were tinnitus<sup>21-23</sup> and HL,<sup>21-23</sup> and the vestibular symptoms were vertigo and/or dizziness<sup>20-23</sup> and imbalance.<sup>23</sup>

The type of administration was related to the onset of adverse effects in three studies, in which all individuals who received a dose by intravenous infusion reported adverse effects,<sup>20</sup> while in cases of oral administration, some had symptoms,<sup>21,23</sup> and others did not have objective side effects.<sup>20</sup>

Regarding the findings of the audiological tests, no changes were described in the external ear canal and tympanic membrane<sup>20-23</sup> referring to normal tympanometries and middle ear pressure.<sup>21</sup> A decrease in stapedial reflexes was recorded at 125 dB for the frequency of 500 Hz in both ears.<sup>21</sup>

In the evaluation of pure-tone audiometry, the absence of thresholds was observed in all frequencies in the left ear, and, in the right ear, their presence was only observed in the frequencies of 500 Hz, 750 Hz and 2,000 Hz, but with a maximum intensity of 100 dB, characterizing deep sensorineural HL in both ears.<sup>21</sup> Besides, significant variations in high-frequency thresholds were found after the administration of CQ.<sup>20</sup>

In the evaluation of the brainstem auditory-evoked potential (BAEP), changes were described around the eighth month of treatment in 13 patients with rheumatoid arthritis, characterized by increased latencies in waves III and V and in interpeaks I-III and III-V, with the possibility of alterations in the fifth wave being interpreted as a sign of primary changes in the basal part of the cochlea.<sup>23</sup>

Only one study<sup>21</sup> described vestibular assessment tests, showing the absence of spontaneous or positional nystagmus, negative fistula test, and Kobrac caloric test with cold water without response in both ears.

Regarding the remission and persistence of the auditory and vestibular alterations, vertigo<sup>21</sup> and imbalance<sup>23</sup> gradually decreased after the discontinuation of CQ, and were described as transient episodes, but they may become irreversible with the continuous use of the medication.<sup>22</sup>

The persistence and irreversibility of the alterations were more described for the symptoms of tinnitus and HL,<sup>21,22</sup> with remissions of these changes observed in a period of 12 to 16 months after the interruption of the treatment.<sup>23</sup> The onset of irreversible bilateral sensorineural deafness was also reported after a few days of using the drug,<sup>22</sup> as well as the immediate onset after the first dose.<sup>21,22</sup>

In patients with rheumatoid arthritis who required prolonged therapy with CQ for pain control, progressive deterioration of hearing was observed, with a change in the latency of wave I of the BAEP associated with an increase in the auditory threshold and a decrease in the speech discrimination score, with no additional deterioration of the hearing thresholds or vestibular function after two years of follow-up.<sup>23</sup>

Some studies<sup>20,21</sup> agree that the involvement of CQ with cells that carry melanin found in the tissues of the inner ear may be responsible for the adverse effects on individuals, and that this tissue affinity is extensive and variable.

Although some authors confirm the ototoxicity caused by high and prolonged doses of CQ, it may result in irreversible HL and reversible damage if the medication is stopped<sup>21,23</sup> some studies reported that the results did not enable the determination of the real incidence of the medication-

related ototoxicity,<sup>22</sup> and that the threshold changes observed in the high-frequency audiometry did not reveal conclusive signs of ototoxicity, but may indicate a subtle effect of CQ on hearing.<sup>20</sup>

Thus, although CQ is a drug with unusual pharmacokinetic properties,<sup>20</sup> there is a consensus among the studies that interrupting the CQ treatment may favor the reversal of auditory and vestibular alterations caused by its use,<sup>21-23</sup> and that individuals who need to continue the treatment have risks of progression, which can generate permanent HL.<sup>23</sup> Moreover, they suggest that therapists inform the risks at the beginning of the treatment, and that monitoring of the auditory pathway should be performed.<sup>22</sup>

Considering the variability of the ototoxic effects and the time of manifestation of these alterations shown in the present study, new researches must be performed to expand the knowledge of the impact of HQ and CQ in the auditory and vestibular systems.

## Final Comments

The data available in the present review showed evidences of auditory and vestibular alterations associated with the use of QC and HQ in humans, with the most reported symptoms being sensorineural HL, tinnitus, and vertigo for both medications. Such manifestations were reported in the short and long terms after treatment with both substances, and, with the discontinuation of their use, the symptoms ceased or reversed.

The knowledge of these auditory and vestibular effects after the use of these substances can help in the decision regarding the best treatment, so that other available therapies can be considered in the case of patients who are already at risk of suffering these alterations, reducing the probability of hearing disorders and vestibular disorders.

Thus, considering the widespread use of these drugs in the recent COVID-19 pandemic, the present review endorses the importance of further research on the adverse effects related to auditory and/or vestibular functions with the use of HQ and CQ, as a support in the treatment of COVID-19. In addition, the need to alert the patients about the risks inherent to the use of these medications before the treatment and the importance of conducting audiological monitoring during the ingestion of these components are emphasized.

## Funding

Financial support by the Coordenação de Aperfeiçoamento de Pessoal de Nível Superior – Brazil (CAPES) – Finance Code 001.

## Conflict of Interests

The authors have no conflict of interests to declare.

## References

- 1 World Health Organization. 2020 Novel Coronavirus (2019-nCoV) Situation report - 1. [Internet]. . Accessed in 2020 apr 21 from: [https://www.who.int/docs/default-source/coronaviruse/situation-reports/20200121-sitrep-1-2019-ncov.pdf?sfvrsn=20a99c10\\_4](https://www.who.int/docs/default-source/coronaviruse/situation-reports/20200121-sitrep-1-2019-ncov.pdf?sfvrsn=20a99c10_4)



- 2 World Health Organization. 2020 Novel Coronavirus (2019-nCoV) Situation report - 22. [Internet]. . Accessed in 2020 apr 11 from: [https://www.who.int/docs/default-source/coronaviruse/situation-reports/20200211-sitrep-22-ncov.pdf?sfvrsn=fb6d49b1\\_2](https://www.who.int/docs/default-source/coronaviruse/situation-reports/20200211-sitrep-22-ncov.pdf?sfvrsn=fb6d49b1_2)
- 3 World Health Organization. 2020 Coronavirus disease (COVID-19) Situation report - 51. [Internet]. . Accessed in Mar 11 from: [https://www.who.int/docs/default-source/coronaviruse/situation-reports/20200311-sitrep-51-covid-19.pdf?sfvrsn=1ba62e57\\_10](https://www.who.int/docs/default-source/coronaviruse/situation-reports/20200311-sitrep-51-covid-19.pdf?sfvrsn=1ba62e57_10)
- 4 World Health Organization. 2020 Coronavirus disease (COVID-19) Situation report - 131. [Internet]. . Accessed in May 30 from: [https://www.who.int/docs/default-source/coronaviruse/situation-reports/20200530-covid-19-sitrep-131.pdf?sfvrsn=d31ba4b3\\_2](https://www.who.int/docs/default-source/coronaviruse/situation-reports/20200530-covid-19-sitrep-131.pdf?sfvrsn=d31ba4b3_2)
- 5 Huang C, Wang Y, Li X, et al. Clinical features of patients infected with 2019 novel coronavirus in Wuhan, China. *Lancet* 2020;395(10223):497–506. Doi: 10.1016/S0140-6736(20)30183-5
- 6 Jiang F, Deng L, Zhang L, Cai Y, Cheung CW, Xia Z. Review of the Clinical Characteristics of Coronavirus Disease 2019 (COVID-19). *J Gen Intern Med* 2020;35(05):1545–1549. Doi: 10.1007/s11606-020-05762-w
- 7 Sung-sun K. 2020 Physicians work out treatment guidelines for coronavirus. [Internet]. Accessed in 2020 mar 19 from: [m.koreabiomed.com/news/articleView.html?idxno=7428](http://m.koreabiomed.com/news/articleView.html?idxno=7428)
- 8 Yao X, Ye F, Zhang M, et al. In Vitro Antiviral Activity and Projection of Optimized Dosing Design of Hydroxychloroquine for the Treatment of Severe Acute Respiratory Syndrome Coronavirus 2 (SARS-CoV-2). *Clin Infect Dis* 2020;71(15):732–739. Doi: 10.1093/cid/ciaa237
- 9 China Law Translate. 2020 Novel Coronavirus Pneumonia Diagnosis and Treatment Plan (Provisional 7th Edition). [Internet]. Accessed in 2020 Mar 4 from: <https://www.chinalawtranslate.com/coronavirus-treatment-plan-7/>
- 10 National Health Surveillance Agency. (ANVISA) 2020 Clarifications on hydroxychloroquine and chloroquine. [Internet]. . Accessed in 2020 Mar 19 from: [http://portal.anvisa.gov.br/noticias/-/asset\\_publisher/FXrpx9qY7FbU/content/covid-19-esclarecimentos-sobre-hidroxicloroquina-e-cloroquina/219201](http://portal.anvisa.gov.br/noticias/-/asset_publisher/FXrpx9qY7FbU/content/covid-19-esclarecimentos-sobre-hidroxicloroquina-e-cloroquina/219201)
- 11 Ahn DG, Shin HJ, Kim MH, et al. Current Status of Epidemiology, Diagnosis, Therapeutics, and Vaccines for Novel Coronavirus Disease 2019 (COVID-19). *J Microbiol Biotechnol* 2020;30(03):313–324. Doi: 10.4014/jmb.2003.03011
- 12 Jin Y, Yang H, Ji W, et al. Virology, Epidemiology, Pathogenesis, and Control of COVID-19. *Viruses* 2020;12(04):E372. Doi: 10.3390/v12040372
- 13 Lacava AC. Complicações oculares da terapêutica com a cloroquina e derivados. *Arq Bras Oftalmol* 2010;73(04):384–389
- 14 Figueiredo MC, Atherino CCCT, Monteiro CV, Levy RA. Antimaláricos e Ototoxicidade. *Rev Bras Reumatol* 2004;44(03):212–214
- 15 Dwivedi GS, Mehra YN. Ototoxicity of chloroquine phosphate. A case report. *J Laryngol Otol* 1978;92(08):701–703. Doi: 10.1017/S0022215100085960
- 16 Fernandes MRN, Soares DBR, Thien CI, Carneiro S. Hydroxychloroquine ototoxicity in a patient with systemic lupus erythematosus. *An Bras Dermatol* 2018;93(03):469–470. Doi: 10.1590/abd1806-4841.20187615
- 17 Chatelet JN, Auffret M, Combret S, Bondon-Guitton E, Lambert M, Gautier S. [Hydroxychloroquine-induced hearing loss: First case of positive rechallenge and analysis of the French pharmacovigilance database]. *Rev Med Interne* 2017;38(05):340–343. Doi: 10.1016/j.revmed.2016.07.008
- 18 Khalili H, Dastan F, Dehghan Manshadi SA. A case report of hearing loss post use of hydroxychloroquine in a HIV-infected patient. *Daru* 2014;22(01):20
- 19 Jourde-Chiche N, Mancini J, Dagher N, et al. Antimalarial ototoxicity: an underdiagnosed complication? A study of spontaneous reports to the French Pharmacovigilance Network. *Ann Rheum Dis* 2012;71(09):1586. Doi: 10.1136/annrheumdis-2011-201265
- 20 Prince DS, Hardin JG. Hydroxychloroquine-induced vertigo. *JAMA* 1975;233(09):984
- 21 Gustafsson LL, Walker O, Alván G, et al. Disposition of chloroquine in man after single intravenous and oral doses. *Br J Clin Pharmacol* 1983;15(04):471–479. Doi: 10.1111/j.1365-2125.1983.tb01532.x
- 22 Bernard P. Alterations of auditory evoked potentials during the course of chloroquine treatment. *Acta Otolaryngol* 1985;99(3-4):387–392. Doi: 10.3109/00016488509108928
- 23 Seçkin U, Ozoran K, Ikinçiogullari A, Borman P, Bostan EE. Hydroxychloroquine ototoxicity in a patient with rheumatoid arthritis. *Rheumatol Int* 2000;19(05):203–204
- 24 Cox RM. Waiting for evidence-based practice for your hearing aid fittings? It's here!. *Hear J* 2004;57(08):10–17. Doi: 10.1097/01.HJ.0000292854.24590.8d