


Treatment of Pediatric Sternotomy Wound Complications: A Minimally Invasive Approach

Taehee Jo¹  Joon Hur² Eun Key Kim²

¹Department of Plastic and Reconstructive Surgery, Dongsan Medical Center, Keimyung University School of Medicine, Daegu, Republic of Korea

²Department of Plastic Surgery, Asan Medical Center, University of Ulsan College of Medicine, Seoul, Republic of Korea

Address for correspondence Eun Key Kim, MD, PhD, Department of Plastic Surgery, Asan Medical Center, University of Ulsan College of Medicine, 88, Olympic-ro 43-gil, Songpa-gu, Seoul 05505, South Korea (e-mail: nicekek@korea.com).

Thorac Cardiovasc Surg 2022;70:56–64.

Abstract

Background Pediatric sternal wound complications (SWCs) include sterile wound dehiscence (SWD) and superficial/deep sternal wound infections (SSWI/DSWI), and are generally managed by repetitive debridement and surgical wound approximation. Here, we report a novel nonsurgical management strategy of pediatric sternotomy wound complications, using serial noninvasive wound approximation technique combined with single-use negative pressure wound therapy (PICO) device.

Methods Nine children with SWCs were managed by serial approximation with adhesive skin tapes and serial PICO device application. Thorough surgical debridement or surgical approximations were not performed.

Results Three patients were clinically diagnosed as SWD, two patients as SSWI, and four patients as DSWI. None of the wounds demonstrated apparent mediastinitis or bone destructions. PICO device was applied at 16.1 days (range: 6–26 days) postoperatively, together with serial wound approximation by skin tapes. The average duration of PICO use was 16.9 days (range: 11–29 days) and the wound approximation was achieved in all patients. None of the patients underwent aggressive surgical debridement or invasive surgical approximation by sutures.

Conclusion We report our successful management of selected pediatric SWCs, using serial noninvasive wound approximation technique combined with PICO device.

Keywords

- ▶ wound healing
- ▶ wound infection
- ▶ surgery
- ▶ complications
- ▶ sternum

Introduction

Wound complications after cardiac surgery are significant contributors to mortality and morbidity. They also increase hospital stay and medical cost as well as the health care burden. Sternal wound complications (SWCs) after heart surgery are known to occur in ~0.5 to 5% of all patients, and are usually divided into sternal wound infection and sterile wound dehiscence (SWD).¹ Sternal wound infection can be categorized into deep sternal wound infection (DSWI) and superficial sternal wound infection (SSWI) according to the depth of invasion. The criteria for dividing those two may differ

slightly from literature to literature but the consensus is that SSWI is infection confined to the skin and subcutaneous tissue, while DSWI is infection below the fascial layer. Anatomically, DSWI might be further classified into DSWI type 2a for those that do not involve the bone and retrosternal tissue, type 2b for those that reach the retrosternal tissue, and types 2c and 2d when they involve the retrosternal tissue and bone, and in cases of frank osteitis.² A simpler classification divides sternal wound infections into SSWI for wounds confined to the skin and subcutaneous tissue and DSWI for wounds with muscle and bone involvement, mediastinitis, or infections associated with sternal osteomyelitis.³

received

October 14, 2020

accepted after revision

December 6, 2020

published online

February 4, 2021

© 2021, Thieme. All rights reserved.
Georg Thieme Verlag KG,
Rüdigerstraße 14,
70469 Stuttgart, Germany

DOI <https://doi.org/10.1055/s-0040-1722733>.
ISSN 1071-6425.

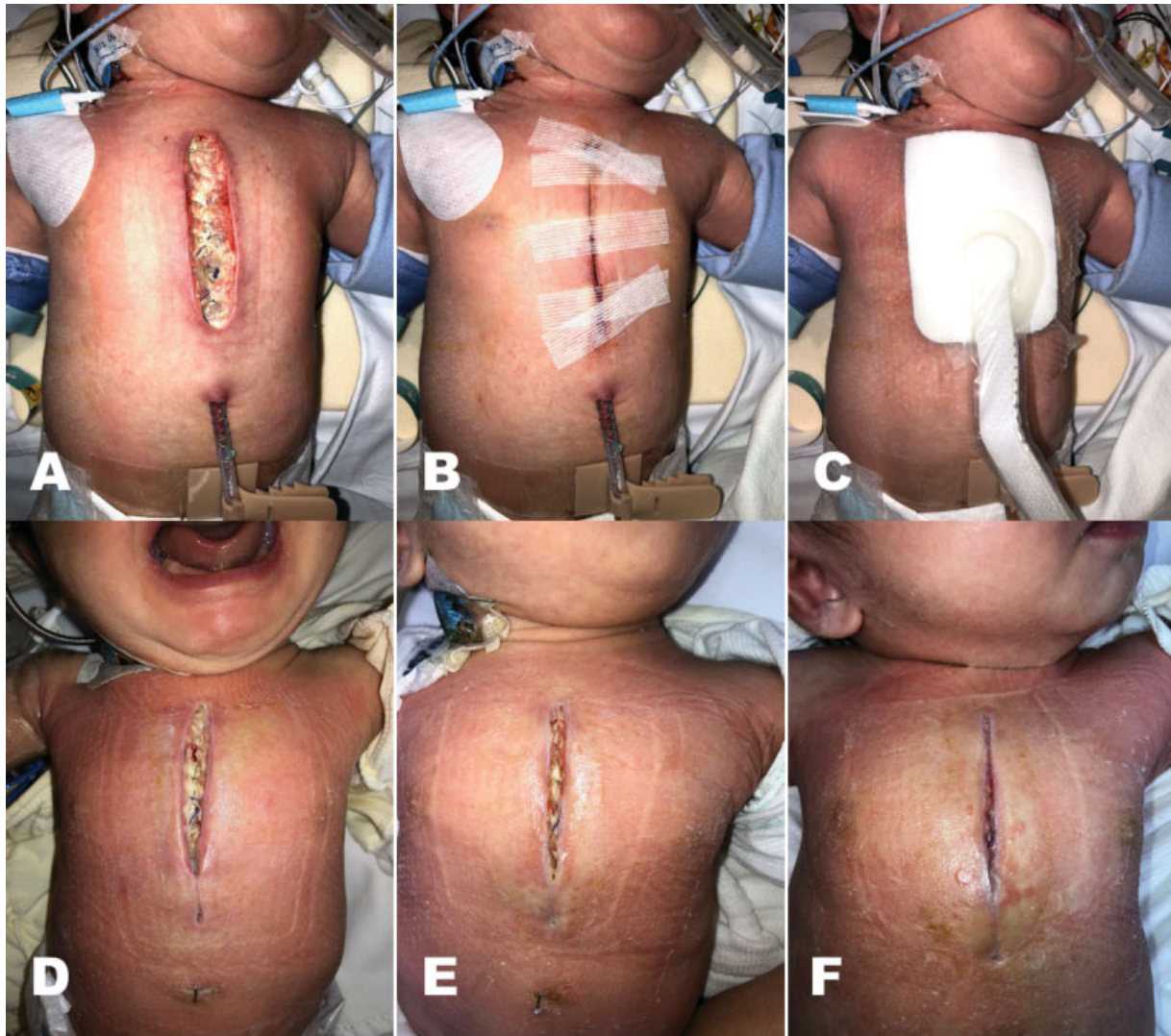

Fig. 1 Noninvasive and serial wound approximation of pediatric sternotomy wound dehiscence. (A) Minimal bed side debridement was performed for easy approximation. (B) Wound was approximated with adhesive skin tapes. (C) Single-use negative pressure device was applied on the approximated wound. (D–F) Seven, 14, and 21 days after first single-use negative pressure device application (patient no. 6).

Since 1997, when Argenta and Morykwas⁴ announced the usefulness of vacuum-assisted closure (VAC) in wound care, this innovative dressing has been widely used in a variety of acute and chronic wounds, including poststernotomy wounds. Agarwal et al,⁵ one of the earliest groups that introduced VAC as the first-line therapy for sternal wound management, applied it to SWD as well as SSWI and DSWI to emphasize the efficacy of VAC as both, sole and adjunctive therapies, in complex sternal wound management. Bakaeen et al⁶ demonstrated the safety and effectiveness of negative pressure wound therapy (NPWT) in noninfected open chest management with potential to improve outcomes. Phoon and Hwang² emphasized that NPWT plays an important role in the management of DSWI and mediastinitis.

The use of NPWT for sternal wound management in children started later, but several reports have since followed. Salazard et al⁷ reported that VAC showed rapid response, with local purulence and C-reactive protein

(CRP) both decreasing within 72 hours in children with severe mediastinitis after delayed sternal closure. Padalino et al⁸ showed the effectiveness and safety of VAC in early or late poststernotomy wound complications in newborns and infants. Hardwicke et al⁹ revealed that NPWT did not only improve the local wound but also significantly improved the systemic physiological parameters in neonates.

We report a retrospective case series with single-use NPWT (PICO, Smith & Nephew Healthcare, Watford, UK) for sternotomy wound complications, which includes SWD, SSWI, and superficial (types 2a and 2b) DSWI without apparent mediastinitis or bone destruction. In particular, we attempted to manage these complications with the early serial, noninvasive wound approximation approach, without applying thorough surgical debridement. We aimed to discuss the clinical as well as the aesthetic benefits of this approach with a focus on proper patient selection and the technical principle.

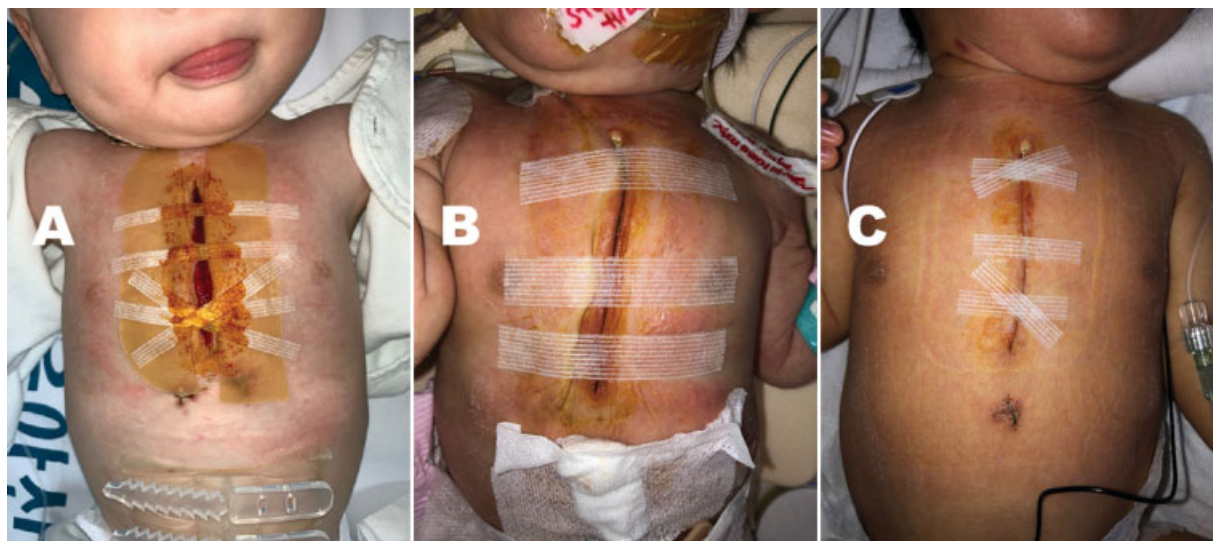


Fig. 2 Skin approximation technique in noninvasive pediatric sternalotomy wound management. Small gaps were left open even though the margins could easily be fully approximated. Therefore, the negative pressures were effectively applied to the wound bed and minimal bed side debridement could be performed in the following single-use negative pressure device change. (A–C) Initial approximation in patient nos. 1, 5, and 7.

Methods

This study was approved by the Institutional Review Board of the hospital (2019-1246). Nine children with SWC who were referred to the plastic surgery department between August 2018 and November 2019 for wound management were retrospectively enrolled. Pediatric sternalotomy complications—including SWD, SSWI, and superficial (types 2a and 2b) DSWI—were managed with minimally invasive and serial approximation technique with PICO device application.

Before starting the treatment, frank abscess or complicated fluid collection was drained under sedation at bedside. Since all patients showed grossly intact sternum with no signs of retrosternal abscess or systemic infection, no attempt was made to surgically approach the retrosternal space. Noticeable demarcated debris or easily separable sloughs were removed with a gauze, curette, and small scissors. We did not aim for complete debridement to reach very fresh bleeding tissues, but rather tried to debride conservatively as possible only to reach a point that remaining necrotic tissue does not interfere with PICO device. When the skin was particularly weak, hydrocolloid dressing (DuoDERM, ConvaTec, Deeside, UK) was attached to both sides of the wound margin. Wound margins were manually approximated from both lateral sides and fixed with adhesive skin tapes (Steri-Strips™, 3M, Minnesota, United States) without excessive tension. During the period when necrotic tissues or sloughs remained in the bed, margins were intentionally approximated with a little gap left open, on which PICO was applied, so that remaining necrosis could be removed in subsequent PICO changes (►Fig. 1). The dressing was changed every 3 to 5 days, and the demarcated necrotic tissue was removed in the same way and further approximated; however, the gap between the margins or skin tapes was maintained even if the margins could easily be approximated, so that negative pressure

could be effectively applied to the wound bed (►Fig. 2). When all the necrotic tissues disappeared, secure taping was performed, and when the margin approximation was almost completed, PICO was replaced with the usual foam dressing.

Due to the descriptive nature of the study, no statistical analysis was performed.

Results

All patients included in the review underwent median sternotomy to correct congenital anomalies, including transposition of great arteries (TGA) and double outlet left ventricle. The patients had a mean age of 38 days (range: 2–184) at the time of operation. We have summarized patients' demographics, diagnoses, and operations in ►Table 1.

The average time interval between the primary sternotomy and the clinical manifestations of SWC was 9 days (range: 3–18). Three patients were clinically diagnosed as SWD, two as SSWI, and four developed DSWI type 2a or 2b. Five of our patients had a positive growth in wound culture, methicillin-resistant *Staphylococcus epidermidis* in four patients and methicillin-resistant *Staphylococcus aureus* in one patient. CRP level at the time of development of the SWC ranged between 9.8 and 84.9 with a mean of 43.2 mg/L (►Table 2). No patient presented with signs of significant systemic infection or bacteremia.

Therapeutic antibiotics administration was started, and the wound was debrided conservatively at the bedside on the day of clinical diagnosis of SWC, just to get rid of prominent necrotic slough. Four patients had a history of conventional VAC therapy applied by cardiothoracic surgeons before plastic surgery consultation. PICO device was applied by plastic surgeons at 6 to 30 days postoperatively, with a mean of 17.2 days. The average CRP level at the time of PICO application was 14.5 mg/L (range: 3.0–32.5).

Table 1 Patients' demographics, diagnosis, and operation

Patient no.	Gestational age and birth weight	Gender	Age and weight at the time of operation	Diagnosis	Operation	Associated anomalies
1	39 + 0 wk, 3,150 g	F	184 d, 5.68 kg	DORV, Taussig–Bing anomaly, s/p PAB, h/o MRSA infection	Rastelli operation	–
2	40 + 0 wk, 3,070 g	M	14 d, 3.31 kg	d-TGA with IVS	ASO (jatene operation), ASD direct closure, PDA division, delayed sternal closure at POD 1	–
3	40 + 1 wk, 3,580 g	F	15 d, 3.46 kg	Fallot type DORV	PAB, PDA ligation	–
4	39 + 4 wk, 2,890 g	F	37 d, 3.50 kg	FSV (TGA, DILV, AVSD), cardiac TAPVR, PS, MAPCA	Central shunt, delayed closure at POD 3	Rt. isomerism asplenia
5	38 + 0 wk, 3,440 g	F	20 d, 3.25 kg	TGA with IVS, ASD, PDA	ASO (jatene operation), ASD direct closure, PDA division	r/o VACTERAL, esophageal atresia with TEF
6	39 + 4 wk, 3,630 g	F	8 d, 3.76 kg	TGA with IVS, ASD, PDA	ASO (jatene operation), ASD direct closure, PDA division	–
7	39 + 2 wk, 4,225 g	M	57 d, 4.63 kg	HLHS (AA, MA) s/p bilateral PAB	Norwood operation, delayed sternal closure at POD 2	Rubinstein–Taybi's syndrome
8	38 + 4 wk, 3,310 g	F	6 d, 3.13 kg	d-TGA with IVS, ASD secundum	ASO (jatene operation), ASD direct closure, PDA division	–
9	39 + 2 wk, 2,980 g	M	2 d, 3.08 kg	d-TGA with IVS	ASO (jatene operation), delayed sternal closure at POD 4	–

Abbreviations: AA, aortic atresia; ASD, atrial septal defect; ASO, arterial switch operation; AVSD, atrioventricular septal defect; DILV, double inlet left ventricle; DORV, double outlet right ventricle; d-TGA, dextro-transposition of great arteries; FSV, functional single ventricle; HLHS, hypoplastic left heart syndrome; IVS, interventricular septum; MA, mitral atresia; MAPCA, major aortopulmonary collateral artery; PAB, pulmonary artery banding; PDA, patent ductus arteriosus; POD, postoperative day; PS, pulmonary valve stenosis; TAPVR, total anomalous pulmonary venous return; TEF, tracheoesophageal fistula.

Table 2 Wound details and clinical diagnosis

Patient no.	Development of SWC	Clinical presentation	Microorganism	Image study	CRP (development of SWC, start of NPWT), mg/L	Clinical diagnosis
1	POD 8	Swelling, discharge	MRSA	Chest wall abscess, extension to anterior mediastinum	32.1 (POD 8) 4.0 (POD 26)	DSWI 2b
2	POD 3	Dehiscence, discharge	MRSE	Complicated fluid collection, mainly in the chest wall	59.0 (POD 3) 5.9 (POD 12)	SSWI
3	POD 6	Discharge, dehiscence	MRSE	Soft tissue infection, r/o extension to anterior mediastinum, bone involvement cannot be excluded	26.1 (POD 6) 15.8 (POD 8)	DSWI type 2b
4	POD 10	Swelling, pus	N/G	Heterogeneous attenuation at sternal op site, suggesting anterior mediastinitis	56.2 (POD 10) 24.1 (POD 20)	DSWI type 2a or 2b
5	POD 5	Dehiscence	MRSE	No evidence of complicated fluid collection in mediastinum	84.9 (POD 5) 32.5 (POD 11)	SSWI
6	POD 4	Discharge, dehiscence	N/G	N/A	44.5 (POD 4) 32.4 (POD 6)	SWD
7	POD 18	Prolonged discharge	MRSE	Complicated fluid collection in anterior mediastinum, beneath the sternum	52.7 (POD 18) 5.6 (POD 22)	DSWI type 2b
8	POD 10	Dehiscence, discharge	N/G	N/A	23.4 (POD 10) 3.0 (POD 22)	SWD
9	POD 17	Dehiscence, pus	N/G	Heterogeneous attenuation at sternal op site, anterior mediastinitis cannot be ruled out	9.8 (POD 17) 7.4 (POD 18)	SWD

Abbreviations: CRP, C-reactive protein; DSWI, deep sternal wound infection; MRSA, methicillin-resistant *Staphylococcus aureus*; MRSE, methicillin-resistant *Staphylococcus epidermidis*; N/A, not available; N/G, no growth; POD, postoperative day; SSWI, superficial sternal wound infection; SWC, sternal wound complications; SWD, sterile wound dehiscence.

Table 3 Wound management and outcomes

Patient no.	Therapeutic antibiotics	Intervention	Start of VAC	Start of PICO	End of PICO	PICO duration	ICU dismissal	Discharge	Hospital stay
1	VAN (POD 3–38)	I&D, POD 9	POD 9	POD 26	POD 37	11 d	POD 13	POD 42	44 d
2	VAN (POD 3–43) TZP (POD 17–20)	Wound open, POD 3	POD 5	POD 12	POD 33	21 d	POD 30	POD 48	62 d
3	VAN (POD 6–36) RFP (POD 16–29) Linezolid (POD 36–49)	Wound open, POD 6	–	POD 8	POD 22	14 d	POD 11	POD 44	60 d
4	VAN (POD 1–56) TZP (POD 9–16) Nafcillin (POD 19–56)	I&D, POD 10	POD 10	POD 20	POD 40	20 d	POD 15	POD 59	70 d
5	VAN (POD 0–53) TZP (POD 3–14) MEM (POD 15–53)	–	–	POD 11	POD 40	29 d	POD 14	POD 54	74 d
6	VAN (POD 4–21) CPDX-PR (POD 22–29)	–	–	POD 6	POD 26	20 d	POD 9	POD 29	37 d
7	VAN (POD 2–45) CFT (POD 2–21) RFP (POD 22–45)	Wound open, POD 18	–	POD 22	POD 34	12 d	POD 11	POD 46	73 d
8	VAN (POD 1–42) TZP (POD 1–4)	Wound open, POD 10	POD 10	POD 22	POD 35	13 d	POD 17	POD 45	51 d
9	VAN (POD 2–57) TZP (POD 2–11) CTX (POD 12–33)	–	–	POD 18	POD 30	12 d	POD 9	POD 56	58 d

Abbreviations: CFT, ceftazidime; CPDX-PR, cefpodoxime proxetil; CTX, cefotaxime; ICU, intensive care unit; I&D, incision and debridement; MEM, meropenem; POD, postoperative day; RFP, rifampicin; TZP, piperacillin/tazobactam; VAC, vacuum-assisted closure; VAN, vancomycin.

The average duration of PICO use was 16.9 days (range: 11–29), and the average hospital stay was 58.8 days. The details of wound management and outcomes for each patient are summarized in **Table 3**. No patient underwent any invasive surgical procedures except for the initial wound opening, or incision and drainage at the time of SCW diagnosis. Wound approximation was achieved without invasive suturing, and the remaining small gap was managed with the usual foam dressing to allow complete epithelization and wound maturation (**Figs. 3 and 4**).

Discussion

The benefits of NPWT in wound management are well documented. It includes improved perfusion, stimulation of angiogenesis, promotion of granulation tissue growth, and removal of excess interstitial fluids. It is also postulated that NPWT increases mitotic activity and removes inhibitory molecules.^{7,10} NPWT in poststernotomy wounds particularly removes excess fluids and tissue debris continuously and helps sternal stabilization, and thus, many authors have recommended NPWT either as a destination or bridge to the final closure for difficult wounds.^{2,10}

This noninvasive therapeutic aid is particularly beneficial to pediatric patients with decreased number of dressing changes. With a closed controlled wound environment,

nursing would be easier with less worry of causing discomfort.⁹ Ramnarine et al¹¹ claimed that NPWT led to immediate and dramatic local improvement, holistic clinical improvement, and better chest wall mechanics in a neonatal patient with poststernotomy wound dehiscence. Although it usually leads an uneventful course, application of NPWT in pediatric patients necessitates special considerations.¹² The first concern is that the threshold value for causing circulatory instability may be exceptionally lower in small patients, so that NPWT might cause exsanguination and rupture of fragile vital organs. Therefore, a lower negative pressure (–25 to –75 mm Hg) is usually recommended in these patients.^{12,13} The other issue is the small dimension of the wound in infants. To overcome, Patalino et al⁸ suggested a modification called “two-layer technique” and prevented the damage of surrounding tissues by correct positioning of the connecting tube.

The single-use NPWT system without canister (PICO) has had revolutionary impact on the management of various acute, chronic, and surgical wounds. It is easily used in the outpatient setting with increased mobility while keeping most of the benefits of conventional NPWT, and additionally has a possible advantage in cost management.^{14,15} PICO delivers a continuous negative pressure of –70 mm Hg which is within the evidence-based therapeutic range and such pressure range might be safer for pediatric SWC applications.

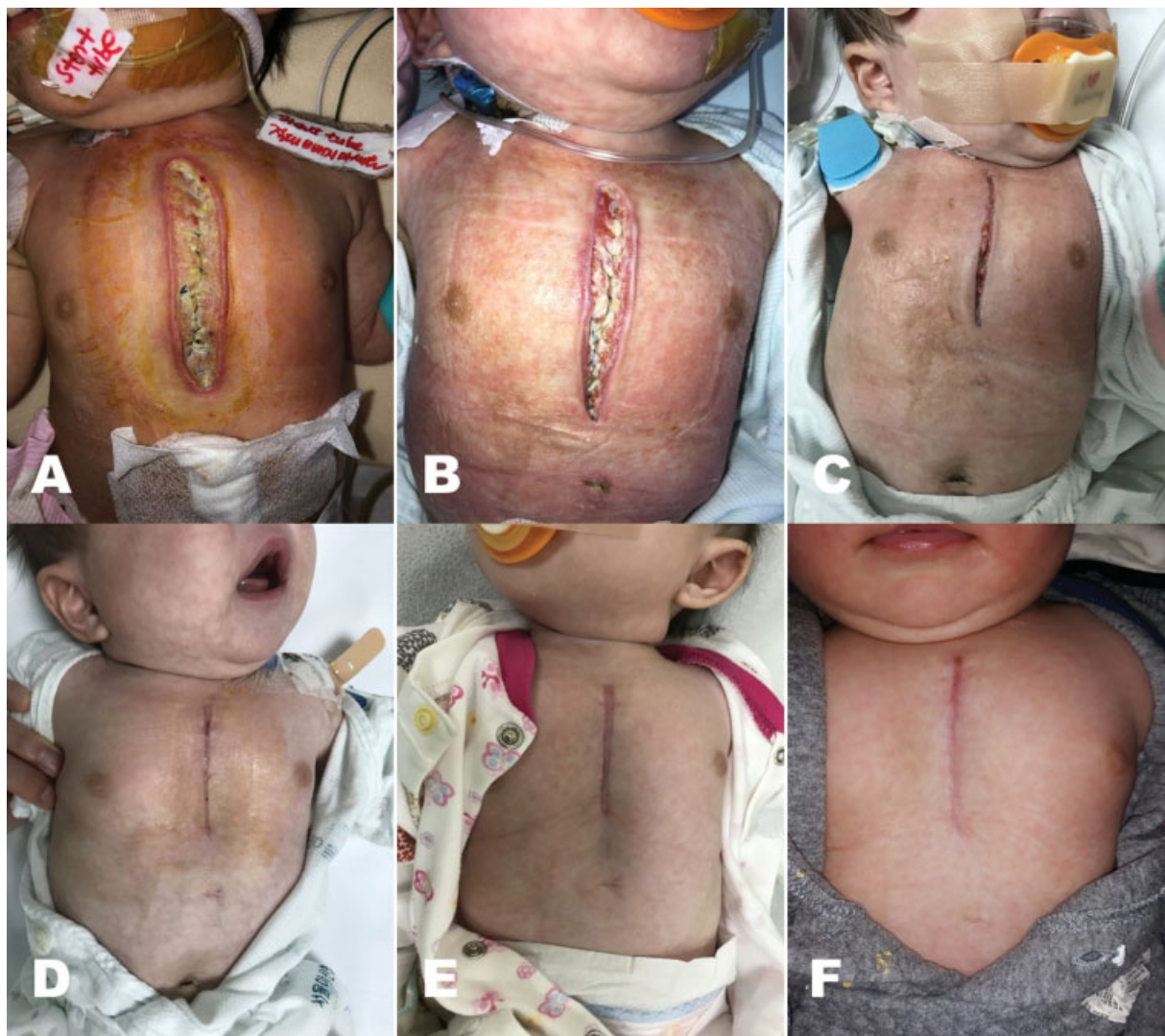

Fig. 3 Noninvasive and serial wound approximation of pediatric sternotomy wound dehisence. Representative case of patient no. 5. (A) Initial wound presentation on postoperative day 11, first day of wound approximation and negative pressure device application; (B) 11 days after treatment; (C) 20 days after treatment; (D) 41 days after treatment, the day of hospital discharge; (E) 2 months after treatment, at the outpatient clinic; and (F) 5 months follow-up.

The inner silicone wound contact layer does not lead to ingrowth of the granulation tissue into the dressing, which alleviates the pain and discomfort during dressing changes, and therefore is another specific benefit in the pediatric population. Its connecting tube is integrated on the top surface of the dressing without any particular pressure area so that no specific effort is required for proper tube placement.

This study was not the first attempt to manage pediatric SWC using PICO. Boyar,¹⁶ in advance, reported their experience with the use of a single-use negative pressure wound device (PICO) combined with the use of medical-grade honey in 11 neonates who had poststernotomy wound dehisence that were infected or colonized. However, our approach is somewhat different, in that we did not rely on secondary intention for complete wound healing. The main difference of our approach is that complete wound healing in our series was not solely dependent on secondary intention.

One of the main benefits of NPWT is that it is considered to stimulate the formation of healthy granulation tissue.^{8,9,13} The role of NPWT in SWC management is often defined as either a sole treatment or a bridge between debridement and definitive closure.⁵ Definitive closure after cessation of NPWT as a bridge treatment usually requires surgical closure, or sometimes skin grafting.^{7,8,12} When used as a sole treatment, wounds are generally allowed to heal secondarily with granulation and epithelization.^{5,16} The delayed closure approach or secondary healings most often leads to excessive scar tissue formation, which are hard to manage especially when the scar is located at the sternal area. To prevent these shortcomings, we chose to serially advance the wound edges and induce relatively uneventful wound healing. Sometimes, we observed that the sponge fillings of NPWT mechanically inhibited the actual reduction of the wound size, so that wound edge failed to advance for closure. If such phenomenon were observed, we elevated and everted the wound

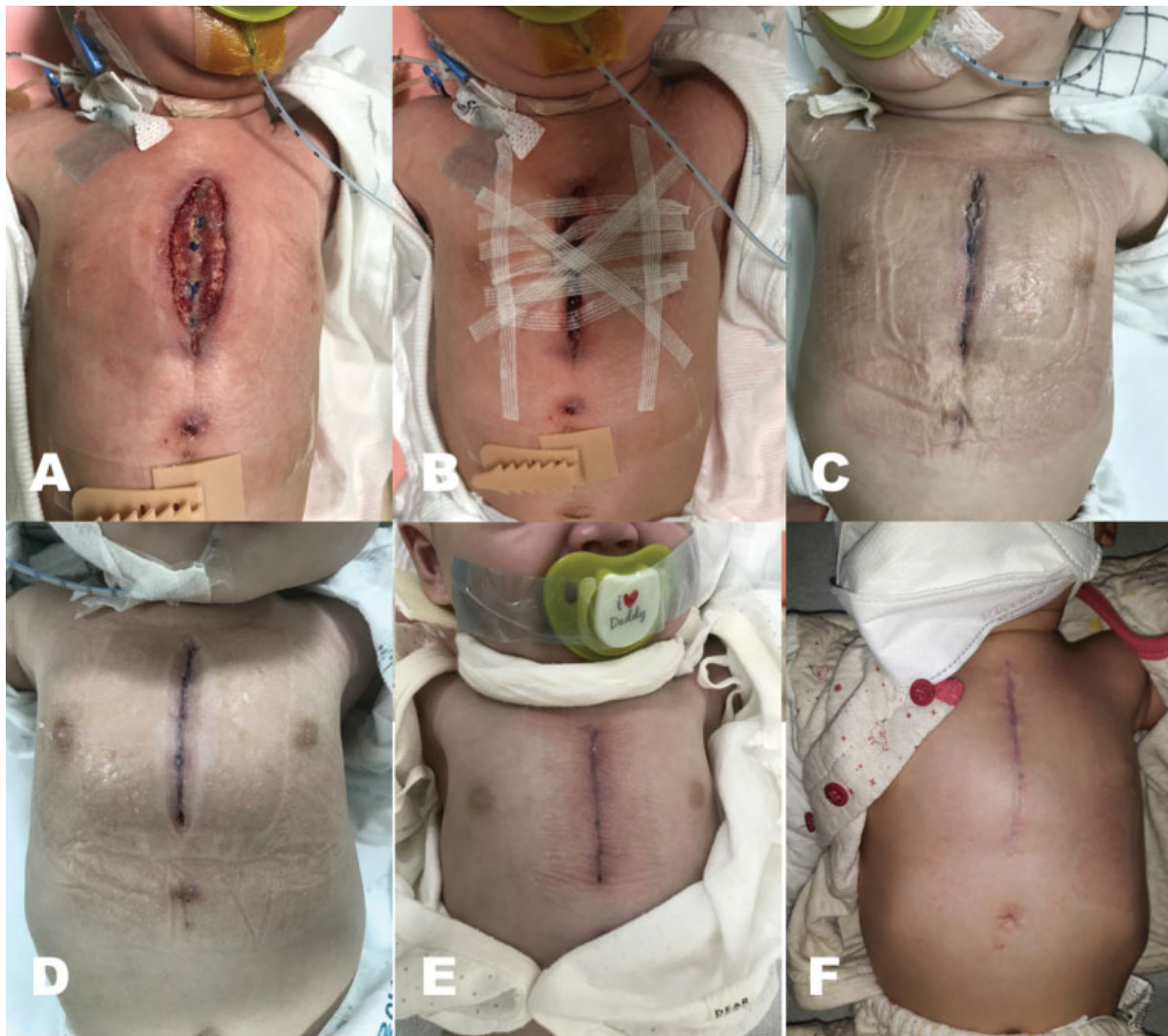

Fig. 4 Noninvasive and serial wound approximation of pediatric sternotomy wound dehiscence. Representative case of patient no. 4. (A) This patient was treated with conventional vacuum-assisted closure for 10 days before referral to the plastic surgeon. Wound margins were widely separated, although healthy granulation tissue was formed in the wound bed. (B) Wound margins were elevated and everted from the wound bed under mild sedation and local anesthesia, and then serial approximation was started; (C) 14 days after treatment; (D) 20 days after treatment, the last day of negative pressure wound therapy; (E) 30 days after treatment; (F) 5 months follow-up.

margins from the wound bed using a Freer elevator, and then resumed the serial approximation. DeFazio et al¹⁷ also witnessed this problem and combined bridging retention sutures with NPWT to achieve progressive tissue retraction over time and guide dermal approximation while minimizing the volume of sponge required to fill the three-dimensional cavity. Although the technical details are different, our concept is similar in that we also simultaneously pursue wound decontamination, reduction of dead space, and marginal apposition. Judicious use of the early serial approximation technique can yield superior aesthetic results than secondary intention healing. In particular, it excludes the necessity of surgical procedures for definitive closure in many SWD, SSWIs, and selected “superficial” DSWIs in pediatric SWC patients. It would be the best to start at the early resilient wound period for maximum benefit, when adhesion and wound contracture have not yet been estab-

lished. Acute resilient wounds in pediatric patients usually allowed gradual approximation by only skin taping even if there was some inflammation and edema.

Debridement is generally known to have paramount importance in managing SWC.⁵ This is true in wounds with apparent and significant infection.⁷ Boyar claimed that debridement is an essential pillar of the “DIME” (Debridement or devitalized tissue, Inflammation or infection, Moisture balance, and Edge preparation) conceptual framework and debrided the wound by surgical, mechanical, or enzymatic methods before treatment commencement.¹⁶ Our principle for wound debridement was rather liberal than these concepts in that we only chose to serially remove fully demarcated debris and readily separable necrotic tissue with gauze, curette, or small scissors every time we exchanged PICO. The sloughs that were not easily removed were left on the wound for subsequent debridement, but we always had

taken into consideration that remaining unhealthy tissues might cause problematic infection under PICO device. Therefore, we always left a small gap between the margins when even minimal necrotic tissues were present, so that we could effectively apply negative pressure dressing to the wound bed. As a result, none of serious local infection signs was observed across the patients. We assume that the infection did not overwhelm and healing went on without massive debridement because NPWT maintained the moist environment and removed discharge and debris, which resultingly helped autolytic debridement and cleansing process of the wound bed. This was possible because our SWC case series was only applied to patients with SWD or relatively superficial infection (or colonization) without apparent osteomyelitis or retrosternal involvement. If there were signs of systemic infection with high CRP level, the cardiac surgeons first managed the patient using conventional NPWT after incision and drainage, and then consulted the plastic surgeons after the systemic and significant infection was resolved to some extent. We believe that thorough removal of all necrotic tissue and slough before treatment commencement is not a requirement in selected SWC patients. However, any foreign body or demarcated necrotic tissue that may continue to be a source of infection should be removed. Eschar, if present, should be removed too, but this is not a common finding in typical dehiscence SWCs in children.

Limitations of our study include (1) description on wound size reduction and clinical improvement was subjective, (2) control group was absent so that impact on wound healing rate, final aesthetic outcome, hospital stay, and total cost could not be objectively compared with other methods, and (3) longer overall treatment time might be required for this approach than for conventional ones.

Conclusion

We have shown that, in selected pediatric SWC patients with intact sternum, wounds can be successfully managed through early serial approximation by skin taping and conservative, noninvasive debridement with the help of PICO device. This approach could offer a comfortable treatment environment while achieving good clinical and aesthetic results, and avoid invasive surgical sessions. However, proper patient selection is crucial because this approach is not appropriate when there is an obvious destruction of the sternum, a complicated fluid collection in deep tissues, or significant retrosternal involvement. Conventional VAC is still recommended as a first-line treatment for initial wounds with significant infection and necrosis. In addition, our approach is difficult to apply in case of established wound contraction or chronic wounds with tissue hardening.

Financial Disclosure

None of the authors has a financial interest in any of the products, devices, or drugs mentioned in this manuscript.

Conflict of Interest

None declared.

Acknowledgment

We thank professor Chun Soo Park, Department of Pediatric Cardiac Surgery, Asan Medical Center, University of Ulsan College of Medicine, for his professional advice.

References

- 1 Fu RH, Weinstein AL, Chang MM, Argenziano M, Ascherman JA, Rohde CH. Risk factors of infected sternal wounds versus sterile wound dehiscence. *J Surg Res* 2016;200(01):400–407
- 2 Phoon PHY, Hwang NC. Deep sternal wound infection: diagnosis, treatment and prevention. *J Cardiothorac Vasc Anesth* 2020;34(06):1602–1613
- 3 Salehi Omran A, Karimi A, Ahmadi SH, et al. Superficial and deep sternal wound infection after more than 9000 coronary artery bypass graft (CABG): incidence, risk factors and mortality. *BMC Infect Dis* 2007;7:112
- 4 Argenta LC, Morykwas MJ. Vacuum-assisted closure: a new method for wound control and treatment: clinical experience. *Ann Plast Surg* 1997;38(06):563–576, discussion 577
- 5 Agarwal JP, Ogilvie M, Wu LC, et al. Vacuum-assisted closure for sternal wounds: a first-line therapeutic management approach. *Plast Reconstr Surg* 2005;116(04):1035–1040, discussion 1041–1043
- 6 Bakaeen FG, Haddad O, Ibrahim M, et al. Advances in managing the noninfected open chest after cardiac surgery: negative-pressure wound therapy. *J Thorac Cardiovasc Surg* 2019;157(05):1891–1903.e9
- 7 Salazard B, Niddam J, Ghez O, Metras D, Magalon G. Vacuum-assisted closure in the treatment of poststernotomy mediastinitis in the paediatric patient. *J Plast Reconstr Aesthet Surg* 2008;61(03):302–305
- 8 Padalino MA, Carrozzini M, Vida V, Stellin G. Vacuum-assisted closure therapy for the treatment of poststernotomy wound dehiscence in neonates and infants. *Thorac Cardiovasc Surg* 2019;67(01):55–57
- 9 Hardwicke J, Richards H, Jagadeesan J, Jones T, Lester R. Topical negative pressure for the treatment of neonatal post-sternotomy wound dehiscence. *Ann R Coll Surg Engl* 2012;94(01):e33–e35
- 10 Sjögren J, Malmström M, Gustafsson R, Ingemansson R. Poststernotomy mediastinitis: a review of conventional surgical treatments, vacuum-assisted closure therapy and presentation of the Lund University Hospital mediastinitis algorithm. *Eur J Cardiothorac Surg* 2006;30(06):898–905
- 11 Ramnarine IR, McLean A, Pollock JC. Vacuum-assisted closure in the paediatric patient with post-cardiotomy mediastinitis. *Eur J Cardiothorac Surg* 2002;22(06):1029–1031
- 12 Sherman G, Shulman-Manor O, Dagan O, et al. Vacuum-assisted closure for the treatment of deep sternal wound infection after pediatric cardiac surgery. *Pediatr Crit Care Med* 2020;21(02):150–155
- 13 Kawajiri H, Aeba R, Takaki H, Yozu R, Iwata S. Negative pressure therapy for post-sternotomy wound infections in young children. *Interact Cardiovasc Thorac Surg* 2014;19(01):102–106
- 14 Payne C, Edwards D. Application of the single use negative pressure wound therapy device (PICO) on a heterogeneous group of surgical and traumatic wounds. *Eplasty* 2014;14:e20
- 15 Hudson DA, Adams KG, Van Huyssteen A, Martin R, Huddleston EM. Simplified negative pressure wound therapy: clinical evaluation of an ultraportable, no-canister system. *Int Wound J* 2015;12(02):195–201
- 16 Boyar V. Treatment of dehiscence, thoracic neonatal wounds with single-use negative pressure wound therapy device and medical-grade honey: a retrospective case series. *J Wound Ostomy Continence Nurs* 2018;45(02):117–122
- 17 DeFazio MV, Economides JM, Anghel EL, Mathis RK, Barbour JR, Attinger CE. Traction-assisted internal negative pressure wound therapy with bridging retention sutures to facilitate staged closure of high-risk wounds under tension. *Wounds* 2017;29(10):289–296