

Percutaneous debridement and washout of walled-off abdominal abscess and necrosis using flexible endoscopy: a large single-center experience

Authors

Bradley Mathers, Matthew Moyer, Abraham Mathew, Charles Dye, John Levenick, Niraj Gusani, Brandy Dougherty-Hamod, Thomas McGarrity

Institution

Penn State Hershey Medical Center, Hershey, PA.

Bibliography

DOI <http://dx.doi.org/10.1055/s-0041-107802>
 Published online: 27.11.2015
 Endoscopy International Open 2016; 04: E102–E106
 © Georg Thieme Verlag KG
 Stuttgart · New York
 E-ISSN 2196-9736

Corresponding author:

Bradley W. Mathers, MD
 Department of Internal
 Medicine
 Penn State Hershey Medical
 Center
 500 University Drive
 Hershey, PA 17033
 Phone: +1-717-531-8521
 Fax: +1-717-531-6770
 bmathers@hmc.psu.edu

Background and study aims: Direct percutaneous endoscopic necrosectomy has been described as a minimally invasive intervention for the debridement of walled-off pancreatic necrosis (WOPN). In this retrospective cohort study, we aimed to confirm these findings in a US referral center and evaluate the clinical value of this modality in the treatment of pancreatic necrosis as well as other types of intra-abdominal fluid collections and necrosis.

Patients and methods: Twelve consecutive patients with WOPN or other abdominal abscess requiring debridement and washout underwent computed tomography (CT)-guided drainage catheter placement. Each patient then underwent direct percutaneous endoscopic necrosectomy and washout with repeat debridement performed until complete. Drains were then removed once output fell below 30mL/day and imaging confirmed resolution. The primary endpoints were time to clinical resolution and sustained resolution at 1-year follow up.

Results: Ten patients were treated for WOPN, one for necrotic hepatic abscesses, and one for omental necrosis. The median time to intervention was 85 days with an average of 2.3 necrosectomies performed. Complete removal of drains was accomplished in 11 patients (92%). The median time to resolution was 57 days. No serious adverse events occurred; however, one patient developed pancreaticocutaneous fistulas. Ten patients completed 1-year surveillance of which none required drain replacement. No patients required surgery or repeat endoscopy.

Conclusions: This series supports the premise that direct percutaneous endoscopic necrosectomy is a safe and effective intervention for intra-abdominal fluid collections and necrosis in appropriately selected patients. Our study demonstrates a high clinical success rate with minimal adverse events. This modality offers several potential advantages over surgical and transgastric approaches including use of improved accessibility, an excellent safety profile, and requirement for only deep or moderate sedation.

Introduction

Acute pancreatitis is one of the most common medical conditions encountered by medical professionals worldwide. While most cases resolve without sequelae, between 10% and 20% of patients will develop more serious adverse events such as pancreatic necrosis, with an increased rate of morbidity and mortality [1]. Furthermore, approximately 30% of patients with necrotizing pancreatitis will develop a secondary infection in the weeks following, usually 3 to 4 weeks after the onset of necrosis [2]. If left untreated, infected pancreatic necrosis has a markedly elevated mortality rate; however, aggressive supportive care and intervention significantly improves outcomes [3,4]. Ideally, therapeutic intervention is delayed

to allow maturation of the collection to form walled-off pancreatic necrosis (WOPN).

The optimal interventional modality for the treatment of WOPN remains controversial. Historically, surgical necrosectomy was performed; however with adverse event rates of 40% to 70% and mortality rates as high as 56% reported, this procedure possess its own toxicity and is typically approached with trepidation [5,6]. The PANTER study demonstrated that a step-up approach, starting with CT-guided percutaneous drain placement was superior to up-front open surgical necrosectomy, thus demonstrating the value of a minimally invasive approach for this condition [7]. However, many of these patients eventually still required surgical necrosectomy. More recently, direct transgastric endoscopic necrosectomy involving endoscopic ultrasound (EUS)-guided,

License terms



Table 1 Published case series involving direct percutaneous endoscopic necrosectomy.

Study	Participants	Time to intervention (mean)	Number of necrosectomies (mean)	Average hospital stay (median)	Adverse events	Resolution
Dhingra et al	15	39.2 days	5	54 days	Fistula, bleeding	93 %
Mui et al	13	n/a	3	84 days	Fistula	67 %

transluminal drainage and debridement has been shown to be an effective treatment for WOPN with an improved safety profile [8–10]. However, this approach can be complex and is limited to necrosis abutting the stomach or duodenum.

Direct percutaneous endoscopic necrosectomy was first described in 2000 as a novel minimally invasive intervention for debridement and washout of WOPN with two series more recently reported in China and India (Table 1) as well as several case reports [11–16]. This novel interventional endoscopy approach utilizes a percutaneous access tract previously placed by interventional radiology methods to directly access the abscess or necrosis for debridement and washout using flexible endoscopy. This allows the patient to avoid major surgery and typically requires only moderate sedation. Furthermore, direct percutaneous endoscopic necrosectomy could possibly be used for various types of intra-abdominal fluid collections, regardless of anatomic location, provided that it can be first accessed by interventional radiology techniques. A recent clinical series from India illustrated the efficacy and safety of direct percutaneous endoscopic necrosectomy in the treatment of infected WOPN [12]. In this study, we intend to confirm these results in a US referral center and further evaluate the clinical value of direct percutaneous endoscopic necrosectomy in the treatment of other types of intra-abdominal fluid collections and necrosis.

Patients and methods

In this retrospective cohort study, 12 consecutive patients undergoing direct percutaneous endoscopic necrosectomy over the period of 2007 to 2014 were identified. All patients had previously undergone CT-guided percutaneous drain placement without resolution of their symptoms due to the presence of solid necrosis and/or loculations. Time to intervention was defined as the number of days between the onset of symptoms and the first percutaneous endoscopic necrosectomy. The primary endpoint was complete removal of all percutaneous drains without recurrence of clinical symptoms. Time to resolution was defined as the number of days between the first endoscopic intervention and the date in which all drains were removed.

Endoscopic Technique

Prior to endoscopy, all patients had their percutaneous drains upsized to 24- to 28-F diameter to accommodate the endoscope through the body wall access point (Fig. 1 a). Once accessed, a fluid sample was collected and sent for amylase level and cytology. The patients were then placed under either moderate sedation with fentanyl and midazolam or general anesthesia if clinically warranted. The percutaneous drain(s) was then removed and standard 8.8-mm upper endoscope (GIF-Q180; Olympus Inc., Center Valley, PA) was introduced through the established tract into the necrotic cavity (Fig. 1 b and Fig. 1 c). The cavity was visualized (Fig. 1 d), lavaged with normal saline, and necrotic debris then removed using blunt removal and washout. A

standard polypectomy snare was typically used through the scope to mobilize and remove solid debris (Fig. 1 e). Large necrotic pieces were sequentially removed over the course of the procedure, and once debridement was satisfactory, the endoscope removed and the percutaneous drain replaced over a guidewire. If needed, repeat percutaneous debridement would occur within a few days until all necrotic material was removed (Fig. 1 f). Drain output was monitored and drains were downsized and then removed once output fell below 30 mL per day and cross-sectional imaging confirmed resolution (Fig. 1 g). Patients were subsequently followed in clinic over the course of 1 year to monitor for recurrence of signs or symptoms and need for further intervention.

Results

A total of 12 patients underwent direct percutaneous endoscopic necrosectomy over the study time period (Table 2). The majority of patients (75%) were female with an average age of 51. Ten patients (83%) had been diagnosed with WOPN, one (8%) with omental necrosis after resection of a gastrointestinal stromal tumor, and one (8%) with bilateral, necrotic, loculated hepatic abscesses. Six patients (50%) presented with manifestations of marked disease severity including sepsis and multiorgan failure. The median time from onset of symptoms until the first necrosectomy was 85 days (range 21–248) (Table 3). The mean number of necrosectomies performed was 2.3.

Complete removal of percutaneous drains was accomplished in 11 patients (92%). The one patient in whom the drains were not removed died 3 months after her last pancreatic endocrine neoplasm (PEN) from metastatic colon cancer. The median time from the initial PEN to complete removal of drains was 57 days. No adverse events were observed in 11 patients (92%). One patient (8%) experienced a persistent sinus tract fistula, which has been treated conservatively. There were no procedure-related mortalities. Ten patients (83%) completed 1 year of outpatient follow up, none of whom required further intervention. One patient has had drains removed for 7 months (at the time of publication) and has not yet completed 1-year follow up. One patient died of metastatic colon cancer 3 months after her last necrosectomy with drains in place. No patients required surgery or repeat percutaneous access after necrosectomy.

Discussion

Infected WOPN is a life-threatening adverse event of acute pancreatitis. Previous studies have shown that a more minimally invasive, step-up approach with percutaneous drainage is superior to up-front surgery; however, these patients often fail drainage and ultimately require surgical necrosectomy which carries high morbidity and mortality rates [3, 7]. More recently, several endoscopic modalities have been developed to improve or replace the

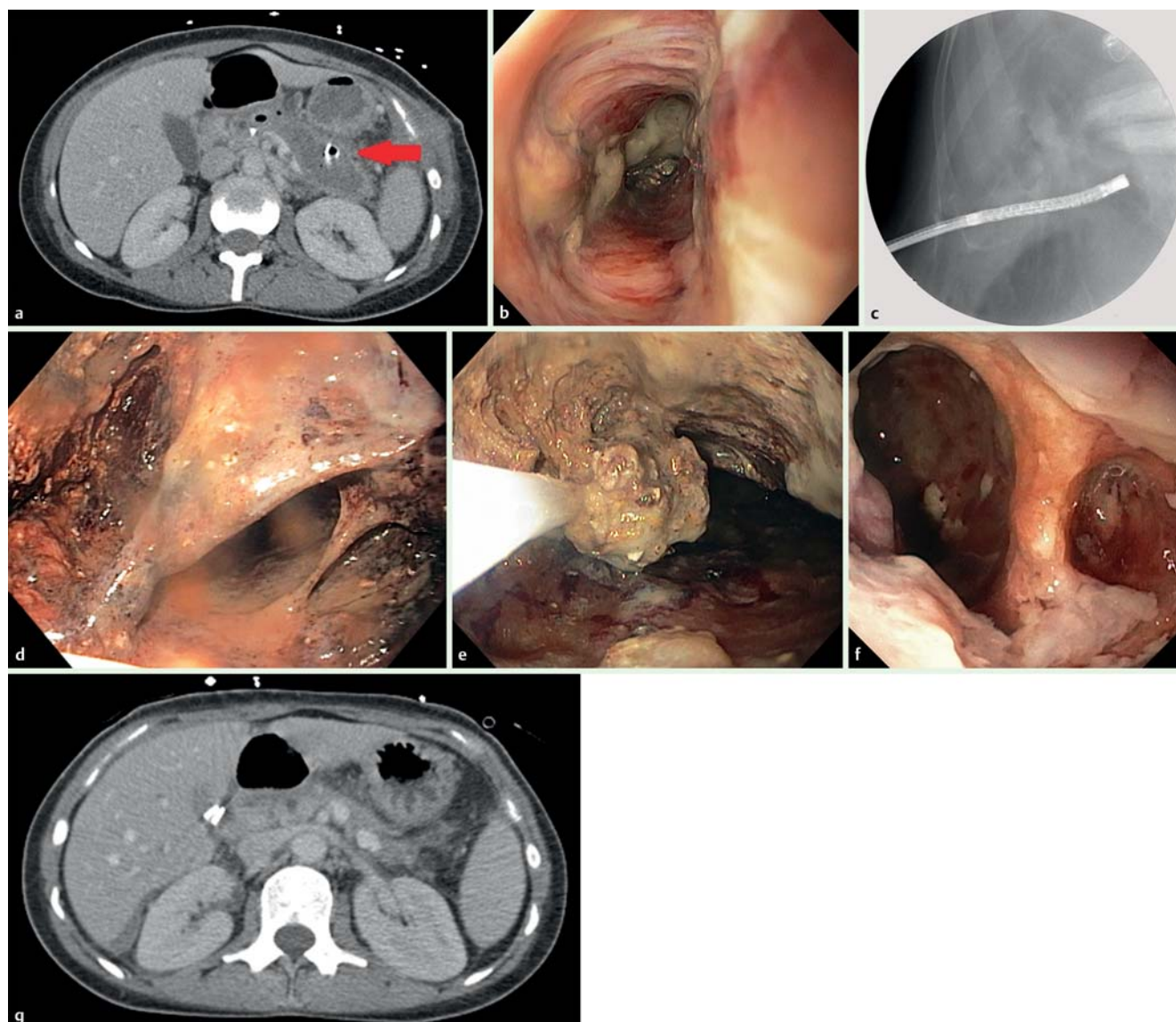


Fig. 1 a Axial CT scan with WOPN (red arrow) with percutaneous drain in place. b Endoscopic image of sinus tract. c Fluoroscopy of percutaneous endoscope accessing WOPN via sinus tract. d Initial visualization of necrotic cavity prior to debridement. e Removal of necrotic material with polypectomy snare. f Endoscopic image of necrotic cavity after debridement. g Follow-up axial CT scan 9 months after direct percutaneous endoscopic necrosectomy demonstrating complete resolution of WOPN.

step-up approach and avoid surgical necrosectomy [3,8,9]. Direct percutaneous endoscopic necrosectomy has shown initial promise in this arena, however, the supporting data are limited [11, 12].

In this study, we have demonstrated the effectiveness and safety of direct percutaneous endoscopic necrosectomy in the treatment of infected WOPN as well as other intra-abdominal fluid collections. When compared with the recent Indian study by Dhingra et al, the current series demonstrates a lower mean number of necrosectomy procedures required per patient (2.3 vs. 5). We also had a longer median time from onset of symptoms until the initial percutaneous necrosectomy (85 days vs. 39 days). This longer delay may have allowed further maturation of the walled-off fluid collection, thereby allowing for a more complete and aggressive debridement per session, which facilitated fewer total sessions per patient. We had successful removal of all percutaneous drains in all but one patient with a median time to resolution of 57 days. Furthermore, there were no mortalities and

only one minor adverse event. In comparison with the Chinese series by Mui et al, the current series had a significantly higher clinical success rate (92% vs. 66%). We attribute this difference to their use of a small 5-mm choledochoscope, thereby limiting the extent and efficacy of debridement.

Several other minimally invasive interventions have been studied in the treatment of WOPN, particularly direct transgastric endoscopic necrosectomy. Indeed, evidence demonstrates that direct transgastric endoscopic necrosectomy is effective with superior mortality and morbidity rates when compared with surgical approaches in the management of WOPN in appropriate patients [3, 8–10]. In the GEPARD study, 93 patients with infected WOPN underwent direct transgastric endoscopic necrosectomy with an 80% clinical success rate [9]. However, they also experienced a 26% adverse event rate and 7.5% 30-day mortality rate. In another multicenter study, 104 patients with WOPN underwent direct transgastric endoscopic necrosectomy with a success rate of 91% and an adverse event rate of 14% with one periproce-

Table 2 Patient demographics and procedure details.

Sex, age	Etiology of necrosis	Sepsis/multiorgan failure	Size of necrosis (cm)	Number of percutaneous drains	Time to intervention (days)	Number of PEN	Time to resolution (days)	Adverse events	1-year sustained resolution
M, 63	Pancreatic	No	10.5 × 3.7	1	99	2	57	Fistula	Yes
M, 46	Hepatic	Yes	11.9 × 9.7 12.7 × 6.4	3	21	4	74	None	Yes
F, 51	Pancreatic	Yes	23.8 × 15.5	1	61	2	171	None	Yes
F, 34	Pancreatic	Yes	21.2 × 14.9 13.5 × 7.6 12.3 × 5.5	3	68	5	123	None	Yes
F, 65	Pancreatic	Yes	14.7 × 3.8	2	87	4	n/a	None	n/a
F, 73	Omental	No	9.8 × 3.5	1	86	1	31	None	Yes
F, 45	Pancreatic	No	14.1 × 12.9	1	79	1	10	None	Yes
F, 26	Pancreatic	No	6.4 × 2.5	1	248	1	19	None	Yes
F, 53	Pancreatic	No	11.6 × 5.2	1	124	1	57	None	Yes
M, 41	Pancreatic	Yes	7.0 × 3.2	3	53	1	59	None	Yes
F, 61	Pancreatic	No	12.4 × 2.5	1	159	1	210	None	Yes
F, 54	Pancreatic	Yes	10.6 × 9.6	2	84	5	40	None	n/a

PEN, percutaneous endoscopic necrosectomy

Table 3 Group analysis of procedure details and outcomes.

Time to intervention (days, median)	85
Number of percutaneous necrosectomies performed (mean)	2.3
Time to resolution (days, median)	57

dural death [10]. Thus, although a transgastric approach offers excellent clinical success rates and improved safety profiles when compared with surgical approaches, the overall morbidity and mortality rates of 25 and 7 are still significant [3]. Here we have demonstrated a comparable success rate, but with an improved risk profile when compared with reported rates of surgical necrosectomy and even direct transgastric endoscopic necrosectomy.

We believe direct percutaneous endoscopic necrosectomy offers several advantages over the transgastric approach in certain situations. First, percutaneous access along a predefined tract avoids many of the inherent complexities of a transluminal approach, which may explain the superior safety profile reported here. Second, direct percutaneous endoscopic necrosectomy can be performed using conscious sedation in an endoscopy suite rather than the general anesthesia often required for prolonged per-oral endoscopies. Third, the percutaneous approach is not limited to collections with abutment to the stomach or duodenum but rather, can be utilized for any intra-abdominal fluid collection accessible to interventional radiology techniques, such as the successful bilateral hepatic abscess debridement and washout and omental necrosis debridement included in this series.

There are several limitations to our study and this technique worth noting. First, a well-known potential adverse event of percutaneous drainage of pancreatic fluid collections is pancreaticocutaneous fistula formation, as was seen in one patient in this study. Our patient experienced only mild discomfort, but these fistulas have the potential to become infected and cause long-term problems. Second, one of the advantages of direct transgastric endoscopic necrosectomy is complete internalization of all hardware and close proximity of the target to the drainage site without traversing intervening bowel or abdominal vessels. In that respect, each patient is unique and, in our experience, many patients will be best served with direct transgastric endoscopic

necrosectomy or rarely a surgical approach, depending on their anatomic and clinical features. Third, this was a retrospective study with no control group for comparison of outcomes. Finally, this complex procedure should only be performed in a tertiary care center with expert interventional endoscopists and appropriate surgical availability. Despite these limitations, this is the largest US report of outcomes from direct percutaneous endoscopic necrosectomy and supports the efficacy and safety of this approach.

In conclusion, direct percutaneous endoscopic necrosectomy is a safe and effective intervention for intra-abdominal fluid collections and necrosis in appropriately selected patients. Our study demonstrates a high clinical success rate with minimal adverse events. This modality offers several new advantages including use of conscious sedation, improved accessibility, and an excellent safety profile.

Competing interests: None

References

- 1 Wu BU, Johannes RS, Sun X et al. The early prediction of mortality in acute pancreatitis: a large population-based study. *Gut* 2008; 57: 1698–1703
- 2 Besselink MG, van Santvoort HC, Boermeester MA et al. Timing and impact of infections in acute pancreatitis. *Br J Surg* 2009; 96: 267–273
- 3 Haghshenas Kashani A, Laurence JM, Kwan V et al. Endoscopic necrosectomy of pancreatic necrosis: a systematic review. *Surg Endosc* 2011; 25: 3724–3730
- 4 Gooszen HG, Besselink MG, van Santvoort HC et al. Surgical treatment of acute pancreatitis. *Langenbeck's archives of surgery/Deutsche Gesellschaft für Chirurgie* 2013; 398: 799–806
- 5 Bradley EL3rd, Howard TJ, van Sonnenberg E et al. Intervention in necrotizing pancreatitis: an evidence-based review of surgical and percutaneous alternatives. *J Gastrointest Surg* 2008; 12: 634–639
- 6 Rau B, Bothe A, Beger HG. Surgical treatment of necrotizing pancreatitis by necrosectomy and closed lavage: changing patient characteristics and outcome in a 19-year, single-center series. *Surgery* 2005; 138: 28–39 van Santvoort HC, Besselink MG, Bakker OJ et al. A step-up approach or open necrosectomy for necrotizing pancreatitis. *N Engl J Med* 2010; 362: 1491–1502
- 7 Kumar N, Conwell DL, Thompson CC. Direct endoscopic necrosectomy versus step-up approach for walled-off pancreatic necrosis: comparison of clinical outcome and health care utilization. *Pancreas* 2014; 43: 1334–1339

- 8 *Seifert H, Biermer M, Schmitt W* et al. Transluminal endoscopic necrosectomy after acute pancreatitis: a multicentre study with long-term follow-up (the GEPARD Study). *Gut* 2009; 58: 1260–1266
- 9 *Gardner TB, Coelho-Prabhu N, Gordon SR* et al. Direct endoscopic necrosectomy for the treatment of walled-off pancreatic necrosis: results from a multicenter U.S. series. *Gastrointest Endosc* 2011; 73: 718–726
- 10 *Carter CR, McKay CJ, Imrie CW*. Percutaneous necrosectomy and sinus tract endoscopy in the management of infected pancreatic necrosis: an initial experience. *Ann Surg* 2000; 232: 175–180
- 11 *Dhingra R, Srivastava S, Behra S* et al. Single or multiport percutaneous endoscopic necrosectomy performed with the patient under conscious sedation is a safe and effective treatment for infected pancreatic necrosis (with video). *Gastrointest Endosc* 2015; 81(2): 351–359
- 12 *Mui LM, Wong SK, Ng EK* et al. Combined sinus tract endoscopy and endoscopic retrograde cholangiopancreatography in management of pancreatic necrosis and abscess. *Surg Endosc* 2005; 19: 393–397
- 13 *Cerecedo-Rodriguez J, Hernandez-Trejo A, Alanis-Monroy E* et al. Endoscopic percutaneous pancreatic necrosectomy. *Gastrointest Endosc* 2014; 80: 165–166
- 14 *Inoue T, Ichikawa H, Okumura F* et al. Local administration of amphotericin B and percutaneous endoscopic necrosectomy for refractory fungal-infected walled-off necrosis: a case report and literature review. *Medicine (Baltimore)* 2015; 94: e558
- 15 *Kumbhari V, Storm AC, Tieu AH* et al. Percutaneous flexible endoscopic necrosectomy for a retroperitoneal abscess. *Endoscopy* 2014; 0146
- 16 *Yamamoto N, Isayama H, Takahara N* et al. Percutaneous direct-endoscopic necrosectomy for walled-off pancreatic necrosis. *Endoscopy* 2013; 45 Suppl 2