

# Pediatric Oncologic Imaging: A Key Application of Combined PET/MRI

## PET/MRT in der pädiatrischen Onkologie: Ein Hauptanwendungsgebiet

### Authors

S. Gatidis, C. la Fougère, J. F. Schaefer

### Affiliation

Department of Radiology, University of Tübingen, Germany

### Key words

- PET/MR
- children
- oncology
- FDG

received 29.4.2015  
accepted 16.10.2015

### Bibliography

DOI <http://dx.doi.org/10.1055/s-0041-109513>  
Published online: 2016  
Fortschr Röntgenstr 2016; 188: 359–364 © Georg Thieme Verlag KG Stuttgart · New York · ISSN 1438-9029

### Correspondence

**Herr Dr. Sergios Gatidis**  
Abteilung für Diagnostische und Interventionelle Radiologie, Universitätsklinikum Tübingen  
Hoppe-Seyler-Str. 3  
72076 Tübingen  
Germany  
Tel.: ++ 49/70 71/8 77 20  
Fax: ++ 49/70 71/58 45  
sergios.gatidis@med.uni-tuebingen.de

### Zusammenfassung

Die pädiatrische Bildgebung stellt ein Hauptanwendungsgebiet der kombinierten PET/MRT dar. In ersten Studien konnten die klinische Durchführbarkeit und mögliche Vorteile der PET/MRT im Vergleich zur PET/CT und MRT dargelegt werden. Neben einer deutlichen Reduktion der Strahlenexposition um etwa 50–75 % bietet die kombinierte PET/MRT einen diagnostischen Gewinn durch multiparametrische Charakterisierung pathophysiologischer Prozesse und ermöglicht eine Verringerung der notwendigen bildgebenden Untersuchungen. Nur wenige Studien zur pädiatrischen PET/MRT wurden bisher veröffentlicht. Weitere Studien sind notwendig, um die klinische Bedeutung dieser neuen Methode abschätzen zu können. Dieser Artikel soll die existierende Literatur zur pädiatrischen PET/MRT zusammenfassen und einen Einblick in praktische Erfahrungen aus mehr als 160 durchgeführten pädiatrischen PET-/MRT-Untersuchungen in Tübingen geben.

### Kernaussagen:

- ▶ Die kombinierte PET/MRT ist in besonderem Maße für die Anwendung in der pädiatrischen Onkologie geeignet.
- ▶ Durch den Einsatz der kombinierten PET/MRT kann die Strahlenexposition pädiatrischer Patienten gesenkt und die Anzahl notwendiger Untersuchungen reduziert werden.
- ▶ Gezielte klinische Studien sind notwendig, um spezifische Anwendungsgebiete der kombinierten PET/MRT in der Kinderradiologie genauer zu definieren.

### Introduction

Whole-body combined PET/MR imaging has found its way into clinical practice recently and has opened up new possibilities for multiparametric morphologic and functional imaging [1]. The first

### Abstract

Pediatric imaging has been identified as a key application of combined whole-body PET/MRI. First studies have revealed the clinical feasibility and possible advantages of PET/MRI over PET/CT and MRI. Besides a significant reduction in radiation exposure of about 50–75 %, combined whole-body PET/MRI offers the diagnostic advantage of the multiparametric characterization of pathophysiologic processes and helps reduce the number of necessary imaging studies. However, very few studies focusing on pediatric PET/MRI have been published to date. Additional studies are necessary in order to fully appreciate the clinical impact of this novel method. This review article shall summarize the existing literature concerning pediatric PET/MRI and give insight into the practical experience derived from over 160 pediatric PET/MRI examinations that were performed in Tübingen.

### Key Points:

- ▶ Combined PET/MR is a promising imaging modality in pediatric oncology.
- ▶ Using combined PET/MRI, diagnostic radiation exposure of pediatric patients and the number of necessary imaging studies can be reduced.
- ▶ Further clinical studies are necessary in order to define specific indications for combined PET/MRI in pediatric radiology.

### Citation Format:

- ▶ Gatidis S, la Fougère C, Schaefer J F Pediatric Oncologic Imaging: A Key Application of Combined PET/MRI. Fortschr Röntgenstr 2016; 188: 359–364

PET/MR studies identified clinical applications where PET/MRI as a combined modality may have advantages over the established modalities of PET/CT and MRI, e.g., CNS imaging [2], local prostate imaging [3], or local oncologic staging [4]. Advantages are mostly seen in the superior soft-tissue con-

trast of MRI compared to CT, the possibility of multiparametric tissue characterization using PET/MRI, and the possible reduction of radiation exposure using PET/MRI compared to PET/CT. While there is a lively debate about the clinical benefits and cost-effectiveness of many of these applications, pediatric imaging is broadly recognized as one of the key drivers for combined PET/MRI [5]. First clinical studies revealed possible advantages of PET/MRI over PET/CT, beyond the significant reduction in radiation exposure, specifically in pediatric oncologic patients [6–8].

This review article shall summarize the existing literature concerning pediatric PET/MRI and give insight into the practical experience derived from over 160 pediatric PET/MRI examinations that were performed in Tübingen.

## PET/MR technology

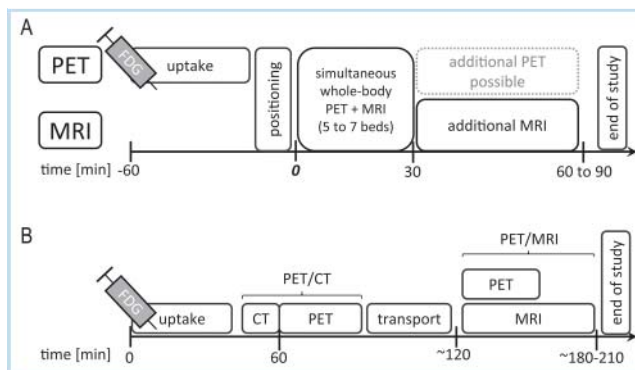
Two different technical approaches to combined PET/MR have been proposed, namely, sequential [9] and simultaneous [1, 10] PET/MRI. In sequential PET/MRI, PET and MRI scanners are spatially separated, whereas simultaneous imaging demands an integrated scanner. The sequential approach is technologically less complex, as interference of MR magnetic fields and PET technology are minimized by the spatial distance of the scanners. Especially in pediatric imaging, however, where patient compliance may be limited, the simultaneous approach offers significant advantages with regard to work flow and acquisition time and, importantly, in the spatial and temporal correlation of PET and MRI. Commercially available simultaneous systems are based on 3-Tesla MR systems and have a bore size of about 60 cm and axial PET coverage of about 25 cm, which provides sufficient space for pediatric patients and allows for whole-body PET examinations using five to seven bed positions in most patients [1, 10].

## Work flow in pediatric PET/MRI

### Patient preparation

Thorough patient preparation is a prerequisite for a successful PET/MR examination, especially in pediatric imaging where patient compliance may be limited. The indication for a PET/MRI examination should be established for each individual patient using an interdisciplinary approach involving the pediatric radiologist, nuclear medicine physician, and referring pediatrician. This includes the choice of the appropriate PET tracer and the assessment of the need for patient sedation. Informed consent must be acquired by the legal guardians before the examination. Specifics of patient preparation (e. g., fasting before FDG application or before sedation) must be communicated.

For FDG examinations, it is of importance to avoid activation of brown adipose tissue that has a high prevalence among pediatric patients and can impair diagnostic validity of PET. For this purpose, patients should be kept warm before and after tracer injection, and propranolol can be administered after consideration of contraindications [11, 12]. Similarly, furosemide may be administered in order to minimize tracer accumulation within the urinary bladder when examining the anatomic area of the pelvis. Additional catheterization of the urinary bladder can also be considered in these cases. [12]



**Fig. 1** Workflow in whole body FDG-PET/MRI used in our institution. **A** Routine whole-body FDG-PET/MRI workflow. Most uptake time is spent outside the scanner. Examination starts with simultaneous PET and MRI, additional MRI sequences can be appended. **B** Study protocol for sequential PET/CT and PET/MRI in a research setting. After a single tracer injection PET/CT is performed first, then the patient is brought to the PET/MRI scanner for the PET/MRI examination.

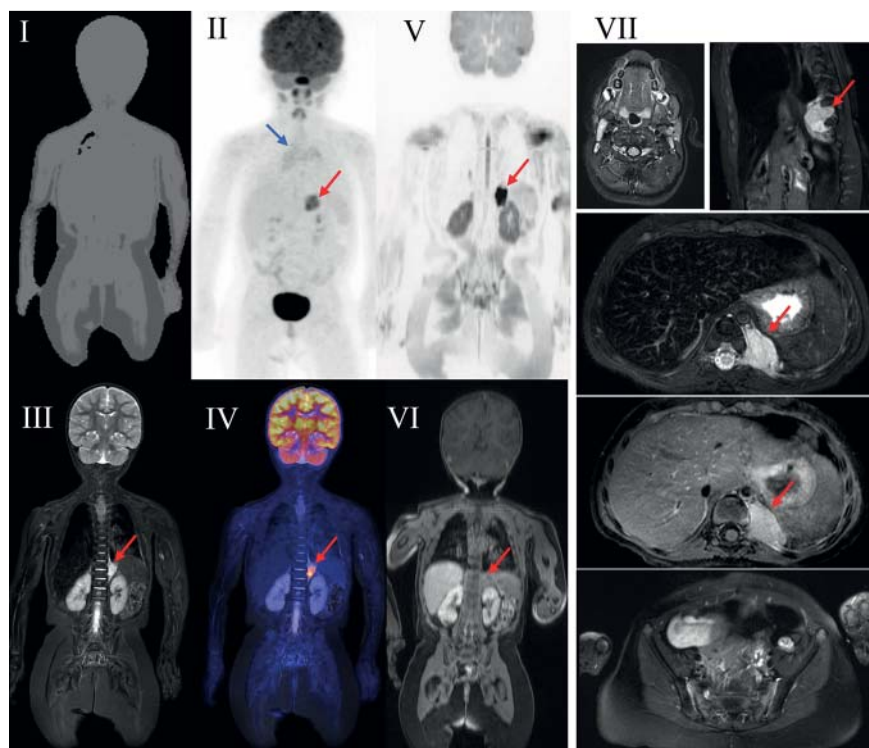
**Abb. 1** Ablauf einer Ganzkörper-PET/MRT-Untersuchung an unserem Institut. **A** Ablauf im Rahmen der klinischen Routine. Ein Großteil der Uptake-Zeit wird außerhalb des Scanners verbracht. Die Untersuchung beginnt mit simultaner PET- und MRT-Messung; zusätzliche MR-Messungen können angeschlossen werden. **B** Untersuchungsablauf bei sequentieller Durchführung von PET/CT und PET/MRT im Rahmen klinischer Studien. Nach Tracer-Applikation erfolgt zunächst die PET/CT-Untersuchung; anschließend wird der Patient zum PET/MRT transportiert, wo die PET/MRT-Untersuchung durchgeführt wird.

## Examination protocol

The complexity and variability of PET/MR examination protocols is higher compared to MRI or PET/CT, as specific patient preparation for PET and complex MR protocols are combined. Numerous workflows have already been proposed for simultaneous PET/MRI [13, 14]. Despite the high number of possible acquisition strategies, in practice most pediatric whole-body protocols show certain similarities.

Fig. 1A shows a standard FDG-PET/MRI acquisition protocol implemented in our institution for pediatric oncologic whole-body imaging. After tracer injection, the patient rests outside the scanner for most of the uptake time (in case of FDG, for 45 of the 60 minutes of uptake time). This allows for voiding of the urinary bladder before the examination, reducing local radiation dose, and minimizing high activity PET artifacts in the pelvic region. Subsequently, the patient is positioned within the scanner. Alternatively, tracer injection can be performed directly prior to the examination and PET uptake time can be used for MR-only imaging. However, this approach not only increases local radiation dose of the urinary bladder but also increases the potential risk of premature termination of the examination by the patient before PET data are acquired.

The examination usually starts with a basic module consisting of a whole-body PET acquisition accompanied by simultaneous whole-body MR imaging, mostly using coronal fat-saturated T2-weighted or inversion recovery sequences [7, 13, 14], in a bed-per-bed manner. Depending on the simultaneous MR protocol, PET acquisition time is usually between 4 and 6 minutes per bed position. In addition, a dedicated MR sequence has to be acquired for each bed position for MR-based attenuation correction. On most scanners, a double-echo chemical shift gradient-echo sequence is used for this purpose (Dixon technique) [15].



**Fig. 2** Typical oncologic whole-body 18F-FDG-PET/MRI protocol. 2 year-old girl with recurrent metastatic teratoma. Attenuation map (I), coronal STIR (III), and potentially diffusion-weighted imaging (V,  $b = 800 \text{ s/m}^2$ ) are acquired simultaneously with PET (II). Additional local imaging of organ systems and the primary tumor in different orientations and contrasts (VII) as well as contrast-enhanced whole-body images (VI) are acquired subsequently. The red arrows mark a paravertebral metastasis with elevated 18F-FDG uptake, uptake of contrast agent, and diffusion restriction. The blue arrow shows typical physiologic 18F-FDG-uptake of the thymus in children.

**Abb. 2** Typisches onkologisches Ganzkörper 18F-FDG-PET/MRT-Protokoll. 2-jähriges Mädchen mit metastasierendem Teratom. Die Schwächungskarte (I), die coronare STIR (III) und ggf. diffusionsgewichtete Sequenzen (V) werden gleichzeitig mit der PET-Messung aufgenommen. Zusätzliche lokale Bildgebung einzelner Organe oder des Primärtumors folgen im Anschluss in unterschiedlichen Orientierungen (VII) und nach Kontrastmittelgabe (VI). Die roten Pfeile markieren eine paravertebrale Metastase mit fokal erhöhter Glukosestoffwechselaktivität und Diffusionsneinschränkung. Der blaue Pfeil markiert die physiologische FDG-Anreicherung des kindlichen Thymus.

**Table 1** Typical sequence parameters used for whole-body MRI in PET/MRI in our institution.

**Tab. 1** Typische Sequenzparameter, wie sie in unserem Institut implementiert sind.

	Dixon AC	STIRcor	T2-TSE	STIRax	DWI	T1 Flash fs
TE (echo time) [ms]	1.23/2.46	78	100	81	60	1.5
TR (repetition time) [ms]	3.6	6400	3500	4500	6000	3.8
bandwidth [Hz/px]	965	383	260	220	1860	744
matrix size	79 × 192	256 × 256	256 × 300	197 × 384	108 × 192	320 × 180
resolution [mm <sup>3</sup> ]	4.1 × 2.6 × 2.6	1.5 × 1.5 × 4	1.25 × 1.25 × 5	1.2 × 0.83 × 5	2.6 × 2.6 × 5	1.2 × 1.2 × 3
excitation angle [°]	10	120	90	120	90	10
inversion time [ms]		200		220		
b-values [mm <sup>2</sup> /s]					50 and 800	
approximate duration	18 sec	3 min	4 min	4 min	2 min	18 sec

Dixon AC: T1-weighted, double echo, gradient echo sequence for attenuation correction. STIRcor: Coronal short tau inversion recovery (STIR) sequence. T2-TSE: Axial T2-weighted turbo spin-echo sequence (mostly for abdominal imaging). STIRax: Axial STIR, used for neck and lung imaging. DWI: Diffusion-weighted sequence. T1 Flash fs: Fat-saturated 3D gradient echo sequence used for contrast-enhanced imaging.

After this basic module, additional MRI sequences are usually measured depending on the clinical question, available previous imaging, and patient compliance (► Fig. 2). ► Table 1 shows typical parameters of whole-body MR sequences used in our institution [16].

A whole-body PET/MRI examination takes at least 20–30 minutes if only the basic module (PET and simultaneous MRI) is acquired. However, a typical oncologic whole-body PET/MR examination, including additional MR-only measurements, takes about 60 to 90 minutes including functional MRI (diffusion-weighted imaging, contrast-enhanced imaging) and highly-resolved local tumor imaging.

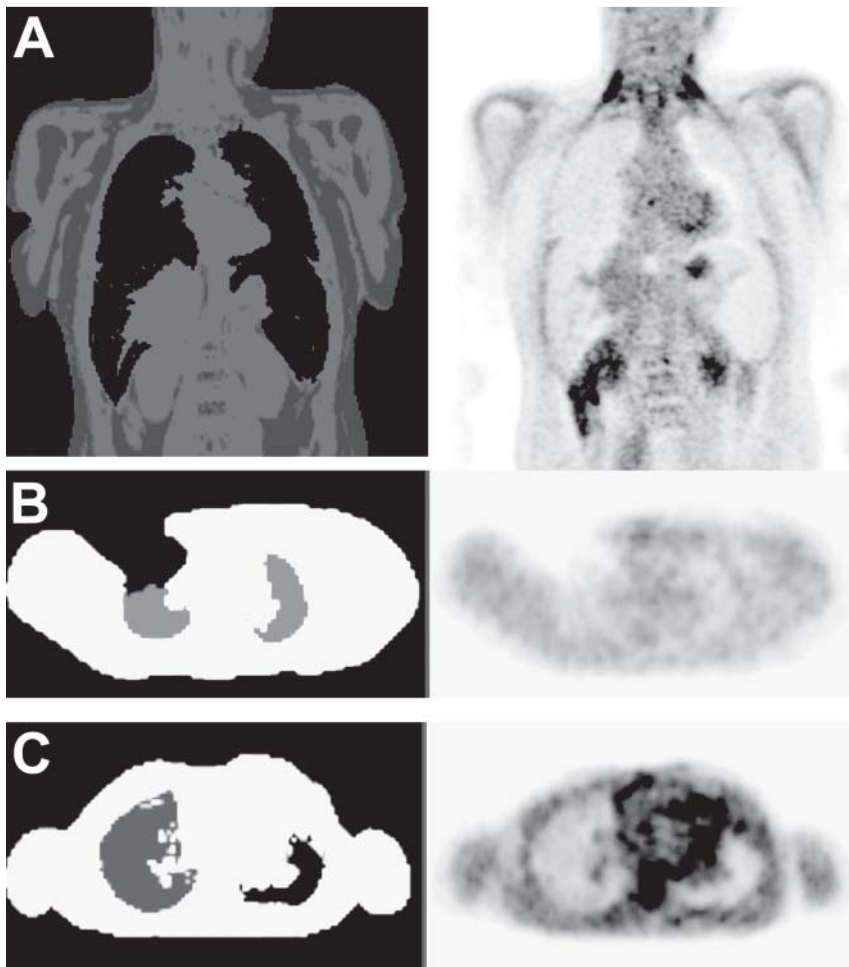
### Image interpretation and pitfalls

Reading and interpreting PET/MRI data is a complex task, as numerous different sequences have to be analyzed together with

PET data. This requires a high level of expertise in pediatric MRI and pediatric nuclear medicine.

Compared with adult patients, children display different physiologic and anatomic characteristics that lead to specific findings in PET and MRI (e.g., thymus tissue, brown adipose tissue, etc.) [16, 17] that have to be considered in order to avoid false interpretations. In our institution, examinations are interpreted in consensus by multidisciplinary teams consisting of a radiologist and a nuclear medicine physician. Results are routinely presented and discussed at the institutional interdisciplinary pediatric tumor board.

A major issue when reading PET/MRI data is the choice of appropriate software tools that can handle data amounts and complexity. Unfortunately, it is still felt among PET/MR users that the availability of tailored software solutions for PET/MRI is rather limited [5]. When reading PET/MRI data, certain technical drawbacks related to MR-based attenuation correction have to be considered in order to avoid misinterpretation. In PET/MRI, PET attenuation coeffi-



**Fig. 3** Typical segmentation artefacts of MR-based attenuation correction. **A** Patient with hepatic and splenic iron overload after chemotherapy. Liver and spleen are segmented as lung tissue in the attenuation map (left) resulting in significant underestimation of tracer uptake in these organs (right). **B** Patient with metal implant of the right chest wall causing susceptibility artefacts with signal loss in the attenuation map (left) and local underestimation of tracer uptake (right). **C** Segmentation error of lung tissue. The left lung is erroneously segmented as background in the attenuation map (left) leading to a slight underestimation of tracer uptake (right).

**Abb. 3** Typische Segmentierungsartefakte der MR-basierten Schwächungskorrektur. **A** Hepatischer und lienaler Signalverlust durch Eisenüberladung nach Chemotherapie. Beide Organe sind fälschlicherweise als Lungengewebe segmentiert (links), was zu einer Unterschätzung der FDG-Aufnahme führt (rechts). **B** Metallimplantat (Port-System) der rechten Thoraxwand. Lokale Suszeptibilitätsartefakte führen zu Artefakten in der Schwächungskarte (links) und dadurch zu einer Unterschätzung der FDG-Aufnahme (rechts). **C** Segmentierungsfehler der linken Lunge. Die linke Lunge wird fälschlicherweise als Luft segmentiert, was zu einer geringfügigen Unterschätzung der Traceranreicherung führt.

patients are not measured but usually derived based on tissue segmentation using T1-weighted sequences [15]. In general, resulting PET quantification is accurate for adult and pediatric patients. However, significant quantitative errors are observed in and around skeletal structures (e.g., bone metastases and bone marrow) as bone attenuation is routinely neglected [7, 15, 18]. Furthermore, typical segmentation artifacts can occur in MR-based attenuation correction that are mostly observed around metal implants causing MR susceptibility artifacts. Typical artifacts are summarized in **Fig. 3**. Although these artifacts do not have a significant impact on PET-based diagnoses in the majority of cases [19], it is highly recommended to assess the quality of the MR-based attenuation map as a first step in reading PET/MRI data.

### Indications for PET/MRI in pediatric oncology

In general, combined PET/MRI is clinically indicated in all pediatric patients with indication for a PET scan [20]. Available data show that PET measurements acquired on PET/MRI systems have equivalent qualitative and quantitative characteristics compared to PET measurements of PET/CT in adult and pediatric patients [7, 8, 18, 21].

According to national [22, 23] and international [12] guidelines for PET in children with cancer, 18F-FDG-PET is indicated for diagnosis, staging, and restaging in a number of tumor entities, which are mainly lymphoma, sarcoma, neuroblastoma, and CNS tumors.

The role of 18F-FDG-PET in imaging of pediatric lymphoma is well-established for initial staging, risk stratification, and therapy monitoring [12, 24]. Especially in Hodgkin lymphoma, PET imaging plays a decisive role for therapy response monitoring and has a direct impact on diagnostic decisions concerning the indication for radiation therapy [25]. In patients with sarcoma, 18F-FDG-PET can add additional information with regard to risk stratification and detection of tumor recurrence [12, 24]. In patients with neuroblastoma, the role of FDG-PET is limited to tumor characterization and risk stratification complementing diagnostic information from MIBG-scintigraphy [12, 24] and to patients with MIBG-negative tumor load. However, new developments in radiopharmacy may enable comprehensive characterization of neuroblastoma with PET only by using fluoride-labeled 18F-MFGB [26] or specific antibody tracers [27].

For most applications in pediatric oncology, 18F-FDG is the standard tracer. For specific indications, however, alternative tracers are used, e.g., 68Ga-DOTATATE for somatostatin receptor imaging in neuroendocrine [28] tumors or amino acid tracers for CNS tumors [29].

### Advantages and limitations of PET/MRI compared to PET/CT and whole-body MRI

The combination of PET and MRI in a single examination offers certain advantages over the established modalities of PET/CT or MRI beyond the acquisition of separate PET and MRI data.

Whole-body MRI is the method of choice for imaging of numerous oncologic disorders in children, especially for primary diagnosis and staging [30–32]. For this purpose, MRI provides high sensitivity for lesion detection and excellent soft-tissue contrast for local staging (up to 94%) [16, 33]. However, specificity may be limited in MRI (down to 30%) especially in the follow-up situation (e.g., in the assessment of residual disease in Hodgkin lymphoma) [33]. In this situation, the addition of PET can significantly increase diagnostic sensitivity (up to 97%) and specificity (up to 82%) by combination of high anatomic resolution and high sensitivity of MRI and complementary metabolic information of PET [33]. It is thus self-evident that combined PET/MRI is indicated in patients with indications for whole-body MRI and PET. Compared to CT, MRI is diagnostically superior in characterization of soft-tissue lesions and bone marrow processes as well as in local tumor imaging [34–36]. Thus, PET/MRI can replace PET/CT in all applications where MRI is the modality of choice for morphological imaging [7].

First prospective clinical studies with pediatric cancer patients have revealed at least equivalent diagnostic accuracy of combined PET/MRI in direct comparison with PET/CT, with possible advantages for PET/MRI in the detection and characterization of soft-tissue lesions [7, 8]. However, further studies in larger populations are necessary in order to fully appreciate the diagnostic accuracy and clinical impact of PET/MRI in pediatric oncology.

Replacing two previously separate examinations (e.g., MRI and PET/CT and MRI and PET for local and whole-body staging) with a combined examination has additional advantages for pediatric patients beyond the diagnostic information of two different modalities. For example, a combined examination significantly decreases examination time and reduces the number of imaging studies. This is of importance due to possibly limited compliance of pediatric patients. More importantly, however, by reducing the number of imaging studies, the number of sedations and thus anesthesia-related risks [37] can be markedly reduced in young children.

A further advantage of simultaneous combined PET/MRI is the high spatial and temporal correlation of imaging data. Anatomic allocation of PET and MRI can thus be increased [38]. Furthermore, PET image quality can be improved by MR-based PET motion correction [39].

The most-discussed motivation for pediatric PET/MRI compared to PET/CT is the marked reduction in diagnostic radiation exposure (by 50–73% [7, 8]) that is achieved by replacing CT with MRI. Typical dose exposure by FDG-PET in pediatric PET/MRI as reported in first clinical studies ranges from  $4.8 \pm 1.3$  to  $5.6 \pm 1.5$  mSv; the corresponding CT dose of PET/CT amounted to values ranging from  $4.4 \pm 1.7$  to  $18.2 \pm 10$  mSv [7, 8]. Recent studies suggest that radiation exposure in childhood, especially by CT, bears the risk of negative long-term effects including secondary malignancies [40, 41]. In contrast to adult oncologic patients, pediatric patients often have an excellent long-term prognosis [42] and receive numerous follow-up examinations with significant cumulative radiation exposure [43]. In this context, the use of PET/MRI enables a significant reduction of cumulative doses. Combined PET/MRI will also enable a reduction of PET tracer doses by prolonging PET acquisition times. This is possible without increasing total acquisition time, as MRI acquisition is usually more time-consuming and PET acquisition can be performed simultaneously [44].

However, specific limitations of PET/MRI exist that must be mentioned. For instance, detection of pulmonary lesions is still lim-

ited in MRI compared to CT. Although MRI seems to be sufficient for pulmonary staging on a patient basis [45], small lung lesions can be missed in MRI [46]. It is thus recommended to perform an additional lung CT in patients with clinically relevant risk for pulmonary spread, e.g., in the initial staging of sarcoma.


In addition, PET/MRI cannot be performed in patients with contraindications for MRI. In these patients, PET/CT using dose-optimized protocols is an excellent alternative.

Finally, MR image quality is more dependent on patient compliance compared to CT. This may result in reduced image quality in PET/MRI in single patients. However, our experience in pediatric whole-body MRI and PET/MRI shows that older pediatric patients usually collaborate well. For children younger than 6–8 years, sedation is usually necessary for PET/CT and PET/MRI.

### PET/MRI as a research tool in pediatric radiology and oncology



The availability of simultaneous PET/MRI scanners is very limited today. Existing scanners are often used in the context of clinical studies.

Typically, PET/MRI studies are performed in order to assess the diagnostic value of PET/MRI compared to other modalities for specific patient populations and clinical questions. Often, PET/MRI is directly compared to PET/CT in these studies [7, 8, 10, 21, 38, 45, 47]. Performing studies of this kind in children is highly challenging. High ethical and organizational demands must be considered, and patient compliance may interfere with data acquisition. Despite these difficulties, prospective clinical studies are of importance in order to identify patients that benefit most from combined PET/MRI.  **Fig. 1B** shows a typical research protocol for a comparative study of PET/CT and PET/MRI used in our institution [16].

Equally important, PET/MRI is a potentially powerful tool for functional and molecular imaging and for characterization of tissues. More than any other available imaging modality, it can be used to assess changes in tumorous tissues during therapeutic interventions. In the near future, PET/MRI will likely be used in the context of therapeutic clinical studies for the purpose of monitoring therapy effects and thus will help advance pediatric oncology.

### Conclusion



Combined simultaneous PET/MRI is a promising modality for diagnosis, staging, and therapy monitoring in pediatric oncology. It offers several advantages over PET/CT and should thus be preferentially considered for pediatric patients where available. For specific indications, PET/MRI can add significant complementary diagnostic information to MRI-only. When performing PET/MRI, organizational challenges should be considered. Limitations of the technique, especially concerning attenuation correction and lung imaging, must be taken into account. Beyond clinical applications, PET/MRI is a potentially powerful research tool that may help advance pediatric oncology in the future.

### References

- 1 Delso G, Furst S, Jakoby B et al. Performance measurements of the Siemens mMR integrated whole-body PET/MR scanner. *J Nucl Med* 2011; 52: 1914–1922

- 2 *Bisdas S, Ritz R, Bender B et al.* Metabolic mapping of gliomas using hybrid MR-PET imaging: feasibility of the method and spatial distribution of metabolic changes. *Invest Radiol* 2013; 48: 295–301
- 3 *Hartenbach M, Hartenbach S, Bechtloff W et al.* Combined PET/MRI improves diagnostic accuracy in patients with prostate cancer: a prospective diagnostic trial. *Clin Cancer Res* 2014; 20: 3244–3253
- 4 *Ohno Y, Koyama H, Yoshikawa T et al.* Three-way Comparison of Whole-Body MR, Ceregistered Whole-Body FDG PET/MR, and Integrated Whole-Body FDG PET/CT Imaging: TNM and Stage Assessment Capability for Non-Small Cell Lung Cancer Patients. *Radiology* 2015; 275: 849–861
- 5 *Bailey DL, Antoch G, Bartenstein P et al.* Combined PET/MR: The Real Work Has Just Started. Summary Report of the Third International Workshop on PET/MR Imaging; February 17–21, 2014, Tubingen, Germany. *Mol Imaging Biol* 2015; 17: 297–312
- 6 *Hirsch FW, Sattler B, Sorge I et al.* PET/MR in children. Initial clinical experience in paediatric oncology using an integrated PET/MR scanner. *Pediatr Radiol* 2013; 43: 860–875
- 7 *Schafer JF, Gatidis S, Schmidt H et al.* Simultaneous Whole-Body PET/MR Imaging in Comparison to PET/CT in Pediatric Oncology: Initial Results. *Radiology* 2014; 273: 220–231
- 8 *Gatidis S, Schmidt H, Guckel B et al.* Comprehensive Oncologic Imaging in Infants and Preschool Children With Substantially Reduced Radiation Exposure Using Combined Simultaneous 18F-Fluorodeoxyglucose Positron Emission Tomography/Magnetic Resonance Imaging. *Invest Radiol* 2015, Aug 24 [Epub ahead of print]
- 9 *Zaidi H, Ojha N, Morich M et al.* Design and performance evaluation of a whole-body Ingenuity TF PET-MRI system. *Phys Med Biol* 2011; 56: 3091–3106
- 10 *Igaru A, Mittra E, Minamimoto R et al.* Simultaneous whole-body time-of-flight 18F-FDG PET/MRI: a pilot study comparing SUVmax with PET/CT and assessment of MR image quality. *Clin Nucl Med* 2015; 40: 1–8
- 11 *Parysow O, Mollerach AM, Jager V et al.* Low-dose oral propranolol could reduce brown adipose tissue F-18 FDG uptake in patients undergoing PET scans. *Clin Nucl Med* 2007; 32: 351–357
- 12 *Stauss J, Franzius C, Pfluger T et al.* Guidelines for 18F-FDG PET and PET-CT imaging in paediatric oncology. *Eur J Nucl Med Mol Imaging* 2008; 35: 1581–1588
- 13 *von Schulthess GK, Veit-Haibach P.* Workflow Considerations in PET/MR Imaging. *J Nucl Med* 2014; 55: 19S–24S
- 14 *Martinez-Moller A, Eiber M, Nekolla SG et al.* Workflow and scan protocol considerations for integrated whole-body PET/MRI in oncology. *J Nucl Med* 2012; 53: 1415–1426
- 15 *Bezrukov I, Mantlik F, Schmidt H et al.* MR-Based PET attenuation correction for PET/MR imaging. *Semin Nucl Med* 2013; 43: 45–59
- 16 *Schaefer JF, Kramer U.* Whole-body MRI in children and juveniles. *Fortschr Röntgenstr* 2011; 183: 24–36
- 17 *Shammas A, Lim R, Charron M.* Pediatric FDG PET/CT: physiologic uptake, normal variants, and benign conditions. *Radiographics* 2009; 29: 1467–1486
- 18 *Wiesmuller M, Quick HH, Navalpakkam B et al.* Comparison of lesion detection and quantitation of tracer uptake between PET from a simultaneously acquiring whole-body PET/MR hybrid scanner and PET from PET/CT. *Eur J Nucl Med Mol Imaging* 2013; 40: 12–21
- 19 *Brendle C, Schmidt H, Oergel A et al.* Segmentation-based attenuation correction in positron emission tomography/magnetic resonance: erroneous tissue identification and its impact on positron emission tomography interpretation. *Invest Radiol* 2015; 50: 339–346
- 20 *Purz S, Sabri O, Viehweger A et al.* Potential Pediatric Applications of PET/MR. *J Nucl Med* 2014; 55: 32S–39S
- 21 *Al-Nabhani KZ, Syed R, Michopoulou S et al.* Qualitative and quantitative comparison of PET/CT and PET/MR imaging in clinical practice. *J Nucl Med* 2014; 55: 88–94
- 22 *Barrington SF, Begent J, Lynch T et al.* Guidelines for the use of PET-CT in children. *Nucl Med Commun* 2008; 29: 418–424
- 23 *Franzius C, Stauss J, Pfluger T et al.* Procedure guidelines for whole-body 18F-FDG PET and PET/CT in children with malignant diseases. *Nuklearmedizin* 2010; 49: 225–233
- 24 *Uslu L, Donig J, Link M et al.* Value of 18F-FDG PET and PET/CT for evaluation of pediatric malignancies. *J Nucl Med* 2015; 56: 274–286
- 25 *Kluge R, Korholz D.* Role of FDG-PET in Staging and Therapy of Children with Hodgkin Lymphoma. *Klin Padiatr* 2011; 223: 315–319
- 26 *Zhang H, Huang R, Cheung NK et al.* Imaging the norepinephrine transporter in neuroblastoma: a comparison of [18F]-MFBG and 123I-MIBG. *Clin Cancer Res* 2014; 20: 2182–2191
- 27 *Vavere AL, Butch ER, Dearing JL et al.* 64Cu-p-NH2-Bn-DOTA-hu14.18K322A, a PET radiotracer targeting neuroblastoma and melanoma. *J Nucl Med* 2012; 53: 1772–1778
- 28 *Ruf J, Heuck F, Schiefer J et al.* Impact of Multiphase 68Ga-DOTATOC-PET/CT on therapy management in patients with neuroendocrine tumors. *Neuroendocrinology* 2010; 91: 101–109
- 29 *Gulyas B, Halldin C.* New PET radiopharmaceuticals beyond FDG for brain tumor imaging. *Q J Nucl Med Mol Imaging* 2012; 56: 173–190
- 30 *Kwee TC, Takahara T, Vermoolen MA et al.* Whole-body diffusion-weighted imaging for staging malignant lymphoma in children. *Pediatr Radiol* 2010; 40: 1592–1602
- 31 *Goo HW, Choi SH, Ghim T et al.* Whole-body MRI of paediatric malignant tumours: comparison with conventional oncological imaging methods. *Pediatr Radiol* 2005; 35: 766–773
- 32 *Krohmer S, Sorge I, Krausse A et al.* Whole-body MRI for primary evaluation of malignant disease in children. *Eur J Radiol* 2010; 74: 256–261
- 33 *Pfluger T, Melzer HI, Mueller WP et al.* Diagnostic value of combined (1)(8)F-FDG PET/MRI for staging and restaging in paediatric oncology. *Eur J Nucl Med Mol Imaging* 2012; 39: 1745–1755
- 34 *Mayerhoefer ME, Karanikas G, Kletter K et al.* Evaluation of diffusion-weighted MRI for pretherapeutic assessment and staging of lymphoma: results of a prospective study in 140 patients. *Clin Cancer Res* 2014; 20: 2984–2993
- 35 *Aisen AM, Martel W, Braunstein EM et al.* MRI and CT evaluation of primary bone and soft-tissue tumors. *Am J Roentgenol* 1986; 146: 749–756
- 36 *Zimmer WD, Berquist TH, McLeod RA et al.* Magnetic resonance imaging of osteosarcomas. Comparison with computed tomography. *Clin Orthop Relat Res* 1986; 289–299
- 37 *Wilder RT, Flick RP, Sprung J et al.* Early exposure to anesthesia and learning disabilities in a population-based birth cohort. *Anesthesiology* 2009; 110: 796–804
- 38 *Brendle CB, Schmidt H, Fleischer S et al.* Simultaneously acquired MR/PET images compared with sequential MR/PET and PET/CT: alignment quality. *Radiology* 2013; 268: 190–199
- 39 *Wurslin C, Schmidt H, Martirosian P et al.* Respiratory motion correction in oncologic PET using T1-weighted MR imaging on a simultaneous whole-body PET/MR system. *J Nucl Med* 2013; 54: 464–471
- 40 *Miglioretti DL, Johnson E, Williams A et al.* The use of computed tomography in pediatrics and the associated radiation exposure and estimated cancer risk. *JAMA Pediatr* 2013; 167: 700–707
- 41 *Pearce MS, Salotti JA, Little MP et al.* Radiation exposure from CT scans in childhood and subsequent risk of leukaemia and brain tumours: a retrospective cohort study. *Lancet* 2012; 380: 499–505
- 42 *Robison LL, Green DM, Hudson M et al.* Long-term outcomes of adult survivors of childhood cancer. *Cancer* 2005; 104: 2557–2564
- 43 *Chawla SC, Federman N, Zhang D et al.* Estimated cumulative radiation dose from PET/CT in children with malignancies: a 5-year retrospective review. *Pediatr Radiol* 2010; 40: 681–686
- 44 *Oehmigen M, Ziegler S, Jakoby BW et al.* Radiotracer Dose Reduction in Integrated PET/MR: Implications from National Electrical Manufacturers Association Phantom Studies. *J Nucl Med* 2014; 55: 1361–1367
- 45 *Schwenzer NF, Schraml C, Muller M et al.* Pulmonary lesion assessment: comparison of whole-body hybrid MR/PET and PET/CT imaging—pilot study. *Radiology* 2012; 264: 551–558
- 46 *Rauscher I, Eiber M, Furst S et al.* PET/MR imaging in the detection and characterization of pulmonary lesions: technical and diagnostic evaluation in comparison to PET/CT. *J Nucl Med* 2014; 55: 724–729
- 47 *Catalano OA, Rosen BR, Sahani DV et al.* Clinical impact of PET/MR imaging in patients with cancer undergoing same-day PET/CT: initial experience in 134 patients—a hypothesis-generating exploratory study. *Radiology* 2013; 269: 857–869