Small intestine grasped by over-the-scope-clip during attempt to close an iatrogenic colonic perforation

The over-the-scope-clip (OTSC; Ovesco, Tübingen, Germany) has been developed for the closure of intestinal defects [1,2]. We report on the case of a misplaced OTSC, which grasped the small intestine through an iatrogenic colonic perforation.

A 78-year-old women underwent follow-up colonoscopy after right-sited colon resection, which was performed for colon carcinoma. In the transverse colon, a flat polyp was detected. After performing the lifting procedure, a polypectomy was carried out using a snare. Immediately after polypectomy, a transmural iatrogenic perforation was observed (**Fig. 1 a**).

The investigator immediately tried to close the perforation by applying an OTSC, using the standard procedure that involves suctioning the defect to ensure correct clip positioning. After releasing the OTSC, the small intestine was seen in the colonic lumen, with the clip fixed around it (**Fig. 1 b**, **Video 1**).

The patient was transferred to the surgical department for laparotomy 2 hours after the perforation event. During laparotomy, the livid color of the jejunum wall could be seen where the OTSC had grasped the small intestine. The intestinal lumen was occluded completely (**Fig. 2 a**). The OTSC was released using a side cutter,

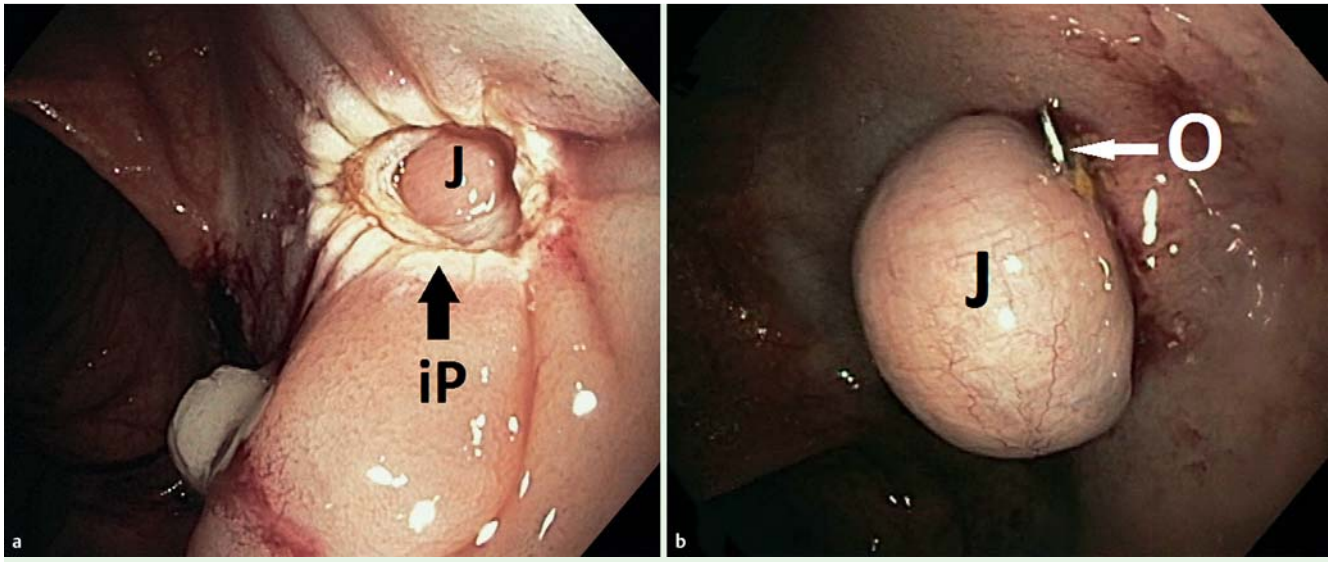

Fig. 1 Closure of an iatrogenic colonic perforation using an over-the-scope clip (OTSC). **a** Iatrogenic transmural perforation defect (iP) of the colon after polypectomy. The small intestine (J) can be seen through the defect. **b** An attempt to close the perforation using an OTSC (O) resulted in the small intestine (J) being grasped by the clip.

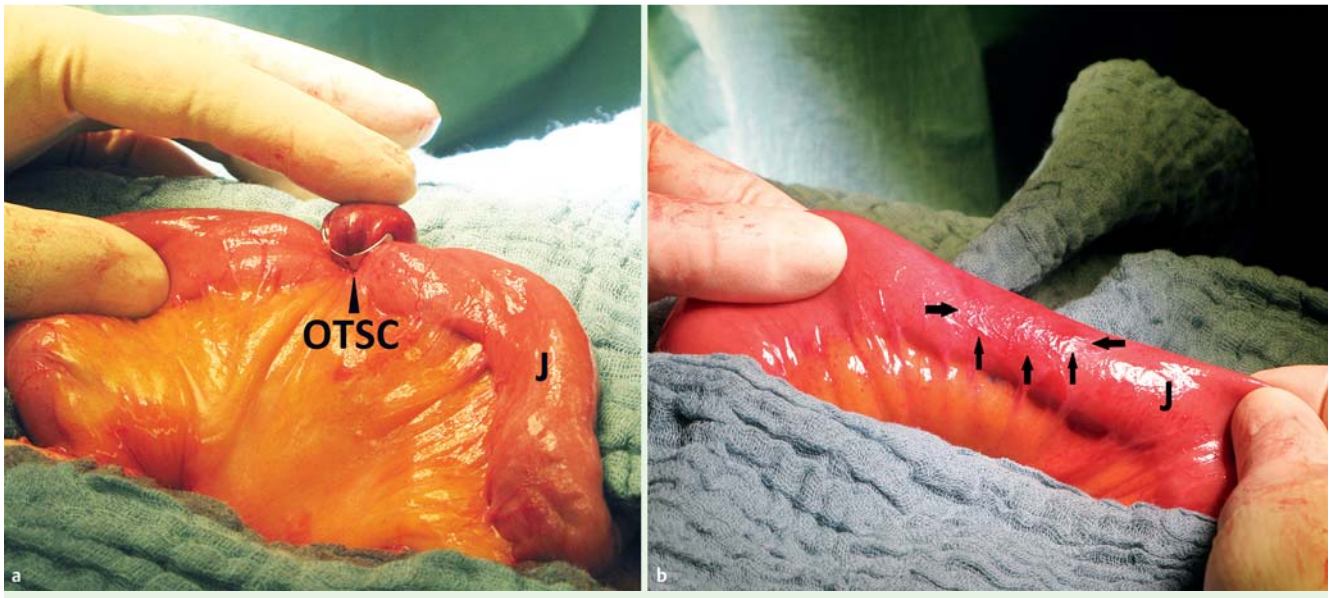

Fig. 2 Laparotomy was carried out to release the small intestine (J) from the over-the-scope clip (OTSC). **a** The intestinal lumen was occluded by the OTSC. **b** After removing the OTSC, the small intestine was inspected for damage. The arrows show the area that had been grasped by the clip.

This document was downloaded for personal use only. Unauthorized distribution is strictly prohibited.

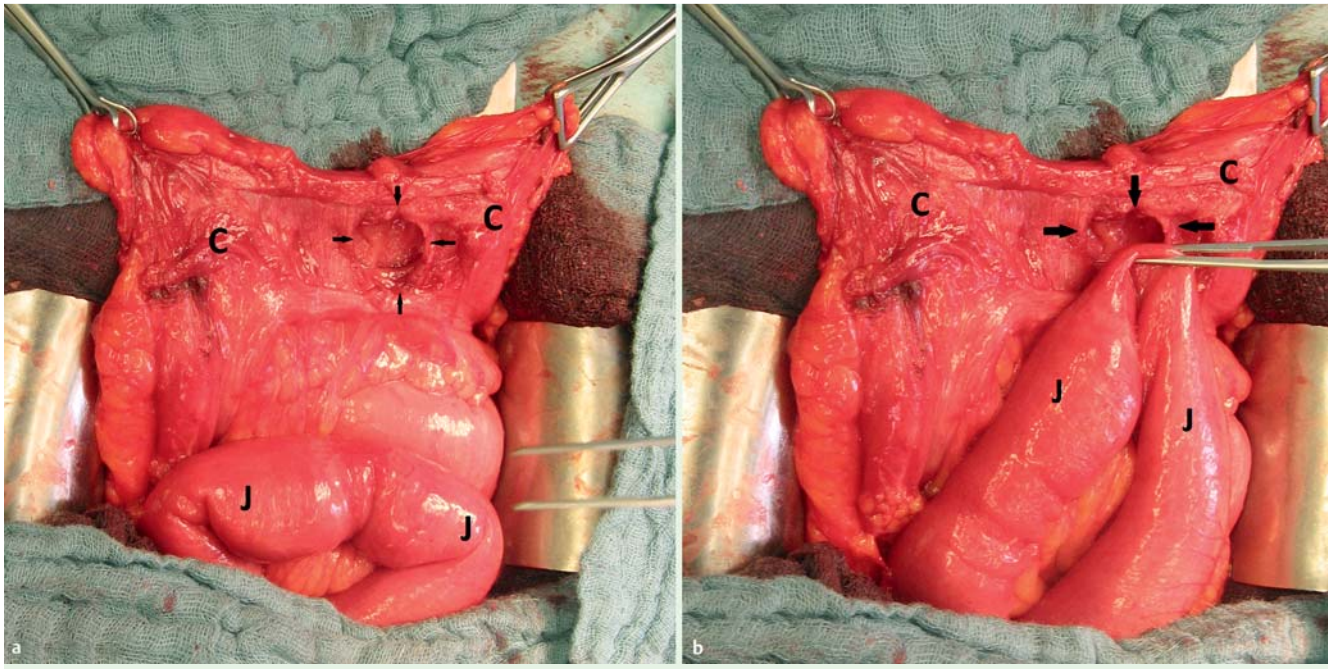

Fig. 3 Repair of the colonic perforation. **a** The perforation (arrows) in the colon (C). **b** Position of the small intestine (J) in relation to the colonic perforation.

Video 1

An attempt to close an iatrogenic colonic perforation using an over-the-scope clip resulted in the small intestine being grasped by the clip.

and the incarcerated small intestine recovered well within minutes (**Fig. 2b**). No transmural defect of the wall was seen, and therefore resection or suturing was not required. In the transverse colon, a defect of 3 cm in diameter was found (**Fig. 3**), relating to the original colonic perforation; the colon segment was resected.

We conclude that use of the OTSC closure technique is limited by the size of the intestinal defect. When a large perforation occurs into the abdominal cavity, caution is required to avoid suctioning the small intestine into the OTSC. Using a twin grasper might be a safer placing technique for OTSCs in this case. Surgical treatment should take place without delay if there is any doubt about the adequacy of a leakage closure, in order to prevent further severe complications.

Endoscopy_UCTN_Code_CPL_1AJ_2AC

Competing interests: None

Gunnar Loske[1], Tobias Schorsch[1], Emmerich Daseking[1], Eckard Martens[2], Christian Theodor Müller[1]

[1] Department for General, Abdominal, Thoracic and Vascular Surgery, Katholisches Marienkrankenhaus Hamburg gGmbH, Hamburg, Germany

[2] Department for Medical Oncology and Hematology, Gastroenterology and Infectious Diseases, Katholisches Marienkrankenhaus Hamburg gGmbH, Hamburg, Germany

References

1 *Mennigen R, Senninger N, Laukoetter MG.* Novel treatment options for perforations of the upper gastrointestinal tract: endoscopic vacuum therapy and over-the-scope clips. World J Gastroenterol 2014; 20: 7767 – 7776

2 *Baron TH, Song LM, Ross A* et al. Use of an over-the-scope clipping device: multicenter retrospective results of the first U.S. experience (with videos). Gastrointest Endosc 2012; 76: 202 – 208

Bibliography

DOI http://dx.doi.org/10.1055/s-0041-110594
Endoscopy 2016; 48: E26–E27
© Georg Thieme Verlag KG
Stuttgart · New York
ISSN 0013-726X

Corresponding author
Gunnar Loske, MD
Department for General, Abdominal, Thoracic and Vascular Surgery
Katholisches Marienkrankenhaus Hamburg gGmbH
Alfredstr. 9
22087 Hamburg
Germany
Fax: +49-40-25461400
Loske.chir@marienkrankenhaus.org

This document was downloaded for personal use only. Unauthorized distribution is strictly prohibited.