

## Endoscopic removal of a nasogastric tube accidentally ligated to the duodenum after open abdominal surgery

A 61-year-old man underwent open abdominal surgery for primary repair of a duodenal perforation. Preoperatively, a nasogastric tube had been inserted into the stomach for decompression. An attempt was made to remove the tube 6 days postoperatively but this was not possible because of marked resistance. Upper gastrointestinal endoscopy revealed that the nasogastric tube and granulation tissue were intertwined with a 3-0 Vicryl suture at the second portion of the duodenum (● Fig. 1 a).

A rat-tooth forceps and snare were used to try to sever the suture; however, the tube was not extirpated. Next, an endoscopic loop cutter (Olympus Medical Systems Corp., Aomori, Japan) was inserted into the side hole of the endoscope and an attempt was made to cut the suture (● Fig. 1 b). This effort was unsuccessful. The loop cutter had to be pulled forcibly while holding the suture, which finally resulted in the stitch being severed. The nasogastric tube was then removed successfully without further complications (● Fig. 1 c). At the 1-week follow-up, the patient exhibited no abnormalities.

Very few cases of a nasogastric tube unintentionally sutured to the gastrointestinal tract have been reported worldwide [1–5]. This is the first reported case of this happening in the duodenum. If resistance is felt when pulling on a nasogastric tube,

the tube should be left intact and endoscopy should be performed to identify the cause, as vigorous attempts to extirpate the tube may result in perforation or severe bleeding.

When the tube is trapped in the anastomotic site, it is safe to perform endoscopic treatment 2 weeks postoperatively [1,3]. However, in our case, endoscopic treatment was performed early and additional force was applied to the loop cutter to cut the tube. Despite this, it was a safe procedure because the tube was trapped in a comparatively intact part of the duodenum. Endoscopic treatment was safe, less expensive, and more convenient. It should be considered a first choice for this complication.

Endoscopy\_UCTN\_Code\_CPL\_1AH\_2AJ

Competing interests: None

**Su Young Kim<sup>1</sup>, Jun-Won Chung<sup>1</sup>, Jun-Young Yang<sup>2</sup>**

<sup>1</sup> Division of Gastroenterology, Department of Internal Medicine, Gachon University, Gil Medical Center, Incheon, South Korea

<sup>2</sup> Department of Surgery, Gachon University, Gil Medical Center, Incheon, South Korea

### References

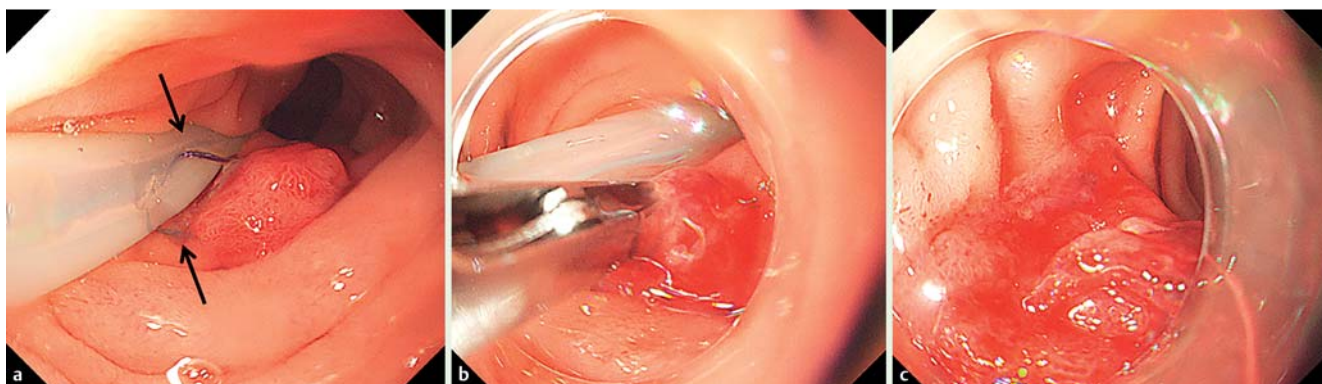
- 1 Chen CN, Lee WJ, Cheng TJ et al. Endoscopic removal of nasogastric tube sutured unintentionally to gastrojejunostomy. *Surg Laparosc Endosc* 1997; 7: 359–360
- 2 Shaaban H, Armstrong C. Nasogastric tube accidentally stitched to the stomach during laparoscopic antireflux surgery. *Endoscopy* 2009; 41 (Suppl. 02): E61
- 3 Han HF, Perng CL, Hung HC et al. Iatrogenic entrapped nasogastric tube with endoscopic removal. *J Clin Gastroenterol* 1999; 29: 103–104
- 4 Wilkinson MN, Jayaraman V, Watkins K et al. Newly developed flexible endoscopic scissors for removal of a nasogastric tube trapped within a gastrojejunal anastomotic staple line. *Endoscopy* 2011; 43 (Suppl. 02): E234–E235
- 5 Mahmood A, Joseph E, Robinson RB et al. The role of endoscopy in nasogastric tube removal following esophageal surgery: a case report. *Int J Surg* 2007; 5: 342–344

### Bibliography

DOI <http://dx.doi.org/10.1055/s-0041-111028>  
 Endoscopy 2016; 48: E18  
 © Georg Thieme Verlag KG  
 Stuttgart · New York  
 ISSN 0013-726X

### Corresponding author

**Jun-Won Chung, MD, PhD**  
 Division of Gastroenterology  
 Department of Internal Medicine  
 Gachon University  
 Gil Medical Center  
 21, Namdong-daero 774beon-gil  
 Namdong-gu  
 Incheon  
 Korea  
 Fax: 82-32-4603408  
[junwonchung@daum.net](mailto:junwonchung@daum.net)



**Fig. 1** Endoscopic views showing: **a** the nasogastric tube fixed by the 3-0 Vicryl suture (arrow) within the duodenum; **b** an endoscopic loop cutter being used in an attempt to extract the nasogastric tube; **c** the duodenum following removal of the nasogastric tube.