

Endoscopic ultrasound-guided hepaticogastrostomy using a 6-F cystotome and 12-cm covered metal stent

Authors

Koichiro Mandai, Koji Uno, Yusuke Okada, Azumi Suzuki, Kenjiro Yasuda

Institution

Department of Gastroenterology, Kyoto Second Red Cross Hospital, 355-5 Haruobi-cho, Kamigyo-ku, Kyoto 602-8026, Japan

submitted 7. October 2015
accepted after revision
15. December 2015

Bibliography

DOI <http://dx.doi.org/10.1055/s-0041-111502>
Published online: 3.3.2016
Endoscopy International Open 2016; 04: E287–E291
© Georg Thieme Verlag KG
Stuttgart · New York
E-ISSN 2196-9736

Corresponding author

Koichiro Mandai

Department of
Gastroenterology
Kyoto Second Red Cross
Hospital
355-5 Haruobi-cho, Kamigyo-ku
Kyoto 602-8026
Japan
Phone: +81-75-231-5171
Fax: +81-75-256-3451
mndkchr@gmail.com

Background and study aims: An increasing number of reports describe endoscopic ultrasound-guided hepaticogastrostomy for malignant biliary obstruction in patients with endoscopic retrograde cholangiopancreatography failure. However, this procedure has not yet been standard-

ized; as a result, the rate of adverse events, including bile leakage and stent migration, is relatively high. Here, we report our experience with four cases of endoscopic ultrasound-guided hepaticogastrostomy performed according to our institutional procedure.

Introduction

Reports have described the increasing use of endoscopic ultrasound-guided hepaticogastrostomy (EUS-HG) to treat malignant biliary obstruction in patients with endoscopic retrograde cholangiopancreatography (ERCP) failure. However, a previous review article noted that despite its high success rate, EUS-HG is associated with a relatively high rate of adverse events [1], which is attributable to the lack of standardized protocols and specialized equipment. Previously at our institution, EUS-HG was performed on three patients using a biliary dilation catheter for hepaticogastric fistula dilation and a 7-cm, straight plastic stent or 8-cm fully covered metal stent. However, in two of the three patients, achieving fistula dilation was time-consuming and the stent migrated into the peritoneal cavity in two of the three patients. Recently, we introduced a 6F cystotome (Cysto Gastro Set; Endo-flex, GmbH, Voerde, Germany) for fistula dilation and an 8-mm, 12-cm covered stent with a 1-cm uncovered portion at the distal, intrahepatic end (bare-end type, Niti-S biliary S-type; TaeWoong Medical, Seoul, Korea) (Fig. 1) for stenting. Here, we present our experience with four cases of EUS-HG in which our institutional procedure (6F cystotome and 8-mm, 12-cm covered metal stent) was used, and evaluate the safety of this procedure.

Case Reports

Between October 2014 and August 2015, we treated four consecutive cases of malignant biliary obstruction via EUS-HG with a 6F cystotome and 8-mm, 12-cm covered metal stent. The indication for EUS-HG was limited to cases with ERCP failure. Procedural consent was obtained from each patient, and the Institutional Review Board granted permission to review the patients' records. The characteristics of these four cases are summarized in Table 1.

All procedures were performed using a convex-type echoendoscope (GF-UCT260; Olympus Medical Systems, Tokyo, Japan) and carbon dioxide insufflator. The left intrahepatic bile duct was punctured from the stomach using a 19G needle (SonoTip; Medi-Globe, Rosenheim, Germany) under Doppler imaging guidance to avoid any intervening arteries or veins. After aspirating the bile juice, a small amount of contrast medium was injected to visualize the biliary tree. Next, a 0.025-in guidewire (VisiGlide; Olympus Medical Systems, Tokyo, Japan) was inserted into the bile duct through a 19G needle, which was subsequently exchanged for an ERCP catheter with a 3.5F tip (PR-V110Q; Olympus Medical Systems, Tokyo, Japan) to avoid guidewire shearing. The guidewire was then advanced into the common or right intrahepatic bile duct, and the fistula was dilated using a 6F cystotome (Cysto Gastro Set); subsequently, an electrosurgical high-frequency generator (ESG-100; Olympus Medical Systems, Tokyo, Japan) with the diathermy current set to the cut mode (90W in pulse-cut slow mode) was

License terms





Fig. 1 Bare-end type Niti-S biliary S-type stent with a 1-cm uncovered portion at the distal end (red arrow); the remaining portion is fully covered.

used. Finally, we placed an 8-mm, 12-cm covered stent with a 1-cm uncovered portion at the distal, intrahepatic end (bare-end type, Niti-S biliary S-type) from the left intrahepatic bile duct to the stomach.

Patient 1

A 71-year-old man presented with a malignant biliary stricture and gastric outlet obstruction due to unresectable advanced gastric cancer, for which he had undergone endoscopic transpapillary biliary drainage (EBD), gastrojejunostomy bypass, and chemotherapy, respectively. He was admitted to our institution with an EBD occlusion. ERCP was attempted to restore the transpapillary biliary drainage, but malignant invasion prevented the passage of a side-viewing endoscope through the antrum of the stomach. Although we could reach the ampulla by passing a single-balloon enteroscope (SBE) through the gastrojejunostomy anastomosis, EBD restoration failed. Therefore, we decided to perform EUS-HG and successfully placed a bare-end type, Niti-S biliary S-type stent from the left intrahepatic bile duct (segment 3: B3) to the stomach (▶ Fig. 2b and ▶ Fig. 2c). The patient experienced post-procedural abdominal pain that was relieved in a few days. He was discharged on day 13 post-EUS-HG. He developed acute cholangitis on day 109 post-EUS-HG for which endoscopic reintervention was not attempted, as his performance status had deteriorated because of cancer progression. He died on day 126 post-EUS-HG.

Patient 2

A 71-year-old man had undergone extrahepatic bile duct resection and choledochojejunostomy for distal cholangiocarcinoma. He was referred to our department 2 months after surgery with obstructive jaundice caused by a malignant stenosis of the afferent loop. EBD using a SBE was attempted, but the endoscope could not be passed through the afferent loop stenosis. Similarly, a guidewire could not be passed through the stenosis, and it was therefore impossible to treat the afferent loop stenosis via balloon dilation or stent placement. Therefore, we decided to perform EUS-HG and successfully placed a bare-end type, Niti-S biliary S-type stent from the left intrahepatic bile duct (segment 3: B3) to the stomach (▶ Fig. 3a–c). The patient did not experience abdominal pain after the procedure and was discharged on day 7 post-EUS-HG. He was readmitted for acute cholangitis on day 32 post-EUS-HG; an esophagogastroduodenoscopy was performed for biliary drainage, and the stent was found to be occluded with biliary sludge. Accordingly, we inserted an endoscope (Q260J; Olympus Medical Systems) in the stent opening and aspirated the sludge, thus restoring the bile flow (▶ Fig. 3d–f). Before the patient died due to cancer progression on day 215 post-EUS-HG, acute cholangitis and stent occlusion due to biliary sludge occurred seven times (every 2–4 weeks) and each time, the same treatment was performed.

Table 1 Patient characteristics

Case	Age (years), Sex	Primary disease	Surgical procedure	Punctured BD	Procedure time (min)	HGS stent		Complication	Stent length in the gastric luminal portion (cm)	FU period after EUS-HGS (days)	Time to stent dysfunction (days)
						Diameter (mm)	Length (cm)				
1	71 M	Gastric cancer	Gastrojejunostomy bypass	B3	29	8	12	Abdominal pain	6.6	126	109
2	71 M	Cholangiocarcinoma	Resection of extrahepatic bile duct, choledochojejunostomy	B3	17	8	12	None	4.6	216	32
3	71 F	Pancreatic cancer	None	B3	35	8	12	None	4.8	146	57
4	91 M	Pancreatic cancer	None	B2	29	8	12	None	3.1	36	–

M, male; F, female; BD, bile duct; HGS, hepaticogastrostomy; FU, follow-up; EUS, endoscopic ultrasound

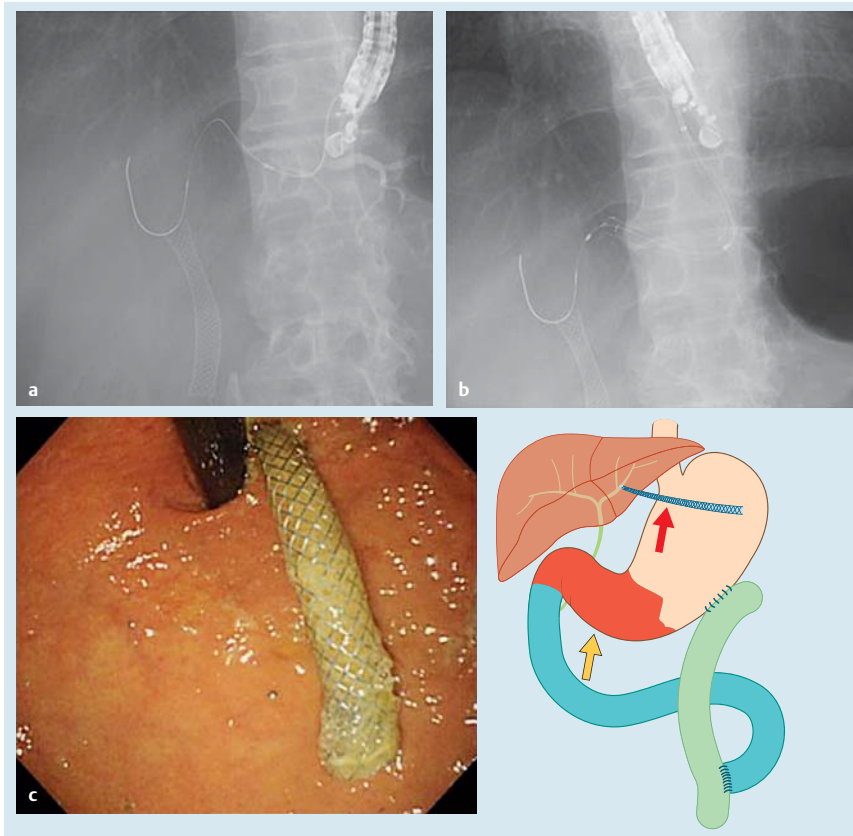


Fig. 2 Fluoroscopic image showing a cystotome over a guidewire inserted into the intrahepatic bile duct. **a** Fluoroscopic image showing a metallic stent placed from the left intrahepatic bile duct to the stomach. **b** Endoscopic image showing protrusion of the metallic stent from the stomach wall. **c** Schema of this case, showing the malignant stenosis (yellow arrow) and the metallic stent (red arrow) placed from the left intrahepatic bile duct to the stomach.

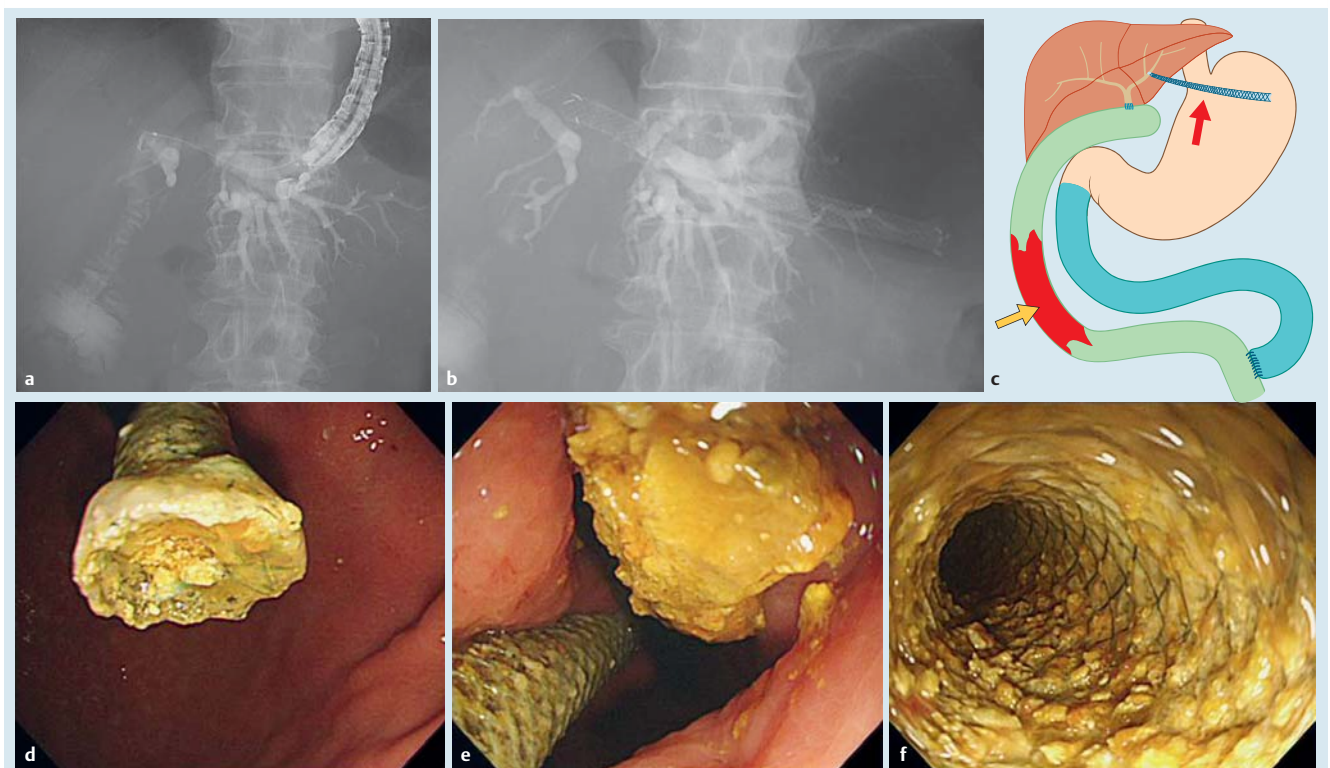


Fig. 3 **a** Fluoroscopic image showing the small intestine through the cholecystojejunoscopy. **b** Fluoroscopic image showing a metallic stent placed from the left intrahepatic bile duct to the stomach. **c** Schema of this case, showing the malignant afferent loop stenosis (yellow arrow) and the metallic stent (red arrow) placed from the left intrahepatic bile duct to the stomach. **d–f** Endoscopic images at the time of reintervention. The stent was occluded by biliary sludge, which was removed. The inside of the stent was cleaned.

Patient 3

A 71-year-old woman presented with malignant duodenal stenosis and biliary stricture resulting from unresectable pancreatic cancer. An EBD for the biliary stricture was impossible because a side-viewing endoscope could not be passed through the duodenal stenosis. Therefore, we placed a duodenal stent (Niti-S Pyloric Duodenal D-type stent; TaeWoong Medical) in the malignant duodenal stenosis and performed EUS-HG for biliary drainage. We successfully placed a bare-end type, Niti-S biliary S-type stent from the left intrahepatic bile duct (segment 3: B3) to the stomach (● Fig. 4). The patient did not experience abdominal pain after the procedure and was discharged on day 8 post-EUS-HG. She was later readmitted for acute cholangitis on day 57 post-EUS-HG. We performed cholangiography by inserting an ERCP catheter (PR-V104Q; Olympus Medical Systems) into the stent using a side-viewing endoscope (JF-260V; Olympus Medical Systems). The cholangiogram revealed sludge within the stent, which we removed using a retrieval balloon catheter (Extractor Pro XL; Boston Scientific Japan, Tokyo, Japan; ● Fig. 4a,b). Despite continued chemotherapy, the patient died of cancer progression on day 146 post-EUS-HG.

Patient 4

A 91-year-old man was admitted to our institution with obstructive jaundice caused by pancreatic cancer. ERCP was initially attempted but failed due to malignant invasion of the duodenum;

accordingly, we decided to perform EUS-HG. Before attempting this procedure, we placed clips on the esophagogastric junction to facilitate recognition under fluoroscopic guidance. We punctured the left intrahepatic bile duct (segment 2: B2) using a 19G needle, and placed a bare-end type, Niti-S biliary S-type stent from the left intrahepatic bile duct (B2) to the stomach (● Fig. 5a–c). The patient did not experience abdominal pain after the procedure and was discharged on day 17 post-EUS-HG. He did not experience stent dysfunction during the follow-up period.

Discussion

As noted in the introduction, a previous review article reported a relatively high rate of adverse events associated with EUS-HG, with an average complication rate of 17.0% [1]. The reported major complications associated with this procedure include cholangitis, bleeding, stent migration, peritonitis, and bile leakage. We believe that smooth fistula dilation is necessary to reduce the risk of intraabdominal bile leakage associated with frequent device exchange and a long procedure time.

At our institution, we have used a 6F cystotome (Cysto Gastro Set) for fistula dilation during EUS-guided biliary drainage since October 2014. This coaxial device is fitted with a guidewire and allows safe and rapid fistula dilation. Other institutions have used a biliary dilation catheter, balloon dilation catheter, and cystotome

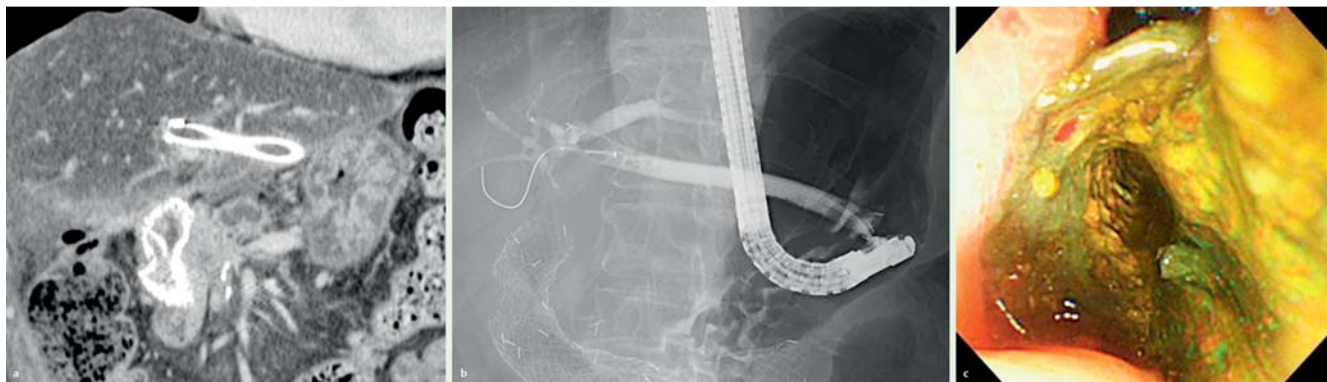

Fig. 4 a Computed tomography showing a duodenal stent in the malignant duodenal stenosis and a biliary stent placed from the left intrahepatic bile duct to the stomach. a. Fluoroscopic image at the time of reintervention. The inside of the stent was cleaned using a retrieval balloon catheter over a guidewire. b. Endoscopic image at the time of reintervention. A large amount of sludge was removed from the inside of the stent.

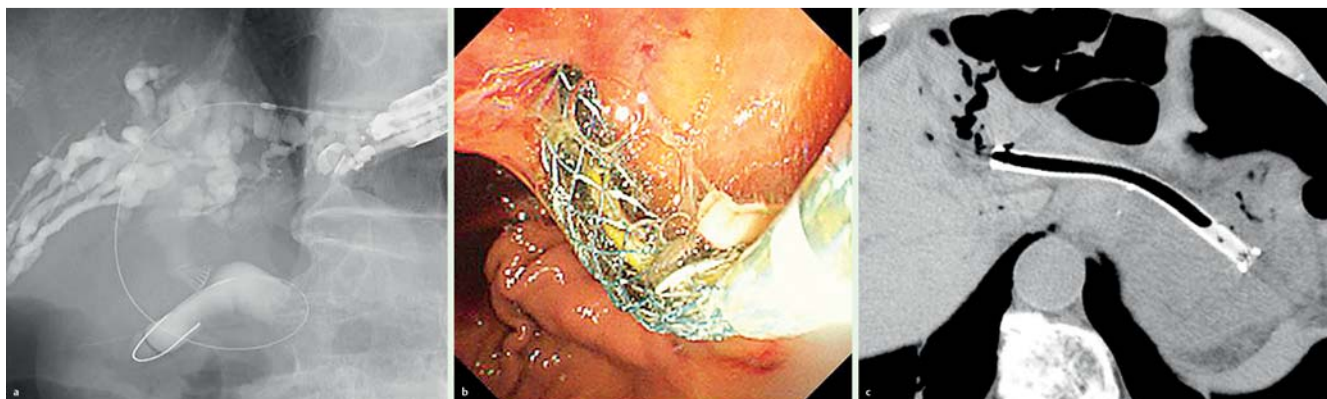


Fig. 5 Fluoroscopic image showing a cystotome over a guidewire inserted into the intrahepatic bile duct. a. Endoscopic image at the time of stent placement, showing a metallic stent protruding from the stomach wall. b. Computed tomography image showing the placement of a metallic stent from the left intrahepatic bile duct to the stomach.

for fistula dilation during EUS-guided biliary drainage, as reported in a Japanese multicenter retrospective study [2]. That retrospective study reported that EUS-guided choledochoduodenostomy was unsuccessful in two patients treated without a cystotome owing to fistula dilation failure, whereas EUS-guided biliary drainage, including EUS-HG, was successful in all cases involving a cystotome. Smooth fistula dilation was possible in all four of our cases; in addition, we achieved a mean procedure time of 27.5 minutes and did not encounter peritonitis due to bile leakage in any of our cases. Recently, another study reported the usefulness of a novel fine-gauge balloon catheter for hepaticogastric fistula dilation [3]. Further studies of safe and useful methods of fistula dilation are required.

According to the literature, the complication of stent migration to the peritoneal cavity may occur in both the early and late post-EUS-HG phases and might lead to a very poor prognosis. The literature describes a case in which a 6-cm covered metallic stent migrated with a fatal outcome, and a case in which an 8-cm covered metallic stent migrated, necessitating surgical treatment [4, 5]. Before incorporating a bare-end type, Niti-S biliary S-type stent, we performed EUS-HG in three patients but two of them experienced stent migration. In one case, a 7-cm straight plastic stent migrated to the peritoneal cavity on day 2 post-EUS-HG, necessitating percutaneous drainage; in the other case, an 8-cm covered metallic stent migrated to the peritoneal cavity during the procedure, necessitating the placement of an additional metallic stent.

From the above literature and our experiences, we believe that 10-cm or longer stents should be used to avoid stent migration. In a recent report, severe complications, including stent migration, did not occur in 12 patients with EUS-HG using a 10-cm or 12-cm bare-end type, Niti-S biliary S-type stent [6]. Although all of those cases also involved EUS-antegrade stenting for biliary stenosis, the report suggests that EUS-HG with a 10-cm or longer metallic stent is safe. We achieved technical success in all cases involving the placement of 12-cm stents, and none of the patients experienced complications such as stent migration. Moreover, a recent report described a significantly shorter median stent patency duration in patients who underwent EUS-HG with a stent length <3 cm in the luminal portion, relative to those with a stent length \geq 3 cm; therefore, we believe that a longer stent should be used for EUS-HG [7]. In all of our cases, the stent length in the luminal portion exceeded 3 cm.

In addition, the diameter of the stent used in EUS-HG remains controversial. In our cases, we used an 8-mm stent to avoid stent dysfunction due to granulation of the hepatic side of the stent, which is caused by intrahepatic bile duct overexpansion. However, the outcomes achieved with this stent diameter should be compared with outcomes following the placement of 6-mm and 10-mm stents.

Only a few reports have described endoscopic reintervention after EUS-HG with a metal stent; these include a case in which the portion of the stent that protruded into the stomach was trimmed using argon plasma coagulation, and a case of hepatico-

gastric fistula in which a metal stent was exchanged while retaining the guidewire and endoscopic nasobiliary drainage tube [8, 9]. Of our four patients, three exhibited stent dysfunction and two underwent endoscopic reintervention (Patients 2 and 3). Successful reintervention was performed by aspirating biliary sludge from the inside of the stent with a conventional endoscope in Patient 2, and by removing sludge with a retrieval balloon catheter and a side-viewing endoscope in Patient 3. In Patient 2, acute cholangitis and stent occlusion due to biliary sludge occurred frequently. Despite the absence of malignant duodenal stenosis, considerable quantities of food were found in the patient's stomach at each endoscopic re-intervention. Delayed gastric emptying was thought to be the cause of frequent stent occlusion, but prokinetic agents were not effective. An anti-reflux covered metal stent was reported to be useful for transpapillary biliary drainage in patients with recurrent biliary metal stent occlusion, and the potential usefulness of this stent type in patients with EUS-HG should be investigated [10].

In summary, our experiences with the cases described here have led us to conclude that EUS-HG with a 6F cystotome and an 8-mm, 12-cm covered metal stent is likely safe; however, further large-scale investigations will be required to confirm our findings.

Competing interests: None

References

- 1 Ikeuchi N, Itoi T. Endoscopic ultrasonography-guided biliary drainage: an alternative to percutaneous transhepatic puncture. *Gastrointest Interv* 2015; 4: 31–39
- 2 Kawakubo K, Isayama H, Kato H et al. Multicenter retrospective study of endoscopic ultrasound-guided biliary drainage for malignant biliary obstruction in Japan. *J Hepatobiliary Pancreat Sci* 2014; 21: 328–334
- 3 Ogura T, Sano T, Onda S et al. Endoscopic ultrasound-guided biliary drainage with a novel fine-gauge balloon catheter: one-step placement technique. *Endoscopy* 2015; 47: E245–E246
- 4 Martins FP, Rossini LG, Ferrari AP. Migration of a covered metallic stent following endoscopic ultrasound-guided hepaticogastrostomy: fatal complication. *Endoscopy* 2010; 42: E126–E127
- 5 Okuno N, Hara K, Mizuno N et al. Stent migration into the peritoneal cavity following endoscopic ultrasound-guided hepaticogastrostomy. *Endoscopy* 2015; 47: E311
- 6 Ogura T, Masuda D, Imoto A et al. EUS-guided hepaticogastrostomy combined with fine-gauge antegrade stenting: a pilot study. *Endoscopy* 2014; 46: 416–421
- 7 Ogura T, Yamamoto K, Sano T et al. Stent length is impact factor associated with stent patency in Endoscopic ultrasound-guided hepaticogastrostomy. *J Gastroenterol Hepatol* 2015; DOI 10.1111/jgh.13021
- 8 Yane K, Katanuma A, Maguchi H et al. Successful re-intervention with metal stent trimming using argon plasma coagulation after endoscopic ultrasound-guided hepaticogastrostomy. *Endoscopy* 2014; 46: E391–E392
- 9 Kawakubo K, Isayama H, Kogure H et al. Exchange of self-expandable metal stent in endoscopic ultrasound-guided hepaticogastrostomy. *Endoscopy* 2012; 44: E311–E312
- 10 Hamada T, Isayama H, Nakai Y et al. Novel antireflux covered metal stent for recurrent occlusion of biliary metal stents: a pilot study. *Dig Endosc* 2014; 26: 264–269