

Gestational and Non-gestational Trophoblastic Disease. Guideline of the DGGG, OEGGG and SGGG (S2k Level, AWMF Registry No. 032/049, December 2015)

Gestationsbedingte und nicht gestationsbedingte Trophoblasterkrankungen.
Leitlinie der DGGG, OEGGG und SGGG (S2k-Level, AWMF-Registernummer 032/049, Dezember 2015)

Authors

C. Tempfer¹, L.-C. Horn², S. Ackermann³, M. W. Beckmann⁴, R. Dittrich⁴, J. Eienkel⁵, A. Günthert⁶, H. Haase⁷, J. Kratzsch⁸, M. C. Kreissl⁹, S. Polterauer¹⁰, A. D. Ebert¹¹, K. T. M. Schneider¹², H. G. Strauss¹³, F. Thiel¹⁴

Affiliations

The affiliations are listed at the end of the article.

Key words

- trophoblastic tumor
- mole
- hydatidiform mole
- human chorionic gonadotropin
- treatment recommendations

Schlüsselwörter

- Trophoblasttumor
- Mole
- Blasenmole
- hCG
- Therapieempfehlung



gynécologie
suisse



Deutsche Version unter:
[www.thieme-connect.de/
ejournals/gebfra](http://www.thieme-connect.de/ejournals/gebfra)

Bibliography

DOI <http://dx.doi.org/10.1055/s-0041-111788>
Geburtsh Frauenheilk 2016; 76: 134–144 © Georg Thieme Verlag KG Stuttgart · New York · ISSN 0016-5751

Correspondence

Prof. Dr. med. Clemens Tempfer, MBA
Universitätsfrauenklinik der Ruhr-Universität Bochum
Marien-Hospital Herne
Hoelkeskampring 40
44625 Herne
clemens.tempfer@rub.de

Abstract



Purpose: The aim was to establish an official interdisciplinary guideline, published and coordinated by the German Society of Gynecology and Obstetrics (DGGG). The guideline was developed for use in German-speaking countries. In addition to the Germany Society of Gynecology and Obstetrics, the guideline has also been approved by the Swiss Society of Gynecology and Obstetrics (SGGG) and the Austrian Society of Gynecology and Obstetrics (OEGGG). The aim was to standardize diagnostic procedures and the management of gestational and non-gestational trophoblastic disease in accordance with the principles of evidence-based medicine, drawing on the current literature and the experience of the colleagues involved in compiling the guideline.

Methods: This s2k guideline represents the consensus of a representative panel of experts with a range of different professional backgrounds commissioned by the DGGG. Following a review of the international literature and international guidelines on trophoblastic tumors, a structural consensus was achieved in a formalized, multi-step procedure. This was done using uniform definitions, objective assessments, and standardized management protocols.

Recommendations: The recommendations of the guideline cover the epidemiology, classification and staging of trophoblastic tumors; the measurement of human chorionic gonadotropin (hCG) levels in serum, and the diagnosis, management, and follow-up of villous trophoblastic tumors (e.g., partial mole, hydatidiform mole, invasive mole) and non-villous trophoblastic tumors (placental site nodule, exaggerated placental site, placental site tumor, epitheloid trophoblastic tumor, and choriocarcinoma).

Zusammenfassung



Ziel: Erstellung einer offiziellen, internationalen, interdisziplinären Leitlinie, publiziert und koordiniert von der Deutschen Gesellschaft für Gynäkologie und Geburtshilfe (DGGG). Die Leitlinie wurde für den deutschsprachigen Raum entwickelt und wird neben der DGGG auch von der Schweizerischen Gesellschaft für Gynäkologie und Geburtshilfe (SGGG) und der Österreichischen Gesellschaft für Gynäkologie und Geburtshilfe (OEGGG) mitgetragen. Ziel der Leitlinie war es, die Diagnostik und Therapie von gestationsbedingten und nicht gestationsbedingten Trophoblasterkrankungen anhand der aktuellen Literatur sowie der Erfahrung der beteiligten Kolleginnen und Kollegen evidenzbasiert zu standardisieren.

Methoden: Anhand der internationalen Literatur und unter Verwendung internationaler Leitlinien zum Thema Trophoblasttumore entwickelten die Mitglieder der beteiligten Fachgesellschaften im Auftrag der Leitlinienkommission der DGGG in einem strukturierten Prozess einen formalen Konsensus. Dies erfolgte unter Verwendung von einheitlichen Definitionen, objektivierte Bewertungsmöglichkeiten und standardisierten Therapieprotokollen.

Empfehlungen: Die Empfehlungen der Leitlinie betreffen die Epidemiologie, Klassifikation und Stadieneinteilung von Trophoblasttumoren, die Bestimmung von humanem Choriongonadotropin (hCG) sowie die Diagnose, Therapie und Nachsorge von villösen Trophoblasttumoren (Partialmole, Blasenmole, invasive Mole) und nicht villösen Trophoblasttumoren (Plazentabett-Knoten, hyperplastische Implantationsstelle, Plazentabett-Tumor, epitheloider Trophoblasttumor und Chorionkarzinom).

Table 1 Authors.

Author Mandate holder	DGGG/DKG working group/professional association/organization/society
Coordinating lead guideline authors:	
Prof. Dr. C. Tempfer, Bochum	German Society of Gynecology and Obstetrics (Deutsche Gesellschaft für Gynäkologie und Geburtshilfe [DGGG])
Prof. Dr. L.-C. Horn, Leipzig	German Society of Pathology (Deutsche Gesellschaft für Pathologie [DGP])
Other participating authors contributing to the guideline	
PD Dr. S. Ackermann, Darmstadt	Gynecological Oncology Working Group (Arbeitsgemeinschaft Gynäkologische Onkologie [AGO])
Prof. Dr. M. W. Beckmann, Erlangen	German Society of Gynecology and Obstetrics (Deutsche Gesellschaft für Gynäkologie und Geburtshilfe [DGGG]) and German Cancer Society (Deutsche Krebsgesellschaft [DKG])
Prof. Dr. R. Dittich, Erlangen	Gynecological Oncology Working Group (Arbeitsgemeinschaft Gynäkologische Onkologie [AGO])
Dr. J. Eienkel, Leipzig	German Society of Gynecology and Obstetrics (Deutsche Gesellschaft für Gynäkologie und Geburtshilfe [DGGG])
Prof. Dr. A. Günthert, Lucerne	Swiss Society of Gynecology and Obstetrics (Schweizerische Gesellschaft für Gynäkologie und Geburtshilfe [SGGG])
Frau H. Haase	Self-help group for women after cancer (Frauenselbsthilfe nach Krebs e.V. [FSH])
Prof. Dr. J. Kratzsch, Leipzig	German Society for Clinical Chemistry and Laboratory Medicine (Deutsche Vereinte Gesellschaft für Klinische Chemie und Laboratoriumsmedizin e.V. [DGKL])
PD Dr. M. Kreissl, Augsburg	German Society of Nuclear Medicine (Deutsche Gesellschaft für Nuklearmedizin [DGN])
PD Dr. S. Polterauer, Vienna	Austrian Society of Obstetrics and Gynecology (Österreichische Gesellschaft für Gynäkologie und Geburtshilfe [OEGGG])
Prof. Dr. med. Dr. phil. Dr. h. c. mult. A. D. Ebert, Berlin	Federal Association of Gynecologists (Berufsverband der Frauenärzte e.V. [BVF])
Prof. Dr. K. T. M. Schneider, Munich	Maternal Fetal Medicine Study Group (AG Materno-fetale Medizin [AGMFM])
Dr. H.-G. Strauss, Halle	Uterus Commission of the Gynecological Oncology Working Group (Arbeitsgemeinschaft Gynäkologische Onkologie [AGO])
PD Dr. F. Thiel, Göppingen	German Society of Gynecology and Obstetrics (Deutsche Gesellschaft für Gynäkologie und Geburtshilfe [DGGG])
External moderator of the formal consensus process:	
Dr. M. Follmann, MPH, MSc.	AWMF-certified guideline adviser; German Cancer Society (Deutsche Krebsgesellschaft [DKG])

I Information about the Guideline

Guidelines program of the DGGG, OEGGG and SGGG

Information on the guidelines program of the DGGG, OEGGG and SGGG is available at the end of the guideline.

Citation format

Gestational and non-gestational trophoblastic disease. Guideline of the DGGG, OEGGG and SGGG (S2k Level, AWMF Registry No. 032/049, December 2015). Geburtsh Frauenheilk 2016; 76: 134–144

Guideline documents

The complete long version and a PowerPoint slide version of this guideline as well as a summary of the conflicts of interest of all the authors is available in German on the homepage of the AWMF: <http://www.awmf.org/leitlinien/detail/II/032-049.html>

Authors

See [Table 1](#).

Abbreviations

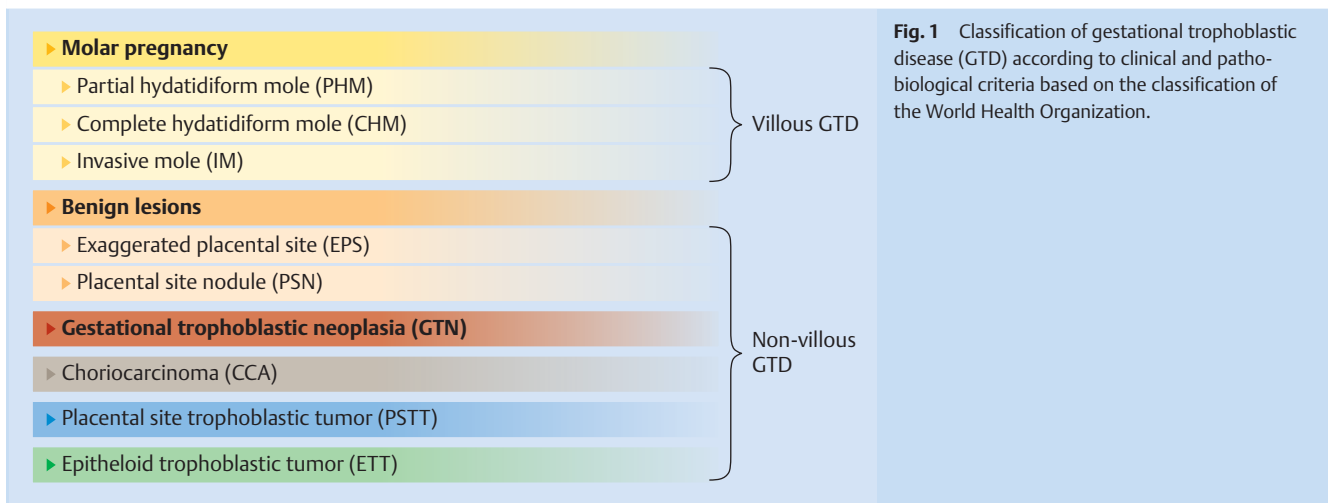
aPSN	atypical placental site nodule
BSA	body surface area
CCA	choriocarcinoma
CT	computed tomography
EPS	exaggerated placental site
ETT	epitheloid trophoblastic tumor
FDG	fluorodesoxyglucose
FIGO	International Federation of Gynecology and Obstetrics
FISH	fluorescence in situ hybridization
GTD	gestational trophoblastic disease
GTN	gestational trophoblastic neoplasia

GW	week of gestation
hCG	human chorionic gonadotropin
HM	hydatidiform mole
HPF	high power field
HPL	human placental lactogen
IM	intramuscular
IUP	intrauterine pessary
IV	intravenous
LH	luteinizing hormone
MRI	magnetic resonance imaging
NGTD	non-gestational trophoblastic disease
PET	positron emission tomography
PM	partial mole
PO	per os, orally
PSN	placental site nodule
PSTT	placental site trophoblastic tumor
TNM	tumor-node-metastasis staging system
UICC	Union internationale contre le cancer
WHO	World Health Organization

II Using this Guideline

Purpose and objectives

Because of the rarity and biological heterogeneity of gestational and non-gestational trophoblastic disease and the widespread uncertainty about what constitutes optimal diagnostic procedures and what is the appropriate management, a guideline which could improve patient care would be useful. The aim of this guideline is therefore to standardize diagnostic procedures and the management of gestational and non-gestational trophoblastic disease according to the principles of evidence-based medicine, using recent literature and the experience of the colleagues involved in compiling this guideline.



Targeted patient care

Outpatient and inpatient care.

Target audience

The recommendations in this guideline are aimed at all physicians (particularly gynecologists, pathologists, radiation therapists, radiologists and nuclear medicine physicians, laboratory physicians and medical oncologists) and other professionals who care for patients with gestational or non-gestational trophoblastic disease. The guideline is also aimed at all women with gestational or non-gestational trophoblastic disease.

Period of validity

The validity of this guideline was confirmed by the boards/responsible persons of the participating professional associations/working groups/organizations/societies, the board of the DGGG and the DGGG Guideline Commission in November and December 2015 and the guideline was thus approved in its entirety. This guideline is valid from January 1, 2016 to December 31, 2018. The guideline can be updated earlier if required, e.g., if studies/data are published that would change clinical practice. If the guideline continues to represent the current state of knowledge, then the guideline's period of validity can be extended.

III Guideline

1 Methodology

During the compilation of this guideline, particular consideration was given to the previous DGGG guideline (Gestational and non-gestational trophoblastic disease; AWM Registry no. 023/049; first compiled and published 01/2007), the recommendations issued by the International Society for the Study of Trophoblastic Disease, the European Organisation for the Treatment of Trophoblastic Disease and the Gynecologic Cancer InterGroup published in 2014 [1], and the recommendations of the European Society for Medical Oncology (ESMO) Guidelines Working Group published in 2013 [2]. In addition, a search for recent evidence-based studies was done using PubMed and the Cochrane Library. This guideline, which already existed in a prior version published in 2007, was adapted to take account of more recent literature and existing international guidelines. No key questions were formulated. As this is an S2k guideline, there was no structured litera-

ture search with an evaluation of the evidence level. No formal methodological evaluation of the studies was carried out. During the compilation of the new guideline, the relevant literature was allocated to the various chapters. A rough draft was then prepared based on the individual chapters, and the draft was edited in a joint preliminary consensus process. Over the course of 3 Delphi rounds, the editors drew up a number of statements and recommendations based on the draft, with recommendations taking the form of clear instructions for action. The revised text was subsequently circulated among all of the members of the guidelines committee. Members proposed various amendments to the text and concluded by approving the final manuscript. During a consensus conference held on September 28, 2015, the statements and recommendations were amended to take account of interdisciplinary issues. At the consensus conference, the statements and recommendations of the guideline were agreed upon following a moderated consensus process and a formal process of coordination. The consent protocol is available on request.

2 Classification and Staging of Gestational Trophoblastic Disease

The term "gestational trophoblastic disease" (GTD) covers a cytogenetically and clinically heterogeneous group of clinical conditions characterized by disordered differentiation and/or the proliferation of trophoblastic epithelium [3]. The morphological classification follows the WHO classification [4]. GTD is differentiated into villous and non-villous GTD according to the presence or absence of chorionic villi (● Fig. 1). Villous and non-villous GTD includes both benign and malignant disease as well as lesions which progress from benign to malignant, for example, persistent postmolar trophoblastic gestational disease. Postoperative staging is based on the current TNM classification and should be performed in all surgically treated cases of malignant GTD (e.g. choriocarcinoma, PSTT, ETT). FIGO staging is optional. Risk stratification of GTD also serves as the basis for any indication for chemotherapy and should be performed according to the most recent FIGO risk scoring system. The FIGO risk scoring system of Ngan et al., published in 2003, was used for this guideline [3] (● Table 2).

Table 2 International Federation of Gynecology and Obstetrics (FIGO) risk scoring system.

	Score			
	0	1	2	4
Age (years)	<40	≥40		
Antecedent pregnancy	MP	abortion	TP	
Interval from last pregnancy and initiation of CHXT (months)	<4	4–6	7–12	>12
hCG (IU/l)	<10 ³	10 ³ –10 ⁴	10 ⁴ –10 ⁵	>10 ⁶
Number of metastases	0	1–4	5–8	>8
Site of metastasis	lung	spleen, kidney	GI tract	brain, liver
Largest tumor diameter (cm)		3–5	>5	
Previous CHXT			monotherapy	combination CHXT

Assessment: 0–6 points → low risk; ≥7 points → high risk; MP = molar pregnancy; TP = term pregnancy; CHXT = chemotherapy; hCG = human chorionic gonadotropin; GI = gastrointestinal

3 Epidemiology of GTD

The reported incidence of hydatidiform mole in developed countries is 1 per 591 pregnancies [5], with an incidence of GTD of 1 per 714 live births [6]. The incidence of GTD increases with age and is correlated with ethnicity [7]. The incidence for Asian women is double that reported for women of Caucasian descent [8]. Moreover, the course of disease also appears to differ depending on maternal ethnicity. In a retrospective cohort study of 316 women with GTD, the percentage of Asian women requiring second-line chemotherapy was significantly higher compared to Caucasian and Afro-American women, and Asian women also required significantly more chemotherapy cycles until remission was achieved [9].

4 Determination of Human Chorionic Gonadotropin (hCG)

Apart from the histological proof of trophoblastic disease, determination of serum hCG levels is the most important aspect influencing the choice and duration of therapy; serum hCG is also used to assess the efficacy of treatment. In clinical practice, the hCG level may, in many cases, be the only tangible parameter indicating trophoblastic disease. As trophoblastic tumors produce different forms of hCG, precise determination of hCG levels is clinically very important. When measuring hCG levels, it is important to use an assay that cross-reacts strongly with the following six irregular forms of hCG specifically produced by GTD: hyperglycosylated hCG, nicked hyperglycosylated hCG, nicked hyperglycosylated hCG without the C-terminal peptide, free beta hCG, nicked free beta-hCG and beta-core fragment.

Because the cross-reactivity of commercially available hCG assays with GTD-relevant isoforms, fragments, and breakdown products of the hCG molecule varies greatly, users may not understand how the result of an assay was achieved, and results may be contradictory [10–12]. It is therefore important to use only those hCG assays which have been successfully validated or used in prior clinical trials for diagnosis and to monitor therapy [13–15]. The results of retrospective studies into false-positive hCG results should also be considered when choosing the assay [16].

The following approaches are suggested if there is a suspicion that results for hCG levels may be false-positive:

1. Test the linearity of hCG results by diluting the sample,
2. Parallel determination of hCG in serum and urine,
3. Send the sample to a second laboratory which uses another appropriate assay to determine hCG to confirm the result.

5 Partial Mole

Cytogenetically more than 90% of cases are triploid in origin (69XXX, 69XXY, 69XYY), two thirds of the genome are paternally derived and only one third from the mother. Partial moles are therefore also referred to as androgenetic in origin [17, 18]. On ultrasound, findings include an enlarged placenta with grape-like clusters of villi. Serum hCG may be elevated. Embryonic or fetal development may be present but accompanied by malformations of varying severity. It is rare for a fetus to achieve viability. To avoid confusion with hydatidiform mole the diagnostic term “partial hydatidiform mole” should not be used, as there are significant differences in terms of cytogenetics and prognosis.

The goal of treatment for partial mole is the complete evacuation of trophoblastic material from the uterine cavity. Suction curettage performed under ultrasound control is done to evacuate trophoblastic material from the uterine cavity. Because of the increased risk of bleeding, units of red blood cell concentrate should be on hand during curettage of a partial mole. Because of the risk of developing persistent GTD (0.5–2%), regular weekly testing of serum hCG should be done after a partial mole has been diagnosed until the results for hCG are negative (i.e. until hCG is below the limit of detection in at least two consecutive tests). If hCG levels are negative and hCG has not been detected in at least two consecutive tests, the probability of persistent postmolar trophoblastic disease is less than 1 : 3000 [1]. This means that additional monthly determination of hCG levels in the patient with partial mole is no longer required.

6 Hydatidiform Mole (Complete Mole)

Cytogenetically the majority of hydatidiform moles have a 46,XX set of chromosomes [19]. A non-viable ovum with no maternal chromosomes is fertilized by a sperm, followed by duplication of the paternal genome (androgenetic origin). **Table 3** shows the most important clinical and pathological characteristics for the differential diagnosis of partial mole and hydatidiform mole (complete mole).

Ultrasound imaging shows an enlarged uterus with cystic structures but no fetus. Serum and urine hCG levels are usually significantly elevated, which can lead to hyperemesis, hyperthyroidism or symptoms of preeclampsia. Ovarian theca lutein cysts are present in around 30% of cases.

The goal of treatment for hydatidiform mole is complete evacuation of all trophoblastic material from the uterine cavity. Evacuation of trophoblastic material from the uterine cavity is done by suction curettage under ultrasound control.

Table 3 Clinical and pathological characteristics of partial mole and hydatidiform (complete) mole.

Characteristics	Partial mole	Hydatidiform mole
Symptoms	missed abortion embryonic/fetal malformations	vaginal bleeding absence of an embryo/fetus
Macroscopy	individual vesicles, large placenta	grossly evident hydropic villi, villous vesicles
Embryonic/fetal tissue	yes, with/without malformations	absent
Microscopy		
Stromal edema	mild, focal	pronounced, diffuse
Villi	stem villi	all/many villi ¹
Trophoblastic hyperplasia	focal, mild	severe, possibly circumferential
Trophoblastic atypia	none/mild	severe
p57 ^{KIP2} /PHLDA2	positive ²	negative ³
Karyotype	usually triploid, biparental	diploid (usually 46,XX), for the most part uniparental; paternally derived
Clinical picture		
Size of the uterus	usually normal	usually enlarged
Ultrasonography	occasional placental cysts	"snow storm"
Ovarian theca lutein cysts	unusual	not rare
hCG level	not usually elevated	usually significantly elevated
Persistent GTD	rare (0.02–5%)	around 25%

¹ may be absent or may not be appreciable in early hydatidiform mole

² > 25%

³ may be positive in very rare cases

It is not clear whether prostaglandin priming affects the prognosis and the risk of developing subsequent GTN. In a case-control study of 291 patients, prostaglandin priming was not found to be associated with an increased risk of subsequent GTN and chemotherapy [20]. Medical methods of evacuating the uterus may be associated with an increased risk of GTN and a subsequent need for chemotherapy [21, 22]. Weekly monitoring of hCG levels is needed after curettage to treat hydatidiform mole. Once hCG levels are found to be negative (i.e., at least two consecutive hCG measurements are under the detection level of the respective assay), monthly monitoring of hCG levels should be continued for at least 6 months after curettage. Oral contraceptives should be used for hormonal contraception in this period. If hCG levels of up to 1500 IU/l persist, re-curettage of trophoblastic tissue which has remained in utero may be indicated and could avoid the necessity for chemotherapy in some patients. Prophylactic chemotherapy after curettage of hydatidiform mole should not be administered if hCG levels are decreasing or are negative.

The following criteria are used for a diagnosis of persistent villous GTD (persistent postmolar trophoblastic disease):

1. Four or more consecutive hCG tests with results showing that hCG have plateaued (defined as < 10% change compared to the prior measurement) over a period of at least 3 weeks (e.g. on days 0, 7, 14, 21).
2. An increase in hCG levels by at least 10% compared to the prior measurement over a period of 2 weeks or a continual increase over at least 3 consecutive measurements done in the last 2 weeks (e.g. on days 0, 7, 14).
3. Persistent hCG levels over a period of 6 months.

The incidence of persistent trophoblastic disease after hydatidiform mole reported in the literature ranges between 19 and 23% [23]. If the measured hCG levels meet the criteria for persistent villous GTD, the following diagnostic imaging procedures should be carried out in addition to gynecological examination with palpation to detect or exclude metastasis: CT of the thorax and the abdomen, transvaginal ultrasound, MRI of the brain. If

Table 4 Chemotherapy regimen for persistent postmolar trophoblastic disease in patients with low International Federation of Gynecology and Obstetrics (FIGO) risk score.

▶ MTX 8-day regimen (50 mg total dose IM on days 1, 3, 5, 7 with folate 15 mg PO 24–30 hours after MTX on days 2, 4, 6, 8), repeated every 14 days
▶ MTX regimen as above, with the dose of 1 mg/kg adjusted for body weight
▶ MTX 30 mg/m ² BSA IM per week
▶ MTX 0.4 mg/kg body weight (maximum 25 mg/day) IV daily on days 1–5, repeated every 14 days
▶ AD 1.25 mg/m ² BSA IV every 2 weeks
▶ AD 0.5 mg IV on days 1–5, repeated every 14 days
▶ AD 10 µg/kg IV on days 1–5, repeated every 14 days

MTX = methotrexate; AD = actinomycin D; IM = intramuscular; BSA = body surface area; IV = intravenous, PO = oral

there is suspicion of metastasis, an FDG-PET/CT may be carried out.

6.1 Management of persistent villous GTD

6.1.1 Low-risk patients

Chemotherapy is indicated for patient with a diagnosis of persistent villous GTD. The drug of choice for **low-risk patients** (FIGO score < 7; cf. ● Table 2) is **methotrexate** 50 mg administered by intramuscular (IM) injection on days 1, 3, 5, 7 together with folate 15 mg administered PO on days 2, 4, 6 (cf. ● Table 4). If the patient develops methotrexate resistance (increase or plateauing of hCG levels) the patient should be switched to **actinomycin D** therapy or polychemotherapy (● Tables 4 and 5).

The following criteria should be used to diagnose **methotrexate resistance**:

- ▶ Four or more consecutive measurements showing a plateauing of hCG levels (defined as < 10% change to the previously measured level) over a period of at least 3 weeks (e.g. measured on days 0, 7, 14, 21).

Table 5 Chemotherapy regimen for persistent postmolar trophoblastic disease in patients with high International Federation of Gynecology and Obstetrics (FIGO) risk score.

EMA/CO regimen
Day 1: AD 0.5 mg IV; etoposide 100 mg/m ² IV; MTX 300 mg/m ² IV
Day 2: AD 0.5 mg IV; etoposide 100 mg/m ² IV; folate 15 mg PO every 12 hours × 4
Day 8: vincristine 0.8 mg/m ² IV or 1 mg/m ² IV (maximum 2 mg/m ² IV); cyclophosphamide 600 mg/m ² IV
Repeat every 14 days
If brain metastases are present: increase MTX dose on day 1 to 1 g/m ² ; increase folate dose to 30 mg; additionally on day 8: MTX 12.5 mg intrathecal
EP-EMA regimen
Day 1: etoposide 150 mg/m ² IV over 30 minutes; cisplatin 75 mg/m ² IV (3 × 25 mg over 4 hours each time)
Day 8: etoposide 150 mg/m ² IV over 30 minutes; MTX 300 mg/m ² IV over 12 hours; AD 0.5 mg IV (bolus)
Day 9–10: folate 4 × 15 mg PO every 12 hours (start: 24 hours after MTX)
Repeat every 14 days
EMA-EP regimen
Day 1: etoposide 100 mg/m ² IV; MTX 300 mg/m ² IV; AD 0.5 mg IV
Day 2: folate 15 mg PO every 12 hours × 4 (start: 24 hours after MTX)
Day 8: etoposide 150 mg/m ² IV; cisplatin 75 mg/m ² IV
Repeat every 14 days
BEP regimen
Day 1 and Day 8: bleomycin 30 mg IV (Bolus)
Days 1 to 5: etoposide 100 mg/m ² IV (over 30 minutes); cisplatin 20 mg/m ² IV over 1 hour + hydration
Repeat every 21 days

MTX = methotrexate; AD = actinomycin D; IM = intramuscular; IV = intravenous; PO = oral

- ▶ An increase in hCG levels of at least 10% compared to the previously measured level over a period of 2 weeks or a continuous increase over at least 3 consecutive measurements carried out over a period of 2 weeks (e.g. measured on days 0, 7, 14).

If treatment consists of monochemotherapy, the patient should receive 3 more consolidation cycles after hCG levels are no longer detectable (at least three consecutive weekly measurements of hCG where hCG levels are below the detection limit of the assay used). In a retrospective comparison of two versus three MTX consolidation cycles administered after hCG levels had dropped below the detection limit in 351 Dutch and 600 British patients with persistent postmolar trophoblastic disease, chemotherapy resistance rates were 8.4% for patients who had received two consolidation cycles and 4% for patients who had received three consolidation cycles [24].

If hCG levels remain negative after completion of chemotherapy (at least three consecutive weekly measurements of hCG with hCG levels below the detection limit of the assay used), hCG levels should be monitored and hCG measured once a month for one year.

In patients with chemotherapy resistance, re-staging will be necessary to search for metastasis and must include gynecological examination with palpation, transvaginal ultrasound, CT of the thorax and abdomen and MRI of the brain. If there is suspicion of metastasis, an FDG-PET/CT may be carried out. If the EMA/CO regimen fails, patients should be switched to a platinum-based (EP-EMA or BEP) regimen (Table 5).

6.1.2 High-risk patients

High-risk patients (FIGO score ≥ 7; Table 3) should receive chemotherapy according to the **EMA/CO** regimen (Table 5). Induction chemotherapy with 1 to 3 cycles of etoposide 100 mg/m² on days 1, 2 and cisplatin 20 mg/m² on day 1, 2 Q7 can reduce early (<4 weeks after initiation of therapy) hemorrhage-related mortality in high-risk patients with FIGO score > 12. In a retrospective comparative study of 291 patients with high-risk GTD, induction chemotherapy with etoposide/cisplatin followed by an EMA/CO regimen was found to reduce the rate of early deaths from 7% (11/151) to 0.7% (1/140) [25].

Measurement of hCG levels should be done prior to starting every cycle in patients treated with the EMA/CO regimen. If hCG levels plateau or increase, patients should be switched to multi-agent therapy with EMA-EP or BEP. Chemotherapy should be continued until hCG levels are negative (at least three consecutive weekly measurements of hCG with hCG levels below the detection limit of the assay used). Incomplete chemotherapy increases the risk of therapy resistance. Once hCG levels are negative, patients should receive up to three additional cycles of EMA/CO as consolidation chemotherapy. Consolidation cycles are not recommended for patients given EMA-EP or BEP chemotherapy. In patients with chemotherapy resistance, re-staging will be necessary to search for metastasis and must include gynecological examination with palpation, transvaginal ultrasound, CT of the thorax and abdomen, and MRI of the brain. An FDG-PET/CT should be carried out if there is a suspicion of metastasis based on imaging findings. If hCG levels are negative (at least three consecutive weekly measurements of hCG with hCG levels below the detection limit of the assay used) after the completion of therapy, hCG levels should be monitored for one year and hCG measured every month. Hormonal contraception is indicated during this period.

Reproductive outcomes after hydatidiform mole with or without chemotherapy do not differ from the pregnancy outcomes reported for the general population. With the exception of a slightly increased risk of stillbirth (incidence 1.3%) and a possibly increased risk of early miscarriage, pregnancy outcomes after GTD or persistent trophoblastic disease and successful chemotherapy are similar to those of the general population [26,27].

7 Invasive Mole

Invasive mole is confirmed by the presence of chorionic villi and a morphological diagnosis of hydatidiform mole within the myometrium, the lymphatics or blood vessels or, in rare cases, in extrauterine sites such as the vagina or lungs after vascular spread. Clinical manifestations of invasive mole include persistent or increasing hCG levels. Findings suspicious for invasive mole on vaginal ultrasound include evidence of internal hemorrhage or echo-dense areas in the myometrium. Theca lutein cysts can also be present. Staging is based on CT of the thorax and abdomen, MRI of the brain, transvaginal ultrasound and gynecological examination with palpation. If there is suspicion of metastasis, an FDG-PET/CT may be carried out. Chemotherapy is required to treat invasive mole. The drug of choice for **low-risk patients** (FIGO score < 7; Table 3) is **methotrexate** 50 mg IM on days 1, 3, 5, 7 and folate 15 mg PO on days 2, 4, 6. **High-risk patients** (FIGO score ≥ 7) should be treated with the **EMA/CO** regimen. Chemotherapy is not required for low-risk patients who have undergone hysterectomy. Monitoring of hCG levels during and after treatment should be done according to the same standards used for hydatidiform mole.

8 Non-villous GTD

8.1 Placental site nodules (PSN)

Placental site nodules and placental site plaque present as nodular or plaque-like lesions of the intermediate trophoblast; they are usually found incidentally in curettage material or hysterectomy specimens. In around 50% of cases, PSN are associated with dysfunctional bleeding [28]. PSN can occur following miscarriage, abortion, term pregnancy or extrauterine pregnancy at varying intervals after a prior pregnancy (up to > 7 years). Cases of PSN have also been reported in postmenopausal women. Curettage, usually consisting of complete removal of the lesion, is the treatment of choice. PSN is a benign lesion. Follow-up based on measurement of hCG levels is not necessary.

8.2 Exaggerated placental site (EPS)

In the older literature, exaggerated placental site is also referred to as syncytial endometritis. EPS is described as a hyperproliferation of the intermediate trophoblast around the placental implantation site. The prevalence of EPS in miscarriages in the 1st trimester of pregnancy is reported to be 1.6% [29]. EPS is usually found incidentally and can occur after birth, miscarriage, abortion or in the context of extrauterine pregnancy. There is no macroscopic evidence of tumor formation. EPS is often found in combination with hydatidiform mole. In this case, the increased risk of persistent trophoblastic disease results from trophoblastic proliferation of the hydatidiform mole.

In biopsies or on examination of curettage material EPS may be mistakenly interpreted as choriocarcinoma or PSTT [30, 31]. Proof or exclusion of a tumorous lesion, measurement of serum hCG levels and immunohistochemical examination are useful for the differential diagnosis. There are currently no molecular or pathological indications which support the suggestion that EPS may represent a precursor lesion of PSTT [32].

Isolated EPS without hydatidiform mole does not require chemotherapy. Postoperative monitoring of hCG levels should only be done for clinical indications such as persistent vaginal bleeding. If hCG levels persist after EPS, they will need to be investigated. In most cases they are caused by residual trophoblastic cells which can be removed by re-curettage.

8.3 Placental site trophoblastic tumor (PSTT)

PSTT account for 2% of GTD [33]. Histologically PSTT are a proliferation of intermediate trophoblasts at the placental implantation site (also known as implantation site intermediate trophoblast), which in the majority of cases are accompanied by a clinically detectable tumor. PSTT is a disease which occurs in women of reproductive age; the mean patient age is 30 years but PSTT can occur in women with a wide age range (from 19 to 62 years). Symptoms are acyclic bleeding or amenorrhea. The uterus is enlarged in around one quarter of patients and around 80% of patients have elevated hCG levels between 1000 and 2000 IU/l.

Most cases appear after miscarriage or unremarkable pregnancy. Only 5–8% of patients with PSTT have a history of hydatidiform mole, in sharp contrast to choriocarcinoma which, in more than 50% of cases, is preceded by hydatidiform mole. The mean interval between PSTT and antecedent pregnancy is 3 years but can be as much as 18 years [28]. PSTTs are usually benign lesions; however, 10–15% of cases are clinically malignant and are associated with a mortality rate of up to 20%. A lengthy interval since the last pregnancy has been proposed as an unfavorable prognostic factor [34].

Assessment of malignancy in PSTT is challenging. Parameters which could serve as indicators for a malignant behaviour include [28, 33–36]:

- ▶ tumor growth extending beyond the uterus,
- ▶ high-grade nuclear and cellular polymorphism,
- ▶ (extensive) coagulative necrosis,
- ▶ destructive growth,
- ▶ deep myometrial infiltration,
- ▶ evidence of trophoblastic cells with clear cytoplasm,
- ▶ > 5 mitotic figures per 10 HPF, and
- ▶ high proliferative activity (Ki-67 labeling index) of more than 50%.

After a diagnosis of PSTT is made based on the curettage specimen, simple hysterectomy is the treatment of choice. The following diagnostic imaging procedures should be carried out to detect or exclude metastasis in addition to gynecological examination with palpation: CT of the thorax and abdomen, transvaginal ultrasound, MRI of the brain. If there is suspicion of metastasis, an FDG-PET/CT may be carried out.

Chemotherapy is required to treat FIGO stages II to IV and should consist of either the EMA/CO or EP-EMA regimen. The BEP regimen is appropriate if the EMA/CO and EP-EMA regimens are unsuccessful.

Because of the limited data, the prognosis for PSTT is difficult. The mortality rate reported in a recent review of 137 published cases with PSTT was 16% [37]. A retrospective cohort study of 35550 women diagnosed between 1976 and 2006 with trophoblastic disease included 62 women with PSTT [38]. Patients with FIGO stage I disease had a 10-year survival rate of 90% and did not benefit from adjuvant chemotherapy. The 10-year survival rate of patients with FIGO stage II disease was only 52% and was similar to the 10-year survival rates of patients with FIGO stages III–IV disease (49%). Patients with FIGO stage II–IV disease underwent adjuvant chemotherapy. The most important prognostic factor was the interval since the last pregnancy. In all patients who died from underlying disease the interval since the last pregnancy was ≥ 48 months. Feltmate et al. reported on 13 hysterectomized patients with PSTT, eight of whom received adjuvant chemotherapy. Only one of the four patients who received chemotherapy within one week of surgery developed recurrence, while all four patients who only started chemotherapy ≥ 3 weeks after surgery developed recurrence [34]. These data indicate that adjuvant chemotherapy should be administered soon after surgery.

If serum hCG levels are negative after the completion of chemotherapy (at least three consecutive weekly measurements of hCG where hCG levels are below the detection limit of the assay used), hCG levels should be monitored for one year and serum hCG measured every month.

8.4 Epithelioid trophoblastic tumor (ETT)

ETT, which accounts for only 1.4% of all GTD, is a rare but distinct gestational trophoblastic entity derived from intermediate trophoblastic cells. Only 108 cases have been published to date [39]. ETT is considered a neoplasm composed of chorionic-type intermediate trophoblasts [40]. Histologically ETT is a well-circumscribed lesion with a pushing border and presents as a monomorphic population of mononuclear trophoblastic cells with abundant eosinophilic cytoplasm and geographic necrosis with eosinophilic hyalinized material. The small blood vessels in the tumor cell nests surrounded by hyaline necrosis preserve their regular architecture.

ETT usually occurs in women of reproductive age. The antecedent pregnancy is unremarkable in 67% of patients, and the interval to the antecedent pregnancy ranged from 1 to 18 years [41]. Common symptoms include dysfunctional bleeding with indications of tumor growth and enlarged uterus. Serum hCG levels are almost always slightly elevated (<2500 IU/l). Based on their analysis of the literature, Zhang et al. found that in 26/58 cases ETT was located in the lower uterine segment or endocervix [42]. In 6 cases reported in the literature, ETT was initially misdiagnosed as a squamous cell carcinoma. Up to 40% of patients with ETT present with extrauterine spread at diagnosis. These cases generally have a malignant course with a high mortality rate [39]. The lungs are the most common site of metastasis from ETT [42]. Like PSTT, ETT responds poorly to chemotherapy [39,42]. The goal of treatment must therefore be complete surgical removal. A long interval since the previous pregnancy is an unfavorable prognostic factor. The treatment of choice is hysterectomy. As with PSTT, polychemotherapy is indicated if metastasis is present at the initial diagnosis of ETT. If serum hCG levels are negative after the completion of chemotherapy (at least three consecutive weekly measurements of hCG where hCG levels are below the detection limit of the assay used), serum hCG levels should be monitored for one year with hCG measured every month.

8.5 Choriocarcinoma

Choriocarcinoma, also known as chorioepithelioma, is characterized by a proliferation of cytotrophoblasts and syncytiotrophoblasts and extensive angioinvasion. Symptoms include dysfunctional vaginal bleeding. The diagnosis of choriocarcinoma is based on the curettage specimen. Measured hCG is usually over 100 000 U/l. Elevated hCG levels can result in unspecified symptoms such as those listed for hydatidiform mole. In more than 50% of cases choriocarcinoma is preceded by hydatidiform mole. However, choriocarcinoma has also been reported after miscarriage, term pregnancy and, in rare cases, after extrauterine pregnancy [43]. In 2.5% of cases, particularly after a prior unremarkable pregnancy or a miscarriage, the initial diagnosis is not based on clinical findings but is made subsequent to the resection of metastasis. As with hydatidiform mole, suction curettage under ultrasound control should be performed if there is a suspicion of choriocarcinoma.

Extensive hemorrhage is common, along with a high risk of perforation. Primary hysterectomy is not recommended, as the intraoperative manipulation of the uterus during surgery is associated with hematogenous dissemination of tumor cells, which can lead to pulmonary metastasis [44]. Hysterectomy is usually indicated for serious, life-threatening hemorrhage.

Staging after **histological confirmation** of choriocarcinoma is done based on gynecological examination with palpation, transvaginal ultrasound, CT of the thorax and abdomen, and MRI of the brain. If there is suspicion of metastasis, an FDG-PET/CT may be carried out.

8.5.1 Low-risk patients

Chemotherapy is indicated after **histological confirmation** of choriocarcinoma. The regimen of choice for **low-risk patients** (FIGO score < 7; cf. **Table 3**) is **methotrexate** 50 mg IM on days 1, 3, 5, 7 and folate 15 mg PO on days 2, 4, 6. If the patient develops methotrexate resistance (increased or plateauing of hCG levels – see below for definition) the patient should be switched to **actinomycin D** therapy or polychemotherapy.

In a retrospective cohort study of 65 women with low-risk choriocarcinoma Taylor et al. reported a spontaneous normalization

of hCG levels without adjuvant chemotherapy in 24/65 patients [45]. Some of their patients had intramural or intraplacental choriocarcinoma or unclear histology. The study showed that selected patients with choriocarcinoma do not require chemotherapy. Nevertheless, the authors of the study recommended that, in principle, low-risk patients with choriocarcinoma should receive MTX monotherapy.

8.5.2 High-risk patients

Treatment of **high-risk patients** (FIGO score ≥ 7 ; **Table 3**) should consist of the **EMA/CO** combination regimen (**Table 5**). Induction chemotherapy with 1 to 3 cycles of etoposide 100 mg/m² on days 1, 2, Q7 and cisplatin 20 mg/m² on days 1, 2, Q7 can reduce early (< 4 weeks after initiation of therapy) hemorrhage-related mortality in high-risk patients with WHO score > 12 (**Table 3**). Chemotherapy should be continued until serum hCG levels are negative (at least three weekly measurements of hCG where hCG levels are below the detection limit of the assay used). Incomplete chemotherapy increases the risk of treatment resistance. Once hCG levels are negative, patients should receive up to three additional EMA/CO cycles as consolidation chemotherapy. Consolidation cycles are not required for EMA-EP or BEP chemotherapy.

After completing chemotherapy, serum hCG should be monitored with monthly measurements of hCG levels for one year.

9 Surgery

Surgery plays an important role in primary therapy and consists of suction curettage for partial mole and hydatidiform mole and hysterectomy for ETT or PSTT. Caution is advised when proposing surgery for patients with recurrence.

The confirmation of residual lesions after patients have completed chemotherapy for low-risk GTD does not have a predictive value for progression or rate of recurrence [46]. A comparison of 901 patients with postmolar trophoblastic persistence and complete remission (serum hCG is negative; no residual lesions found on imaging) and 135 patients with postmolar trophoblastic persistence and partial remission (serum hCG is negative; detectable residual lesions on imaging) showed no significant differences with regard to rates of recurrence and progression. In 46/135 patients, the residual lesion spontaneously decreased or disappeared completely during follow-up. In 83 cases the residual lesion remained the same. Only 6 cases had progression of disease. Surgical resection of residual foci found only on imaging is therefore not useful for most patients with low-risk GTD. It is possible that patients with residual lesions confirmed by biopsy might benefit more from surgical resection, but this has not yet been verified.

Emergency surgery to treat hemorrhagic complications of metastasis has been described in the literature and can save lives in individual cases; surgery can therefore be an alternative to selective vascular embolization in selected cases [1, 47].

Hysterectomy can be discussed for patients with GTD who do not plan to have more children, as hysterectomy may reduce the likelihood of the patient requiring chemotherapy for persistent trophoblastic disease.

Surgical resection of individual residual lesions in patients with chemo-resistant disease can be done in selected patients [2, 48]. There are currently no studies with larger case numbers to investigate this issue, meaning that the benefits of this procedure are unclear.

10 Special Cases

10.1 Multiple pregnancies and GTD

Multiple pregnancies and GTD with one healthy twin have been described in the literature. In a series of 77 cases with hydatidiform mole and one healthy twin, the pregnancy was terminated in 24 cases [49]. Of the 53 women who continued their pregnancy, 23 had a spontaneous miscarriage and two developed severe pre-eclampsia with subsequent termination of pregnancy. Twenty-four of the remaining 28 women had a live birth. Irrespective of the pregnancy outcome, 15/77 women had subsequent chemotherapy for persistent trophoblastic disease.

10.2 Atypical PSN

Atypical PSN (aPSN) is a rare variant of PSN. The term is used to describe a lesion where it is not possible to make a clear morphological distinction between PSN and ETT. Proposed criteria for aPSN are a diameter of more than 0.4 cm, higher cellularity, a compact growth pattern, poorly circumscribed borders and a higher Ki-67 labeling index [40, 50]. Because of its extreme rarity the experience with aPSN is limited. Kaur et al. described 21 cases of an aPSN, with 3/21 patients diagnosed with malignant trophoblastic neoplasm concomitant to aPSN or found at follow up [51]. The authors therefore recommend a thorough clinical and imaging workup and regular follow-up of patients with a diagnosis of aPSN.

11 Non-gestational Trophoblastic Disease (NGTD)

NGTD includes choriocarcinoma of the ovary as a rare variant of mixed or pure germ cell tumors. Rare cases of trophoblastic differentiation in the form of choriocarcinoma or PSTT have been described in the context of adenocarcinoma and carcinosarcoma (previously known as malignant mixed müllerian tumors) of the endometrium [52–54]. It is extremely rare for primary trophoblastic differentiated tumors to be found at other sites.

In individual case reports, treatment of cases with mixed histology is usually based on the site of the carcinoma and the dominant histology. Carta et al. reported on a case with uterine endometrioid adenocarcinoma and focal NGTD. The patient was treated successfully by hysterectomy and adnexectomy [55].

In contrast, Horn et al. described a case of serous carcinoma of the endometrium with a choriocarcinomatous component [56]. After hysterectomy and bilateral adnexectomy the patient developed pulmonary metastatic disease and died, despite chemotherapy, two months postoperatively.

Affiliations

- ¹ Universitätsfrauenklinik der Ruhr-Universität Bochum, Bochum
- ² Institut für Pathologie, Universitätsklinikum Leipzig, Leipzig
- ³ Frauenklinik, Klinikum Darmstadt, Darmstadt
- ⁴ Frauenklinik, Universitätsklinikum Erlangen, Erlangen
- ⁵ Universitätsfrauenklinik, Universitätsklinikum Leipzig, Leipzig
- ⁶ Frauenklinik, Luzerner Kantonsspital, Lucerne, Switzerland
- ⁷ Frauenselbsthilfe nach Krebs, e. V.
- ⁸ Institut für Laboratoriumsmedizin, Klinische Chemie und Molekulare Diagnostik, Universitätsklinikum Leipzig, Leipzig
- ⁹ Klinik für Nuklearmedizin, Klinikum Augsburg, Augsburg
- ¹⁰ Universitätsfrauenklinik, Medizinische Universität Wien, Vienna, Austria
- ¹¹ Praxis für Gynäkologie und Geburtshilfe, Berlin
- ¹² Abteilung für Geburtshilfe und Perinatalmedizin, Klinikum rechts der Isar, Technische Universität München, Munich
- ¹³ Klinik und Poliklinik für Gynäkologie, Universitätsklinikum Halle (Saale), Halle (Saale)
- ¹⁴ Frauenklinik, Alb Fils Kliniken, Göppingen

References

- 1 Mangili G, Lorusso D, Brown J et al. Trophoblastic disease review for diagnosis and management: a joint report from the International Society for the Study of Trophoblastic Disease, European Organisation for the Treatment of Trophoblastic Disease, and the Gynecologic Cancer Inter-Group. *Int J Gynecol Cancer* 2014; 24 (9 Suppl. 3): S109–S116
- 2 Seckl MJ, Sebire NJ, Fisher RA et al.; ESMO Guidelines Working Group. Gestational trophoblastic disease: ESMO Clinical Practice Guidelines for diagnosis, treatment and follow-up. *Ann Oncol* 2013; 24 (Suppl. 6): vi39–vi50
- 3 Ngan HY, Bender H, Benedet JL et al.; FIGO Committee on Gynecologic Oncology. Gestational trophoblastic neoplasia, FIGO 2000 staging and classification. *Int J Gynaecol Obstet* 2003; 83 (Suppl. 1): 175–177
- 4 El-Helw LM, Coleman RE, Everard JE et al. Impact of the revised FIGO/WHO system on the management of patients with gestational trophoblastic neoplasia. *Gynecol Oncol* 2009; 113: 306–311
- 5 Savage P, Cooke R, O'Nions J et al. Effects of single-agent and combination chemotherapy for gestational trophoblastic tumors on risks of second malignancy and early menopause. *J Clin Oncol* 2015; 33: 472–478
- 6 Tham BW, Everard JE, Tidy JA et al. Gestational trophoblastic disease in the Asian population of Northern England and North Wales. *BJOG* 2003; 110: 555–559
- 7 Braga A, Uberti EM, Fajardo Mdo C et al. Epidemiological report on the treatment of patients with gestational trophoblastic disease in 10 Brazilian referral centers: results after 12 years since International FIGO 2000 Consensus. *J Reprod Med* 2014; 59: 241–247
- 8 Lybol C, Thomas CM, Bulten J et al. Increase in the incidence of gestational trophoblastic disease in The Netherlands. *Gynecol Oncol* 2011; 121: 334–338
- 9 Maestá I, Berkowitz RS, Goldstein DP et al. Relationship between race and clinical characteristics, extent of disease, and response to chemotherapy in patients with low-risk gestational trophoblastic neoplasia. *Gynecol Oncol* 2015; 138: 50–54
- 10 Whittington J, Fantz CR, Gronowski AM et al. The analytical specificity of human chorionic gonadotropin assays determined using WHO International Reference Reagents. *Clin Chim Acta* 2010; 411: 81–85
- 11 Cole LA, Sutton JM, Higgins TN et al. Between-method variation in human chorionic gonadotropin test results. *Clin Chem* 2004; 50: 874–882
- 12 Cole LA, DuToit S, Higgins TN. Total hCG tests. *Clin Chim Acta* 2011; 412: 2216–2222
- 13 Harvey RA, Mitchell HD, Stenman UH et al. Differences in total human chorionic gonadotropin immunoassay analytical specificity and ability to measure human chorionic gonadotropin in gestational trophoblastic disease and germ cell tumors. *J Reprod Med* 2010; 55: 285–295
- 14 Stenman UH, Tiitinen A, Alfthan H et al. The classification, functions and clinical use of different isoforms of HCG. *Hum Reprod Update* 2006; 12: 769–784
- 15 Sutton JM. Charge variants in serum and urine hCG. *Clin Chim Acta* 2004; 341: 199–203
- 16 Cole LA, Laidler LL, Muller CY. USA hCG reference service, 10-year report. *Clin Biochem* 2010; 43: 1013–1022
- 17 Vassilakos P, Riotton G, Kajii T. Hydatidiform mole: two entities. A morphologic and cytogenetic study with some clinical consideration. *Am J Obstet Gynecol* 1977; 127: 167–170
- 18 Hoffner L, Surti U. The genetics of gestational trophoblastic disease: a rare complication of pregnancy. *Cancer Genet* 2012; 205: 63–77
- 19 Vogel M, Horn LC. [Gestational trophoblastic disease, Villous gestational trophoblastic disease]. *Pathologe* 2004; 25: 269–279
- 20 Flam F, Lundström V, Pettersson F. Medical induction prior to surgical evacuation of hydatidiform mole: is there a greater risk of persistent trophoblastic disease? *Eur J Obstet Gynecol Reprod Biol* 1991; 42: 57–60
- 21 Tidy JA, Gillespie AM, Bright N et al. Gestational trophoblastic disease: a study of mode of evacuation and subsequent need for treatment with chemotherapy. *Gynecol Oncol* 2000; 78: 309–312
- 22 Berkowitz RS, Goldstein DP. Clinical practice. Molar pregnancy. *N Engl J Med* 2009; 360: 1639–1645
- 23 Sun SY, Melamed A, Goldstein DP et al. Changing presentation of complete hydatidiform mole at the New England Trophoblastic Disease Center over the past three decades: does early diagnosis alter risk for gestational trophoblastic neoplasia? *Gynecol Oncol* 2015; 138: 46–49

- 24 Lybol C, Sweep FC, Harvey R *et al.* Relapse rates after two versus three consolidation courses of methotrexate in the treatment of low-risk gestational trophoblastic neoplasia. *Gynecol Oncol* 2012; 125: 576–579
- 25 Alifrangis C, Agarwal R, Short D *et al.* EMA/CO for high-risk gestational trophoblastic neoplasia: good outcomes with induction low-dose etoposide-cisplatin and genetic analysis. *J Clin Oncol* 2013; 31: 280–286
- 26 Garrett LA, Garner EI, Feltmate CM *et al.* Subsequent pregnancy outcomes in patients with molar pregnancy and persistent gestational trophoblastic neoplasia. *J Reprod Med* 2008; 53: 481–486
- 27 Vargas R, Barroilhet LM, Esselen K *et al.* Subsequent pregnancy outcomes after complete and partial molar pregnancy, recurrent molar pregnancy, and gestational trophoblastic neoplasia: an update from the New England Trophoblastic Disease Center. *J Reprod Med* 2014; 59: 188–194
- 28 Baergen RN, Rutgers JL, Young RH *et al.* Placental site trophoblastic tumor: a study of 55 cases and review of the literature emphasizing factors of prognostic significance. *Gynecol Oncol* 2006; 100: 511–520
- 29 Shih IM, Kurman RJ. The pathology of intermediate trophoblastic tumors and tumor-like lesions. *Int J Gynecol Pathol* 2001; 20: 31–47
- 30 Menczer J, Livoff A, Malinger G *et al.* Exaggerated placental site erroneously diagnosed as non-metastatic trophoblastic disease. A case report. *Eur J Gynaecol Oncol* 1999; 20: 115–116
- 31 Nigam S, Dass R. Exaggerated placental site reaction mimicking choriocarcinoma. *Acta Obstet Gynecol Scand* 2003; 82: 587–588
- 32 Dotto J, Hui P. Lack of genetic association between exaggerated placental site reaction and placental site trophoblastic tumor. *Int J Gynecol Pathol* 2008; 27: 562–567
- 33 Papadopoulos AJ, Foskett M, Seckl MJ *et al.* Twenty-five years' clinical experience with placental site trophoblastic tumors. *J Reprod Med* 2002; 47: 460–464
- 34 Feltmate CM, Genest DR, Wise L *et al.* Placental site trophoblastic tumor: a 17-year experience at the New England Trophoblastic Disease Center. *Gynecol Oncol* 2001; 82: 415–419
- 35 Chang YL, Chang TC, Hsueh S *et al.* Prognostic factors and treatment for placental site trophoblastic tumor-report of 3 cases and analysis of 88 cases. *Gynecol Oncol* 1999; 73: 216–222
- 36 Piura E, Piura B. Brain metastases from gestational trophoblastic neoplasia: review of pertinent literature. *Eur J Gynaecol Oncol* 2014; 35: 359–367
- 37 Kohorn EI. Worldwide survey of the results of treating gestational trophoblastic disease. *J Reprod Med* 2014; 59: 145–153
- 38 Schmid P, Nagai Y, Agarwal R *et al.* Prognostic markers and long-term outcome of placental-site trophoblastic tumours: a retrospective observational study. *Lancet* 2009; 374: 48–55
- 39 Davis MR, Howitt BE, Quade BJ *et al.* Epithelioid trophoblastic tumor: a single institution case series at the New England Trophoblastic Disease Center. *Gynecol Oncol* 2015; 137: 456–461
- 40 Shih IM, Kurman RJ. Epithelioid trophoblastic tumor: a neoplasm distinct from choriocarcinoma and placental site trophoblastic tumor simulating carcinoma. *Am J Surg Pathol* 1998; 22: 1393–1403
- 41 Shih IM, Seidman JD, Kurman RJ. Placental site nodule and characterization of distinctive types of intermediate trophoblast. *Hum Pathol* 1999; 30: 687–694
- 42 Zhang X, Lü W, Lü B. Epithelioid trophoblastic tumor: an outcome-based literature review of 78 reported cases. *Int J Gynecol Cancer* 2013; 23: 1334–1338
- 43 Horn LC, Bilek K, Pretzsch G *et al.* Choriocarcinoma in extrauterine tubal pregnancy. *Geburtsh Frauenheilk* 1994; 54: 375–377
- 44 Horn LC, Vogel M. Gestational trophoblastic disease. Non-villous forms of gestational trophoblastic disease. *Pathologe* 2004; 25: 281–291
- 45 Taylor F, Short D, Winter MC *et al.* A retrospective study to evaluate single agent methotrexate treatment in low risk gestational choriocarcinoma in the United Kingdom. *Gynecol Oncol* 2015; 136: 258–263
- 46 Yang J, Xiang Y, Wan X *et al.* The prognosis of gestational trophoblastic neoplasia patient with residual lung tumor after completing treatment. *Gynecol Oncol* 2006; 103: 479–482
- 47 Doll KM, Soper JT. The role of surgery in the management of gestational trophoblastic neoplasia. *Obstet Gynecol Surv* 2013; 68: 533–542
- 48 Soper JT. Role of surgery and radiation therapy in the management of gestational trophoblastic disease. *Best Pract Res Clin Obstet Gynaecol* 2003; 17: 943–957
- 49 Sebire NJ, Seckl MJ. Immunohistochemical staining for diagnosis and prognostic assessment of hydatidiform moles: current evidence and future directions. *J Reprod Med* 2010; 55: 236–246
- 50 Tsai HW, Lin CP, Chou CY *et al.* Placental site nodule transformed into a malignant epithelioid trophoblastic tumour with pelvic lymph node and lung metastasis. *Histopathology* 2008; 53: 601–604
- 51 Kaur B, Short D, Fisher RA *et al.* Atypical placental site nodule (APSN) and association with malignant gestational trophoblastic disease; a clinicopathologic study of 21 cases. *Int J Gynecol Pathol* 2015; 34: 152–158
- 52 Akbulut M, Tosun H, Soysal ME *et al.* Endometrioid carcinoma of the endometrium with choriocarcinomatous differentiation: a case report and review of the literature. *Arch Gynecol Obstet* 2008; 278: 79–84
- 53 Nguyen CP, Levi AW, Montz FJ *et al.* Coexistent choriocarcinoma and malignant mixed mesodermal tumor of the uterus. *Gynecol Oncol* 2000; 79: 499–503
- 54 Massenkeil G, Crombach G, Dominik S *et al.* Metastatic choriocarcinoma in a postmenopausal woman. *Gynecol Oncol* 1996; 61: 432–437
- 55 Carta G, Accurti V, Di Nicola M *et al.* Uterine endometrioid carcinoma with focal area of choriocarcinomatous differentiation: case report. *Eur J Gynaecol Oncol* 2014; 35: 731–733
- 56 Horn LC, Hänel C, Bartholdt E *et al.* Serous carcinoma of the endometrium with choriocarcinomatous differentiation: a case report and review of the literature indicate the existence of 2 prognostically relevant tumor types. *Int J Gynecol Pathol* 2006; 25: 247–251

Guideline Program

Editors

Leading Professional Medical Associations



**German Society of Gynecology and Obstetrics
(Deutsche Gesellschaft für Gynäkologie
und Geburtshilfe e. V. [DGGG])**

Head Office of DGGG and Professional Societies
Hausvogteiplatz 12
DE-10117 Berlin
info@dggg.de
<http://www.dggg.de/>

President of DGGG

Prof. Dr. med. Diethelm Wallwiener
Universitätsfrauenklinik Tübingen
Calwerstraße 7
DE-72076 Tübingen

DGGG Guidelines Representative

Prof. Dr. med. Matthias W. Beckmann
Universitätsklinikum Erlangen
Frauenklinik
Universitätsstraße 21–23
DE-91054 Erlangen

Guidelines Coordination

Dr. med. Paul Gaß, Tobias Brodkorb, Marion Gebhardt
Universitätsklinikum Erlangen
Frauenklinik
Universitätsstraße 21–23
DE-91054 Erlangen
fk-dggg-leitlinien@uk-erlangen.de
<http://www.dggg.de/leitlinienstellungennahmen>

**Austrian Society of Gynecology and Obstetrics
(Österreichische Gesellschaft für Gynäkologie
und Geburtshilfe [OEGGG])**

Innrain 66A
AT-6020 Innsbruck
stephanie.leutgeb@oeggg.at
<http://www.oeggg.at>

President of OEGGG

Prof. Dr. med. Uwe Lang
Universitätsklinik für Frauenheilkunde
und Geburtshilfe Graz
Auenbruggerplatz 14
AT-8036 Graz

OEGGG Guidelines Representative

Prof. Dr. med. Karl Tamussino
Universitätsklinik für Frauenheilkunde
und Geburtshilfe Graz
Auenbruggerplatz 14
AT-8036 Graz

gynécologie suisse

**Swiss Society of Gynecology and Obstetrics
(Schweizerische Gesellschaft für Gynäkologie
und Geburtshilfe [SGGG])**

Gynécologie Suisse SGGG
Altenbergstraße 29
Postfach 6
CH-3000 Bern 8
sekretariat@sggg.ch
<http://www.sggg.ch/>

President of SGGG

Dr. med. David Ehm
FMH für Geburtshilfe und Gynäkologie
Nägeligasse 13
CH-3011 Bern

SGGG Guidelines Representative

Prof. Dr. med. Daniel Surbek
Universitätsklinik für Frauenheilkunde
Geburtshilfe und feto-maternale Medizin
Inselspital Bern
Effingerstraße 102
CH-3010 Bern