



Atypical Acute Retroviral Syndrome Presenting as a Facial Palsy

Boomer Olsen¹ Ekaphol Wooden¹

¹Arizona College of Osteopathic Medicine, Midwestern University, Glendale, Arizona, United States

Address for correspondence Boomer Olsen, BA, Arizona College of Osteopathic Medicine, Midwestern University, 19555 59th Avenue, Glendale, AZ 85308, United States (e-mail: bolsen82@midwestern.edu).

J Health Allied Sci^{NU} 2021;11:196–198.

Abstract

Keywords

- ▶ HIV
- ▶ acute retroviral syndrome
- ▶ Bell's palsy
- ▶ facial palsy
- ▶ oral hairy leukoplakia

Acute retroviral syndrome (ARS) refers to signs and symptoms present during acute human immunodeficiency virus (HIV) infection. Historically, ARS has been characterized as a mononucleosis-like illness. However, ARS may present with typical (i.e., mononucleosis-like) or atypical signs and symptoms. Here, we review typical and atypical ARS and discuss a 30-year-old man who first presented with a facial palsy and returned 2 years later with oral hairy leukoplakia, at which time he was found to have HIV and acquired immunodeficiency syndrome (AIDS). We suggest that facial palsies should pique clinical suspicion for HIV, especially in the context of recent or concurrent flu- or mononucleosis-like illness.

Introduction

Acute retroviral syndrome (ARS) refers to signs and symptoms of acute human immunodeficiency virus (HIV) infection.¹ Clinical suspicion for ARS is often based on signs and symptoms believed to be typical of ARS. However, 70% of patients present with typical ARS and 30% present with atypical ARS,¹ which both include a broad range of signs and symptoms. ▶ **Fig. 1** illustrates data from 12 studies that assessed frequencies of 19 signs and symptoms believed to be typical of ARS. Yet, frequencies of these typical signs and symptoms differed greatly across studies and the most frequent signs and symptoms are nonspecific (e.g., fever, malaise/fatigue, pharyngitis, myalgia, headache). ▶ **Table 1** lists data from a study of 70 patients with atypical ARS.¹ Among just 70 patients, there were 32 unique presentations and seven patients were entirely asymptomatic. The variety of signs and symptoms, or lack thereof, associated with typical and atypical ARS makes the clinical diagnosis of ARS challenging.

Case Report

First Encounter

A 30-year-old man presented to the primary care clinic with tongue numbness and left-sided facial droop for 6 days, and flu-like symptoms 1 month before the visit. He reported a family history of Bell's palsy but did not report a social history suggesting increased risk for HIV infection. On his left side, he lacked forehead folds and had decreased ability to clench his jaw, inflate his cheek, close his eye, and smile. On both sides, he had decreased forehead, infraorbital, and chin sensation. A computed tomography scan of the head was normal and the consulting neurologist confirmed our primary diagnosis of Bell's palsy (i.e., idiopathic facial palsy), which resolved with prednisone.

Second Encounter

The patient returned 2 and a half years later, reporting white spots on the right side of his tongue for 1 year and left side of

published online
February 10, 2021

DOI <https://doi.org/10.1055/s-0041-1723053>
ISSN 2582-4287.

© 2021. Nitte (Deemed to be University).

This is an open access article published by Thieme under the terms of the Creative Commons Attribution-NonDerivative-NonCommercial-License, permitting copying and reproduction so long as the original work is given appropriate credit. Contents may not be used for commercial purposes, or adapted, remixed, transformed or built upon. (<https://creativecommons.org/licenses/by-nc-nd/4.0/>).

Thieme Medical and Scientific Publishers Pvt. Ltd. A-12, 2nd Floor, Sector 2, Noida-201301 UP, India

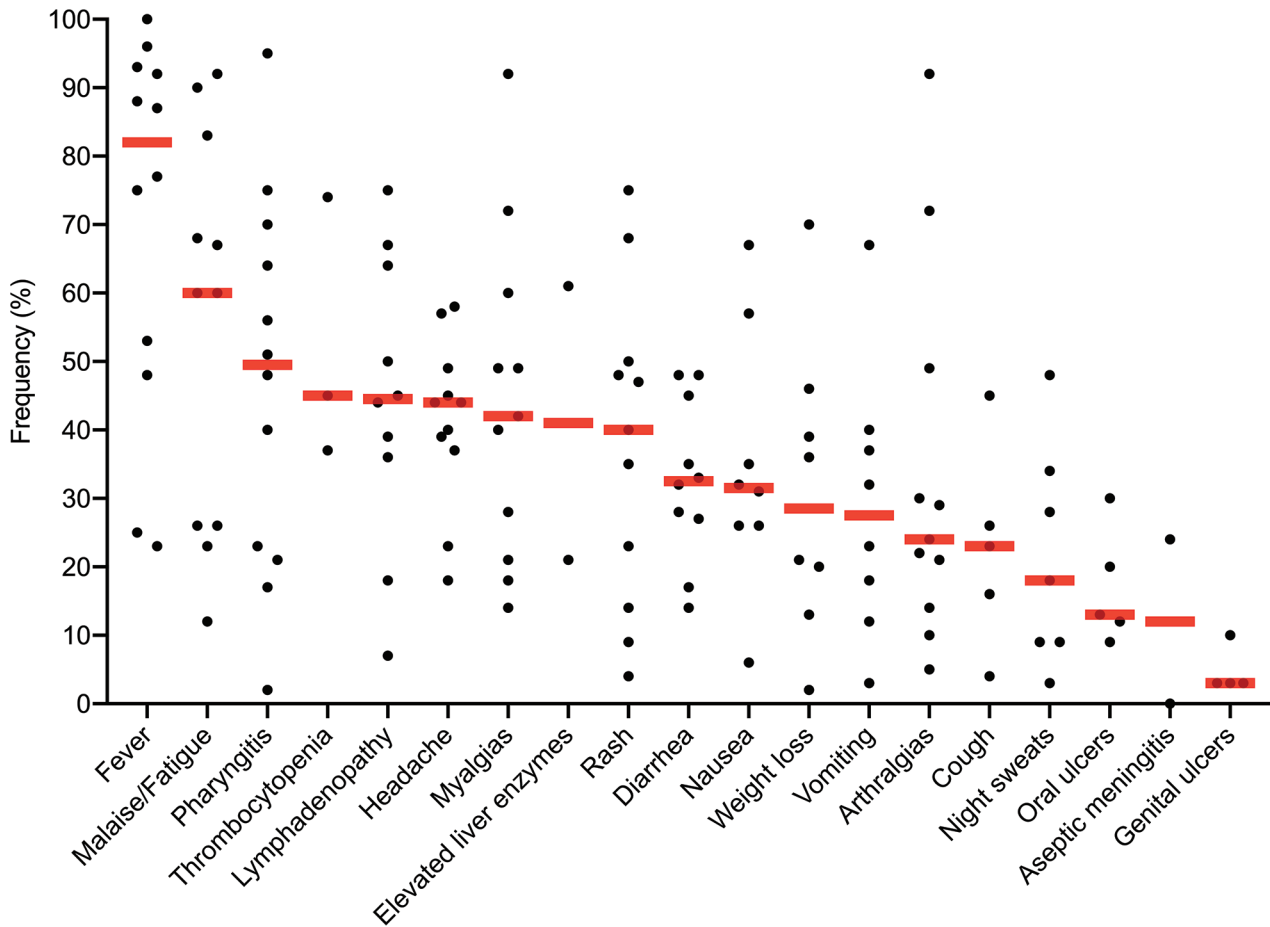


Fig. 1 Diverse signs and symptoms associated with typical acute retroviral syndrome. Data are from a study that describes primary data and reviews 11 published studies.¹ Black dots represent frequencies of signs and symptoms as reported by the studies. Red bars represent median frequencies of the signs and symptoms. Note that median frequencies do not give weight to the number of patients included in each study (range: 12–378, median = 32).

his tongue for several weeks. Physical examination revealed a corrugated, white plaque on the right side of his tongue (► **Fig. 2A**) and circular, white plaque with a 5 mm diameter on the left side of his tongue (► **Fig. 2B**). A punch biopsy of the left-sided tongue lesion was positive for squamous hyperplasia and negative for dysplasia and neoplasm, suggesting oral hairy leukoplakia. An HIV-1 antibody immunoassay was positive, HIV-1 polymerase chain reaction revealed 5.52 log₁₀ copies/mL (reference, < 1.30 log₁₀ copies/mL), and CD4 cell count was 101 cells/μL (reference, 365–2087 cells/μL). He was referred to an infectious disease specialist and started on antiretroviral therapy.

Discussion

Because of the broad range of presentations, clinical examination has limited capacity to identify acute HIV infection.² Thus, organizations like the Centers for Disease Control and Prevention and United States Preventive Services Taskforce call for extensive HIV screening (i.e., at least one lifetime test and repeat testing for those with increased risk).^{3,4} Still, some

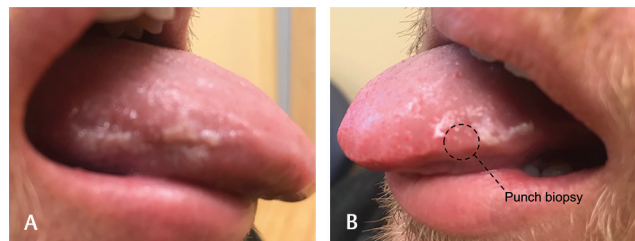


Fig. 2 Photos of the patient's tongue lesions taken several months after the second encounter. (A) The right lesion remained unchanged since the second encounter. (B) During the second encounter, a punch biopsy removed the entire left lesion. The pictured lesion developed during the following months.

HIV-positive patients will slip through cracks in screening guidelines. It falls on primary care providers to catch these patients, preferably during acute HIV infection, to interrupt transmission and reduce HIV-related morbidity and mortality.⁵

During the first encounter, our patient presented with left-sided facial weakness and left- and right-sided facial sensory deficits. The latter finding suggests involvement of both

Table 1 Diverse presentations associated with atypical acute retroviral syndrome

System	Presentation	n
	Asymptomatic	7
Cardiovascular	Acute atrial fibrillation	1
	Pancytopenia	3
	Thrombophlebitis	1
Constitutional	Weight loss or night sweats	7
Ocular	Herpes keratitis	1
Gastrointestinal	Acalculous cholecystitis	1
	Anal abscess	1
	Appendicitis-like illness	1
	Diarrhea	1
	HSV-1 stomatitis, esophagitis, and anitis	1
	Gastritis with bleeding	1
	Tonsillitis	4
Neurological	Acute psychiatric disorder	1
	HSV-1 meningitis	1
	Paresis (e.g., faciobrachial)	2
	Paresthesias and aphasia	1
	Vertigo	1
	Encephalitis	2
Opportunistic	Autoimmune thrombocytopenia	1
	<i>Candida</i> stomatitis and esophagitis	12
	CMV gastritis	1
	CMV hepatitis	2
	Multisegmental herpes zoster	1
	Peripheral polyradiculoneuritis	1
	Diarrhea (>30 days)	1
Respiratory	Pneumonia	3
	Upper respiratory tract infection	2
Skin and soft tissue	Impetigo contagiosa	1
	Dermatitis	2
	Soft tissue infection	3
Urogenital	Acute renal failure	1
	Epididymitis	1
Total		70

Abbreviations: CMV, cytomegalovirus; HSV-1, herpes simplex virus 1.
 Note: Data are from a study in which 70 patients presented with atypical ARS.
 Source: Adapted with permission from Braun and Kouyos.¹

trigeminal nerves, which is consistent with reports of additional cranial nerve deficits in patients with Bell's palsy.⁶ However, no risk factors or symptoms suggested HIV infection. Although we did not investigate the potential for an HIV infection at this time, the patient likely had an acute HIV infection, as he experienced flu-like symptoms (i.e., typical ARS) before the visit and soon after developed the facial palsy (i.e., atypical ARS). By the second encounter, his HIV infection had progressed to acquired immunodeficiency syndrome (AIDS), at which time he presented with oral hairy leukoplakia. The majority of facial palsies are idiopathic (i.e., Bell's palsy),⁷ but ~0.1% are caused by HIV.⁸ Although few reports describe facial palsies at the time of ARS, there is a clear connection between facial palsies and HIV infections.⁸⁻¹⁰

Conclusion

We suggest that facial palsies should pique clinical suspicion for HIV, especially in the context of recent or concurrent flu- or mononucleosis-like illness.

Conflict of Interest

None declared.

Acknowledgments

The authors thank Sheila Donnelly, MLS, and Christine Cellini for helpful discussions regarding copyright permissions.

References

- Braun DL, Kouyos RD, Balmer B, Grube C, Weber R, Günthard HF. Frequency and spectrum of unexpected clinical manifestations of primary HIV-1 infection. *Clin Infect Dis* 2015;61(6):1013–1021
- Wood E, Kerr T, Rowell G, et al. Does this adult patient have early HIV infection?: The rational clinical examination systematic review. *JAMA* 2014;312(3):278–285
- Branson BM, Handsfield HH, Lampe MA, et al; Centers for Disease Control and Prevention (CDC). Revised recommendations for HIV testing of adults, adolescents, and pregnant women in health-care settings. *MMWR Recomm Rep* 2006;55(RR-14):1–17, quiz CE1–CE4
- Owens DK, Davidson KW, Krist AH, et al; US Preventive Services Task Force. Screening for HIV infection: US Preventive Services Task Force Recommendation Statement. *JAMA* 2019;321(23):2326–2336
- Kitahata MM, Gange SJ, Abraham AG, et al; NA-ACCORD Investigators. Effect of early versus deferred antiretroviral therapy for HIV on survival. *N Engl J Med* 2009;360(18):1815–1826
- Benatar M, Edlow J. The spectrum of cranial neuropathy in patients with Bell's palsy. *Arch Intern Med* 2004;164(21):2383–2385
- Peitersen E. Bell's palsy: the spontaneous course of 2,500 peripheral facial nerve palsies of different etiologies. *Acta Otolaryngol Suppl* 2002;(549):4–30
- Hohman MH, Hadlock TA. Etiology, diagnosis, and management of facial palsy: 2000 patients at a facial nerve center. *Laryngoscope* 2014;124(7):E283–E293
- Komolafe MA, Fatusi OA, Alatise OI, et al. The role of human immunodeficiency virus infection in infranuclear facial paralysis. *J Natl Med Assoc* 2009;101(4):361–366
- Serrano P, Hernández N, Arroyo JA, de Llobet JM, Domingo P. Bilateral Bell palsy and acute HIV type 1 infection: report of 2 cases and review. *Clin Infect Dis* 2007;44(6):e57–e61