

Optimization of the Soft Tissue Envelope of the Nose in Rhinoplasty Utilizing Fat Transfer Combined with Platelet-Rich Fibrin

Milos Kovacevic, MD¹ Aaron M. Kosins, MD² Abdülkadir Göksel, MD³ Frank Riedel, MD, PhD⁴
Gregor Bran, MD, PhD⁵ Johannes A. Veit, MD, PhD^{4,6}

¹HNO-Praxis Hanse-Viertel, Hamburg, Germany

²Department of Plastic Surgery, University of California, Irvine School of Medicine, Irvine, California

³Rhinoistanbul, Istanbul, Turkey

⁴HNO-Zentrum Rhein-Neckar, Mannheim, Germany

⁵GB Aesthetics London, London, Great Britain

⁶Department of Otorhinolaryngology, Head and Neck Surgery, University Medical Center Mannheim, Mannheim, Germany

Address for correspondence Milos Kovacevic, MD, HNO-Praxis Hanse-Viertel, Hamburg, Germany (e-mail: info@hno-hamburg.com).

Facial Plast Surg 2021;37:590–598.

Abstract

A thin or damaged skin soft tissue envelope may cause concerns in primary and secondary rhinoplasty. During postoperative healing, unpredictable scarring and contraction may occur and lead to significant aesthetic and trophic sequelae. Besides a meticulous surgical technique, there are no reliable techniques to prevent long-term skin damage and shrinkage. Fat transfer with addition of platelet-rich fibrin (PRF) harbors the possibility of local soft tissue regeneration and skin rejuvenation through growth factors and mesenchymal stem cells. It may also facilitate the creation of a thin fat layer on the dorsum to prevent shrink-wrap forces and conceal small irregularities. The goal is to provide evidence for the feasibility, durability, and beneficial effect of diced macrofat transfer bonded with PRF on the nasal dorsum. We present the technique of fat transfer conjugated with PRF as a nasal dorsal graft. Clinical endpoints were the prevention of trophic disturbances and atrophy at a 1-year postoperative follow-up. We present the skin mobility test as a clinical indicator of a healthy soft tissue envelope. The presented case series consists of 107 rhinoplasties. Fat was harvested in the umbilical or costal region. PRF was created by centrifugation of autologous whole blood samples. Macrofat was diced, cleaned, and bonded with PRF. The compound transplants were transferred to the nasal dorsum. There were no perioperative complications or wound-healing issues. Mean follow-up was 14 months. Clinical inspection showed good skin quality and no signs of shrinkage, marked scarring, or color changes with positive skin mobility test in all patients. Survival of fat was confirmed by ultrasonography and magnetic resonance imaging. Diced macrofat transfer in conjunction with PRF to the nasal dorsum is a feasible and safe method. A beneficial effect on the soft tissue envelope is demonstrated as well as the prevention of shrink-wrap forces.

Keywords

- ▶ platelet-rich fibrin
- ▶ PRF
- ▶ nasal soft tissue
- ▶ rhinoplasty
- ▶ fat transfer

published online
February 26, 2021

Issue Theme Facial Plastic Surgery
Original Research; Guest Editors: Anthony P. Sclafani, MD, MBA, FACS, and Alwyn D'Souza, MBBS, FRCS Eng, FRCS (ORL-HNS)

© 2021, Thieme. All rights reserved.
Thieme Medical Publishers, Inc.,
333 Seventh Avenue, 18th Floor,
New York, NY 10001, USA

DOI <https://doi.org/10.1055/s-0041-1723785>.
ISSN 0736-6825.

Optimization of the soft tissue envelope in rhinoplasty is gaining more and more attention.¹ A thin soft tissue envelope on the nasal dorsum may cause aesthetic or even functional concerns as pain or paresthesia in the postoperative course for both primary and secondary rhinoplasty cases. During the postoperative healing process, unpredictable scarring and contraction of the soft tissue envelope can occur leading to a plastering down of the soft tissue envelope to the nasal dorsum particularly at the bony cartilaginous junction—the keystone area and in the tip/lower lateral curvilinear area. This may be triggered by iatrogenic trauma to the perichondrium, periosteum, superficial musculoaponeurotic system (SMAS), or adjacent blood vessels and nerves.² Eventually, this process can lead to significant aesthetic and trophic sequelae. Scarring and shrinkage of the soft tissue envelope and skin can lead to irregularities or color changes. The development of even painful sensations and paresthesia on the nasal dorsum remains controversial.^{3,4} Besides meticulous surgical technique with maximum soft tissue and blood vessel preservation, few techniques are available to prevent long-term skin damage and shrinkage.^{5,6}

Autologous fat grafting of the nose is not a common technique, although there are studies providing evidence for faster postoperative recovery from bruising and swelling.^{7,8}

To our knowledge, the long-term effects of fat grafting on nasal skin quality and the long-term survival of free fat transplants in the nose have not been investigated so far.

Fat grafting is a technique first described more than a century ago, but has been widely popularized and technically enhanced by Coleman.⁹ Fat grafting for aesthetic and reconstructive cases throughout the body and face has gained popularity. Previous studies have shown that autologous fat grafts from the abdominal wall harbor a significant number of viable adipocytes with stem cell features such as CD34 and therefore harbor the potential of local soft tissue regeneration.^{10,11}

The beneficial and rejuvenative effects of adipocyte transfer to local soft tissue has been demonstrated previously, although the optimal method of fat harvesting remains controversial.¹² There is evidence that less traumatic harvesting techniques, such as low pressure suction or direct excision in combination with low speed centrifugation or gravitational sedimentation, are superior for survival of intact transferred adipocytes.^{10,13}

In well-vascularized areas with a thicker soft tissue envelope, the survival percentage of transferred fat cells may reach values of up to a maximum of 60%.¹⁴ However, the percentage of adipocyte survival, especially in an area as the nasal dorsum, remains unclear although successful serial microfat injections for correction of irregularities and even volume augmentation in Asian patients have been published in several case series.^{15,16}

Platelet-rich fibrin (PRF) is an autologous, highly condensed solution containing thrombocytes, serum, growth factors, serine protease inhibitors, and immunoglobulins. The regenerative effect has been shown previously and is used in reconstructive, aesthetic, and dental medicine.^{17,18} Furthermore, PRF has glue-like features and may be used as an autologous serum to bond transplants with sufficient strength to prevent displacement.¹⁹ The authors propose that the addition of PRF to free fat transfer has the possibility to enhance fat graft survival

through the addition of growth factors and protease inhibitors that boost local soft tissue regeneration by enhanced adipose-derived stem cell survival.²⁰ In the nose, it may also facilitate the creation of a thin fat layer to prevent shrink-wrap forces, to conceal small irregularities, and to create a soft tissue glide plane allowing for mobility of the soft tissue envelope.

The novel technique presented has been termed “diced fat,” which is harvested by direct excision with the addition of PRF. The creation of small fat particles with scissors (– **Video 1**) is a less traumatic and damaging treatment—compared with liposuction—trying to minimize the production of cell detritus and subsequent fibrosis. The goal of this methodological case series is to provide evidence for the feasibility, durability, and local beneficial effect of diced fat transfer bonded with PRF to the nasal dorsum.

Video 1

The abdominal fat harvesting, preparation and processing with PRF. Online content including video sequences viewable at: <https://www.thieme-connect.com/products/ejournals/html/10.1055/s-0041-1723785>.

Patients and Methods

A retrospective chart analysis was performed of 107 consecutive functional and aesthetic rhinoplasty patients between January 2018 and July 2019. One hundred seven patients were included who underwent diced fat with PRF transfer by the authors (M.K. and J.A.V.). A chart analysis of these 107 patients were reviewed and patients were included if they had at least 1 year of follow-up and underwent the composite transfer. All patients received informed consent regarding the investigation; the analysis was performed in accordance with the guidelines of good clinical practice and the Declaration of Helsinki.

Surgical Technique

All patients were operated via open transcolumella approach in general anesthesia with hypotensive blood pressure and a single dose of antibiotic prophylaxis. Soft tissue elevation was done sub-SMAS on the nasal tip, and supraperichondrial and subperiosteal on the dorsum. Operative steps were performed according to individual pathology. Fat transfer was done at the end of operation before closure of skin incisions. To prevent any potential pressure necrosis or other wound-healing issues as well as to increase the viability of fat transplants, the taping and cast on the nasal dorsum was done with low pressure.

Fat Harvesting and Preparation

Autologous fat was harvested from either the inframammary fold (in case of synchronous rib harvesting) or transumbilically. After injection of 10 mL lidocaine 1% with 1:100,000 epinephrine, deep subcutaneous fat was carefully excised using scissors and a fan-like motion to avoid any irregularities (– **Video 1**). Approximately 10 mL of macroscopic fatty tissue

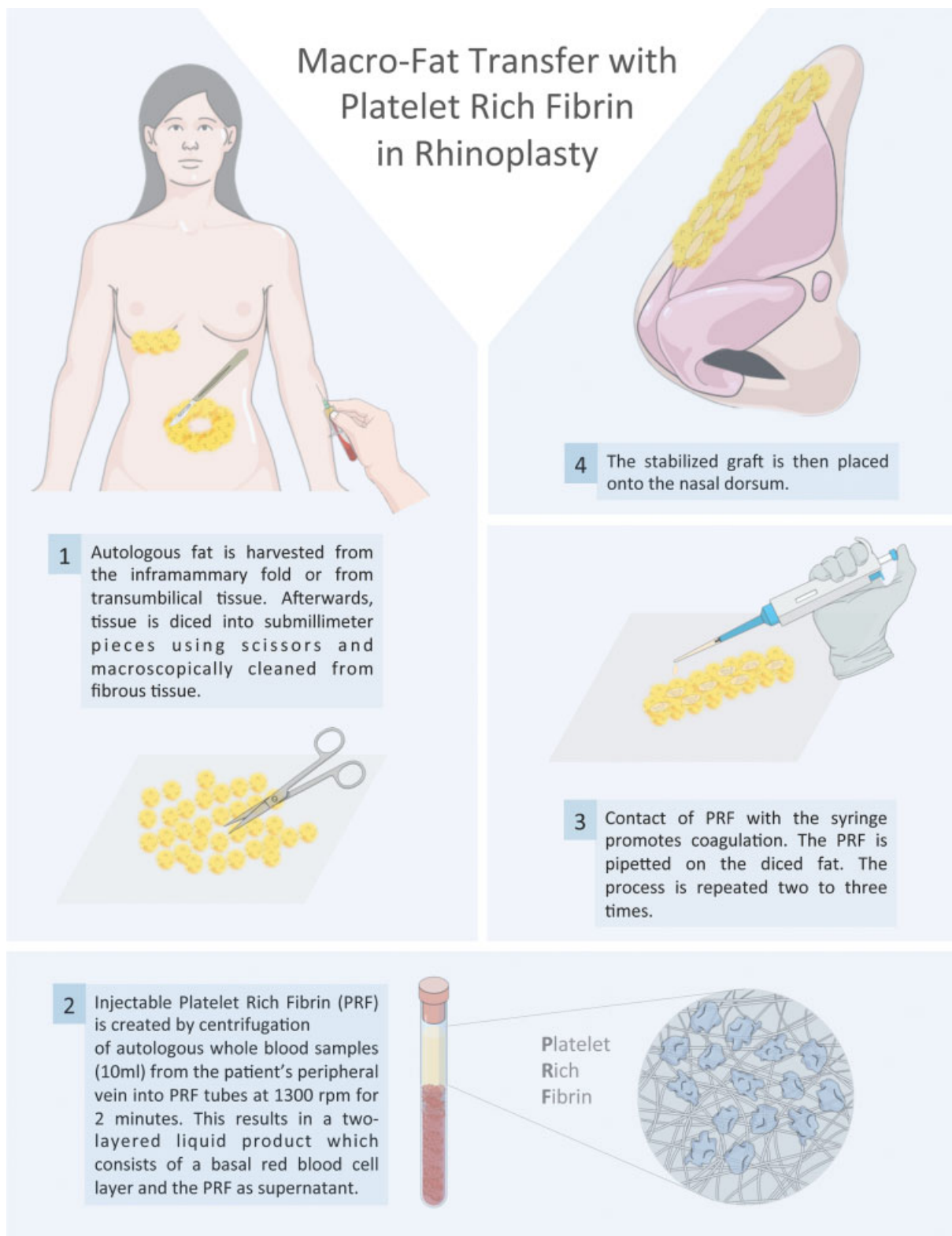


Fig. 1 The surgical steps of fat and blood harvesting (1), preparation of diced macrofat and centrifugation of whole blood to create platelet-rich fibrin (PRF) (2), preparation of diced macrofat/PRF transplant with scissors (3), and placement on nasal dorsum (4) are shown schematically. (Courtesy of Dr. Julia Thierauf, MGH, Boston, USA)

was harvested. The macroscopic fat was separated from adjacent connective tissue using 15-blade scalpel or scissors and cut into submillimeter pieces. The desired shape for nasal dorsal transplant ($\sim 30 \text{ mm} \times 15 \text{ mm} \times 1.5\text{--}2 \text{ mm}$), was

created of loose fatty cells. The transplant was covered with a wet sponge for 2 to 3 minutes and immediately after bonded with the PRF and placed on the nasal dorsum (**► Figs. 1** and **► Video 1**).

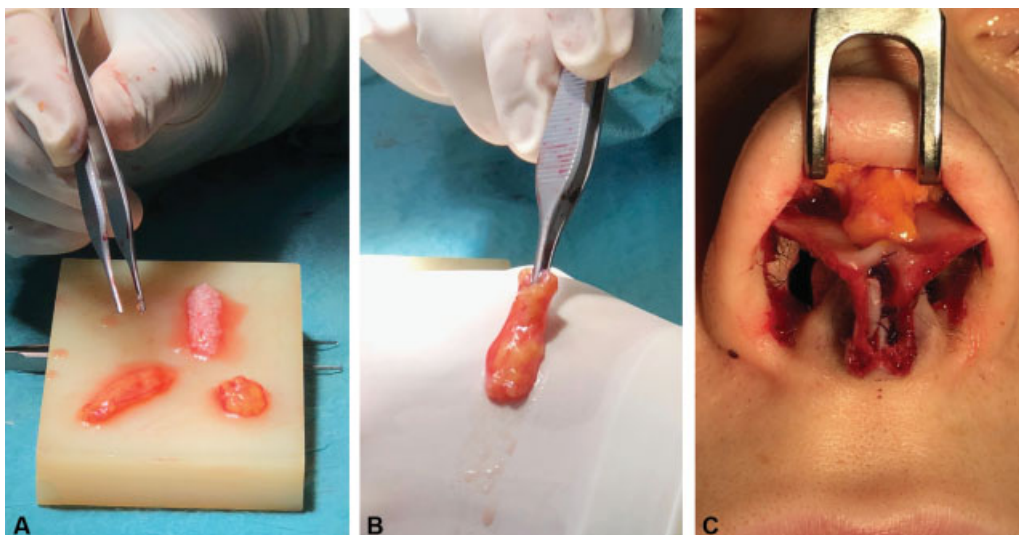


Fig. 2 Diced macrofat transplant bonded with platelet-rich fibrin (PRF) (A, B) after placement on nasal dorsum (C).

Preparation PRF

PRF was created by centrifugation of autologous whole blood samples and titration as published previously.^{19,21} The protocol for “injectable PFR” (A-PRF, Nice, France) works with centrifuged autologous blood without any addition of anticoagulant and bovine thrombin. For establishment of the liquid PRF we use the following protocol: Approximately 10 mL of whole blood are drawn from the patient’s peripheral vein into A-PRF tubes (glass - A-PRF tubes), and centrifuged immediately at 1,300 revolutions per minute (rpm) for 2 minutes and 10 seconds. If the coagulation is faster creating a visible fibrin clot, the process should be repeated with 1,300 rpm for 1 minute and 40 seconds. It is crucial to mention that drawing of the blood must not last more than 10 seconds and be straightforward. If the blood current is slow with possible hemolysis and trauma, problems might occur trying to create a clear separated PRF layer on top. This results in a two-layered liquid product, which consists of a basal red blood cell layer and a yellow supernatant, the PRF. The PRF fraction is pipetted into a

glass syringe. Contact of PRF with the glass syringe promotes physiological coagulation. The PRF is immediately sprayed on top of the diced fat compound and coagulation is completed after a few minutes. The stabilized graft with a thickness of 1.5 mm is placed onto the nasal dorsal area (→Figs. 1, 2 and →Video 1).

Analysis

Patients were evaluated for soft tissue changes by the surgeon. These variables were assessed visually and by the soft tissue mobility test. Before surgery it is important to assure skin mobility, and in case of scarring and lack of mobility to discuss fat transfer during surgery with the patient. After surgery it is an important sign for prediction of potential shape distortion due to shrink-wrap forces. The skin mobility test is positive if an (ink) dot at the center of the k-area can move/glide with the skin over the bony cartilaginous dorsum for more than 3 mm in a horizontal axis and approximately 2 mm vertically. The test is positive if the soft tissue envelope had normal mobility and pliability at 1 year after surgery (→Fig. 3).

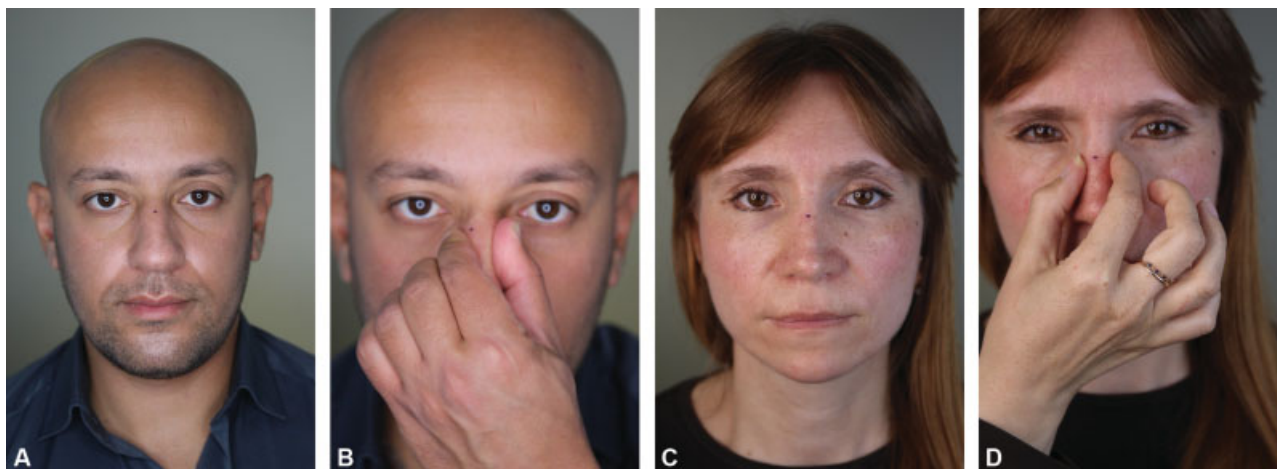

Fig. 3 The skin mobility test is positive if an (ink) dot at the center of the k-area can move/glide with the skin over the bony cartilaginous dorsum for more than 3 mm in a horizontal axis (A, B) and ~2 mm vertically. The test is considered negative if the skin is less mobile and fixed to the bony-cartilaginous framework without gliding plane (C, D).

Survival of compound transplants was furthermore confirmed by ultrasonography (11 patients) and magnetic resonance imaging (MRI) (4 patients). Ultrasonographic evaluation was performed after 12 months (10 MHz, Phillips) to evaluate survival of the transplant. In 4 patients a postoperative MRI (3 Tesla, Siemens) was performed at 12 months to evaluate survival of the transplant.

Results

Clinical Outcomes

One hundred seven patients were included who underwent diced fat with PRF transfer (80 primary and 27 secondary cases) by the authors (M.K. and J.A.V.). Sixty-seven percent (72/107) of patients were female and the median age was 29 years. Thirty percent (32/107) were smokers. The only other comorbidities were hypertension in two patients. Autologous fat was harvested from either the inframammary fold (in case

of synchronous rib harvesting) in 17 cases or transumbilically in 90 cases. On average a fat “blanket” of 15 × 30 mm with a thickness of 1.5 mm was transplanted on the nasal dorsal osseo-cartilagenous framework (OCF) in a sub-SMAS pocket (between radix and supratip) before wound closure. There were no perioperative complications or wound-healing issues including donor site infection or pneumothorax from the fat harvesting. Mean follow-up was 14 months.

Clinical inspection revealed identical or improved skin quality compared with preoperative findings (→Figs. 4 and 5). In secondary cases, skin shrinkage and preexisting color changes and dorsal irregularities were improved (→Fig. 6). Of the secondary cases, 8/27 had a negative skin mobility test preoperatively. At 1 year, all patients, both primary and secondary had a positive skin mobility test (107/107). No patient complained of scarring or shrinking in the nasal dorsal area. In all patients there was a slightly palpable deep subcutaneous layer, covering potential smaller irregularities and

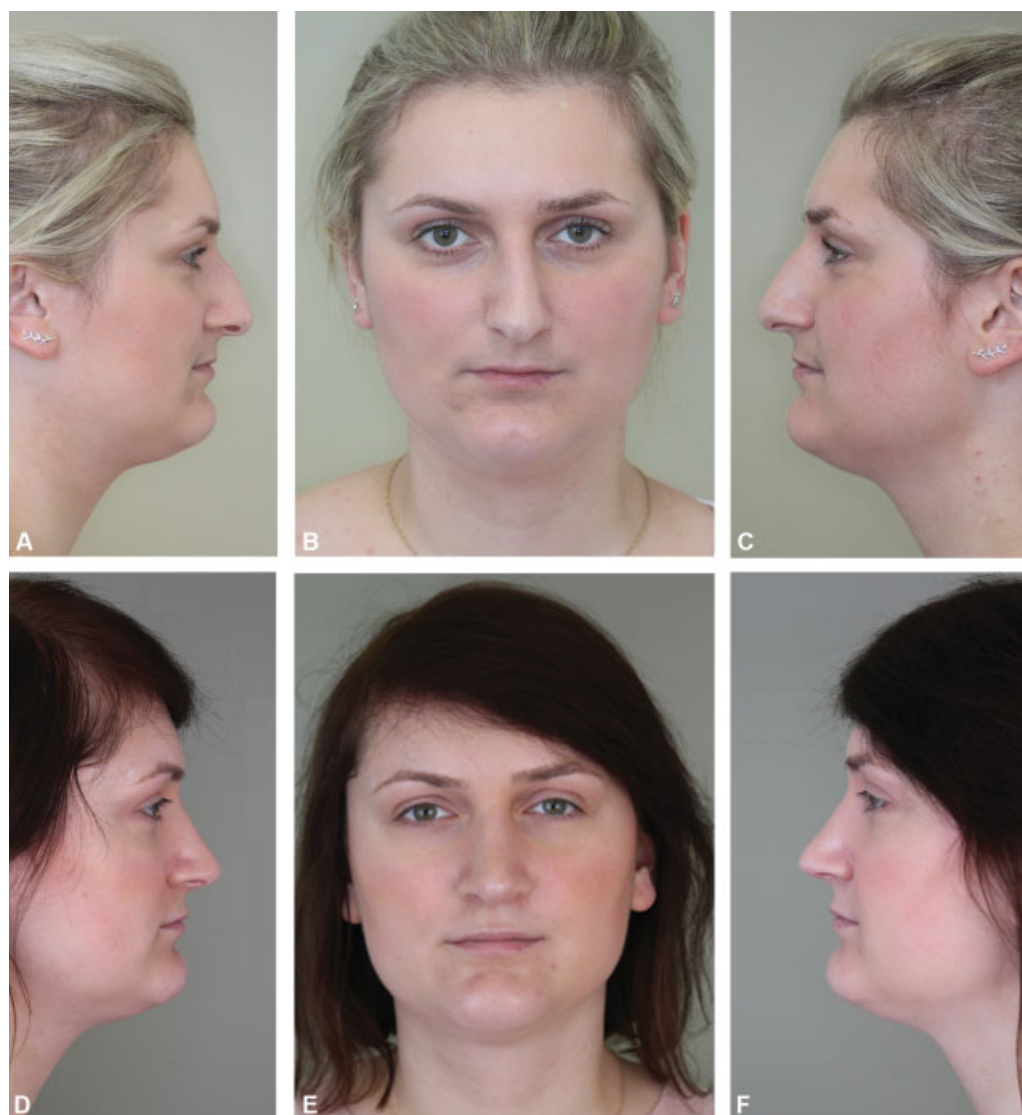

Fig. 4 Preoperative views of a female very thin-skinned patient and a deviated hump nose (A–C). Twelve-month postoperative views (open piezo-assisted dorsal preservation rhinoplasty with push down, septal extension graft, and dorsal diced fat-grafting with platelet-rich fibrin [PRF]) of the same patient with favorable outcome regarding axis deviation, profile alignment, and prevention of skin shrinkage or discoloration (D–F). The skin mobility test was positive.

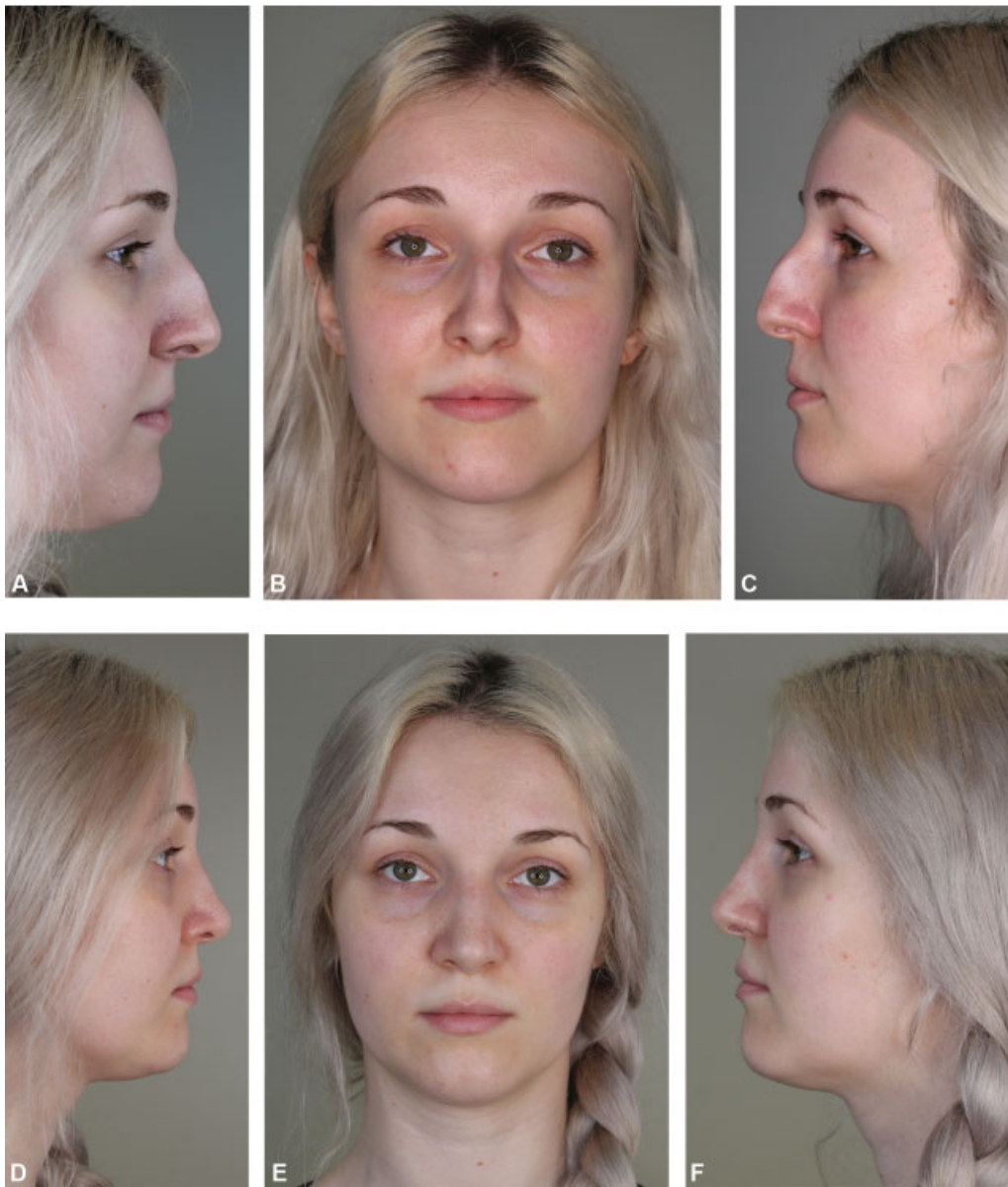

Fig. 5 Preoperative views of a female extremely thin-skinned patient and a deviated hump nose. The hump is creating a whitish discoloration of the skin (A–C). Twelve-month postoperative views (open piezo-assisted sequential hump removal, spreader grafts, septal extension graft, tip-plasty, and dorsal diced fat-grafting with platelet-rich fibrin [PRF]) of the same patient with favorable outcome regarding axis deviation, profile alignment, and prevention of skin shrinkage or discoloration (D–F). The skin mobility test was positive.

preventing relevant shrinking with possible implications on underlying structures.

Imaging Outcomes

Survival of compound transplants was furthermore confirmed by ultrasonography (11 patients) and MRI (4 patients). Postoperative MRI was done at 12 months and revealed a fatty layer in the deep nasal dorsal soft tissue envelope (►Fig. 7). The deep fatty layer was clearly distinguishable from the SMAS and bone layer and showed an estimated fat survival of 55 to 75%.

Ultrasonographic evaluation at 12 months' follow-up (10 MHz, Phillips) revealed a thin (median 0.9 mm [range 0.3–2.2 mm]) extra layer at the nasal dorsum deep to the SMAS layer when compared with preoperative ultrasonogra-

phy (►Fig. 8). This may reflect the additional fatty layer with survival of a relevant portion of transplanted adipocytes.

Complications

In all 107 patients there was a normal clinical course after surgery with transient ecchymosis, periorbital hematoma, and swelling. There were no signs of inflammation, especially in the nasal dorsal area, with all patients following 5-day oral antibiotic regimes. In one patient there was a prolonged bleeding, which led to a subcutaneous nasal hematoma and subsequent fat graft displacement. After resolution of acute swelling a “fat hump” was palpable and visible but was successfully treated with repeated triamcinolone injections (0.1 mL of 10 mg/mL 4 injections in 4 weeks).

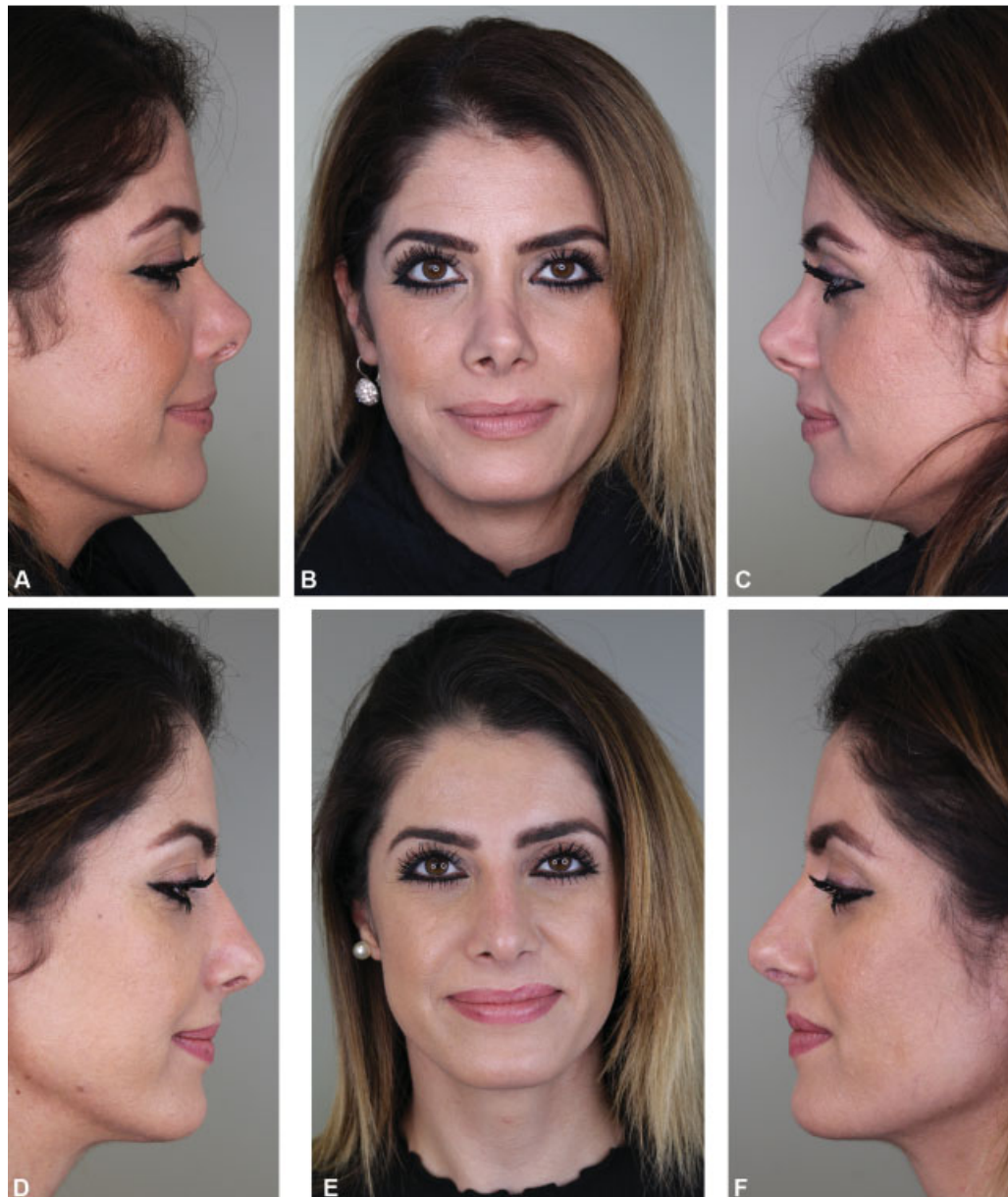

Fig. 6 Preoperative views of a female presenting after two previous rhinoplasties elsewhere, showing signs of shortened nose, inverted-v-deformity, and skin irregularities (A–C). Twelve-month postoperative views (open piezo-assisted revision-rhinoplasty with rib cartilage transplants, extended spreader grafts, septal extension grafts, alar transposition with lateral crural strut grafts, and dorsal diced fat-grafting with platelet-rich fibrin [PRF]) of the same patient with favorable outcome regarding axis deviation, profile alignment, and prevention of skin shrinkage or discoloration (D–F). The skin mobility test was positive.

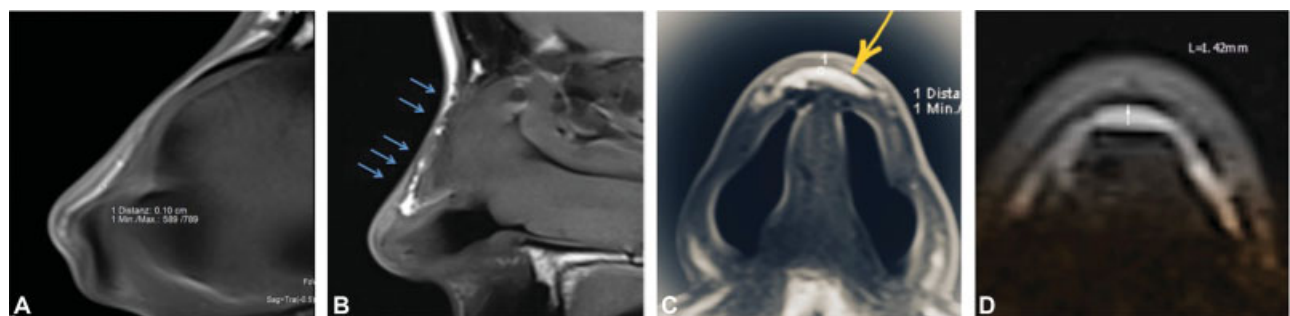


Fig. 7 Sagittal T1-weighted magnetic resonance imaging (MRI) scan of patient without nasal intervention and normal anatomy (A). Postoperative, sagittal high-resolution MRI of patient 12 months after rhinoplasty. In T1-weighted imaging fat islands can be identified in the nasal dorsum with a maximum in the supratip and radix area (arrows) (B). In axial view the transplanted fat layer can also be distinguished as a max. 1.42 mm fat-isodense area in the deep subcutaneous location above the cartilaginous framework.

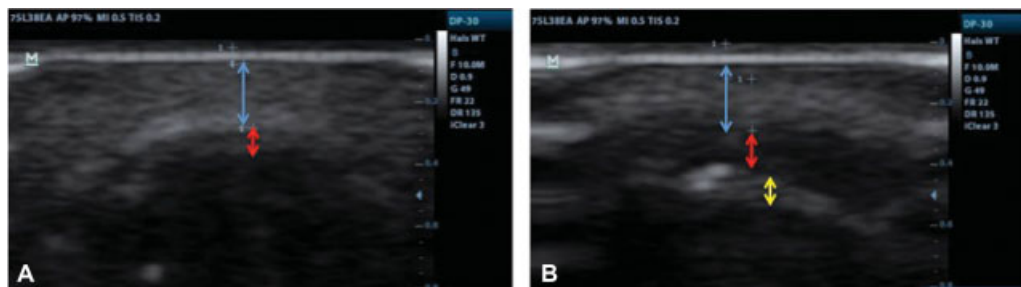


Fig. 8 Preoperative sagittal ultrasonography (10 MHz, Phillips) of patient without nasal intervention and normal anatomy (A). Dermis and subcutaneous tissue (blue arrow) with 2.0 mm in diameter and thin superficial musculoaponeurotic system (SMAS) layer (red arrow) underneath with 0.8 mm. Twelve-month postoperative ultrasonography an additional fat layer (yellow arrow, 0.8 mm) can be distinguished.

Discussion

Management of the soft tissue envelope, especially in thin-skinned patients and secondary cases, is gaining more and more attention in rhinoplasty. Meticulous surgical preparation in supra- or even subperichondreal layers may help to limit soft tissue damage and prevent surgical sequelae as discolorations, persistent swelling, uncontrolled scar formation, and shrink-wrap forces that may eventually lead to significant esthetic concerns.²⁻⁵ In primary cases with extremely thin dorsal skin or in secondary cases with preexisting soft tissue damage, additional techniques are often necessary to achieve durable results. A negative soft tissue mobility test preoperatively is an absolute indication for diced fat bonded to PRF to restore the glide plane of the soft tissue envelope over the osseocartilaginous vault. Traditionally, autologous or heterologous fascia transplants on the nasal dorsum are used for camouflage and slight dorsal augmentation.^{22,23} Although effective, these techniques bear the risk of unpredictable absorption and final thickness, some donor site morbidity, and rare immune reactions in heterologous fascia.

Benefits of Direct Fat Harvesting

Autologous fat transplantation has been described for acceleration of nasal healing or augmentation in Asian patients.^{15,24} Positive outcomes have been reported but fundamental questions regarding the optimal harvesting technique and methods to prevent adipocyte lysis remain to be elucidated. For abdominal and peripheral fat harvesting, it is known that trauma to the adipocytes can be limited by usage of optimal blunt cannula and the avoidance of higher negative pressure.²⁵ With our technique, the direct excision of small quantities limits trauma and required no negative pressure being applied to the adipocytes. Centrifugation is avoided in the described technique by direct downsizing and cleaning with scissors. Naturally, the exact particle size may vary far more in this technique, compared with centrifugation and filtering, but the amount of cell detritus and cytolysis is much more limited. There is evidence that a particle size of around 1 mm cubic is optimal for viability of adipocytes. Smaller particles harbor more cytolysis and larger particles may lead to significant central necrosis of transplants.^{15,24,25}

Benefits of PRF for Fat Survival

The most important aspect for survival of fat transplants is the vascularization at the recipient site. Fat transplants should be surrounded by well-perfused soft tissue to allow for vessel ingrowth. The vascularity of nasal soft tissue is abundant in primary cases, but may be limited in secondary cases. There is evidence of the positive effect of PRF only alone on the nasal dorsum but no data on the combination of PRF and fat transfer.²⁶ The addition of PRF to free fat transplants may increase survival of fat cells through the increased density of growth factors such as vascular endothelial growth factor, insulin-like growth factor, and protease inhibitors. There is evidence from animal models that survival of adipocytes can be enhanced significantly by the addition of PRF.^{27,28} There is evidence from meta-analysis in animal models, that fat graft survival is enhanced by the addition of PRF compared with control groups.²⁰ In one animal study an extra PRF injection into the grafting area after 1 week enabled better survival of fat cells. Furthermore, there are publications on the beneficial effect of microfat transfer in the nose.^{12,15} Toriumi has recently demonstrated the beneficial effect of nanofat-infused fascia transplants for the damaged skin/soft tissue envelope.²⁹

Clinical Implications

Diced fat transfer should be considered in case of

- Primary rhinoplasties with very thin skin.
- Primary and secondary rhinoplasties with visible underlying hump or irregularities.
- Primary and secondary rhinoplasties with negative skin mobility test.
- Secondary rhinoplasties with skin irregularities and trophic disturbances.

Limitations of the Study

Our presented case series has limitations due to the retrospective character of the analysis as well as a lack of objective parameters for evaluation of skin quality. Unfortunately, systematic analysis of all patients was not possible due to limited access to MRI. Ultrasonography was only performed in 10% of cases, only 10 MHz ultrasonography was available, which is not optimal for skin examination (better 20 MHz). Nevertheless, prevention of skin shrinkage and amelioration of skin quality

were observed in all patients. None of the patients displayed donor site morbidities or prolonged healing episodes or transplant failure or inflammation. One of the true benefits of the applied technique is the true autologous origin of all tissues and a limited technical and time-consuming effort.

Conclusion

In conclusion, free macrofat transfer with PRF was a successful and safe technique in our cases series and helped to prevent dorsal soft tissue damage, skin discolorations, and the development of shrink-wrap forces in primary and secondary rhinoplasty. All patients had a positive skin mobility test postoperatively with an established glide plane over the keystone area and horizontal movement of more than 3 mm. Further studies will be necessary to better understand the long-term effect and durability of this technique.

Conflict of Interest

None declared.

References

- Kosins AM. Comprehensive diagnosis and planning for the difficult rhinoplasty patient: applications in ultrasonography and treatment of the soft-tissue envelope. *Facial Plast Surg* 2017;33(05):509–518
- Toriumi DM, Mueller RA, Grosch T, Bhattacharyya TK, Larrabee WF Jr. Vascular anatomy of the nose and the external rhinoplasty approach. *Arch Otolaryngol Head Neck Surg* 1996;122(01):24–34
- Kerolus JL, Nassif PS. Treatment protocol for compromised nasal skin. *Facial Plast Surg Clin North Am* 2019;27(04):505–511
- Rosenberger ES, Toriumi DM. Controversies in revision rhinoplasty. *Facial Plast Surg Clin North Am* 2016;24(03):337–345
- Çakır B, Oreroğlu AR, Doğan T, Akan M. A complete subperichondrial dissection technique for rhinoplasty with management of the nasal ligaments. *Aesthet Surg J* 2012;32(05):564–574
- Saban Y. Rhinoplasty: lessons from “errors” : from anatomy and experience to the concept of sequential primary rhinoplasty. *HNO* 2018;66(01):15–25
- Gabrick K, Walker M, Timberlake A, Chouairi F, Saberski E, Steinbacher D. The effect of autologous fat grafting on edema and ecchymoses in primary open rhinoplasty. *Aesthetic Surg J* 2020;40(04):359–366
- Nguyen PS, Baptista C, Casanova D, Bardot J, Magalon G. Rhinoplastie et injection de tissu adipeux autologue. *Ann Chir Plast Esthet* 2014;59(06):548–554
- Coleman SR. Facial recontouring with lipostructure. *Clin Plast Surg* 1997;24(02):347–367
- Simonacci F, Bertozzi N, Grieco MP, Grignaffini E, Raposio E. Procedure, applications, and outcomes of autologous fat grafting. *Ann Med Surg (Lond)* 2017;20:49–60
- Hassan WU, Greiser U, Wang W. Role of adipose-derived stem cells in wound healing. *Wound Repair Regen* 2014;22(03):313–325
- Clauser L, Zavan B, Galiè M, Di Vittorio L, Gardin C, Bianchi AE. Autologous fat transfer for facial augmentation: surgery and regeneration. *J Craniofac Surg* 2019;30(03):682–685
- Sinno S, Wilson S, Brownstone N, Levine SM. Current thoughts on fat grafting: using the evidence to determine fact or fiction. *Plast Reconstr Surg* 2016;137(03):818–824
- Krastev TK, Beugels J, Hommes J, Piatkowski A, Mathijssen I, van der Hulst R. Efficacy and safety of autologous fat transfer in facial reconstructive surgery: a systematic review and meta-analysis. *JAMA Facial Plast Surg* 2018;20(05):351–360
- Erol OO. Microfat grafting in nasal surgery. *Aesthet Surg J* 2014;34(05):671–686
- Kao W-P, Lin Y-N, Lin T-Y, et al. Microautologous fat transplantation for primary augmentation rhinoplasty: long-term monitoring of 198 Asian patients. *Aesthet Surg J* 2016;36(06):648–656
- Verboket RD, Anbar B, Söhling N, et al. Changes in platelet-rich fibrin composition after trauma and surgical intervention. *Platelets* 2020;31(08):1069–1079
- Srinivas B, Das P, Rana MM, Qureshi AQ, Vaidya KC, Ahmed Raziuddin SJ. Wound healing and bone regeneration in postextraction sockets with and without platelet-rich fibrin. *Ann Maxillofac Surg* 2018;8(01):28–34
- Kovacevic M, Riedel F, Wurm J, Bran GM. Cartilage scales embedded in fibrin gel. *Facial Plast Surg* 2017;33(02):225–232
- Smith OJ, Kanapathy M, Khajuria A, et al. Systematic review of the efficacy of fat grafting and platelet-rich plasma for wound healing. *Int Wound J* 2018;15(04):519–526
- Choukroun J, Adda F, Schoeffler CVA. An opportunity in peri-implantology: the PRF. *Implantodontie* 2001;42:55–62
- Jang YJ, Song HM, Yoon JY, Sykes JM. Combined use of crushed cartilage and processed fascia lata for dorsal augmentation in rhinoplasty for Asians. *Laryngoscope* 2009;119(06):1088–1092
- Guerrerosantos J. Temporoparietal free fascia grafts in rhinoplasty. *Plast Reconstr Surg* 1984;74(04):465–475
- Lin T-M, Huang S-H, Lin Y-N, et al. Fat grafting for facial contouring (nose and chin). *Clin Plast Surg* 2020;47(01):91–98
- Papadopoulos NA, Wigand S, Kuntz N, et al. The impact of harvesting systems and donor characteristics on viability of nucleated cells in adipose tissue: a first step towards a manufacturing process. *J Craniofac Surg* 2019;30(03):716–720
- Gode S, Ozturk A, Kismalı E, Berber V, Turhal G. The effect of platelet-rich fibrin on nasal skin thickness in rhinoplasty. *Facial Plast Surg* 2019;35(04):400–403
- Liu R, Long Y, Liu L, Zhao X. Effect of platelet-rich fibrin on fat grafting in animal models: a meta-analysis. *Aesthetic Plast Surg* 2020;44(02):570–578
- Yu P, Zhai Z, Lu H, Jin X, Yang X, Qi Z. Platelet-rich fibrin improves fat graft survival possibly by promoting angiogenesis and adipogenesis, inhibiting apoptosis, and regulating collagen production. *Aesthet Surg J* 2020;40(09):NP530–NP545
- Toriumi DM. Dorsal augmentation using autologous costal cartilage or microfat-infused soft tissue augmentation. *Facial Plast Surg* 2017;33(02):162–178