Article published online: 2021-02-19

Subchondral Bone Condition and Intraoperative Grading of Cartilage Degeneration Underneath Patella Unrelated to the Clinical Outcome after TKA with Unresurfaced Patella

Hyung Jun Park, MD[1] Moon Jong Chang, MD, PhD[1] Tae Woo Kim, MD, PhD[1]
Chong Bum Chang, MD, PhD[2] Kee Soo Kang, MD[1] Seung-Baik Kang, MD, PhD[1]

[1] Department of Orthopedic Surgery, Seoul National University College of Medicine, SMG-SNU Boramae Medical Center, Seoul, South Korea
[2] Department of Orthopedic Surgery, Seoul National University College of Medicine, Seoul National University Bundang Hospital, Seongnam, South Korea

Address for correspondence Seung-Baik Kang, MD, PhD, Department of Orthopedic Surgery, Seoul National University College of Medicine, SMG-SNU Boramae Medical Center, 5 Gil 20, Boramae Road, Dongjak-gu, Seoul, 07061, South Korea (e-mail: ossbkang@gmail.com).

J Knee Surg 2022;35:1417–1424.

Abstract

The degree of cartilage degeneration assessed intraoperatively may not be sufficient as a criterion for patellar resurfacing in total knee arthroplasty (TKA). However, single-photon emission tomography/computed tomography (SPECT/CT) is useful for detecting osteoarthritic involvement deeper in the subchondral bone. The purpose of the study was to determine whether SPECT/CT reflected the cartilage lesion underneath the patella in patients with end-stage osteoarthritis (OA) and whether clinical outcomes after TKA without patellar resurfacing differed according to the severity of patellofemoral (PF) OA determined by visual assessment and SPECT/CT findings. This study included 206 knees which underwent TKA. The degree of cartilage degeneration was graded intraoperatively according to the International Cartilage Repair Society grading system. Subjects were classified into low and high uptake groups according to the degree of bone tracer uptake (BTU) on SPECT/CT in the PF joint. The Feller's patella score and Western Ontario and McMaster Universities Osteoarthritis Index (WOMAC) were assessed preoperatively and postoperative 1 and 2 years. The increased BTU in the PF joint was associated with more severe degenerative cartilage changes underneath the patella ($p < 0.001$). The risk for the presence of denudated cartilage was greater in the high uptake group (odds ratio = 5.89). There was no association between clinical outcomes and visual grading of patellar cartilage degeneration or the degree of BTU on SPECT/CT. The visual assessment of the degree of cartilage degeneration underneath the patella and preoperative SPECT/CT evaluation of the PF joint were not predictive of clinical outcome after TKA with unresurfaced patella.

Keywords
- patellofemoral joint
- single-photon emission tomography
- computed tomography
- clinical outcome
- total knee replacement

The optimal approach for patellar management during total knee arthroplasty (TKA) remains controversial. Consensus about patellar resurfacing exists in patients with inflammatory arthritis such as rheumatoid arthritis.[1] In contrast, patients with osteoarthritis (OA), preoperative anterior knee pain is traditionally used as an indication of selective patella resurfacing.[2] Additionally, damaged patellar articular cartilage noted during surgery may be used to direct patellar resurfacing during TKA performed for knee OA.[3–5] However, the decision to perform patellar resurfacing in the presence of patellar cartilage loss is not uniformly accepted. Some surgeons recommend patellar resurfacing according to

received
September 4, 2020
accepted after revision
January 2, 2021
published online
February 19, 2021

© 2021. Thieme. All rights reserved.
Thieme Medical Publishers, Inc., 333 Seventh Avenue, 18th Floor, New York, NY 10001, USA

DOI https://doi.org/10.1055/s-0041-1723980.
ISSN 1538-8506.

This document was downloaded for personal use only. Unauthorized distribution is strictly prohibited.

the severity of cartilage degeneration underneath the patella.[4–6] Others reported that there was no difference in clinical and radiographic outcomes between patients with and without patellar resurfacing regardless of the degree of patellar cartilage degeneration.[7–10]

Single-photon emission tomography (SPECT) is an imaging modality performed after the administration of a radioactive tracer.[11] Active osteoblasts are the main target of the injected tracer. Bone tracer uptake (BTU) reflects bone turnover in the subchondral bone plate and bone marrow, which is influenced by blood flow and mechanical loading on bone.[12,13] Recently, SPECT has been combined with computed tomography (CT) for anatomical accuracy. This hybrid system (SPECT/CT) is sensitive for detecting subchondral lesions.[12]

If the BTU observed on SPECT/CT can reflect subchondral bone involvement and the degree of cartilage degeneration, it may be required to determine the degree of patellar OA before surgery. Studies have reported that BTU on SPECT/CT increased along the size and depth of cartilage lesions.[13,14] Hirschmann et al reported that BTU on SPECT/CT could be detectable before structural changes were found on magnetic resonance imaging (MRI), CT, and conventional radiographs.[15] These findings suggest that SPECT/CT reflects not only the current state of cartilage lesion, but also the condition before the obvious cartilage degeneration was found by using other imaging modalities. In addition, it was revealed that in addition to the clinical symptoms, the responsibility for treatment is related to BTU in middle-aged patients with anterior knee pain.[11,16] Therefore, if the SPECT/CT is evaluated prior TKA, it could be useful to predict the patellofemoral (PF) clinical outcomes and help to decide how to manage the PF compartment. However, no study has previously reported the relationship between cartilage degeneration underneath the patella and BTU on SPECT/CT in patients who candidates for TKA. In addition, no study has reported the clinical outcomes of PF after TKA according to SPECT/CT findings.

We sought to determine whether SPECT/CT reflected the cartilage lesion underneath the patella in patients with end-stage OA who underwent TKA without patellar resurfacing. We also wanted to determine whether the PF and overall outcomes after TKA differed according to the severity of cartilage degeneration underneath the patella evaluated by intraoperative gross grading and findings on SPECT/CT. We hypothesized that BTU would increase according to the degree of cartilage degeneration underneath the patella. We also hypothesized that SPECT/CT findings, which reflect subchondral involvement rather than visual cartilage degeneration grading determined at the surface, would be related to PF and overall clinical outcome after TKA.

Materials and Methods

Study Design and Population

This retrospective study included 125 patients (206 knees) who underwent primary TKA without patellar resurfacing. The inclusion criteria were following (1) TKA due to OA (Kellgren-Lawrence grade 3 or 4) with pain unresponsive to conservative treatment, (2) preoperative SPECT/CT evaluation, and (3) clinical evaluation at preoperative, postoperative 1 year and 2 years after TKA. In total, 127 patients (208 knees) were eligible for inclusion among the patients who underwent TKA between 2015 and 2017 in our institute. Among the patients eligible for inclusion, two patients (two knees) were excluded by the following exclusion criteria (1) inflammatory arthritis such as rheumatoid arthritis and post-traumatic arthritis, (2) neuromuscular disorders such as Parkinson's disease and Charcot joint, and (3) postoperative complications such as periprosthetic fracture and periprosthetic joint infection within 2 years after TKA. Two patients (two knees) were excluded as periprosthetic fractures within 2 years after TKA. Finally, 125 patients (206 cases) were included in the study (►**Fig. 1**). Institutional review board approval was obtained before pursuing the retrospective review of data.

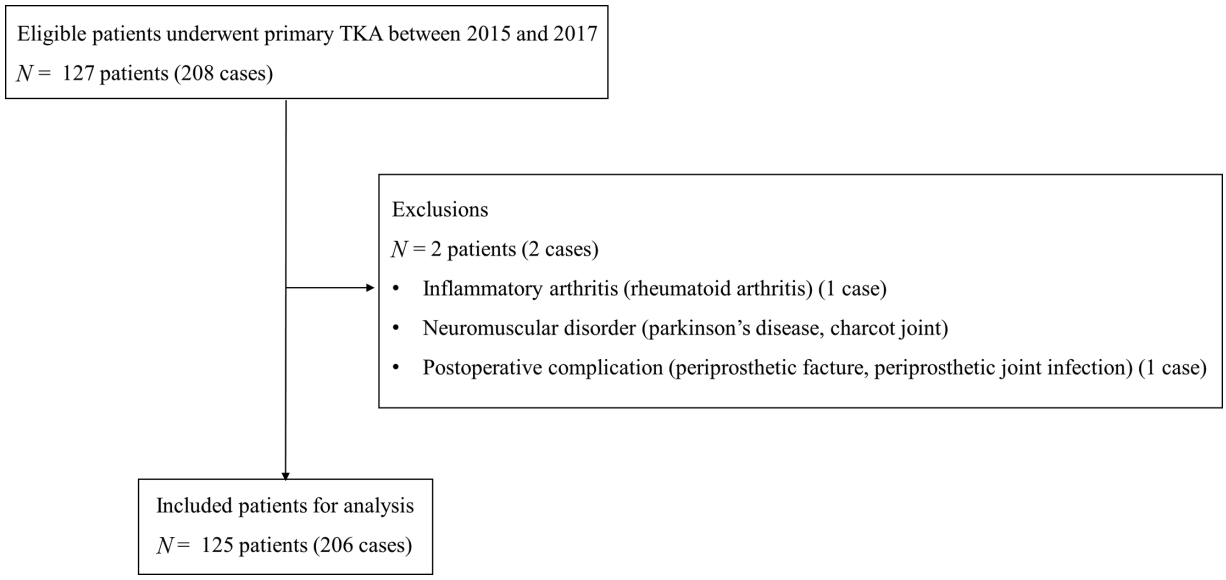

Fig. 1 Patient selection for the study.

 © 2021. Thieme. All rights reserved.

This document was downloaded for personal use only. Unauthorized distribution is strictly prohibited.

Surgical Techniques and Implants

All TKAs were performed with posterior stabilized patellar-friendly designed femoral implants by a single senior surgeon. The surgical techniques were the same for all TKAs. The medial parapatellar approach with a midline incision was used. Distal femoral and proximal tibial bone resection was performed using an intramedullary guide. A transepicondylar axis and Whiteside's line were used for femoral component rotation.[17] The size of the femoral component was determined by the posterior referencing method. The rotation of the tibial component was set by considering not only the anatomical landmarks such as the medial one-third of the tibial tuberosity (Insall's reference), patella tendon, and alignment with femoral component and tibial crest.[17,18] In terms of patellar managements, the peripheral osteophytes around patella were removed and the denuded patella was tried to be made flattened.[19] All patellar rims were denervated by electrocautery.[20] A partial lateral facetectomy was performed after the lateral peripatellar soft tissue was released.[21,22] Patellar tracking was validated by the towel clip technique after the tourniquet was deflated.[23]

Single-Photon Emission Tomography/Computed Tomography Evaluation

SPECT/CT (GE Healthcare Milwaukee, WI) was performed after patients were injected with ^{99}mTc-hydroxymethylenediphosphonate (HDP). This system incorporates a bone scintigraphy and a CT scan in one step. Images of the knee were obtained 2 hours after injection which were reconstructed in three planes: axial, coronal, and sagittal (SPECT with 128 × 128 matrix, 32 angular step, 35 seconds per frame, step and shoot).[11,24] BTU was graded on a four-scale system; grade 0, BTU was equivalent to normal cancellous bone; grade 1, BTU was higher than normal cancellous bone and however lower than the articular surface; grade 2, BTU was equivalent to the articular surface; and grade 3, BTU was higher than the articular surface.[11] Grades 1 and 2 were classified as the low uptake group and grades 3 and 4 were classified as the high uptake group (►**Fig. 2**).

Intraoperative Visual Grading of Cartilage Degeneration

The degree of cartilage degeneration underneath the patella was assessed intraoperatively. The evaluation was based on the International Cartilage Repair Society (ICRS) and recorded on the surgical record along the anatomical side of the medial and lateral facets.[25] They were categorized into two groups; the low grade group (ICRS grade 0, 1, 2, and 3) and the high grade group (ICRS grade 4) because the denuded patella was accepted for patellar resurfacing to some surgeons.[3–5]

Clinical and Radiographic Evaluations

The Feller's patella score and Western Ontario and McMaster Universities Osteoarthritis Index (WOMAC) were assessed for clinical evaluation.[26,27] To analyze how much difference in WOMAC Index score was clinically meaningful, minimal clinically important meaningful difference (MCID) in the WOMAC index score was determined according to the study of Clement et al.[28] After the score was being translated into a percentage, MCID for total score was 10, for pain was 11, for function was 9, and for stiffness was 8. Patellar tilting angle and patellar lateral shift were measured preoperatively and at 1 and 2 years postoperatively.[29] Lateral patellar tilt was measured between the line bisecting the widest portion of the patella and the line connecting the most anterior portion of the femoral condyles. Lateral patella shift was defined as the proportion of the distance from the anterior portion of the femoral condyle to the lateral portion of the patella compared with the distance between the most anterior portion of the femoral condyles.[29]

The patients were similar in terms of demographic variables, preoperative clinical and radiographic status regardless of the groups categorized by SPECT/CT and ICRS grading (►**Table 1**).

Statistical Analysis

The independent sample *t*-test and Mann–Whitney test were used to compare the demographic and radiographic data. The correlation between the degree of cartilage degeneration underneath the patella in the intraoperative field and the degree of BTU on SPECT/CT was evaluated by Goodman and Kruskal's gamma (γ) statistics. In addition, after comparing SPECT/CT and intraoperative findings, the lesions were classified according to the anatomical agreement into three groups: group matched, the anatomical sites of the most denuded lesion and the highest BTU was properly matched; group partially matched, the anatomical sites were mismatched but as BTU was found in the denuded lesion, the denuded lesion could be included in SPECT/CT;

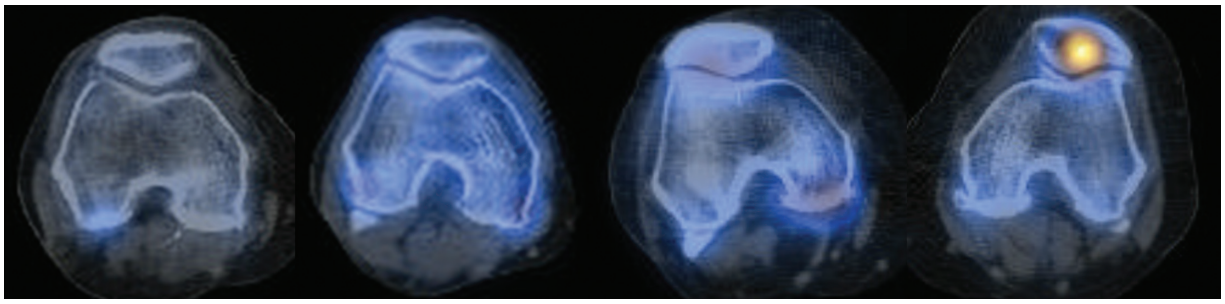

Fig. 2 The grading system of single-photon emission tomography/computed tomography for patellofemoral compartment; grade 0, BTU was equivalent to normal cancelous bone; grade 1, BTU was higher than normal cancelous bone, however, lower than the articular surface; grade 2, BTU was equivalent to the articular surface; grade 3, BTU was higher than the articular surface. BTU; bone tracer uptake.

 © 2021. Thieme. All rights reserved.

This document was downloaded for personal use only. Unauthorized distribution is strictly prohibited.

Table 1 Baseline of demographics and radiologic findings

	Gr 1–3 ($n = 166$)	Gr 4 ($n = 40$)	*p*-Value	Low uptake group ($n = 120$)	High uptake group ($n = 86$)	*p*-Value
Demographics						
Age (y)	69.5 ± 6.6	71.3 ± 5.2	0.114[a]	70.0 ± 6.7	69.7 ± 5.9	0.703[a]
BMI (kg/m^2)	27.2 ± 3.7	26.0 ± 3.2	0.061[a]	27.1 ± 3.8	26.8 ± 3.4	0.563[a]
Sex			0.655[b]			0.960[b]
Female (%)	151 (91)	38 (95)		110 (91.7)	79 (91.9)	
Male (%)	15 (9)	2 (5)		10 (8.3)	7 (8.1)	
Laterality			0.401[b]			0.814[b]
Right (%)	80 (69.0)	21 (52.5)		58 (48.3)	43 (50)	
Left (%)	86 (51.8)	19 (47.5)		62 (51.7)	43 (50)	
Physical examination						
Range of motion (degrees)	117 ± 19.6	117 ± 17.4	0.671[b]	117 ± 19.6	118 ± 19.1	0.682[b]
Radiologic findings						
Lateral patella tilt (degrees)	8.2 ± 4.3	7.5 ± 4.7	0.412[b]	8.5 ± 4.3	7.4 ± 4.5	0.217[b]
Lateral patella shift	10.5 ± 7.2	9.3 ± 8.0	0.407[b]	10.6 ± 7.4	9.8 ± 7.5	0.785[b]

Abbreviations: BMI, body mass index; Gr, the International Cartilage Repair Society grade; HU, high uptake group; LU, low uptake group.
Statistical analysis:
[a]Independent sample *t*-test.
[b]Mann–Whitney test.

and group mismatched, not only the anatomical sites were mismatched, but also the denuded lesion was not included in SPECT/CT because BTU was not observed in the denuded lesion (►**Fig. 3**). To determine the risk of the presence of denuded patellar cartilage according to the degree of BTU in SPECT/CT, a Chi-square test was performed. Repeated measures analysis of variance was utilized to compare the clinical outcomes preoperatively and 1 and 2 years postoperatively according to the intraoperative gross findings and the findings on SPECT/CT. For post hoc analysis, the Mann–Whitney test was performed where a *p*-value was corrected by the Bonferroni method. Statistical analyses were performed with SPSS 26 (SPSS Inc., Chicago, Illinois, USA). A *p*-value <0.05 was considered statistically significant.

Results

SPECT/CT reflected the degree of cartilage degeneration and the anatomical site of the cartilage lesion in the PF joint. There was a strong association between the degree of BTU and the degree of cartilage degeneration underneath the patella ($\gamma = 0.451$, $p < 0.001$; ►**Table 2**). The risk for the presence of ICRS grade 4 cartilage degeneration was greater in the high uptake group than the low uptake group (odds ratio = 5.89, 95% confidence interval: 2.69–12.92; ►**Table 2**). When comparing the anatomical site of the cartilage lesion on SPECT/CT with that on intraoperative finding, the proportion at which SPECT/CT included the intraoperative cartilage finding was 94.7% (group matched, 73.3% and group partially matched, 21.4%).

Clinical outcomes did not worsen by the severity of cartilage degeneration underneath the patella evaluated in the intraoperative field, but also the degree of BTU in preoperative SPECT/CT. There was no significant difference in clinical scores in total score and subscale score including the incidence and severity of anterior knee pain after TKA between the two groups (►**Tables 3** and **4**; ►**Figs. 4** and **5**). The WOMAC index total score was 12.9 in the low grade group and 12.2 in the high grade group, respectively at 2 years after TKA according to the ICRS grading system. In addition, the WOMAC index total score was 12.8 in the low uptake group and 12.7 in the high uptake group, respectively, 2 years after TKA ($p > 0.05$) (►**Tables 3** and **4**). Although the high uptake group showed more severe stiffness than the low uptake group at 2 years after TKA (1.1 vs. 1.6, $p = 0.007$), it did not reach a clinically meaningful difference.

Discussion

The indication for selective patellar resurfacing is controversial. Several surgeons have previously reported that denuded patella is required to be resurfaced.[4–6] Others reported that there was no difference in clinical outcomes according to the severity of PF OA regardless of patella resurfacing.[7–10] As SPECT/CT reflected the subchondral status before the structural change occurred, the evaluation of clinical outcomes related to PF after TKA according to SPECT/CT might be helpful to surgeons in managing the PF compartment.[15] The principal finding of our study was that SPECT/CT reflected the degree of cartilage degeneration underneath the patella in the patients with end-stage OA who underwent TKA. However, there was no difference in clinical outcome along the cartilage degeneration underneath the patella, as evaluated by intraoperative grading. Although the patients

 © 2021. Thieme. All rights reserved.

This document was downloaded for personal use only. Unauthorized distribution is strictly prohibited.

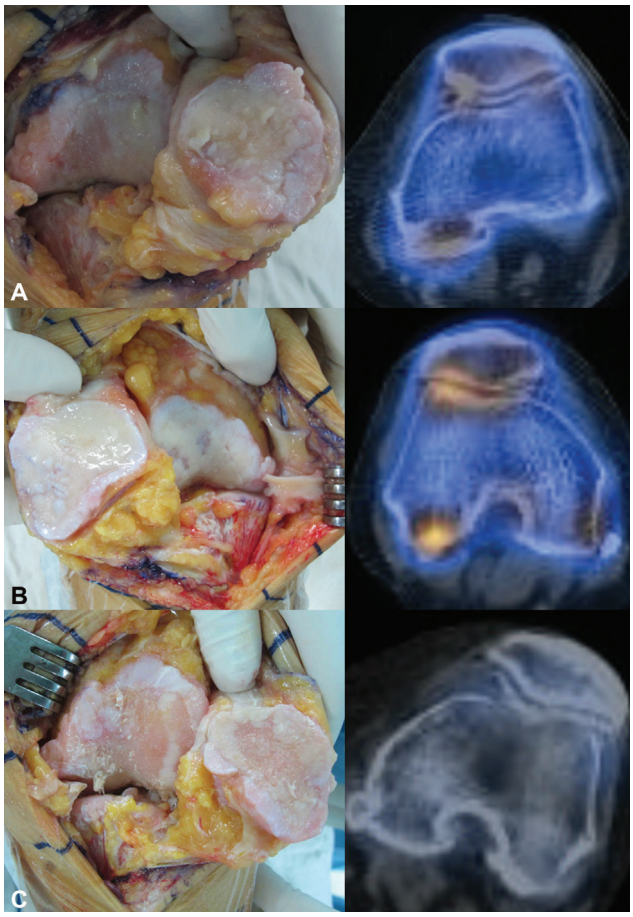

Fig. 3 Comparing the anatomical site of the cartilage lesion in SPECT/CT and in intraoperative field. After comparing SPECT/CT and intraoperative finding, the lesions were classified according to the anatomical agreement into three groups: group matched, the anatomical sites of the most denuded lesion and the highest BTU was properly matched; group partially matched, the anatomical sites were mismatched but as BTU was found in the denuded lesion, the denuded lesion could be included in SPECT/CT; and group mismatched, not only the anatomical sites were mismatched, but also the denuded lesion was not included in SPECT/CT because there was no BTU in the denuded lesion. (**A**) group matched, (**B**) group partially matched, and (**C**) group mismatched. SPECT/CT, single-photon emission tomography/computed tomography; BTU, bone tracer uptake; ICRS, International Cartilage Repair Society.

with higher uptake in SPECT/CT showed more severe stiffness after TKA, it did not reach any clinically meaningful difference. Therefore, the severity of PF OA even evaluated by SPECT/CT did not predict worse clinical and radiologic outcomes until 2 years after TKA without patellar resurfacing.

The results of our study confirmed our hypothesis that there would be increased BTU in the PF joint according to the degree of patellar cartilage degeneration. Studies have reported the relationship between the cartilage lesion on MRI, knee arthroscopy, and the BTU on SPECT/CT.[11–14] The BTU was higher as the size of the cartilage lesion increased and as the degree of cartilage degeneration was severe.[14] The degree of cartilage degeneration on knee arthroscopy was agreement with BTU in SPECT/CT ($r = 0.625$).[11] Mass et al claimed that nonmorphological cartilage lesion was found on MRI in 35% of patients with increased BTU.[13] They suggested this finding might be an early stage of cartilage pathology.[13] Our findings are in line with the studies that have demonstrated that SPECT/CT reflected the degenerative state of cartilage. A total of 73.3% (group matched) showed current cartilage degeneration and 21.4% (group partially matched) reflected the nonmorphological cartilage lesion. Therefore, SPECT/CT is probably one of the modalities to show not only the current degenerative state, but also the condition before the structural change was found.

The results of our findings did not support our hypothesis that the PF clinical outcome and functional outcome would be worse in patients with increased PF BTU in SPECT/CT. Studies have reported that there is more anterior knee pain and poor clinical outcomes after TKA without patellar resurfacing in patients with severe PF OA.[4,5] However, Studies have revealed that the severity of PF OA is not related to worse clinical and radiographic outcomes and that patellar resurfacing could not improve clinical outcomes in patients with severe PF OA.[7,10] In our study, the stiffness subscale of the WOMAC index score was statistically worse in the high uptake group on SPECT/CT. These findings seem to concur with previous reports. However, the MCID for stiffness was 8 after the score was translated into a percentage.[28,30] The difference between the two groups in our study (0.5) could be translated into 6.5 according to the aforementioned method. This suggested that although the difference in the stiffness subscale score was statistically meaningful, it did not reach any clinically meaningful difference. Therefore, there was no clinically meaningful outcome difference according to the severity of PF OA even evaluated by SPECT/CT.

Several limitations should be considered in our study. First, the study was designed retrospectively and the proportion of females was higher than males. Therefore, the same results may not apply to populations with different sex proportions. However, in Asians, it is well known that OA is more frequent in women, and even in Westerners, it is known that there are more knee OAs in women.[31–33] Thus, the author believes that our research can provide valuable information to readers. Second, methods to evaluate the clinical outcome of the PF joint have not been established.[34] Therefore, if we used another score system, the study had the possibility to show different results. Fourth, PF outcomes might be influenced not only by the patella, but also the anterior portion of the distal femur. As the anterior portion of the distal femur was resurfaced during TKA, the effect of the PF compartment might be decreased. Additionally, we did not leave the patella alone, but did several procedures such as resection of the peripheral osteophyte, patelloplasty, peripatellar neurectomy, and partial lateral facetectomy with lateral peripatellar soft tissue release. These procedures might positively affect the PF compartment. Fifth, although the stiffness subscale score did not reach any clinical meaningful difference at 2-year follow-up study, it reached the statistical difference at 2 years after surgery which did not observed in 1 year after surgery. It is possible that longer follow-up may be

This document was downloaded for personal use only. Unauthorized distribution is strictly prohibited.

Table 2 The risk for cartilage degeneration according to the bone tracer uptake in single-photon emission tomography/computed tomography

Bone tracer uptake	ICRS					γ[a]
	Gr 0 ($n=12$)	Gr 1 ($n=12$)	Gr 2 ($n=60$)	Gr 3 ($n=82$)	Gr 4 ($n=40$)	
Gr 0 ($n=11$)	1	0	6	2	2	0.451
Gr 1 ($n=109$)	10	11	33	47	8	
Gr 2 ($n=71$)	1	1	19	25	25	
Gr 3 ($n=15$)	0	0	2	8	5	
Bone tracer uptake	ICRS		Odds ratio (95% CI)		*p*-Value[b]	
	Gr 1–3 ($n=166$)	Gr 4 ($n=40$)				
Low uptake ($n=86$)	110	10	Reference value			
High uptake ($n=120$)	56	30	5.89 (2.69–12.92)		<0.001	

Abbreviations: CI, confidence interval; Gr, grade; ICRS, the International Cartilage Repair Society; SPECT/CT, single-photon emission tomography/computed tomography.
Statistical analysis:
[a]Goodman and Kruskal's gamma (γ) statistics.
[b]Chi-square test.

Table 3 Clinical outcomes after total knee arthroplasty without patellar resurfacing according to the degree of patellofemoral osteoarthritis evaluated by intraoperative findings

	Preoperative			Postoperative 1 y			Postoperative 2 y		
	Gr 1–3 ($n=166$)	Gr 4 ($n=40$)	*p*-Value[a]	Gr 1–3 ($n=166$)	Gr 4 ($n=40$)	*p*-Value[a]	Gr 1–3 ($n=166$)	Gr 4 ($n=40$)	*p*-Value[a]
Physical examination									
Range of motion (degrees)	117 (19.6)	117 (17.4)	0.671	121 (13.8)	121 (12.3)	0.952	119 (15.9)	120 (15.8)	0.421
Radiologic findings									
Lateral patella tilt (degrees)	8.2 (4.3)	7.5 (4.7)	0.412	5.2 (4.3)	5.6 (4.2)	0.591	4.5 (3.7)	5.2 (5.2)	0.965
Lateral patella shift	10.5 (7.2)	9.3 (8.0)	0.407	5.8 (6.5)	6.4 (7.0)	0.699	6.2 (5.8)	6.4 (7.4)	0.965
Incidence of anterior knee pain	62.7	57.5	0.942	15.1	12.5	0.652	14.5	17.5	0.175
Patella score									
Anterior knee pain	10.7 (4.0)	10.4 (4.6)	0.788	14.3 (1.7)	14.4 (1.7)	0.802	14.3 (1.8)	14.1 (2.3)	0.653
Quadriceps strength	4.5 (0.9)	3.9 (1.4)	0.002	4.7 (0.7)	4.8 (0.7)	0.879	4.8 (0.6)	4.6 (0.8)	0.116
Ability to rise from chair	3.1 (0.8)	2.8 (0.8)	0.044	3.8 (1.1)	3.9 (1.0)	0.837	3.9 (1.0)	4.2 (1.0)	0.105
Stair-climbing	2.5 (0.9)	2.3 (0.7)	0.240	3.6 (1.1)	3.7 (1.0)	0.584	3.8 (0.9)	3.9 (0.9)	0.728
Total	20.7 (4.8)	19.3 (5.3)	0.137	26.5 (3.0)	26.8 (3.1)	0.553	26.9 (2.9)	26.8 (3.7)	0.550
WOMAC score									
Pain	7.4 (2.9)	7.3 (2.4)	0.903	1.7 (2.4)	1.6 (3.3)	0.634	1.2 (1.8)	1.0 (1.7)	0.644
Stiffness	1.9 (1.9)	2.2 (2.1)	0.401	1.8 (1.7)	1.8 (1.8)	0.903	1.3 (1.6)	1.1 (1.3)	0.549
Function	24.8 (7.7)	24.5 (6.5)	0.798	15.1 (9.1)	13.6 (7.6)	0.519	12.9 (7.0)	12.2 (6.2)	0.650
Total	34.1 (10.5)	34.0 (9.2)	0.846	18.6 (11.7)	17.0 (10.8)	0.518	12.9 (7.0)	12.2 (6.2)	0.650

Abbreviations: TKA, total knee arthroplasty; PF, patellofemoral; Gr, the International Cartilage Repair Society grade; WOMAC, Western Ontario and McMaster Universities Osteoarthritis Index.
Note: The values are represented as mean (± standard deviation).
[a]Statistical analysis: Mann–Whitney test, *p*-value was corrected by Bonferroni method.

associated with additional outcome degradation. Finally, our findings were made among the patient who did not have patellar resurfacing. If the PF compartment with high uptake on SPECT/CT was performed with patellar resurfacing, the clinical outcome could have been different.

Conclusion

Visual assessment of the degree of cartilage degeneration underneath the patella and preoperative SPECT/CT evaluations of the PF joint were not predictive of early

 © 2021. Thieme. All rights reserved.

This document was downloaded for personal use only. Unauthorized distribution is strictly prohibited.

Table 4 Clinical outcomes after total knee arthroplasty without patellar resurfacing according to the degree of patellofemoral osteoarthritis evaluated by SPECT/CT

	Preoperative			Postoperative 1 y			Postoperative 2 y		
	LU ($n = 120$)	HU ($n = 86$)	*p*-Value[a]	LU ($n = 120$)	HU ($n = 86$)	*p*-Value[a]	LU ($n = 120$)	HU ($n = 86$)	*p*-Value[a]
Physical examination									
Range of motion (degrees)	117 (19.6)	118 (19.1)	0.682	120 (14.9)	122 (11.4)	0.416	119 (13.8)	120 (18.5)	0.165
Radiologic findings									
Lateral patella tilt (degrees)	8.5 (4.3)	7.4 (4.5)	0.217	5.8 (4.6)	4.8 (3.8)	0.729	4.9 (4.4)	4.4 (3.6)	0.905
Lateral patella shift	10.6 (7.4)	9.8 (7.5)	0.785	5.6 (6.9)	6.4 (6.2)	0.362	6.0 (6.5)	6.6 (5.8)	0.449
Incidence of anterior knee pain	62.5	60.5	0.768	16.7	11.6	0.313	13.3	17.4	0.417
Patella score									
Anterior knee pain	10.5 (4.2)	10.8 (4.0)	0.746	14.2 (1.8)	14.5 (1.5)	0.272	14.3 (2.0)	14.3 (1.7)	0.977
Quadriceps strength	4.4 (1.0)	4.4 (1.0)	0.952	4.7 (0.7)	4.7 (0.7)	0.754	4.8 (0.7)	4.8 (0.6)	0.376
Ability to rise from chair	2.9 (0.8)	3.2 (0.9)	0.013	3.9 (1.1)	3.8 (1.0)	0.671	4.0 (1.0)	4.0 (1.0)	0.532
Stair-climbing	2.4 (0.8)	2.6 (0.9)	0.093	3.6 (1.1)	3.6 (1.0)	0.889	3.8 (0.9)	3.8 (1.0)	0.901
Total	20.1 (5.0)	20.9 (4.7)	0.321	26.5 (3.1)	26.6 (2.8)	0.920	26.8 (3.3)	27.0 (2.8)	0.802
WOMAC score									
Pain	7.7 (3.1)	7.0 (2.3)	0.093	1.8 (3.0)	1.4 (2.1)	0.318	1.2 (1.8)	1.0 (1.7)	0.249
Stiffness	2.0 (2.0)	2.0 (2.0)	0.995	1.8 (1.7)	1.8 (1.7)	0.779	1.1 (1.4)	1.6 (1.6)	0.007
Function	25.6 (8.1)	23.4 (6.5)	0.112	14.9 (9.8)	14.6 (7.2)	0.558	12.8 (7.1)	12.7 (6.4)	0.780
Total	35.3 (11.3)	32.3 (8.3)	0.167	18.6 (12.8)	17.8 (9.6)	0.723	12.8 (7.1)	12.7 (6.4)	0.780

Note: The values are represented as mean (± standard deviation).
Abbreviations: HU, high uptake group; LU, low uptake group; PF, patellofemoral; SPECT/CT, single-photon emission tomography/computed tomography; TKA, total knee arthroplasty; WOMAC, Western Ontario and McMaster Universities Osteoarthritis Index.
[a]Statistical analysis: Mann–Whitney test, *p*-Value was corrected by Bonferroni method.

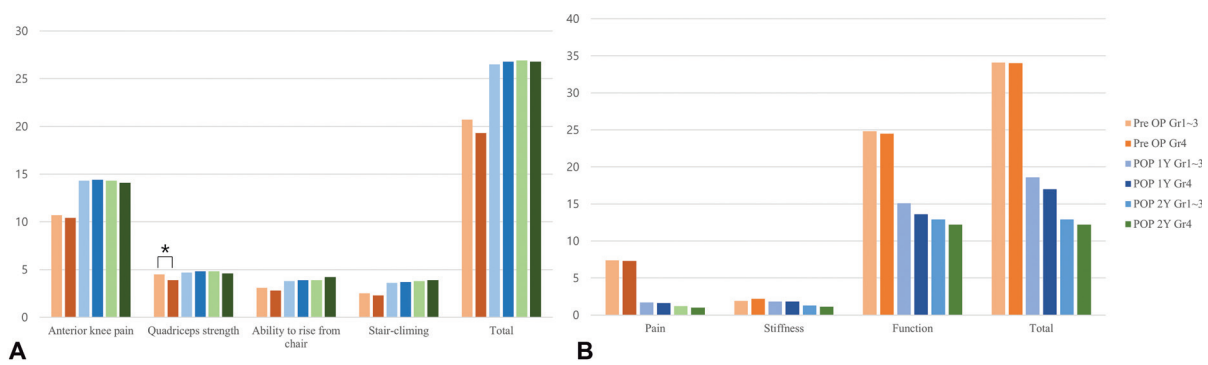

Fig. 4 Clinical outcomes after total knee arthroplasty without patellar resurfacing according to the severity of patellofemoral osteoarthritis evaluated by intraoperative findings. (**A**) Feller's patellar score and (**B**) WOMAC index score. TKA, total knee arthroplasty; Gr, the International Cartilage Repair Society grade, Preop; preoperative, POP; postoperative; WOMAC, Western Ontario and McMaster Universities Osteoarthritis Index; *p-value < 0.05.

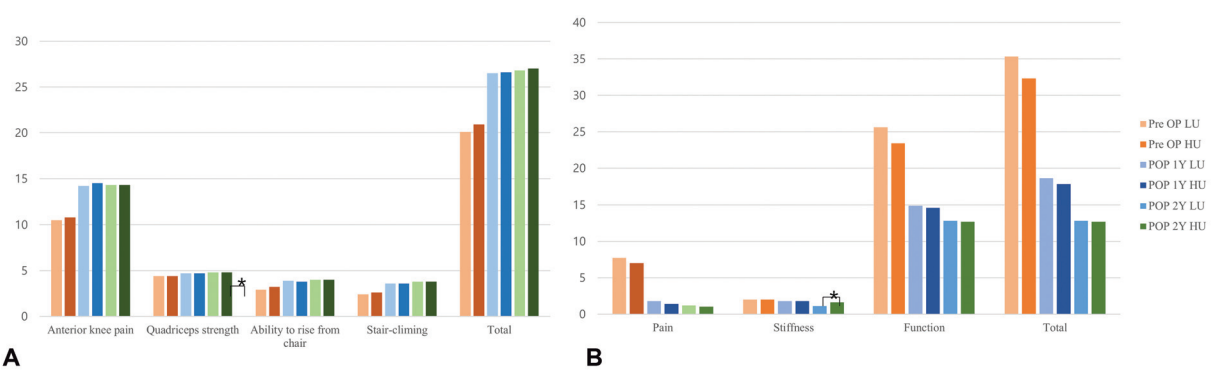

Fig. 5 Clinical outcomes after TKA without patellar resurfacing according to the severity of PF osteoarthritis evaluated by SPECT/CT. (**A**) Feller's patellar score and (**B**) WOMAC index score. Preop, preoperative; POP, postoperative; PF, patellofemoral; SPECT/CT, single-photon emission tomography/computed tomography; TKA, total knee arthroplasty; WOMAC, Western Ontario and McMaster Universities Osteoarthritis Index. *p-value < 0.05.

 © 2021. Thieme. All rights reserved.

This document was downloaded for personal use only. Unauthorized distribution is strictly prohibited.

postoperative clinical outcome after TKA performed without patellar resurfacing.

Funding
This study received its financial support from National Research Foundation (grant number 2017M3A9D80 63538).

Conflict of Interest
None declared.

References

1 Burnett RSJ, Boone JL, Rosenzweig SD, Steger-May K, Barrack RL. Patellar resurfacing compared with nonresurfacing in total knee arthroplasty. A concise follow-up of a randomized trial. J Bone Joint Surg Am 2009;91(11):2562–2567
2 Burnett RS, Bourne RB. Indications for patellar resurfacing in total knee arthroplasty. Instr Course Lect 2004;53:167–186
3 He J-Y, Jiang L-S, Dai L-Y. Is patellar resurfacing superior than nonresurfacing in total knee arthroplasty? A meta-analysis of randomized trials. Knee 2011;18(03):137–144
4 Roberts DW, Hayes TD, Tate CT, Lesko JP. Selective patellar resurfacing in total knee arthroplasty: a prospective, randomized, double-blind study. J Arthroplasty 2015;30(02):216–222
5 Rodríguez-Merchán EC, Gómez-Cardero P. The outerbridge classification predicts the need for patellar resurfacing in TKA. Clin Orthop Relat Res 2010;468(05):1254–1257
6 Bourne RB, Burnett RSJ. The consequences of not resurfacing the patella. Clin Orthop Relat Res 2004;(428):166–169
7 Cho W-J, Bin S-I, Kim J-M, Lee B-S, Sohn D-W, Kwon Y-H. Total knee arthroplasty with patellar retention: the severity of patellofemoral osteoarthritis did not affect the clinical and radiographic outcomes. J Arthroplasty 2018;33(07):2136–2140
8 Eshnazarov KE, Seon JK, Song EK. Comparison of radiological assessments patellar resurfacing with retention for grade IV osteoarthritis in patellofemoral joint accomplished total knee arthroplasty. Vestn Rentgenol Radiol 2016;97(01):28–32
9 Seo SS, Kim CW, Moon SW. A comparison of patella retention versus resurfacing for moderate or severe patellar articular defects in total knee arthroplasty: minimum 5-year follow-up results. Knee Surg Relat Res 2011;23(03):142–148
10 Raaij TMV, Meij EV, Vries AJ, Raay JJAMV. Patellar resurfacing does not improve clinical outcome in patients with symptomatic tricompartmental knee osteoarthritis. An RCT study of 40 patients receiving primary cruciate retaining total knee arthroplasty. J Knee Surg 2020
11 Ro H, Lee HY, Chang CB, Kang SB. Value of SPECT-CT imaging for middle-aged patients with chronic anterior knee pain. BMC Musculoskelet Disord 2015;16(01):169
12 Hirschmann A, Hirschmann MT. Chronic knee pain: clinical value of MRI versus SPECT/CT Semin Musculoskelet Radiol. 2016:003–011
13 Maas O, Joseph GB, Sommer G, Wild D, Kretzschmar M. Association between cartilage degeneration and subchondral bone remodeling in patients with knee osteoarthritis comparing MRI and (99m)Tc-DPD-SPECT/CT. Osteoarthritis Cartilage 2015;23 (10):1713–1720
14 Dordevic M, Hirschmann MT, Rechsteiner J, Falkowski A, Testa E, Hirschmann A. Do chondral lesions of the knee correlate with bone tracer uptake by using SPECT/CT? Radiology 2016;278(01): 223–231
15 Hirschmann MT, Rasch H, Murer M, Rotigliano N. SPECT/CT imaging of the meniscus and cartilage: what does it offer? In: Surgery of the Meniscus. Springer; 2016:163–168
16 Kim J, Kim YK, Oh SW, Chai JE. Clinical significance of knee SPECT/CT in the evaluation of patellofemoral joint of patients with chronic anterior knee pain. J Nucl Med 2016;57 (Suppl 2):1909
17 Scott RD. Femoral and tibial component rotation in total knee arthroplasty: methods and consequences. Bone Joint J 2013;95-B (11, Suppl A):140–143
18 Insall JN, Binazzi R, Soudry M, Mestriner LA. Total knee arthroplasty. Clin Orthop Relat Res 1985;(192):13–22
19 Cerciello S, Robin J, Lustig S, Maccauro G, Heyse TJ, Neyret P. The role of patelloplasty in total knee arthroplasty. Arch Orthop Trauma Surg 2016;136(11):1607–1613
20 Li T, Zhou L, Zhuang Q, Weng X, Bian Y. Patellar denervation in total knee arthroplasty without patellar resurfacing and postoperative anterior knee pain: a meta-analysis of randomized controlled trials. J Arthroplasty 2014;29(12):2309–2313
21 Yuenyongviwat V, Iamthanaporn K, Hongnaparak T. Lateral facetectomy decreased patellofemoral contact pressure in total knee replacement: a cadaveric study. J Clin Orthop Trauma 2017;8(01): 82–84
22 Zhang L-Z, Zhang X-L, Jiang Y, Wang Q, Chen Y-S, Shen H. Lateral patellar facetectomy had improved clinical results in patients with patellar-retaining total knee arthroplasty. J Arthroplasty 2012;27(08):1442–1447
23 Cho W-S, Woo J-H, Park H-Y, Youm Y-S, Kim B-K. Should the 'no thumb technique' be the golden standard for evaluating patellar tracking in total knee arthroplasty? Knee 2011;18(03):177–179
24 Hirschmann MT, Iranpour F, Davda K, Rasch H, Hügli R, Friederich NF. Combined single-photon emission computerized tomography and conventional computerized tomography (SPECT/CT): clinical value for the knee surgeons? Knee Surg Sports Traumatol Arthrosc 2010;18(03):341–345
25 Mainil-Varlet P, Aigner T, Brittberg M, et al; International Cartilage Repair Society. Histological assessment of cartilage repair: a report by the Histology Endpoint Committee of the International Cartilage Repair Society (ICRS). J Bone Joint Surg Am 2003;85-A (Suppl 2):45–57
26 Bellamy N, Buchanan WW, Goldsmith CH, Campbell J, Stitt LW. Validation study of WOMAC: a health status instrument for measuring clinically important patient relevant outcomes to antirheumatic drug therapy in patients with osteoarthritis of the hip or knee. J Rheumatol 1988;15(12):1833–1840
27 Feller JA, Bartlett RJ, Lang DM. Patellar resurfacing versus retention in total knee arthroplasty. J Bone Joint Surg Br 1996;78(02): 226–228
28 Clement ND, Bardgett M, Weir D, Holland J, Gerrand C, Deehan DJ. What is the minimum clinically important difference for the WOMAC index after TKA? Clin Orthop Relat Res 2018;476(10): 2005–2014
29 Bito H, Takeuchi R, Kumagai K, et al. Opening wedge high tibial osteotomy affects both the lateral patellar tilt and patellar height. Knee Surg Sports Traumatol Arthrosc 2010;18(07):955–960
30 Singh J, Sloan JA, Johanson NA. Challenges with health-related quality of life assessment in arthroplasty patients: problems and solutions. J Am Acad Orthop Surg 2010;18(02):72–82
31 Allen KD, Golightly YM. State of the evidence. Curr Opin Rheumatol 2015;27(03):276–283
32 Fransen M, Bridgett L, March L, Hoy D, Penserga E, Brooks P. The epidemiology of osteoarthritis in Asia. Int J Rheum Dis 2011;14 (02):113–121
33 Vina ER, Kwoh CK. Epidemiology of osteoarthritis: literature update. Curr Opin Rheumatol 2018;30(02):160–167
34 Lee C-H, Ha C-W, Kim S, Kim M, Song Y-J. A novel patellofemoral scoring system for patellofemoral joint status. J Bone Joint Surg Am 2013;95(07):620–626

This document was downloaded for personal use only. Unauthorized distribution is strictly prohibited.

 © 2021. Thieme. All rights reserved.