



Platelet-Rich Plasma Versus Hyaluronic Acid for Knee Chondral Injuries In Young Patients*

Comparação entre viscosuplementação e plasma rico em plaquetas em lesões condrais de joelhos de pacientes jovens

Marcus Vinicius Danieli^{1,2} João Paulo Fernandes Guerreiro^{1,2} Telvio Ataíde Vimercati¹
 Pedro Henrique Favaro Mendes² Paulo Raphael Tsutomu Katayama Miyazaki²
 Daniele Cristina Cataneo³

¹Knee Surgery Group, Uniorte Hospital de Ortopedia, Londrina, PR, Brazil

²Hospital Evangélico de Londrina, Londrina, PR, Brazil

³Surgery Department, Universidade Estadual Paulista (UNESP), Faculdade de Medicina, Botucatu, Botucatu, SP, Brazil

Address for correspondence Marcus Vinicius Danieli, PhD, Uniorte Hospital de Ortopedia, Av. Higienópolis, 2600, Londrina, PR, 86050-000, Brazil (e-mail: mvdanieli@hotmail.com).

Rev Bras Ortop 2021;56(5):634–640.

Abstract

Objective The present study aimed to compare the clinical and functional outcomes of hyaluronic acid (HA) or platelet-rich plasma (PRP) applications to treat young patients with knee chondral lesions with no arthrosis.

Methods Prospective clinical and functional evaluation of 30 young adult patients with knee chondral lesions submitted to conservative treatment with HA or PRP for a minimum follow-up time of 12 months. The Western Ontario and McMaster Universities Arthritis Index (WOMAC) and visual analog scale (VAS) were used for the evaluation.

Results According to the WOMAC score, the PRP group showed significant improvement in all evaluated points, whereas the HA group presented no score improvement. In the VAS, the PRP group showed improvement in all evaluated points, and the HA group presented improvement at 6 and 12 months. Compared to the HA group, the PRP group presented better WOMAC scores at all evaluated points and better VAS scores up to 6 months after treatment.

Conclusion Platelet-rich plasma application resulted in better clinical and functional outcomes at both the WOMAC and VAS scores when applied to knees from young patients with chondral lesions, but no arthrosis. These outcomes were sustained for up to 12 months.

Level of evidence Randomized clinical trial (Type 2B)

Keywords

- ▶ hyaluronic acid
- ▶ cartilage, articular
- ▶ knee
- ▶ platelet-rich plasma
- ▶ visco-supplementation

* Study developed at the Knee Surgery Group, Uniorte Hospital de Ortopedia, Londrina, PR, Brazil.

received
 April 13, 2020
 accepted
 September 17, 2020
 published online
 April 19, 2021

DOI <https://doi.org/10.1055/s-0041-1724075>
 ISSN 0102-3616.

© 2021. Sociedade Brasileira de Ortopedia e Traumatologia. All rights reserved.

This is an open access article published by Thieme under the terms of the Creative Commons Attribution-NonDerivative-NonCommercial-License, permitting copying and reproduction so long as the original work is given appropriate credit. Contents may not be used for commercial purposes, or adapted, remixed, transformed or built upon. (<https://creativecommons.org/licenses/by-nc-nd/4.0/>)

Thieme Revinter Publicações Ltda., Rua do Matoso 170, Rio de Janeiro, RJ, CEP 20270-135, Brazil

Resumo

Objetivo Comparar o resultado clínico e funcional da aplicação de ácido hialurônico (AH) ou plasma rico em plaquetas (PRP) no tratamento de pacientes jovens portadores de lesões condrais em joelhos, sem artrose.

Métodos Avaliação clínica e funcional prospectiva de 30 pacientes adultos jovens, com lesão condral no joelho, submetidos a tratamento conservador, com aplicação de AH ou PRP, com seguimento mínimo de 12 meses. Para avaliação, foi utilizado o *Western Ontario and McMaster Universities Arthritis Index* (WOMAC) e a escala visual analógica (EVA) da dor.

Resultados Avaliado pelo questionário de WOMAC, o grupo PRP mostrou melhora em todos os pontos de avaliação com significância estatística, já o grupo AH não mostrou melhora nos escores. Com relação à EVA, o PRP também mostrou melhora em todos os pontos de avaliação, e o grupo AH mostrou melhora com 6 e 12 meses. Quando comparados, o grupo PRP foi melhor que o grupo AH em todos os pontos de avaliação, de acordo com a escala de WOMAC, e até 6 meses nos resultados da EVA.

Conclusão O PRP obteve melhor resultado clínico e funcional quando aplicado em joelhos com lesões condrais de pacientes jovens, sem artrose, avaliado pelo questionário de WOMAC e pela EVA. Este resultado se manteve até 12 meses.

Nível de evidência Ensaio clínico randomizado (Tipo 2B)

Palavras-chave

- ▶ ácido hialurônico
- ▶ cartilagem articular
- ▶ joelho
- ▶ plasma rico em plaquetas
- ▶ viscos-suplementação

Introduction

The treatment of joint cartilage injuries is a challenge for orthopedists. Chondral tissue has limited intrinsic healing potential due to its complex, well-organized structure. Injuries from trauma or degenerative conditions often result in progressive tissue deterioration, leading to disabling joint pain and osteoarthritis.¹

Chondral lesions commonly involve the knee and are mostly asymptomatic. Widuchowski et al.² demonstrated that chondral lesions are observed in up to 63% of knee arthroscopies and classified 67% of such injuries as focal. For Prakash et al.,³ even these focal lesions can progress to osteoarthritis. These injuries have a wide spectrum of symptoms, ranging from sporadic crackling to pain and joint effusion and major functional limitation, impairing basic daily activities

All this sparked an interest in conservative alternatives that are less complex and less costly than surgical procedures, including joint infiltrations with hyaluronic acid (HA) and platelet-rich plasma (PRP).

Platelet-rich plasma is a solution resulting from blood collection, processing, and extraction of the platelet concentrate. It has been employed in several musculoskeletal conditions, and its autologous nature has the advantage of not causing an immunological reaction when the patient's own blood is used.

Platelet-rich plasma has been shown to stimulate chondral tissue production through growth factors and provide support for connections between chondrocytes.⁴ In addition, PRP reduces the proinflammatory action of interleukin-1, a molecule known for inducing chondrocytes and synovial cells to produce enzymes that degrade the extracellular matrix and accelerate degeneration in osteoarthritis.^{5,6} Growth factors from platelets, including transforming

growth factor beta (TGF- β),^{7,8} have chondrogenic action on chondrocytes, inhibiting their apoptosis and inducing collagen production.^{9,10}

Hyaluronic acid is a critical component in joint cartilage and synovial fluid. It consists of repeated sequences of glucuronic acid and N-acetylglucosamine. Type-B synovio-cytes synthesize and secrete HA, which has the following functions: to promote chondrocytes proliferation and differentiation¹¹ and downregulate proinflammatory cytokines, such as interleukin 8 (IL-8) and transforming growth factor alpha (TNF- α).¹² As a pharmacological agent, HA has already been shown to have anabolic, antiinflammatory and anti-nociceptive effects on chondral tissue.¹³ Hyaluronic acid also presents high biocompatibility, in addition to high viscoelastic and hygroscopic capacity. As such, HA works as a great lubricant, impact absorber, and fluid regulator due to its actions on the water balance.¹⁴

Therefore, looking beyond traditional conservative and surgical treatment options, this study seeks to evaluate the clinical and functional efficacy of PRP and HA infiltrations in chondral lesions, since there is little research about their use in young patients with prearthrosis injuries.

Materials and Methods

The present study was approved by the Ethics and Research Committee (CAAE 58459816.5.0000.0099), and all selected individuals agreed to participate in it by signing an informed consent form (ICF). This is a prospective longitudinal study following up 30 patients with cartilage lesions diagnosed using magnetic resonance imaging (MRI) and classified according to the International Cartilage Repair Society (ICRS).

The inclusion criteria were patients with chondral knee injuries up to ICRS grade III and age ranging from 18 to

50 years old, referred to conservative treatment using viscosupplementation with HA or intra-articular PRP. The patients were randomly distributed in the two groups by drawing lots. Before HA or PRP therapy, all patients were conservatively treated for at least 3 months with physical therapy and analgesic medication with no success.

The exclusion criteria were patients over 50 or under 18 years old, with arthrosis (Kellgren & Lawrence classification higher than II at the radiographic examination) and body mass index (BMI) ≥ 30 , in addition to those who refused to participate in the study.¹⁴ Non-steroidal antiinflammatory drugs were terminated for 3 weeks before HA or PRP therapy.

The PRP group was formed by 15 patients who underwent an intra-articular application of PRP. The patient's blood was collected always on the day of each infiltration.

Platelet-rich plasma was collected and prepared in a sterile manner, following the criteria required for handling blood derivatives, on an outpatient basis by a biochemist experienced in the technique. Using peripheral vein puncture, 20 mL of blood was collected in sterile, 5-mL vacutainer tubes with 10% sodium citrate. Tubes were then centrifuged at 1,200 rpm for 10 minutes at room temperature, in a Fanem® (Guarulhos, São Paulo, SP, Brazil) centrifuge with a 6.5 cm radius. This centrifugation resulted in three layers: red blood cells (bottom of the tube), white blood cells (a thin layer over the red blood cells, called buffy coat), and plasma (more superficial layer). The plasma was then transferred to another sterile, 10-mL test tube, without the buffy coat, and subjected to a new centrifugation for 5 minutes at the same rotation speed. This second centrifugation resulted in two layers; the upper half is the platelet-poor plasma, and the lower half is the platelet-rich plasma, also called platelet concentrate. This PRP (leukocytes-poor PRP) extracted was applied intra-articularly, once a week, for 3 consecutive weeks. The dose obtained for each application was 2.5 mL.

The HA group consisted in 15 patients undergoing viscosupplementation with HA. Therapy was performed once a week, for 3 consecutive weeks, with SupraHyal Duo 2.5 mg/2.5 mL (Tedec-Meiji Farma SA; Madrid, Spain, imported to Brazil by Zodiac Produtos Farmacêuticos S/A).

The patients were assessed using the Western Ontario and McMaster Universities Arthritis Index (WOMAC) questionnaire and the visual analog scale (VAS) for pain. Each patient answered both instruments 5 times: before the 1st treatment por injection, on the day of the 3rd treatment por injection and 3, 6, and 12 months after the beginning of therapy.

A linear regression model with mixed (i.e., random and fixed) effects was proposed for statistical comparisons. Linear mixed-effects models analyzed data with grouped responses (more than one measure for the same individual) and inadequate independence between observations from the same group. A posttest with orthogonal contrasts was used for comparisons. The analyses were performed with the SAS 9.2 software (SAS Institute, Cary, NC, USA). All comparisons adopted the significance level of 5%.

The study flowchart is shown in ►Figure 1.

Results

Among the 15 patients initially submitted to PRP therapy, one individual chose to discontinue treatment after the first application due to severe pain and joint effusion in the knee. The condition developed within 24 hours after the procedure and it was totally resolved in 3 days. This patient was excluded from the study, leaving the PRP group with 14 subjects. Similar symptoms were reported by two other patients from this group. They chose to continue in the study and perform the following two infiltrations, with no pain relapse.

The PRP group had 11 men and 3 women, with an average age of 34.93 years old (ranging from 18–50 years old). The HA group was composed of 11 men and 4 women, with an average age of 36.47 years old (ranging from 22–50 years old). Both groups were statistically homogeneous in laterality, age, and gender (►Table 1).

The WOMAC mean scores, standard deviation, median, minimum, and maximum values in both groups are shown in ►Table 2. The PRP group showed significantly improved scores at all assessed points when compared to baseline findings. The HA group did not present better outcomes at any time. The PRP group was better at all assessed points when compared to the HA group (►Tables 2 and 3).

Visual analog scale mean scores, standard deviation, median, minimum, and maximum values in both groups are presented in ►Table 4. Once again, the PRP group showed improvement in all assessed points, but the HA group presented better outcomes at the 6- and 12-month evaluations. In contrast, the PRP group had better outcomes at 3 and 6 months after treatment (►Tables 4 and 5).

Discussion

Platelet-rich plasma has been used successfully to treat osteoarthritis.^{15–20} These effects are even better in younger patients with milder joint involvement.^{17,21–23} However, there was still no study evaluating its application in focal knee chondral lesions with no arthrosis.

In a recent meta-analysis regarding patients with knee osteoarthritis, Chen et al.²⁴ concluded that PRP provides greater pain relief and functional improvement at 12 months when compared to HA and placebo. These authors also indicated the lack of difference in the risk of adverse effects between methods. However, they highlighted the heterogeneity both in PRP preparation and arthrosis severity. Although our outcomes were similar, we included younger subjects without osteoarthritis, expanding the therapeutic options for this technique.

The best PRP dose remains unknown, but studies suggest that repeated applications result in better functional outcomes.^{15,19,21} We opted for three applications, as in the suggested dose of HA in viscosupplementation. The best platelet concentration also remains unknown, potentially requiring an evaluation and quantification of the best growth factor or cytokine present in PRP for each target tissue.^{18,19,25,26}

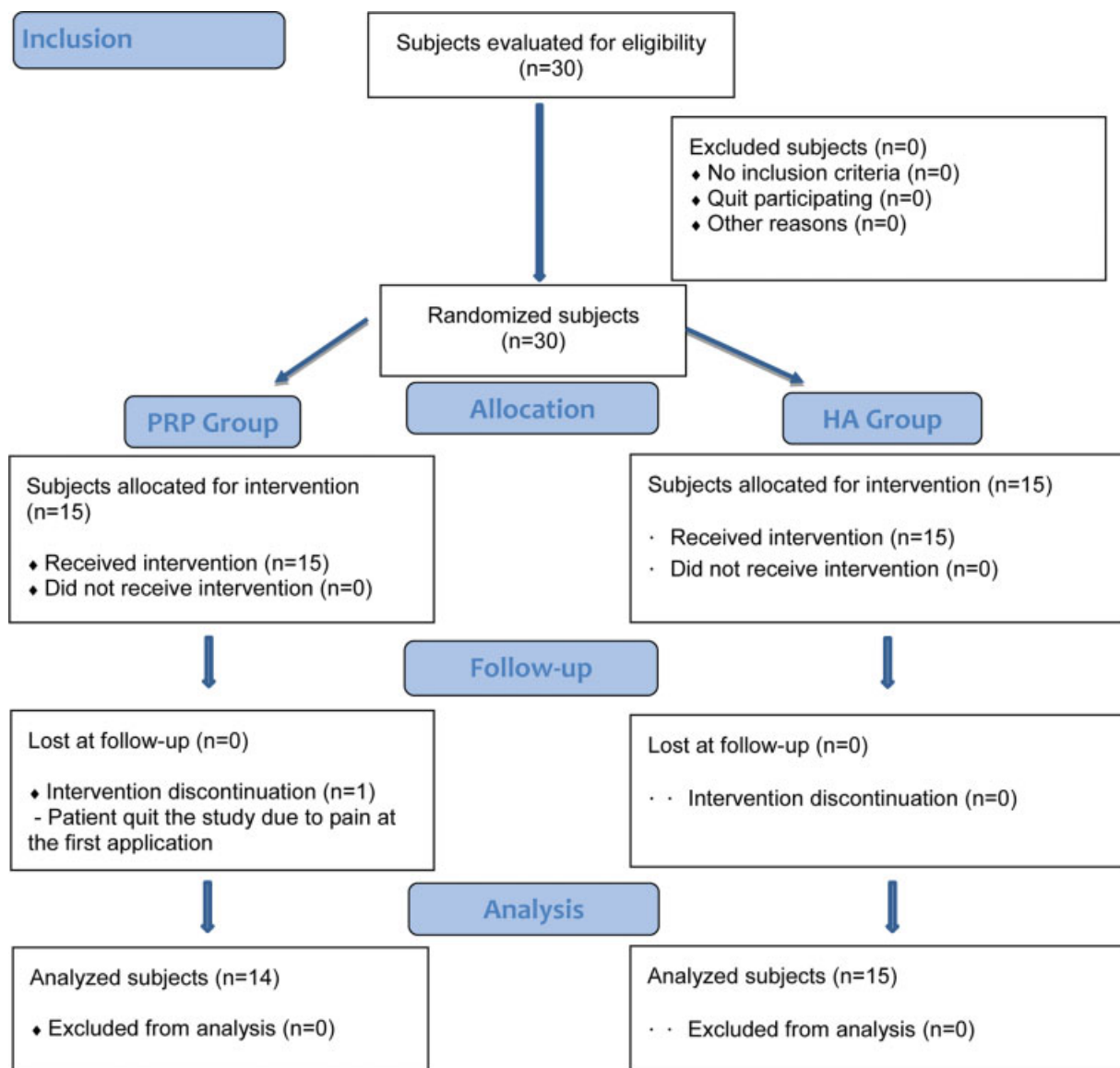


Fig. 1 Study flowchart. Abbreviations: HA, hyaluronic acid; PRP, platelet-rich plasma.

Table 1 Profile of patients from platelet-rich plasma and hyaluronic acid treated groups

GROUP	HA	PRP
N	15	14
Mean age (minimum and maximum value)	36.47 (22-50)	34.93 (18-50)
Female gender	4	3
Male gender	11	11
Right side	7	3
Left side	3	8
Bilateral	5	4

Abbreviations: HA, hyaluronic acid; PRP, platelet-rich plasma.

Leukocytes can cause adverse effects, such as reaction arthritis; in addition, these cells stimulate chondral catabolism.^{23,27} As a result, we used a leukocyte-poor PRP which may have influenced the outcomes in favor of this therapy.

In a meta-analysis, Han et al.²⁸ found similar WOMAC, VAS, and International Knee Documentation Committee (IKDC) scores for PRP and HA from the 1st to the 3rd month after treatment. However, 6 and 12 months after treatment, PRP was the only technique able to sustain the functional and pain improvement observed within the first months. These authors also pointed out that there is no difference for adverse effects between PRP and HA, and that PRP is better for mild or moderate arthrosis cases.

Di et al.,²⁹ in a systematic review, showed that PRP would be better to improve WOMAC scores for a minimum period of 24 weeks. However, the same study analyzed other pain measurements, such as IKDC and VAS, and found no statistical difference when compared to viscosupplementation. Tavassoli et al.³⁰ highlighted that only PRP was able to improve WOMAC scores by more than 30% when compared to 3 HA infiltrations for 3 consecutive weeks. This improvement was significantly greater when 2 doses of PRP were administered at 3-week intervals compared to a single dose.

Table 2 WOMAC score from platelet-rich plasma and hyaluronic acid treated groups

WOMAC						
GROUP	Time	Mean	Standard deviation	Minimum value	Median	Maximum value
PRP	Preoperative	34.78	16.99	1	37.5	61
	Postoperative	20.56	13.56	1	17.0	50
	3 months	16.94	10.32	1	13.5	45
	6 months	16.39	10.81	1	14.5	40
	12 months	19.33	13.86	1	16.0	48
HA	Preoperative	23.95	17.48	2	20.5	62
	Postoperative	21.35	21.18	1	15.0	79
	3 months	24.45	25.96	2	14.5	85
	6 months	21.80	19.69	1	13.5	63
	12 months	25.80	19.68	2	21.5	63

Abbreviations: HA, hyaluronic acid; PRP, platelet-rich plasma.

Table 3 Comparison of WOMAC scores from the platelet-rich plasma and hyaluronic acid treated groups in different times

Comparisons	Estimated value	P-value
PRP (preoperative x postoperative)	14.22	< 0.01
PRP (preoperative x 3 months)	17.83	< 0.01
PRP (preoperative x 6 months)	18.39	< 0.01
PRP (preoperative x 12 months)	15.44	< 0.01
HA (preoperative x postoperative)	2.6	0.34
HA (preoperative x 3 months)	-0.5	0.85
HA (preoperative x 6 months)	2.15	0.43
HA (preoperative x 12 months)	-1.85	0.50
Postoperative (PRP x HA)	15.70	< 0.01
3 months (PRP x HA)	16.27	< 0.01
6 months (PRP x HA)	16.67	< 0.01
12 months (PRP x HA)	17.72	< 0.01

Abbreviations: HA, hyaluronic acid; PRP, platelet-rich plasma.

Table 4 Visual analog scale for pain from platelet-rich plasma and hyaluronic acid treated groups

PAIN SCORE						
GROUP	Time	Mean	Standard deviation	Minimum value	Median	Maximum value
PRP	Preoperative	6.06	2.62	0	6.0	10
	Postoperative	4.50	2.36	0	5.0	8
	3 months	4.50	2.36	0	5.0	8
	6 months	3.67	2.11	0	4.5	7
	12 months	4.06	1.76	1	4.5	6
HA	Preoperative	5.95	2.58	0	6.0	10
	Postoperative	5.20	3.12	0	5.5	10
	3 months	5.20	3.40	0	5.0	10
	6 months	4.85	2.96	0	5.0	10
	12 months	4.50	2.31	1	5.0	8

Abbreviations: HA, hyaluronic acid; PRP, platelet-rich plasma; VAS, visual analog scale.

The routine clinical use of intra-articular PRP is not yet a reality in Brazil and its application is only approved for research purposes. Nevertheless, our study showed that PRP is effective in young patients with chondral knee injuries since it reduces daily activities limitations and patient's overall pain, as determined by the WOMAC and VAS scores, respectively.

On the other hand, HA showed improvement only for 6 months after the application, with effects lasting up to 12 months when evaluated by VAS, and less consistent WOMAC outcomes. In addition, there are several PRP and HA formulas, with different preparation methods and platelet concentrations for PRP and, different molecular weights for viscosupplementation.

One limitation of our study was the small number of patients. This limitation resulted from the difficulty of using both PRP and HA in Brazil due to legal restrictions and costs, respectively. The lack of a control or sham group may be a source of bias. The absence of blinding can be considered a

Table 5 Comparison of visual analog scale for pain scores from the platelet-rich plasma and hyaluronic acid treated groups in different times

Comparisons	Estimated value	P-value
PRP (preoperative x postoperative)	1.56	< 0.01
PRP (preoperative x 3 months)	1.56	< 0.01
PRP (preoperative x 6 months)	2.39	< 0.01
PRP (preoperative x 12 months)	2.00	< 0.01
HA (preoperative x postoperative)	0.75	0.09
HA (preoperative x 3 months)	0.75	0.09
HA (preoperative x 6 months)	1.10	0.01
HA (preoperative x 12 months)	1.45	< 0.01
Postoperative (PRP x HA)	2.12	< 0.01
3 months (PRP x HA)	2.12	< 0.01
6 months (PRP x HA)	1.98	0.02
12 months (PRP x HA)	1.24	0.14

Abbreviations: HA, hyaluronic acid; PRP, platelet-rich plasma; VAS, visual analog scale.

limitation, but we chose to not collect blood from patients randomized to the HA group.

Therefore, in addition to conservative measures, including patient education regarding their injury and limitations, physical activity guidelines for muscle strengthening, weight loss, and use of analgesic and antiinflammatory agents, both methods must be considered in the treatment of knee chondral lesions in young patients. However, further studies in subjects with this type of lesion are required to strengthen the scientific basis.

Conclusion

Based on our findings, we conclude that PRP led to better clinical and functional outcomes, assessed per the WOMAC and VAS scores, when used in young patients with knee chondral lesions and no arthrosis. This outcome was sustained for up to 12 months.

Financial Support

There was no financial support from public, commercial, or non-profit sources.

Conflict of Interests

The authors declare no conflict of interests during this study.

References

- Lories RJ, Luyten FP. The bone-cartilage unit in osteoarthritis. *Nat Rev Rheumatol* 2011;7(01):43–49
- Widuchowski W, Widuchowski J, Trzaska T. Articular cartilage defects: study of 25,124 knee arthroscopies. *Knee* 2007;14(03):177–182
- Prakash D, Learmonth D. Natural progression of osteo-chondral defect in the femoral condyle. *Knee* 2002;9(01):7–10
- Sánchez M, Anitua E, Orive G, Mujika I, Andia I. Platelet-rich therapies in the treatment of orthopaedic sport injuries. *Sports Med* 2009;39(05):345–354
- van Buul GM, Koevoet WLM, Kops N, et al. Platelet-rich plasma releasate inhibits inflammatory processes in osteoarthritic chondrocytes. *Am J Sports Med* 2011;39(11):2362–2370
- Sundman EA, Cole BJ, Karas V, et al. The anti-inflammatory and matrix restorative mechanisms of platelet-rich plasma in osteoarthritis. *Am J Sports Med* 2014;42(01):35–41
- Sánchez M, Anitua E, Azofra J, Aguirre JJ, Andia I. Intra-articular injection of an autologous preparation rich in growth factors for the treatment of knee OA: a retrospective cohort study. *Clin Exp Rheumatol* 2008;26(05):910–913
- Lubkowska A, Dolegowska B, Banfi G. Growth factor content in PRP and their applicability in medicine. *J Biol Regul Homeost Agents* 2012;26(02 Suppl 1):3S–22S
- Pavlovic V, Ciric M, Jovanovic V, Stojanovic P. Platelet Rich Plasma: a short overview of certain bioactive components. *Open Med (Wars)* 2016;11(01):242–247
- Parrish WR, Roides B. Platelet rich plasma in osteoarthritis: more than a growth factor therapy. *Musculoskelet Regen* 2017;3:e1518
- Kawasaki K, Ochi M, Uchio Y, Adachi N, Matsusaki M. Hyaluronic acid enhances proliferation and chondroitin sulfate synthesis in cultured chondrocytes embedded in collagen gels. *J Cell Physiol* 1999;179(02):142–148
- Wang CT, Lin YT, Chiang BL, Lin YH, Hou SM. High molecular weight hyaluronic acid down-regulates the gene expression of osteoarthritis-associated cytokines and enzymes in fibroblast-like synoviocytes from patients with early osteoarthritis. *Osteoarthritis Cartilage* 2006;14(12):1237–1247
- Ghosh P. Osteoarthritis and hyaluronan—palliative or disease-modifying treatment? *Semin Arthritis Rheum* 1993;22(06 Suppl 1):1–3
- Laurent TC, Laurent UBG, Fraser JRE. The structure and function of hyaluronan: An overview. *Immunol Cell Biol* 1996;74(02):A1–A7
- Kavadar G, Demircioglu DT, Celik MY, Emre TY. Effectiveness of platelet-rich plasma in the treatment of moderate knee osteoarthritis: a randomized prospective study. *J Phys Ther Sci* 2015;27(12):3863–3867
- Meheux CJ, McCulloch PC, Lintner DM, Varner KE, Harris JD. Efficacy of Intra-articular Platelet-Rich Plasma Injections in Knee Osteoarthritis: A Systematic Review. *Arthroscopy* 2016;32(03):495–505
- Kanchanatawan W, Arirachakaran A, Chaijenkij K, et al. Short-term outcomes of platelet-rich plasma injection for treatment of osteoarthritis of the knee. *Knee Surg Sports Traumatol Arthrosc* 2016;24(05):1665–1677
- Dai WL, Zhou AG, Zhang H, Zhang J. Efficacy of Platelet-Rich Plasma in the Treatment of Knee Osteoarthritis: A Meta-analysis of Randomized Controlled Trials. *Arthroscopy* 2017;33(03):659–670.e1
- Milano G, Sánchez M, Jo CH, Saccomanno MF, Thampatty B, Wang JH. Platelet-rich plasma in orthopaedic sports medicine: state of the art. *J ISAKOS* 2019;4:188–195
- Louis ML, Magalon J, Jouve E, et al. Growth Factors Levels Determine Efficacy of Platelets Rich Plasma Injection in Knee Osteoarthritis: A Randomized Double Blind Noninferiority Trial Compared With Viscosupplementation. *Arthroscopy* 2018;34(05):1530–1540.e2
- Görmeli G, Görmeli CA, Ataoglu B, Çolak C, Aslantürk O, Ertem K. Multiple PRP injections are more effective than single injections and hyaluronic acid in knees with early osteoarthritis: a randomized, double-blind, placebo-controlled trial. *Knee Surg Sports Traumatol Arthrosc* 2017;25(03):958–965
- Mascarenhas R, Saltzman BM, Fortier LA, Cole BJ. Role of platelet-rich plasma in articular cartilage injury and disease. *J Knee Surg* 2015;28(01):3–10

- 23 Levy DM, Petersen KA, Scalley Vaught M, Christian DR, Cole BJ. Injections for Knee Osteoarthritis: Corticosteroids, Viscosupplementation, Platelet-Rich Plasma, and Autologous Stem Cells. *Arthroscopy* 2018;34(05):1730–1743
- 24 Chen P, Huang L, Ma Y, et al. Intra-articular platelet-rich plasma injection for knee osteoarthritis: a summary of meta-analyses. *J Orthop Surg Res* 2019;14(01):385
- 25 Oh JH, Kim W, Park KU, Roh YH. Comparison of the Cellular Composition and Cytokine-Release Kinetics of Various Platelet-Rich Plasma Preparations. *Am J Sports Med* 2015;43(12):3062–3070
- 26 Ha CW, Park YB, Jang JW, Kim M, Kim JA, Park YG. Variability of the Composition of Growth Factors and Cytokines in Platelet-Rich Plasma From the Knee With Osteoarthritis. *Arthroscopy* 2019;35(10):2878–2884.e1
- 27 Riboh JC, Saltzman BM, Yanke AB, Fortier L, Cole BJ. Effect of Leukocyte Concentration on the Efficacy of Platelet-Rich Plasma in the Treatment of Knee Osteoarthritis. *Am J Sports Med* 2016;44(03):792–800
- 28 Han Y, Huang H, Pan J, et al. Meta-analysis Comparing Platelet-Rich Plasma vs Hyaluronic Acid Injection in Patients with Knee Osteoarthritis. *Pain Med* 2019;20(07):1418–1429
- 29 Di Y, Han C, Zhao L, Ren Y. Is local platelet-rich plasma injection clinically superior to hyaluronic acid for treatment of knee osteoarthritis? A systematic review of randomized controlled trials. *Arthritis Res Ther* 2018;20(01):128
- 30 Tavassoli M, Janmohammadi N, Hosseini A, Khafri S, Esmailnejad-Ganji SM. Single- and double-dose of platelet-rich plasma versus hyaluronic acid for treatment of knee osteoarthritis: A randomized controlled trial. *World J Orthop* 2019;10(09):310–326