


# Outbreak of Enterovirus Infection with Neurological Presentations in a Pediatric Population in Northern Spain: A Clinical Observational Study

Antonio Hedrera-Fernandez<sup>1,2</sup>  Ramon Cancho-Candela<sup>1</sup> Marta Arribas-Arceredillo<sup>1</sup>  
 Maria Garrido-Barbero<sup>3</sup> David Conejo-Moreno<sup>3</sup> Andrea Sario-Jamardo<sup>4</sup>  
 Maria Socorro Perez-Poyato<sup>4</sup> Cristina Rodriguez-Fernandez<sup>5</sup> Pablo del Villar-Guerra<sup>6</sup>  
 Ignacio Bermejo-Arnedo<sup>7</sup> Alfonso Peña-Valenceja<sup>8</sup> Esther Maldonado-Ruiz<sup>8</sup>  
 Saturnino Ortiz-Madinaveitia<sup>9</sup> Ana Belen Camina-Gutierrez<sup>10</sup> Raquel Blanco-Lago<sup>2</sup> Ignacio Malaga<sup>2</sup>

<sup>1</sup> Paediatric Neurology Unit, Hospital Universitario Rio Hortega, Valladolid, Spain

<sup>2</sup> Paediatric Neurology Unit, Hospital Universitario Central de Asturias, Oviedo, Asturias, Spain

<sup>3</sup> Department of Paediatrics, Hospital Universitario de Burgos, Burgos, Spain

<sup>4</sup> Paediatric Neurology Unit, Hospital Universitario Marques de Valdecilla, Santander, Cantabria, Spain

<sup>5</sup> Paediatric Neurology Unit, Hospital Universitario de Leon, León, Spain

<sup>6</sup> Department of Paediatrics, Hospital General de Segovia, Segovia, Spain

<sup>7</sup> Paediatric Neurology Unit, Hospital Universitario de Salamanca, Salamanca, Spain

<sup>8</sup> Department of Paediatrics, Hospital General Rio Carrion, Palencia, Spain

<sup>9</sup> Department of Paediatrics, Hospital Santa Barbara, Soria, Spain

<sup>10</sup> Department of Paediatrics, Hospital Santos Reyes, Aranda de Duero, Burgos, Spain

Address for correspondence Antonio Hedrera-Fernández, MD, Paediatric Neurology Unit, Hospital Universitario Central de Asturias, Avenida de Roma s/n, 33011 Oviedo, Asturias, Spain (e-mail: antonio.hedreraf@sespa.es).

Neuropediatrics 2021;52:192–200.

## Abstract

### Keywords

- ▶ enterovirus
- ▶ rhombencephalitis
- ▶ brainstem encephalitis
- ▶ acute flaccid myelitis
- ▶ enterovirus A-71
- ▶ enterovirus D-68

**Objective** The study aimed to describe the cases of neurological disease related to the outbreak of enterovirus (EV) in three regions in Northern Spain during 2016.

**Materials and Methods** Multicenter retrospective observational study. Clinical, radiological, and microbiological data were analyzed from patients younger than 15 years with confirmed EV-associated neurological disease admitted to 10 hospitals of Asturias, Cantabria, and Castile and Leon between January 1 and December 31, 2016.

**Results** Fifty-five patients were included. Median age was 24 months (interquartile range = 18.5 months). Fifteen patients were classified as aseptic meningitis (27.3%). In total, 37 cases presented brainstem encephalitis (67.3%), 25 of them due to EV-A71 with excellent prognosis (84.6% asymptomatic 2 months following the onset). Three cases of acute flaccid myelitis (5.5%) by EV-D68 were reported and presented persistent paresis 2 months following the onset. Microbiological diagnosis by reverse transcriptase polymerase chain reaction was performed in all cases, finding EV in cerebrospinal fluid in meningitis, but not in brainstem encephalitis and acute flaccid myelitis, where EV was found in respiratory or rectal samples. Step therapy was administered with intravenous immunoglobulin (IVIG; 32.7%), methylprednisolone (10%), and plasmapheresis (3.6%). Four

received

October 15, 2020

accepted after revision

January 14, 2021

published online

March 3, 2021

© 2021, Thieme. All rights reserved.  
 Georg Thieme Verlag KG,  
 Rüdigerstraße 14,  
 70469 Stuttgart, Germany

DOI <https://doi.org/10.1055/s-0041-1725008>.  
 ISSN 0174-304X.

patients received fluoxetine (7.3%). Twenty patients needed to be admitted to pediatric intensive care unit (36.4%).

**Conclusion** Clinical, microbiological, and radiological diagnosis is essential in outbreaks of EV neurological disease, taking into account that it can be difficult to identify EV-A71 and EV-D68 in CSF, requiring throat or rectal samples. There is not specific treatment to these conditions and the efficacy and understanding of the mechanism of action of immunomodulatory treatment (IVIG, corticosteroids, and plasmapheresis) is limited.

## Introduction

Nonpolio human enteroviruses (EV) are single-stranded RNA viruses that belong to the family *Picornaviridae* and are divided into four species named A to D. EV infect millions of people worldwide every year,<sup>1</sup> manifesting among other as pharyngitis, herpangina; hand, foot, and mouth disease (HFMD); myocarditis; and aseptic meningitis,<sup>2</sup> while also it is considered to be the main cause of viral meningitis worldwide.<sup>3</sup> In addition to meningitis, EV infections can cause central nervous system (CNS) disease as encephalitis, brainstem encephalitis (also called rhombencephalitis), and acute flaccid myelitis (AFM).<sup>4</sup>

The peak seasonality of EV infections occurs in summer<sup>2</sup> and its transmission occurs mainly via the fecal-oral route and to a lesser extent by respiratory droplets.<sup>3</sup>

Since the 1970s, there have been several reports of EV outbreaks, especially in the Asia-Pacific region and eastern Europe, related with serotypes A-71 (EV-A71) and D-68 (EV-D68).<sup>4-6</sup>

In Spain, an outbreak of EV-A71 infection with acute neurological symptoms was reported between April and September 2016. More than 100 children were affected, according to data from the Spanish National Microbiology Centre,<sup>7</sup> presenting aseptic meningitis, encephalitis, brainstem encephalitis, and myelitis. The geographical distribution of cases was variable according to the different reports: Catalonia had the first and most numerous reports with 65 confirmed cases of EV-A71 with neurological involvement<sup>8,9</sup> followed by other crowded regions as Madrid (26 cases).<sup>10,11</sup> In other regions, sporadic cases were reported: only one case of aseptic meningitis by EV-A71 was reported in the Balearic Islands<sup>12</sup> and four not-typed EV related with brainstem encephalitis in Andalusia.<sup>13</sup> Phylogenetic analysis showed that most of these EV-A71 belonged to subgenogroup C1<sup>7</sup> that had not previously been detected in Spain<sup>14</sup> and seemed related to EV-A71 C1 viruses identified in Germany<sup>15,16</sup> and France,<sup>17</sup> which probably spread to Spain.

During the same period of time, three cases of EV-D68 infection with acute flaccid paralysis (AFP) were reported, first in Aragon in December 2015 and later in Catalonia and Galicia on February and March 2016, respectively.<sup>18,19</sup>

The aim of this research is to describe the cases of CNS disease related to the outbreak of EV-A71 and EV-D68 in three regions in Northern Spain: Asturias, Cantabria, and Castile and Leon.

## Materials and Methods

Inclusion criteria for this multicenter retrospective observational study consisted of children younger than 14 years with EV-associated neurological disease (which included aseptic meningitis, encephalitis, or acute flaccid myelitis) admitted to 10 hospitals of Asturias (114,498 inhabitants younger than 14 years<sup>20</sup>), Cantabria (78,980 inhabitants younger than 14 years<sup>20</sup>), and Castile and Leon (295,360 inhabitants younger than 14 years<sup>20</sup>) between January 1 and December 31, 2016.

Microbiological diagnosis of EV infection was required in all cases, detected by reverse transcriptase polymerase chain reaction (RT-PCR) testing on cerebrospinal fluid (CSF), pharyngeal, or rectal specimens. These samples were tested in the local laboratory of each hospital and in some of the cases were also retested in the EV laboratory of the Spanish National Centre of Microbiology to confirm the result or for genotyping purposes.

Neurological disease related with EV was defined according to World Health Organization (WHO)<sup>21</sup> and Centers for Disease Control and Prevention (CDC)<sup>22</sup> classifications as showed in ►Table 1.

Diagnostic and therapeutic interventions were decided by the local treating team according to current clinical guidelines.<sup>21,23</sup> Data were collected retrospectively through accessing the research database.

Descriptive statistics were used to characterize the cohort of children with enteroviral neurological disease. Categorical data were compared by using Chi-square test and Fisher's exact test. Quantitative data were compared by using Student's *t*-test, ANOVA, Mann-Whitney U test, and Kruskal-Wallis test. Statistical significance was defined as  $p < 0.05$ . Data were statistically analyzed with IBM SPSS Statistics version 24.

Research and data collection protocols have been approved by the local ethics committee.

## Results

### Patient Demographics

Fifty-five patients younger than 14 years were admitted to hospital with confirmed EV infection and associated neurological disease during 2016. In total, 15 were classified as aseptic meningitis (27.3%), 37 as brainstem encephalitis (67.3%) and 3 as acute flaccid myelitis (5.5%; a 22-month-old female in March in León, a 6-year-old boy in May in Oviedo, and a 4-year-old boy in September in Segovia).

**Table 1** Case definitions of neurological disease related with enteroviruses according to World Health Organization and Centers for Disease Control and Prevention classifications, including grades of rhombencephalitis proposed by Huang et al

<b>Aseptic meningitis</b>	Febrile illness with headache, vomiting, and meningism associated with presence of more than 10 white cells per cubic millimeter in CSF and negative results on CSF bacterial culture
<b>Encephalitis</b>	Impaired consciousness (lethargy, drowsiness, or coma) plus MRI and/or EEG suggestive abnormalities
<b>Brainstem encephalitis</b> (also called rhombencephalitis)	Myoclonus, ataxia, tremor, nystagmus, oculomotor palsies, and bulbar palsy in various combinations <b>Grade I:</b> generalized myoclonic jerks with tremor, ataxia, or both <b>Grade II:</b> myoclonus with cranial-nerve involvement, including ocular disturbances (nystagmus, strabismus, or gaze paresis) and bulbar palsy (dysphagia, dysarthria, dysphonia, and facial weakness) <b>Grade III:</b> transient myoclonus followed by the rapid onset of respiratory distress, cyanosis, poor peripheral perfusion, shock, coma, loss of the doll's eye reflex and apnea
<b>Acute flaccid myelitis</b>	Acute onset of flaccid limb weakness with longitudinal gray-matter predominant spinal cord lesion noted on MRI

Abbreviations: CSF, cerebrospinal fluid; EEG, electroencephalography; MRI, magnetic resonance imaging.

The global incidence of neurological disease by EV in 2016 in the three studied regions was 11.25 cases per 100,000 inhabitants younger than 14 years (calculated over a total population younger than 14 years of 488,838 in Asturias, Cantabria, and Castile and Leon<sup>20</sup>).

The total number of EV infections in this period in the entire geographic area is unknown. However, there are data from some specific centers. For example, in one of the participating centers, 47 samples were detected positive for EV by PCR (32 in respiratory samples, 10 in stool, and 5 in CSF), of which 14 presented neurological symptoms (29.79%).

Main features of the study participants are shown in ▶Table 2. No statistically significant differences were observed based on gender distribution. Median age at debut was 24 months, with a minimum of 21 days and a maximum of 13 years and 10 months. The first case was registered on March 10 and the last on October 25 with a clear predominance of cases during spring and summer (▶Fig. 1).

### Non-Neurological Manifestations

As presented in ▶Table 2, nearly all patients (98.2%) had fever, and the maximum temperature was significantly higher in patients with brainstem encephalitis when compared with other neurological presentations ( $p = 0.021$ ). The presence of gastrointestinal ( $p = 0.002$ ) and respiratory illness ( $p = 0.03$ ) in patients with brainstem encephalitis and AFM was significantly increased when compared with meningitis. Of the 13 patients with HFMD, 10 (76.9%) were positive for EV-A71 ( $p = 0.014$ ).

### Neurological Manifestations

Neurological involvement appeared within a median of 24 hours (interquartile range [IQR]:  $P_{25}$ – $P_{75}$ ; 0–48 hours) after onset of non-neurological symptoms.

### Brainstem Encephalitis

Patients classified as brainstem encephalitis presented with ataxia (83.8%), lethargy (59.5%), tremor (48.6%), myoclonus (29.7%), and dysmetria (10.8%). Thirty cases can be classified as grade I rhombencephalitis. Seven patients can be classified

as grade II rhombencephalitis due to cranial nerve impairment: dysphagia (two cases), strabismus (two cases), facial weakness (one case), dysarthria (one case) and nystagmus (one case).

Only one patient presented dysautonomic signs, consisting of mild and limited cyanosis and bradycardia, without fulfilling criteria to be classified as grade III.

Three patients with brainstem encephalitis presented focal hemiconic seizures and needed treatment with levetiracetam.

One case of brainstem encephalitis presented cervicgia and cervical myelitis was demonstrated in the magnetic resonance imaging (MRI), without any other symptom.

### Aseptic Meningitis

Patients classified as isolated aseptic meningitis did not present any of the previously described symptoms, but cervical stiffness (46.7%), Kernig's and Brudzinski's signs (40%), and headache (40%).

However, some patients with brainstem encephalitis presented also nuchal rigidity (43.2%), headache (21.6%), Kernig's (24.3%), and Brudzinski's (16.2%) signs.

### Acute Flaccid Myelitis

The three patients classified as AFM showed acute flaccid paralysis (100%), with hypotonia (66.7%) and areflexia (33.3%). One of them presented as acute flaccid monoparesis of the right upper limb, another as acute flaccid diparesis of both upper limbs, and the more severe case as acute flaccid tetraparesis with a patchy pattern. Severe motor axonal involvement was detected in the nerve conduction studies in all cases. All of them also presented with cranial nerve impairment (one with facial paresis, one with bilateral optic neuritis and one with vocal cord paralysis), as well as signs of bulbar paralysis (two cases with dysphagia and one case with dysarthria).

### Virological Findings

In all patients RT-PCR was positive to EV (inclusion criterion). RT-PCR in CSF detected EV in 86.7% of patients

**Table 2** Patient demographics and non-neurological manifestations

	Total	Aseptic meningitis	Brainstem encephalitis	Acute flaccid myelitis	p-value
<i>n</i>	55	15 (27.3%)	37 (67.3%)	3 (5.5%)	
<b>Sex</b>					0.043
Male	26 (47.3%)	4 (26.7%)	21 (56.8%)	1 (33.3%)	
Female	29 (52.7%)	11 (73.3%)	16 (43.2%)	2 (66.7%)	
<b>Age of onset (mo)</b>					0.386
Median (P <sub>25</sub> -P <sub>75</sub> )	24 (14.75-33.25)	34 (0.96-94)	24 (18.18-31.04)	50 (36-62.5)	
<b>Date of clinical onset</b>					
First case	10/03/2016	14/03/2016	19/04/2016	10/03/2016	
Last case	25/10/2016	25/10/2016	24/10/2016	29/09/2016	
<b>Hospital admission (d)</b>					<0.001
Median (P <sub>25</sub> -P <sub>75</sub> )	6 (2-10)	4 (3-5)	6 (4.25-13.75)	64 (50-108)	
<b>Patients admitted to PICU</b>	20 (36.4%)	0	17 (45.9%)	3 (100%)	<0.001
<b>PICU admission (d)</b>					0.007
Median (P <sub>25</sub> -P <sub>75</sub> )	7 (3.5-10.5)	0	5.50 (3.25-7.75)	63 (49.5-75.5)	
<b>Non-neurological manifestations</b>					
<b>Fever</b>	54 (98.2%)	14 (93.3%)	37 (100%)	3 (100%)	0.327
Maximum temperature, °C Median (P <sub>25</sub> -P <sub>75</sub> )	38.5 (38.1-38.9)	38.3 (38.0-38.7)	38.9 (38.45-39.4)	38.3 (38.15-38.4)	0.021
<b>Irritability</b>	27 (49.1%)	7 (46.7%)	18 (48.6%)	2 (66.7%)	1
<b>Respiratory illness</b>	16 (29.1%)	1 (6.7%)	12 (32.4%)	3 (100%)	0.003
Cough	12 (21.8%)	0	11 (29.7%)	1 (33.3%)	0.028
Rhinorrhea	12 (21.8%)	1 (6.7%)	10 (27%)	1 (33.3%)	0.244
Respiratory distress/ paralysis	7 (12.7%)	0	4 (22.2%)	3 (100%)	0.026
Pharyngitis	2 (3.6%)	0	2 (5.4%)	0	1
Apnea	1 (1.8%)	0	0	1 (33.3%)	0.055
Bronchitis	1 (1.8%)	0	1 (2.7%)	0	1
<b>Gastrointestinal illness</b>	34 (61.8%)	4 (26.7%)	27 (73%)	3 (100%)	0.002
Vomiting	32 (58.2%)	3 (20%)	26 (70.3%)	3 (100%)	0.001
Hyporexia	8 (14.5%)	0	6 (16.2%)	2 (66.7%)	0.019
Abdominal pain	3 (5.5%)	1 (6.7%)	1 (2.7%)	1 (33.3%)	0.099
Diarrhea	3 (5.5%)	1 (6.7%)	2 (5.4%)	0	1
<b>Hand-foot-mouth rash</b>	13 (23.6%)	1 (6.7%)	12 (32.4%)	0	0.088

Abbreviation: PICU, pediatric intensive care unit.

with meningitis (13 of 15), and only in 11.4% of brainstem encephalitis (4 of 35; *p* < 0.001). However, RT-PCR in pharyngeal sample was positive in 75.8% of brainstem encephalitis (25 of 33) and rectal sample in 76.7% (23 of 30). In all cases of myelitis, the detection of EV was made by pharyngeal sample, while RT-PCR in CSF was negative.

EV genotyping was available in 34 cases. In total, 26 of them were EV-A71: 25 brainstem encephalitis (96.2%, *p* < 0.001) and 1 meningitis (3.8%). All three cases with AFM were EV-D68 (*p* < 0.001). Echovirus-30 was detected in four meningitis cases.

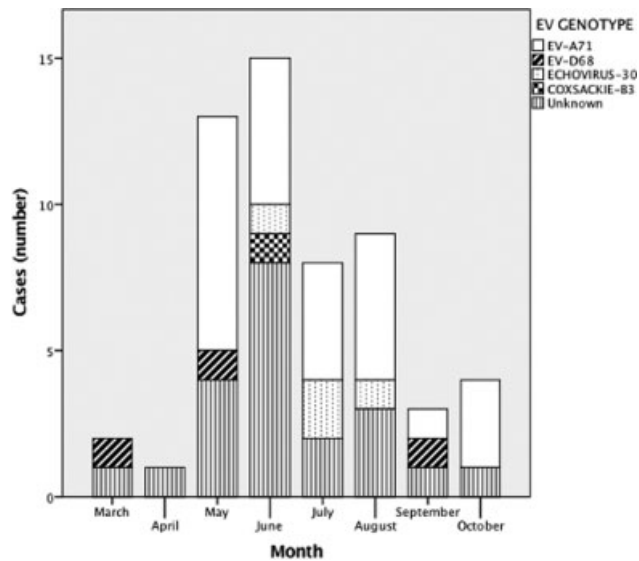
Coxsackie-B3 was observed in one mild brainstem encephalitis case. Distribution of genotypes by months is shown in ► **Fig. 1** and distribution by age groups is shown in ► **Supplementary Fig. S1** (available in the online version).

**Laboratory, Imaging, and Neurophysiological Findings**

**Blood Analysis**

Leukocytosis (median = 12,250 leukocytes/mL, IQR: 9,025-15,475) with a predominance of neutrophils (median = 56.8%,

This document was downloaded for personal use only. Unauthorized distribution is strictly prohibited.



**Fig. 1** Monthly distribution and genotyping data of cases during the year 2016.

IQR: 26.25–87.35%) were observed in full blood count tests, without significant differences between clinical groups. Median for C-reactive protein was 5.5 mg/L (IQR: 0.31–10.69 mg/L) and procalcitonin was 0.10 ng/mL (IQR: 0.055–0.145 ng/mL).

#### Cerebrospinal Fluid Analysis

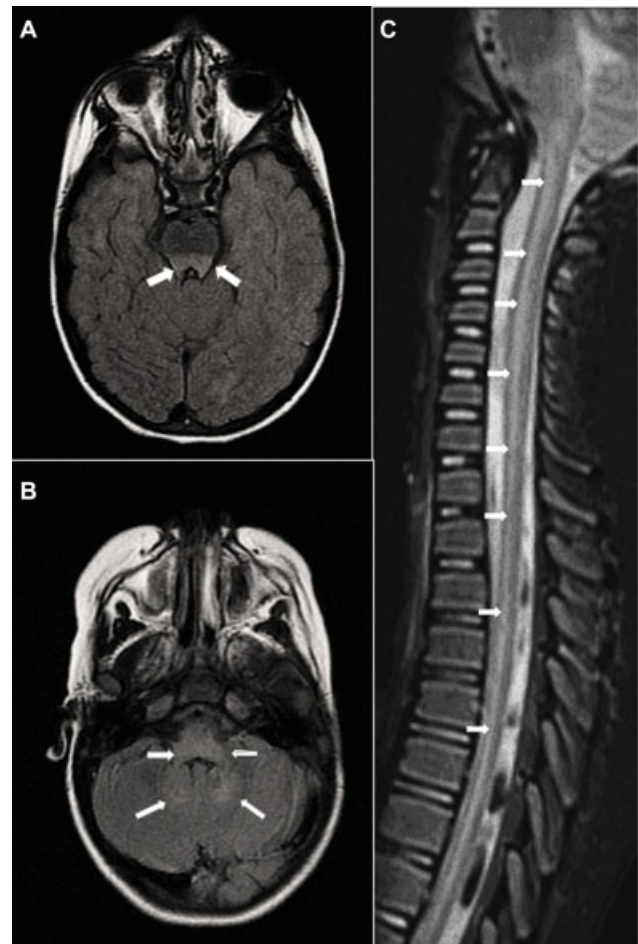
In cerebrospinal fluid, pleocytosis was found (median = 138 leukocytes/mL, IQR: 0.5–275.5) with slight predominance of mononuclears (median = 54%, IQR: 16.5–91.5%) in meningitis and brainstem encephalitis. However, in AFM polymorphonuclears were predominant in CSF (median 90%). CSF protein was normal or minimally increased (median = 44 mg/dL, IQR: 28.75–59.25 mg/dL), but significantly higher in meningitis than in the other two groups (median = 56 mg/dL,  $p = 0.015$ ). CSF glucose was normal (median = 56.5 mg/dL, IQR: 48.14–64.87 mg/dL), significantly increased in AFM than in the other two groups (median = 67 mg/dL,  $p = 0.004$ ).

#### Neuroimaging

Brain MRI was performed in 23 out of 37 cases of brainstem encephalitis (62.2%) in the acute phase. Nine cases (39.1%) were reported to show bilateral and symmetric high-intensity lesions on T2-weighted images in the dorsal brainstem (midbrain, pons, and medulla oblongata; ▶ **Fig. 2A** and **B**).

Spine MRI was performed only in five cases of brainstem encephalitis and in the three cases of AFM. Spine MRI showed T2 longitudinal hyperintensity in cervical and dorsal spinal cord in the gray matter in the three cases of AFM by EV-D68 (▶ **Fig. 2C**). Additionally, cervical myelitis was described in the MRI in one case of brainstem encephalitis by EV-A71, without any other attributable symptom than mild cervicalgia.

Brain computerized tomography (CT) was performed urgently, prior to MRI, in 16 cases and was reported as normal.



**Fig. 2** (A–C) Brain MRI T2-FLAIR weighted, axial, high-intensity lesions in the dorsal brainstem: pons (A), medulla, inferior cerebellar peduncles, and dentate nuclei (B) in a 3-year-old patient with brainstem encephalitis due to EV-A71, performed 2 days after clinical onset (acute phase). Spine MRI T2 weighted, sagittal, high-intensity lesions in gray matter cervical, and dorsal spine (C) in a 6-year-old patient with acute flaccid myelitis by EV-D68, performed 4 days after clinical onset (acute phase). EV, enterovirus; FLAIR, fluid-attenuated inversion recovery; MRI, magnetic resonance imaging.

#### Neurophysiology

Electroencephalogram (EEG) was performed in 26 cases. Diffuse slowing was observed in 72.7% cases of brainstem encephalitis in which EEG was performed (16 cases out of 22).

Nerve conduction studies were performed in the three cases with acute flaccid myelitis, which revealed severe motor axonal neuropathy.

#### Management

All patients have been admitted to hospital, according to the inclusion criteria, and twenty cases (36.4%)—17 brainstem encephalitis and three AFM—needed pediatric intensive care unit (PICU) admission because of decrease of consciousness (seven cases), respiratory distress/paralysis (seven cases), and need for strict neurologic surveillance (six cases).

Twenty-eight patients with brainstem encephalitis (75.7%) and all with AFM received empiric treatment with acyclovir for 5 days (median, IQR: 3.5–6.5 days) at a dose of



60 mg/kg/day, until herpes PCR was negative. Only two patients with meningitis received acyclovir ( $p < 0.001$ ).

Twenty patients with brainstem encephalitis (54.1%), seven with meningitis (46.7%) and all AFM received empiric antibiotic treatment for 5.5 days (mean, standard deviation [SD]=3.24) with cefotaxime or ceftriaxone. Six patients received one of these antibiotics combined with ampicillin and two with vancomycin until blood and CSF cultures were negative.

Intravenous immunoglobulin (IVIG) at a total dose of 2 g/kg spread in 2 days (median, IQR: 1–3 days) was administered to 15 patients with brainstem encephalitis (40.5%) and all cases of AFM.

Seven cases of brainstem encephalitis (18.9%) and all cases of AFM received intravenous methylprednisolone, at a dose of 30 mg/kg/day for 5 days (median IQR: 4–6 days).

Fluoxetine was used in two patients with brainstem encephalitis (5.4%), and two patients with AFM (66.7%) for 14.5 days (median IQR: 2.88–26.13 days). Those last two patients underwent plasmapheresis (66.7% of AFM,  $p < 0.002$ ).

Respiratory assistance was required in six patients with brainstem encephalitis (16.2%)—three noninvasive ventilation (NIV) and three mechanical ventilation—and all three patients with AFM by EV-D68 needed mechanical ventilation.

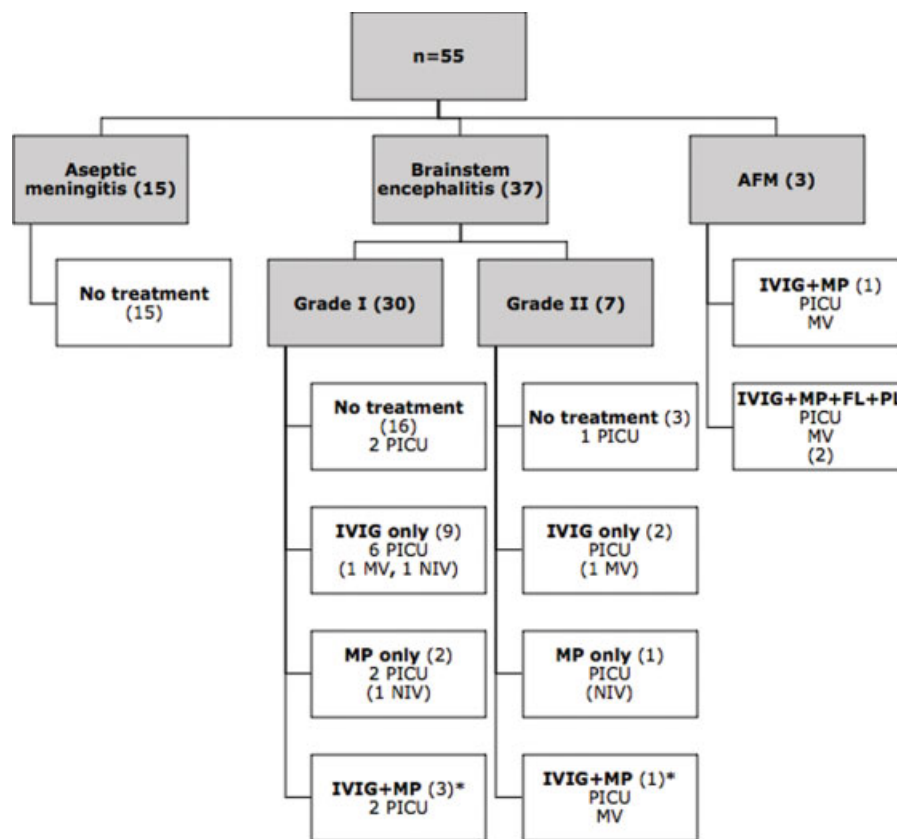
No case of aseptic meningitis required treatment with IVIG ( $p = 0.001$ ), steroids ( $p = 0.001$ ), fluoxetine, plasmapheresis, or respiratory assistance.

The different management according to clinical groups and outcome are reflected in ►Fig. 3.

**Outcomes**

Follow-up assessment 2 months following presentation has shown that 87.3% of patients were asymptomatic, but 12.7% (seven patients) presented sequelae including the three patients that presented AFM ( $p = 0.001$ ) and four with brainstem encephalitis (18.9%), even though in neuroimaging control 2 months following presentation the previous lesions had disappeared both in brainstem and in spinal cord. At the assessment 12 and 24 months following the onset, only the three patients with AFM had sequelae.

All EV-D68 AFM patients had serious sequelae. Motor deficit persisted in the three patients as flaccid paresis in one, two, or four limbs, in each case, with mild improvement in the follow-up assessment 12 and 24 months following the onset, presenting, in each case, flaccid monoparesis of upper right limb, flaccid diparesis of both upper limbs, and flaccid tetraparesis with patchy patron. All of them continued needing respiratory assistance 2 months following presentation (two of them NIV at home and one mechanical ventilation through tracheostomy), improving in the following months (only the patient with previous tracheostomy needed NIV at 12 and 24 months of follow-up). This same patient needed nasogastric tube feeding from the onset and later percutaneous gastrostomy feeding because of severe



**Fig. 3** Treatment and management in acute phase: distribution according to clinical groups. AFM, acute flaccid myelitis; FL, fluoxetine; IVIG, intravenous immunoglobulin; MP, methylprednisolone; MV, mechanical ventilation; NIV, noninvasive ventilation; PICU, pediatric intensive care unit; PL, plasmapheresis. \*One of them treated with FL.

This document was downloaded for personal use only. Unauthorized distribution is strictly prohibited.

dysphagia 2 months after the onset, being able to start eating small amounts at 12 months control and combining gastrostomy and mouth at 24 months control.

On the other hand, 84.6% of patients affected by EV-A71 were asymptomatic 2 months following the onset of the disease and only four had mild sequelae: tremor (two cases), ataxia (one case), and myoclonus (one case). These four patients with mild sequelae were asymptomatic in the follow-up assessment 12 and 24 months following presentation.

No deaths have been registered.

## Discussion

The present multicenter retrospective observational study concerns an outbreak of EV with neurological disease during 2016 in pediatric population of Asturias, Cantabria, and Castile and Leon. Presentations included 37 cases of brainstem encephalitis mostly due to EV-A71 (26 cases) and three cases of acute flaccid myelitis due to EV-D68.

As reported, neurological manifestations related to EV are more frequent in our series in infants and school children (–**Supplementary Fig. S1**; available online only). It has been suggested that the immaturity of the blood–brain barrier, especially of astrocytes, may explain the greater facility for viral neuroinvasion in young children;<sup>24</sup> in addition to the immaturity of the entire immune system<sup>1</sup> including microglia, although the exact cause of this age predominance remains unknown.

Brainstem encephalitis caused by EV-A71, which was rarely observed in these regions previously, manifested mainly with ataxia, lethargy, tremor, myoclonus, and dysmetria (grade I rhombencephalitis<sup>6</sup> in 30 cases) in accordance with what has been described in previous reports.<sup>7–13</sup> Additionally, seven patients presented with cranial nerve involvement (grade II rhombencephalitis<sup>6</sup>). Only one patient had mild dysautonomic signs but could not be classified as grade III rhombencephalitis (no coma, apnea or shock reported). Interestingly, 10 patients EV-A71 positive had HFMD, but no one was noted to have herpangina; both conditions reported as associated with EV-A71.<sup>6,25</sup> This can be possibly explained because of a wide variability of manifestations depending on the neuro or dermato-tropism of the circulating strain.<sup>5</sup> Respiratory (cough and rhinitis) and gastrointestinal (vomiting) symptoms were frequent. Outcome of EV-A71 infection was very good (84.6% of patients asymptomatic 60 days following the onset), which is in accordance with reports from other Spanish series.<sup>7–13</sup> Nevertheless, this contrasts with reports of previous outbreaks in Asia in which grade III rhombencephalitis was more frequent and several deaths were reported.<sup>6</sup> Further investigations are needed to clarify if these differences are due to different strains of EV-A71 in each outbreak or to genetic individual susceptibility of the host–low expression of CD40 and IL-4, HLA genotype, CTLA-4 expression<sup>1</sup>–among other factors.

In addition, we describe three cases of AFM due to EV-D68 which can be added to the three cases already reported in the same period of time in Spain.<sup>18,19</sup> Our patients had a similar clinical course with previously published cases; all of them

started with respiratory symptoms (cough, rhinorrhea, and dyspnea) and vomiting, rapidly followed by acute onset of severe limb weakness (mono-, di-, or tetraparesis) and with MRI showing a spinal cord hyperintensity. All of them, like previously reported case series, presented severe mono-, di-, or tetraparesis and needed respiratory support and feeding assistance through gastrostomy following 2 months of presentation. Regarding the neurotropism and poor outcome observed in these cases, it is striking that, during the same period, three cases of coinfection by EV-A71 and EV-D68 in infants were reported in Balearic Islands without any neurological symptom, presenting only with fever and flu-like symptoms.<sup>12</sup> Similar strains of EV-D68 were sequenced in cases with or without neurological impairment<sup>18</sup> and so far the reason of symptom variability remains unknown. Possibly EV-D68 is not the unique factor in the pathogenesis of AFM, and there are additional causing factors. As it has been previously suggested, EV-D68 would be “necessary but not sufficient.”<sup>26</sup> An autoimmune etiology has been hypothesized, although the clinical and neuroradiographic findings are consistent with a neuro-invasive viral pathogen: short interval (hours) between systemic and neurologic symptom initiation, abrupt limb weakness onset, predominance of gray matter involvement and apparent lack of response to immunosuppressive therapy.

On the other hand, the difficulty to find EV in CSF in brainstem encephalitis and myelitis is intriguing. In meningitis, CSF was the best sample to detect EV (87%). In brainstem encephalitis, it was difficult to find EV in CSF (11%), but throat samples had more sensitivity (76%). In AFM, EV-D68 could not be found in CSF, but it was possible in respiratory samples in all cases, as reported. Why EV is not usually found in CSF of brainstem encephalitis and AFM patients is not clear, but this fact has been described in most of the previously reported series worldwide.<sup>7,21,27</sup> A possible explanation could be that these EV did not produce direct neuronal damage, but a hyperacute postinfectious immune response, inducing inflammatory damage to gray matter.<sup>26</sup> Cytokines and chemokines play an important role in this immune response.<sup>28</sup>

Brain MRI is the preferred neuroimaging modality in brainstem encephalitis, and must be completed with a spinal MRI, as some cases can have clinically unapparent spinal cord injury, as we have reported in one case of rhombencephalitis with mild cervicalgia secondary to cervical myelitis. Follow-up MRI can be performed, but it may not correlate with the clinical outcome. As we have reported, all our patients with AFM and sequelae in had a normal follow-up MRI. Brain CT scan has a very low diagnostic yield: all CT scans performed in our cohort were normal and unable to detect the abnormalities reported in the MRI performed later.

As autoimmune involvement in the pathogenesis of neurological disease due to EV is possible, the current recommended treatment<sup>21,23</sup> consists of immune-modulatory therapy, in three different steps according to severity: IVIG, corticosteroids, and plasmapheresis. A modulation of cytokine production has been considered as a mechanism of IVIG treatment in brainstem encephalitis by EV-A71,<sup>29</sup> but its role in reducing acute morbidity is controversial.<sup>30</sup>

According to our limited experience, mild cases can resolve only with IVIG administration, but severe ones continue to be symptomatic despite receiving all therapies available.

It is precisely because of this lack of response to intensive immune treatment that the autoimmune theory does not explain completely the pathophysiology of the syndrome. Due to the small number of patients treated and the poor results of these therapies, no conclusions can be drawn about their efficacy.

Fluoxetine inhibits replication of group B and D EVs by targeting viral protein 2C<sup>31</sup> with in vitro antiviral activity against EV-D68<sup>32</sup> and was proposed as a possible therapeutic agent for AFM by EV-D68,<sup>33</sup> being well tolerated but not revealing a signal of efficacy according to the available data.<sup>34</sup> In our cohort, two out of three patients with AFM received fluoxetine, and no differences have been observed in the outcomes between those and the patient who did not receive it. This lack of effectiveness of fluoxetine treatment in patients with AFM could support the hypothesis of an autoimmune origin or involvement in the CNS damage. However, just as we mentioned before regarding immune therapy, it is beyond the scope of the present study to address this issue.

To explain all these findings related with neurological disease due to EV infection, previous authors have proposed a dual pathophysiological theory which combines acute viral neuronal damage and a hyperacute autoimmune response.<sup>26</sup> It is because of this theory that current guidelines<sup>21,23</sup> recommend the use of both antiviral and immune treatment in EV patients with severe neurologic disease.

Our study has some limitations. A selection bias is probable as we only took into account cases that needed hospitalization which means that mild cases of meningitis that could be managed at emergency departments or primary care health centers have not been included. Another limitation of this study is that genotyping was unavailable in 21 of our cases. Furthermore, it is possible that there were unreported patients, especially those with milder manifestations, since the data were collected voluntarily by the clinicians.

In conclusion, 55 patients were hospitalized because of neurological disease due to EV in 2016 in the three mentioned regions of Northern Spain. Brainstem encephalitis was the predominant clinical group, mostly due to EV-A71, associated with good prognosis. Less frequent but with a poorer outcome, three cases of AFM by EV-D68 were registered and had persistent paresis months following the onset of the infection. Clinical, microbiological and radiological diagnosis is essential, taking into account that EV-A71 and EV-D68 can be difficult to identify in sterile samples as CSF, requiring throat or rectal samples. There is not specific treatment to these conditions and the efficacy of immune-modulatory step treatment according to severity (IVIG, corticosteroids, and plasmapheresis) is limited. A dual pathophysiological theory which combines acute viral neuronal damage with a hyperacute autoimmune response could explain the origin of the neurological disease related to EV infection.

**Funding**  
None.

**Conflict of Interest**  
None declared.

#### Acknowledgments

The authors thank to all the clinical, laboratory, and diagnostic imaging colleagues who managed the outbreak in all participant centers, taking care of the patients. They also thank to the Spanish National Centre of Microbiology for the genotyping of some patients.

#### References

- Chen B-S, Lee H-C, Lee K-M, Gong Y-N, Shih S-R. Enterovirus and Encephalitis. *Front Microbiol* 2020;11(February):261
- Sawyer MH. Enterovirus infections: diagnosis and treatment. *Semin Pediatr Infect Dis* 2002;13(01):40–47
- Gray JA, Moffat MAJ, Sangster G. Viral meningitis. A 10-year study. *Scott Med J* 1969;14(07):234–242
- Rudolph H, Schrotten H, Tenenbaum T. Enterovirus infections of the central nervous system in children: an update. *Pediatr Infect Dis J* 2016;35(05):567–569
- Ho M, Chen E-R, Hsu K-H, et al; Taiwan Enterovirus Epidemic Working Group. An epidemic of enterovirus 71 infection in Taiwan. *N Engl J Med* 1999;341(13):929–935
- Huang CC, Liu CC, Chang YC, Chen CY, Wang ST, Yeh TF. Neurologic complications in children with enterovirus 71 infection. *N Engl J Med* 1999;341(13):936–942
- González-Sanz R, Casas-Alba D, Launes C, et al. Molecular epidemiology of an enterovirus A71 outbreak associated with severe neurological disease, Spain, 2016. *Euro Surveill* 2019;24(07):
- Casas-Alba D, de Sevilla MF, Valero-Rello A, et al. Outbreak of brainstem encephalitis associated with enterovirus-A71 in Catalonia, Spain (2016): a clinical observational study in a children's reference centre in Catalonia. *Clin Microbiol Infect* 2017;23(11):874–881
- Andrés C, Vila J, Gimferrer L, et al. Surveillance of enteroviruses from pediatric patients attended at a tertiary hospital in Catalonia from 2014 to 2017. *J Clin Virol* 2019;110:29–35
- Leal Barceló AM, Carrascosa García P, Rincón López EM, Miranda Herrero MC, Navarro ML. Brote de infección por enterovirus causantes de afectación neurológica grave en un hospital terciario. *An Pediatr (Barc)* 2018;89(06):378–381
- Taravilla CN, Pérez-Sebastián I, Salido AG, et al. Enterovirus A71 infection and neurologic disease, Madrid, Spain, 2016. *Emerg Infect Dis* 2019;25(01):25–32
- Reina J, Cabrerizo M, Ferrés F. Análisis de las características clínicas de las infecciones causadas por el enterovirus A71 (EV-A71) en las Islas Baleares. *An Pediatr (Barc)* 2017;87(05):289–290
- Valdivielso Martínez AI, Carazo Gallego B, Cubiles Arilo Z, Moreno-Pérez D, Urda Cardona A. Patología neurológica aguda por enterovirus: revisión de casos clínicos en un hospital andaluz de tercer nivel tras brote epidémico de Cataluña. *An Pediatr (Barc)* 2018;89(04):249–251
- Cabrerizo M, Díaz-Cerio M, Muñoz-Almagro C, et al. Molecular epidemiology of enterovirus and parechovirus infections according to patient age over a 4-year period in Spain. *J Med Virol* 2017; 89(03):435–442
- Karrasch M, Fischer E, Scholten M, et al. A severe pediatric infection with a novel enterovirus A71 strain, Thuringia, Germany. *J Clin Virol* 2016;84:90–95
- Böttcher S, Obermeier PE, Neubauer K, Diedrich S Laboratory Network for Enterovirus Diagnostics. Recombinant enterovirus A71 subgenogroup C1 strains, Germany, 2015. *Emerg Infect Dis* 2016;22(10):1843–1846
- Antona D, Kossorotoff M, Schuffenecker I, et al. Severe paediatric conditions linked with EV-A71 and EV-D68, France, May to October 2016. *Euro Surveill* 2016;21(46):



- 18 Cabrerizo M, García-Iñiguez JP, Munell F, et al. First cases of severe flaccid paralysis associated with enterovirus d68 infection in Spain, 2015-2016. *Pediatr Infect Dis J* 2017;36(12):1214–1216
- 19 González-Sanz R, Taravillo I, Reina J, et al. Enterovirus D68-associated respiratory and neurological illness in Spain, 2014-2018. *Emerg Microbes Infect* 2019;8(01):1438–1444
- 20 Instituto Nacional de Estadística (Spanish Statistics National Institute) Population by communities, age, sex and year. Spain; 2016. Accessed April 20, 2020 at: [www.ine.es](http://www.ine.es)
- 21 World Health Organisation. A Guide to Clinical Management and Public Health Response for Hand, Foot, and Mouth Disease. 2010
- 22 Leshem E. Acute flaccid myelitis among persons aged  $\leq 21$  years United States, August 1–November 13, 2014. *Morb Mortal Wkly Rep* 2015;63(53):1243–1244
- 23 Khanh TH, Sabanathan S, Thanh TT, et al. Enterovirus 71-associated hand, foot, and mouth disease, Southern Vietnam, 2011. *Emerg Infect Dis* 2012;18(12):2002–2005
- 24 Saunders NR, Dreifuss J-J, Dziegielewska KM, et al. The rights and wrongs of blood-brain barrier permeability studies: a walk through 100 years of history. *Front Neurosci* 2014;8:404
- 25 Lee T-C, Guo H-R, Su H-JJ, Yang Y-C, Chang H-L, Chen K-T. Diseases caused by enterovirus 71 infection. *Pediatr Infect Dis J* 2009;28(10):904–910
- 26 Sejvar JJ, Lopez AS, Cortese MM, et al. Acute flaccid myelitis in the United States, August–December 2014: results of nationwide surveillance. *Clin Infect Dis* 2016;63(06):737–745
- 27 Messacar K, Asturias EJ, Hixon AM, et al. Enterovirus D68 and acute flaccid myelitis—evaluating the evidence for causality. *Lancet Infect Dis* 2018;18(08):e239–e247
- 28 Wang SM, Lei HY, Liu CC. Cytokine immunopathogenesis of enterovirus 71 brain stem encephalitis. *Clin Dev Immunol* 2012;2012:876241
- 29 Wang SM, Lei HY, Huang MC, et al. Modulation of cytokine production by intravenous immunoglobulin in patients with enterovirus 71-associated brainstem encephalitis. *J Clin Virol* 2006;37(01):47–52
- 30 Chea S, Cheng YB, Chokephaibulkit K, et al. Workshop on use of intravenous immunoglobulin in hand, foot and mouth disease in Southeast Asia. *Emerg Infect Dis* 2015. Doi: 10.3201/eid2101.140992
- 31 Ulferts R, van der Linden L, Thibaut HJ, et al. Selective serotonin reuptake inhibitor fluoxetine inhibits replication of human enteroviruses B and D by targeting viral protein 2C. *Antimicrob Agents Chemother* 2013;57(04):1952–1956
- 32 Rhoden E, Zhang M, Nix WA, Oberste MS. In vitro efficacy of antiviral compounds against enterovirus D68. *Antimicrob Agents Chemother* 2015;59(12):7779–7781
- 33 Tyler KL. Rationale for the evaluation of fluoxetine in the treatment of enterovirus D68-associated acute flaccid myelitis. *JAMA Neurol* 2015;72(05):493–494
- 34 Messacar K, Sillau S, Hopkins SE, et al. Safety, tolerability, and efficacy of fluoxetine as an antiviral for acute flaccid myelitis. *Neurology* 2019;92(18):e2118–e2126