


Long-Term Outcomes of the Electrically Unresponsive, Anatomically Intact Facial Nerve Following Vestibular Schwannoma Surgery

Alireza Shoakazemi¹ Alejandro Feria²  Constantine E. Kanakis³ Emma Stapleton⁴
Omar N. Pathmanaban⁵ Simon R. Freeman⁴ Simon Lloyd⁴ Scott A. Rutherford⁵
Andrew Thomas King⁵ Charlotte L. Hammerbeck-Ward⁵

¹ Department of Neurosurgery, Queen's Hospital, Romford, United Kingdom

² Department of Internal Medicine, University of Kentucky, Bowling Green, Kentucky, United States

³ Department of Pathology and Laboratory Medicine, Loyola University Medical Center, Chicago, Illinois, United States

⁴ Department of Otolaryngology, Salford Royal Hospital, Salford, Manchester, United Kingdom

⁵ Department of Neurosurgery, Salford Royal Hospital, Salford, Manchester, United Kingdom

Address for correspondence Alireza Shoakazemi, MD, FRCS, Department of Neurosurgery, Queen's Hospital, Rom Valley Way, Romford, United Kingdom RM7 0AG (e-mail: Alireza.shoakazemi@nhs.net).

J Neurol Surg B Skull Base 2022;83:367–373.

Abstract

Objective The study aimed to determine long-term outcomes in patients with intraoperative electrical conduction block in an anatomically intact facial nerve (FN).

Methods Single center retrospective review of prospectively collected database of all vestibular schwannoma surgeries between January 1, 2008 and August 25, 2015. Operative notes were reviewed and patients with anatomically intact FNs, but complete conduction block at the end of surgery were included for analysis.

Results In total, 371 patients had vestibular schwannoma surgery of which 18 met inclusion criteria. Mean follow-up was 34.28 months and average tumor size was 28.00 mm. Seventeen patients had House-Brackmann Grade VI facial palsy immediately postoperatively and one patient was grade V. At 1 year, three patients remained grade VI (17%), two improved to grade V (11%), seven to grade IV (39%), six to grade III (33%), and one patient to grade II (6%). On extended follow-up, five patients (28%) had additional 1 to 2 score improvement in facial function. Subset analysis revealed no correlation of tumor size, vascularity, adherence to nerve, operative approach, extent of resection, splaying of FN, and recurrent tumor or sporadic tumors to the extent of FN recovery.

Conclusion Intraoperative conduction block does not condemn a patient to permanent FN palsy. There is potential for a degree of recovery comparable with those undergoing nerve grafting. Our data do not clearly support a policy of same-surgery or early-postoperative primary nerve grafting in the event of a complete conduction block, and instead we favor monitoring for recovery in an anatomically intact nerve.

Keywords

- ▶ conduction block
- ▶ vestibular schwannoma
- ▶ facial nerve
- ▶ electrophysiological monitoring

received

October 14, 2020

accepted after revision

January 3, 2021

published online

March 1, 2021

© 2021, Thieme. All rights reserved.
Georg Thieme Verlag KG,
Rüdigerstraße 14,
70469 Stuttgart, Germany

DOI <https://doi.org/10.1055/s-0041-1725034>.
ISSN 2193-6331.

Introduction

The introduction of the operative microscope and intraoperative electrophysiological monitoring has led to significant improvements in the morbidity and mortality associated with modern skull base surgery. The emphasis of surgical resection of vestibular schwannoma (VS) has thus shifted from decreasing intraoperative and perioperative mortality to improving postsurgical morbidity and preserving neurological function, with particular attention made to the preservation of hearing and facial nerve (FN) function. While the rates of FN anatomical preservation and functional outcomes after VS surgery have greatly improved,^{1–3} there still remains a subset of patients who experience significant functional deficits postoperatively despite anatomic preservation of the FN. In such patients who have an anatomically intact FN but loss of electrical responsiveness during maximal intraoperative stimulation, questions remain as to the natural course and degree of functional improvement that can be expected.

In this study, we aimed to evaluate the time course and level of functional recovery that can be expected in patients who develop FN conduction block during resection of VS and to evaluate for any predictive factors which may influence their recovery.

Materials and Methods

A retrospective review of a prospectively collected operative database was performed identifying all patients who underwent resection of VS at the Manchester Skull Base Unit between January 1, 2008 and August 25, 2015. Information from the database was supplemented with a subsequent review of clinical records and operative notes. Data collection included age at surgery, sex, tumor size, and House-Brackmann grading (HBG) scale preoperatively and immediately postoperatively at 1 year and at latest follow-up, operative approach, extent of resection, sporadic versus recurrent tumor, neurofibromatosis type 2 (NF2) status, preoperative symptoms, FN course, tumor vascularity, tumor adherence to the FN, FN splay, and history of adjunctive FN procedures.

In all cases a Magstim Neurosign N800 monopolar probe was used with stimulation set at 0.05 mA on the FN. A constant current electrical source with waveform threshold of 0.03 mV and 200 microseconds pulse duration was used. When the FN became unresponsive to 0.05 mA, the stimulation was escalated in a stepwise manner up to 2 mA. If the nerve was not responsive to this level of stimulation amplitude, the term “electrically unresponsive” was used.

Statistical analysis was performed by using XLSTAT (XLSTAT Premium, Version 2020.2.3.65344, Addinsoft 1995–2020). Descriptive statistics were expressed by using means with normal distributions and medians with skewed distributions. Contingency analysis using the Chi-square test was used to compare FN outcomes with sex, completeness of tumor removal, sporadic tumors, recurrent tumors, operative approach, tumor vascularity, FN adherence, and FN splay. Logistic fit modeling was used to compare age and tumor size with FN outcomes. Values of $p \leq 0.05$ were considered a

statistically significant result. Cross-reference statistical analysis was conducted to corroborate primary analyses. For variables compared across scalar quantities (i.e., House-Brackmann grade versus age and tumor size), Spearman, and Pearson linear regressions were used to demonstrate, if any, correlations existed therein. Variables which compared variables of linear/scalar quantity against categorical data (i.e., House-Brackmann grade versus sex and operative approach) were analyzed by point-biserial correlations. Variables compared against House-Brackmann grading both at 1 year and latest follow-up with nominal values (i.e., yes/no or triple variable extent of tumor) were evaluated via one-way ANOVA testing. Linear correlations were assessed for best fit for (+1) positive or (–1) negative correlation. Point-biserial variable analyses were evaluated on a two-tailed confidence intervals, with values of $p < 0.05$ determining significance. One-way ANOVA testing was evaluated for significance through interpretation of adjusted correlation (R) values, values of $Pr > F < 0.05$, and $Pr > |t| < 0.005$.

Results

There were 371 VS operations during the study period and 21 patients (6%) were identified as having an anatomically intact, but electrically unresponsive FN despite maximal stimulation at the end of their surgery. Three patients were excluded from the analysis, 2 due to lack of immediate follow-up data, and 1 due to a preoperative ipsilateral HBG V from previous surgery, leaving 18 patients for analysis of their FN recovery at 1 year and latest follow-up. This cohort was comprised of 11 women and 7 men (►Table 1). The average age at time of operation was 49.44 months, with a range from 16 to 72 months. The average follow-up for the cohort was 34.28 months, ranging from 10 to 96 months. Two patients were followed up elsewhere after their first year follow-up in Manchester.

Of the 18 patients analyzed, 16 had a unilateral, sporadic VS and 2 patients had NF2. All patients had a preoperative HBG of I. The mean tumor size was a cerebellopontine angle component of 28.00 mm (range = 5–60 mm, ►Table 2). Surgical approaches for the resection of VS included 13 (72%) through a translabyrinthine approach and 5 (28%) via a retrosigmoid approach. From the operative records, 3 tumors were noted to be vascular and 10 demonstrated particular adherence to the FN. The extent of tumor resection achieved in this cohort was 6 gross total resections, 10 near-total (>95%) resections, and 2 subtotal resections.

All patients had true FN conduction block, that is, loss of electrical responsiveness proximal to the point of presumed block but continued to stimulate distally. With regard to the point of conduction block, one occurred during the translabyrinthine approach with a dural breach close to the FN, but no direct macroscopic trauma to the FN, which never stimulated intraoperatively and was macroscopically intact along its length at the end of the procedure. In 2 patients, there was no stimulation at outset, and in the other 16, all stopped stimulating during tumor dissection from the FN despite maximal stimulation. During the immediate postoperative period,

Table 1 Preoperative patient characteristics

Case	Age	Sex	NF2	Sporadic tumor	Recurrent tumor	Preoperative symptoms
1	63	Male	No	Yes	No	?
2	33	Female	No	Yes	No	HL, B, facial numbness
3	71	Male	No	Yes	No	B
4	36	Female	No	Yes	No	HL, T, B
5	46	Female	No	Yes	No	HL, T, V
6	38	Female	Yes	No	No	?
7	16	Female	No	Yes	No	HL, T, B
8	41	Female	No	Yes	No	HL
9	72	Female	No	Yes	No	?
10	59	Male	No	Yes	No	HL, T, B
11	70	Female	No	Yes	No	HL, B
12	47	Male	No	Yes	No	HL, T
13	48	Female	No	Yes	No	HL, B
14	32	Female	No	Yes	No	HL, T, facial numbness
15	57	Female	No	Yes	No	HL, T
16	62	Male	No	Yes	No	HL, B
17	54	Male	Yes	No	Yes	HL
18	45	Male	No	Yes	No	HL
Summary	49.44 years old	61.11% female	11.11% NF2	88.89% sporadic	5.56% recurrent	77.78% HL

Abbreviations: B, bulbar signs; HL, hearing loss; NF2, neurofibromatosis 2, T, tinnitus; V, vertigo.

Table 2 Tumor characteristics and operative details

Case	Tumor size (mm)	Approach	FN course	Vascular tumor	Adherence to FN	FN splay	Extent of resection
1	10	TL	Behind 8, superior porus	No	Yes	No	NTR
2	30	TL	Anterosuperiorly against brainstem	No	No	No	GTR
3	60	RS	Not documented	Yes	Yes	Yes	STR
4	34	TL	Along brain stem to superior pole then laterally	Yes	Yes	No	NTR
5	17	TL	Not documented	No	No	No	GTR
6	30	TL	Up stem lateral at level of porus	No	Yes	No	NTR
7	30	RS	Not documented	No	No	No	GTR
8	30	RS	Not documented	No	No	Yes	GTR
9	28	TL	Not documented	No	No	No	NTR
10	30	TL	Not documented	No	Yes	No	NTR
11	12	TL	Not documented	No	No	No	GTR
12	40	TL	Unusually laterally displaced	No	Yes	Yes	STR
13	54	TL	Inferiorly	Yes	Yes	Yes	NTR
14	27	RS	Anterior	No	Yes	Yes	NTR
15	5	TL	Not documented	No	No	No	NTR
16	18	TL	Anterior and superior to porus	No	No	No	GTR
17	40	TL	Anterior and superior	No	Yes	Yes	NTR
18	9	RS	Anterior and superior	No	Yes	Yes	NTR
Summary	28.00 mm	72.22% TL	44.44% not documented	16.67% vascular	55.56% adherent	38.89% FN splay	33.33% GTR

Abbreviations: FN, facial nerve; GTR, gross total resection; NTR, near total resection (>95%); RS, retrosigmoid; STR, subtotal resection; TL, translabyrinthine.

Table 3 Facial nerve functional outcomes

Case	Preoperative HBG	Immediate postoperative HBG	1-year HBG	HBG at latest follow-up	Total follow-up time months	Adjuvant procedures
1	1	6	3	3	25	Botox for aberrant FN regeneration, Canthoplasty
2	1	6	3	3	96	None
3	1	6	4	4	62	Canthoplasty, SRS to tumor remnant
4	1	6	4	Followed-up elsewhere	12	Unknown
5	1	6	4	3	64	Unknown
6	1	6	4	2	58	SRS to tumor remnant
7	1	6	5	Followed-up elsewhere	48	Hypoglossal anastomosis
8	1	6	5	4	36	Canthoplasty
9	1	6	6	6	24	Unknown
10	1	6	3	3	21	None
11	1	6	3	3	37	None
12	1	6	3	3	42	SRS prior to surgery
13	1	6	4	3	24	Unknown
14	1	6	4	4	12	Unknown
15	1	6	2	2	22	None
16	1	6	4	2	10	None
17	1	6	6	6	12	None
18	1	5	3	3	12	None

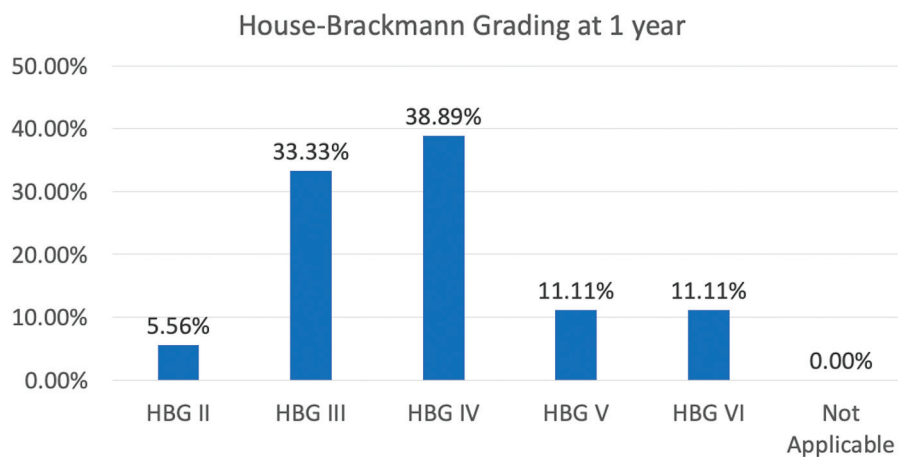
Abbreviations: FN, facial nerve; HBG, House-Brackmann Grading; SRS, stereotactic radiosurgery.

17 patients had HBG VI facial palsy and 1 patient was HBG V. At 1 year, three patients remained at HBG VI (17%), two recovered to grade V (11%), seven to grade IV (39%), six to grade III (33%), and one patient to grade II (6%) (► **Table 3**, ► **Fig. 1**).

On extended follow-up, five (28%) patients were found to have a further 1 to 2 score improvement in FN function (mean follow-up in these patients was 38.4 months), one patient improved from grade V to grade IV, two patients improved from grade IV to grade III, and notably, two patients improved from grade IV to grade II (► **Fig. 2**). Both grade VI patients at

1 year remained grade VI. At the latest follow-up (mean = 34.28 months), three (17%) patients were HBG II, eight (44%) grade III, three (17%) grade IV, two (11%) grade VI, and two (11%) did not have grading available (► **Fig. 3**).

Subset analysis at 1 year and latest follow-up revealed no statistically significant correlation between degree of FN recovery and age, sex, tumor size, sporadic tumors, recurrent tumors, operative approach, vascular tumors, tumors adherent to the FN, FN splay, or extent of resection (► **Supplementary Table S1**, available in the online version).

**Fig. 1** HBG at 1 year. Cohort HBG scores at 1 year. HBG, House-Brackmann Grading.

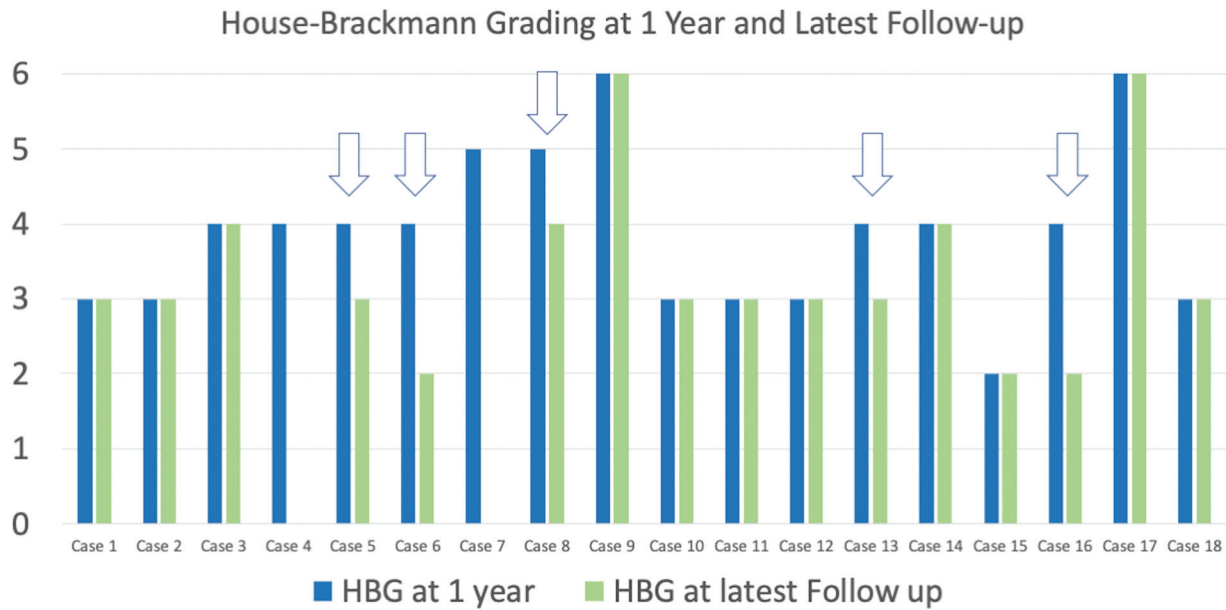


Fig. 2 HBG at 1 year and latest follow-up. Arrows denote cases with further improvement in HBG beyond 1 year. Note cases 4 and 7 did not have follow-up beyond 1 year. HBG, House-Brackman grading.

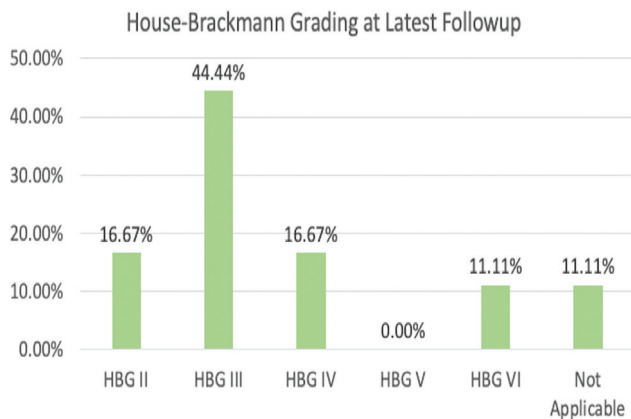


Fig. 3 House Brackman Grading at latest follow-up.

Discussion

Successful preservation of FN function remains the goal of microneurosurgical resection of VS. The loss of FN function is associated with decreased quality of life and is a source of significant stress to VS patients.⁴ Thankfully, in the modern era of microsurgical skull base surgery, the vast majority of patients undergoing resection of VS will experience satisfactory preservation of their FN function. However, the management of patients who experience loss of FN function despite anatomic preservation of the FN presents a unique challenge to skull base surgeons. Questions remain regarding when to recommend facial reanimation surgery and for patients who opt for conservative management, the timing and extent of recovery is difficult to prognosticate.

In patients with FN dysfunction, we appreciate that a HBG III or better implies the patient is able to close their eye completely and is associated with lower morbidity to the eye than patients with HBG IV or worse.⁵ Therefore, the treatment of patients with FN dysfunction is directed at achieving HBG III or better.

Patients with significant FN dysfunction may be offered primary reanimation surgical interventions including end-to-end anastomosis, nerve interposition grafts, faciohypoglossal transposition, and crossed FN grafting with free tissue muscle transfer of the gracilis, latissimus dorsi, or pectoralis minor.⁶ The primary goal of these procedures is to restore symmetrical facial tone at rest and with voluntary movement, however, no method restores emotionally triggered spontaneous movement. End-to-end anastomoses are best used at the time of injury and may be limited by lack of neuronal length to achieve a tension-free anastomoses. The use of interposition grafting, using greater auricular or sural nerve donors can overcome this limitation, but is still best performed as proximal to the time of injury as possible to ensure survival of motor end plates and improve outcomes. When proximal nerve stumps are not accessible, or when the length of interposition graft exceeds what is available from donors, crossover techniques such as faciohypoglossal transposition or crossed facial grafting can be performed; however, these require the sacrifice of a normal functioning donor nerve and may result in homolateral paralyses, tongue atrophy, or speech, and swallowing dysfunction. Free muscle transfer can be added to dynamic reanimation, especially with facial soft tissue defects but requires specialized microvascular expertise.

A body of literature has examined the effectiveness of reanimation procedures in patients with prior resection of VS. Malik et al in 2005 described outcomes at 2 years for various reanimation procedures and reported on 13 patients that underwent end-to-end grafting with 85% improving to HBG III or II, 25 patients that underwent cable grafting with 56% improving to HBG III, and 28 patients that received faciohypoglossal transposition with 25% improving to HBG III. Only two patients in their series improved to HBG II, and they both received end-to-end grafting.⁷ Bacciu et al in 2009

reported on 33 patients who received cable nerve grafting with 75% achieving HBG III at 1 year.⁸

Of the 18 patients with intraoperative conduction block in this study, 17 were found to have HBG VI facial palsy and 1 HBG V. We believe this is most possibly related to the amplitude of the stimulation used intraoperatively and perhaps some degree of immediate postoperative recovery of FN function. In our experience, if a nerve is not stimulating above 2 mA, the patient will have a facial palsy and stimulation is not continued to the limits of the stimulator. There are also patients that retain facial tone and barely perceptible movement particularly in the lower face for a few days, even if there is no intraoperative electrical stimulation, and are graded below VI on the HB scale.

We routinely refrain from use of bipolar on the FN. We believe most of our cases that developed conduction block were due to traction and dissection on the FN. Disruption of microvasculature supplying the nerve during dissection is another possible cause for the conduction block in our cases.⁹ During VS resection, our aim is always to leave as little tumor remnant as is safely possible. In our practice, in the event of loss of electrical stimulation to the nerve—if we have a clear visual on the nerve and even better—had prior stimulation along that visual, we routinely continue tumor dissection. However, if we do not have a clear visual, then we would not necessarily halt, but instead debulk to as thin as we felt reasonable to not further risk nerve integrity. In either scenario, our goal remains to leave as little tumor as possible.

In the present study, seven patients (39%) improved to HBG III or better at 1 year with conservative management, and on extended follow-up (mean = 34.28 months), 11 patients (61%) had improved to HBG III or II. While our sample size is small, the degree of improvement achieved by our patients on conservative management at long-term follow-up is comparable to the rates achieved in facial reanimation surgery. This is in keeping with Carlson et al 2012 who presented a comparable cohort of 11 patients with FN conduction block after VS surgery and similarly did not find any correlative or predictive factors for outcome, but did have 5 patients achieve HBG III function and 2 reach HBG II at 1 year, with an overall percentage of 64% achieving HBG III or better at 1 year on conservative management.¹⁰ On the basis of their findings they discouraged the practice of same-surgery nerve grafting in the setting of an anatomically intact but electrically silent FN.

In our study there was no correlation between FN recovery and tumor size or extent of resection. This stands for all the other variables analyzed such as tumor vascularity, adherence to the nerve or splaying of the nerve. This leaves surgeons with very little way of immediately predicting which patients will make a good recovery.

Of interest, all patients in the present study who were HBG VI at 12 months were found to have no further improvement in HBG score on extended follow-up. Albathi et al reported that the recovery pattern in the first 6 postoperative months among patients who develop facial paralysis after cerebellopontine angle tumor resection may be a useful clinical tool to select patients for early facial reanimation surgery.¹¹ Rivas et al

reported in their multivariate analysis of 281 patients with conduction block after resection of VS that the rate of FN recovery during the first year may serve as a useful predictor of FN outcomes.¹² Furthermore, in their analysis, they too found tumor size, tumor vascularity, preoperative facial function, age at surgery, and ability to stimulate the nerve intraoperatively did not contribute significantly to their predictive model. A multivariate analysis of 229 patients with conduction block following VS resection by Torres et al found tumor adherence and tumor stage were associated with impaired FN function (HB grade III–VI) at initial evaluation on postoperative day 8, but found no predictive factors for FN recovery at 1 year.¹³ The results from our cohort support these authors findings.

The usefulness of intraoperative electrophysiological monitoring during resection of VS cannot be understated. Since its introduction, the rate of inadvertent intraoperative FN transection during VS surgery has decreased and in turn so has the rate of poor FN functional status postoperatively.^{1–3} Electrophysiological monitoring allows the surgeon to identify the FN early in the procedure, even in situations where the nerve is obstructed from direct visualization by tumor or bone.¹⁴ Once identified, the surgeon can take course to preserve the anatomical and functional integrity of the FN while getting real-time feedback on the physiological responsiveness of the nerve. This affords the surgeon a degree of confidence intraoperatively when tumor that is in close proximity to the FN so long as acceptable responsiveness is detected. This scenario is indeed ideal and affords the best current method of achieving maximal tumor resection and preservation of neurological function during resection of VS. When electrical responsiveness is lost; however, the next appropriate step in clinical management becomes more ambiguous.

The results from our cohort along with those in the literature make it clear that loss of electrical responsiveness during surgery does result in immediate functional loss of the FN. The long-term outcome for these patients, however, is more difficult to estimate when based solely on the loss of intraoperative FN responsiveness. It is apparent that some patients go on to achieve acceptable FN function over time while others will not. Outside of the rate of recovery of FN function during the early postoperative period, predictive factors that would help guide clinicians in identifying patients who will achieve a good recovery on their own remain to be found. As such, selecting appropriate surgical candidates for whom FN reanimation surgery is the best means of achieving a degree of functional recovery remains challenging. This is an important question as it would be ill-advised to subject patients to further surgical procedures and their inherent risks and associated costs, when these interventions may achieve no better outcomes as compared with a strategy of watchful waiting. Conversely, in those patients who will never achieve satisfactory recovery of FN function on their own, early referral for reanimation procedures would be prudent to minimize the hardship experienced by these patients, as well as increase the likelihood of a successful intervention.¹¹ Further studies are needed to identify factors which would help select those patients who would naturally achieve good FN outcomes and provide guidance for this puzzling clinical scenario.

Our study has the following limitations. First, this is a retrospective study of a prospectively collected database and as such we relied on the accuracy of the medical record when conducting chart reviews. Second, certain variables such as tumor vascularity and adherence to the FN were taken from the operative note and are subject to interpretation of the operating surgeon. Third, owing to the rare nature of conduction block and subsequently low subject numbers available for review, statistical analysis is inherently limited.

Conclusion

In our series of 18 patients with intraoperative conduction block and postoperative HBG V or VI, we demonstrate that up to 61% of patients may return to HBG III or better with prolonged conservative management. Conduction block at the time of tumor removal does not necessarily condemn a patient to permanent FN palsy. There is potential for a degree of recovery comparable with those undergoing nerve grafting, although a direct comparison of the frequency of good FN functional outcomes with conservative management versus surgical intervention must be interpreted with caution owing to the low number of published series examining the natural course of this rare phenomenon. These data together with our interpretation of the available literature, do not support a policy of same-surgery or early-post operative primary nerve grafting in the event of a complete conduction block. We favor monitoring for recovery in the scenario of an anatomically intact nerve.

Funding

None.

Conflict of Interest

None declared.

References

- 1 Brackmann DE, Cullen RD, Fisher LM. Facial nerve function after translabyrinthine vestibular schwannoma surgery. *Otolaryngol Head Neck Surg* 2007;136(05):773–777
- 2 Kaylie DM, Gilbert E, Horgan MA, Delashaw JB, McMenomey SO. Acoustic neuroma surgery outcomes. *Otol Neurotol* 2001;22(05):686–689
- 3 Samii M, Matthies C. Management of 1000 vestibular schwannomas (acoustic neuromas): the facial nerve–preservation and restitution of function. *Neurosurgery* 1997;40(04):684–694, discussion 694–695
- 4 Ryzenman JM, Pensak ML, Tew JM Jr. Facial paralysis and surgical rehabilitation: a quality of life analysis in a cohort of 1,595 patients after acoustic neuroma surgery. *Otol Neurotol* 2005;26(03):516–521, discussion 521
- 5 House JW, Brackmann DE. Facial nerve grading system. *Otolaryngol Head Neck Surg* 1985;93(02):146–147
- 6 Tate JR, Tollefson TT. Advances in facial reanimation. *Curr Opin Otolaryngol Head Neck Surg* 2006;14(04):242–248
- 7 Malik TH, Kelly G, Ahmed A, Saeed SR, Ramsden RT. A comparison of surgical techniques used in dynamic reanimation of the paralyzed face. *Otol Neurotol* 2005;26(02):284–291
- 8 Bacciu A, Falcioni M, Pasanisi E, et al. Intracranial facial nerve grafting after removal of vestibular schwannoma. *Am J Otolaryngol* 2009;30(02):83–88
- 9 Sun MZ, Oh MC, Safaee M, Kaur G, Parsa AT. Neuroanatomical correlation of the House-Brackmann grading system in the microsurgical treatment of vestibular schwannoma. *Neurosurg Focus* 2012;33(03):E7
- 10 Carlson ML, Van Abel KM, Schmitt WR, Driscoll CL, Neff BA, Link MJ. The anatomically intact but electrically unresponsive facial nerve in vestibular schwannoma surgery. *Neurosurgery* 2012;71(06):1125–1130, discussion 1130
- 11 Albathi M, Oyer S, Ishii LE, Byrne P, Ishii M, Boahene KO. Early nerve grafting for facial paralysis after cerebellopontine angle tumor resection with preserved facial nerve continuity. *JAMA Facial Plast Surg* 2016;18(01):54–60
- 12 Rivas A, Boahene KD, Bravo HC, Tan M, Tamargo RJ, Francis HW. A model for early prediction of facial nerve recovery after vestibular schwannoma surgery. *Otol Neurotol* 2011;32(05):826–833
- 13 Torres R, Nguyen Y, Vanier A, et al. Multivariate analysis of factors influencing facial nerve outcome following microsurgical resection of vestibular schwannoma. *Otolaryngol Head Neck Surg* 2017;156(03):525–533
- 14 Kartush JM, Larouere MJ, Graham MD, Bouchard KR, Audet BV. Intraoperative cranial nerve monitoring during posterior skull base surgery. *Skull Base Surg* 1991;1(02):85–92