



# Examining the Relationship between Concussion and Neurodegenerative Disorders: A Review on Amyotrophic Lateral Sclerosis and Alzheimer's Disease

Edward Poluyi<sup>1</sup> Eghosa Morgan<sup>2</sup> Charles Poluyi<sup>3</sup> Chibuikem Ikwuegbuenyi<sup>4</sup> Grace Imaguezegie<sup>4</sup>

<sup>1</sup>Department of Clinical Neuroscience, University of Roehampton, London, United Kingdom

<sup>2</sup>Department of Neurosurgery, Irrua Specialist Teaching Hospital, Irrua, Nigeria

<sup>3</sup>MPH Program, University of Buffalo, New York, United States

<sup>4</sup>Department of Surgery, Lagos University Teaching Hospital, Lagos, Nigeria

**Address for correspondence** Edward Poluyi, MSc, Department of Clinical Neuroscience, University of Roehampton, London, United Kingdom (e-mail: eddiepolz@yahoo.com).

Indian J Neurotrauma 2022;19:63–68.

## Abstract

**Background** Current epidemiological studies have examined the associations between moderate and severe traumatic brain injury (TBI) and their risks of developing neurodegenerative diseases. Concussion, also known as mild TBI (mTBI), is however quite distinct from moderate or severe TBIs. Only few studies in this burgeoning area have examined concussion—especially repetitive episodes—and neurodegenerative diseases. Thus, no definite relationship has been established between them.

**Objectives** This review will discuss the available literatures linking concussion and amyotrophic lateral sclerosis (ALS) and Alzheimer's disease (AD).

**Materials and Methods** Given the complexity of this subject, a realist review methodology was selected which includes clarifying the scope and developing a theoretical framework, developing a search strategy, selection and appraisal, data extraction, and synthesis. A detailed literature matrix was set out in order to get relevant and recent findings on this topic.

**Results** Presently, there is no objective clinical test for the diagnosis of concussion because the features are less obvious on physical examination. Absence of an objective test in diagnosing concussion sometimes leads to skepticism when confirming the presence or absence of concussion. Intriguingly, several possible explanations have been proposed in the pathological mechanisms that lead to the development of some neurodegenerative disorders (such as ALS and AD) and concussion but the two major events are deposition of tau proteins (abnormal microtubule proteins) and neuroinflammation, which ranges from glutamate excitotoxicity pathways and inflammatory pathways (which leads to a rise in the metabolic demands of microglia cells and neurons), to mitochondrial function via the oxidative pathways.

## Keywords

- ▶ mild traumatic brain injury
- ▶ Alzheimer's disease
- ▶ neurodegeneration
- ▶ amyotrophic lateral sclerosis (ALS)

published online  
February 23, 2021

DOI <https://doi.org/10.1055/s-0041-1725571>  
ISSN 0973-0508.

©2021. Neurotrauma Society of India.

This is an open access article published by Thieme under the terms of the Creative Commons Attribution-NonDerivative-NonCommercial-License, permitting copying and reproduction so long as the original work is given appropriate credit. Contents may not be used for commercial purposes, or adapted, remixed, transformed or built upon. (<https://creativecommons.org/licenses/by-nc-nd/4.0/>).  
Thieme Medical and Scientific Publishers Pvt. Ltd. A-12, 2nd Floor, Sector 2, Noida-201301 UP, India

**Conclusion** mTBI constitutes majority of brain injuries. However, studies have focused mostly on moderate-to-severe TBI as highlighted above with inconclusive and paucity of studies linking concussion and neurodegenerative disorders. Although, it is highly probable that repetitive concussion (mTBI) and subconcussive head injuries may be risk factors for ALS) and AD from this review. It will be imperative therefore to conduct more research with a focus on mTBI and its association with ALS and AD.

## Introduction

Current epidemiological studies have examined the associations between moderate and severe traumatic brain injury (TBI) and their risks of developing neurodegenerative diseases. Concussion, also known as mild TBI (mTBI), is however quite distinct from moderate or severe TBIs. Only few studies in this burgeoning area have examined concussion—especially repetitive episodes—and neurodegenerative diseases. Thus, no definite relationship has been established between them.<sup>1-3</sup>

However, it has been posited that concussion could trigger or accelerate neurodegenerative diseases, distort the functions of neurons, and enhance age-related neurodegenerative disorders.<sup>4</sup> Repetitive subconcussive impacts from prolonged participation in contact sports have also been attributed to neurodegenerative disorders.<sup>5</sup>

Concussion, can lead to functional impairment, emotional problems, and cognitive disabilities and these have been linked to possible risk factors of neurodegenerative disorders.<sup>6,7</sup> A worldwide estimate of 100 to 300 per 100,000 people seek hospital consults annually as a result of mTBI.<sup>1</sup> These injuries, including concussions and subconcussions, could have progressive, persistent, and debilitating impact on the brain causing long-term atrophy of the gray and white matter. This can be determined with the use of blood biomarkers such as serum tau (a biomarker that can detect neuronal integrity disruptions).<sup>8</sup> With time, these predisposes to age-related neurodegeneration and increases the risk factor for neurodegenerative disorders.<sup>9</sup>

Diffuse axonal injury is a diffuse microscopic injury to the white matter tracts. It is often missed during routine investigation for athletes participating in contacts sports as it requires advanced neuroimaging techniques for its detection.<sup>5</sup> Unlike computed tomography (CT) scan and magnetic resonance imaging (MRI), diffusion tensor imaging (DTI) and susceptibility weighted imaging are used to detect white matter microstructural changes and the integrity of fiber tract alteration which are not easily evident on CT/MRI. They are sensitive to microstructural injuries to axons. However, studies have shown that only a minority of cases of white matter microstructural changes can be detected using DTI. In such cases, high-definition fiber tracking is employed to detect structural damage in mTBI.<sup>9,10</sup>

Tauopathy and chronic traumatic encephalopathy (CTE) could also result from repetitive mTBIs.<sup>11</sup> CTE causes atrophy

of the thalamus, hypothalamus, temporal, and frontal lobes. It also causes the formation of neurofibrillary tangles (abnormal deposits of hyperphosphorylated tau) and disarray of neurites in the brain.<sup>9</sup> Currently, there is no clear-cut clinical criteria in differentiating CTE from any other age-related neurodegenerative disorders and some clinically diagnosed cases of Alzheimer's disease (AD), amyotrophic lateral sclerosis (ALS), and Parkinson's disease secondary to TBI have similar neuropathology with CTE (or sometimes vice versa). However, the behavioral and mood symptoms in individual with CTE have an earlier age of onset compared to other neurodegenerative disorders such as AD.<sup>1,9</sup>

This review will discuss the available literatures linking concussion and ALS and AD.

## Concussion and Subconcussive Impacts

Concussion is the transient distortion of the function of the brain secondary to acceleration and deceleration forces which could be linear or rotational, causing the brain to elongate and deform. As a result, blood vessels and individual cells are stretched and membrane permeability is altered. This alteration causes changes in ion concentrations (extracellular and intracellular) and blood flow to the cerebrum. It also disrupts the blood-brain barrier, and the metabolism of glucose.<sup>9,12</sup>

A subconcussive impact is a force effect on the brain that does not lead to symptoms and acute morbidity (as linked with concussion) but is associated with cortical dysfunction that is clinically silent.<sup>12,13</sup> The impacts are linked with variations in the integrity of white matter tracts on neuroimaging where widespread alterations in axial and radial diffusivity could be seen in the affected regions.<sup>13</sup> Repetitive mTBI, mTBI, and repetitive subconcussive head trauma are common in military personnel, domestic abused victims, and contact sport athletes.<sup>1</sup>

Presently, there is no objective clinical test for the diagnosis of concussion because the features are less obvious on physical examination. There are, however, tools used in the clinical setting that can assess the impact of concussion (e.g., balance assessment tools, symptom scales, and computerized neurocognitive tests). Absence of an objective test in diagnosing concussion sometimes leads to skepticism when confirming the presence or absence of concussion.<sup>12,14</sup>

### Neuropathological Findings—Linking Concussion to Neurodegeneration

Interestingly, although there is a paucity of neuropathological findings associated with acute mTBI, petechial hemorrhage and clusters of microglial cells have been seen less than 24 hours post-mTBI following a stretch of the microvascular structures. The numerous retraction bulbs of axons and destruction of myelin are suggested to be a result of acceleration and deceleration forces. Numerous axonal retraction bulbs and myelin destruction were found in variable regions likely to have been exposed to the most acceleration and deceleration forces.<sup>15</sup>

### Neurometabolic Cascade—Linking Concussion to Neurodegeneration

Biochemical injury to the brain during concussion sets a neurometabolic cascade where there is rapid release of neurotransmitters with potassium ions efflux and sodium ions influx leading to an increase in the concentration of intra-axonal calcium. This then turns on protease calpain and stimulates calpain-mediated breakdown of the cytoskeletal proteins which can result in irreversible axonal pathology. A rise in intra-axonal calcium also enhances the release of glutamate, thereby activating N-methyl-D-aspartate receptors leading to depolarization of neurons. Glucose consumption is thus increased to restore balance of ions and this depletes energy stores resulting in the production of lactate acidosis, oxidative metabolism impairment, and cerebral edema. At the site of the injury, there is swelling and disconnection of axons which is more prominent at the white and grey matter interface in the deep gyri.<sup>15</sup>

Sport-related concussion, seen in athletes, is a very common form of TBI.<sup>8</sup> It is known that concussion affects all cell compartments; however, axons are particularly vulnerable to shear injury because of their high membrane-to-cytoplasm ratio and their increased length.<sup>9</sup> Neuronal apoptosis around perivascular regions occurs after mTBI, which signifies

cerebral vascular injury, presenting with symptoms seen in ALS or AD such as headache, muscle cramps, cognitive impairment, limbs weakness, behavioral and sensorimotor deficits, sleep disturbances, and neuropsychiatric problems such as irritability, emotional lability, and loss of consciousness if severe<sup>15,16</sup> (→ Fig. 1).

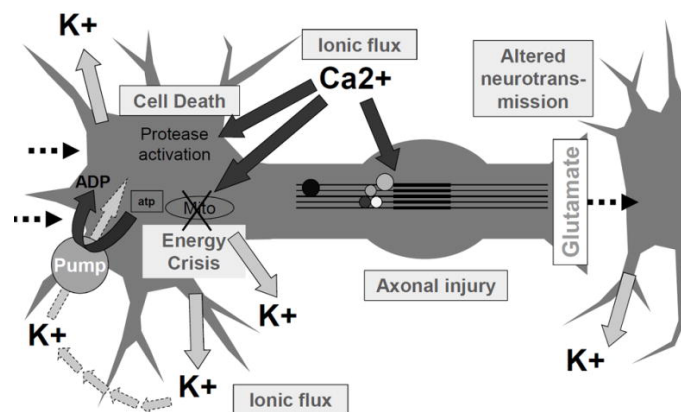
### Does Concussion Increase Risk for Neurodegenerative Disorders such as ALS and AD?

Neurodegenerative disorders are multifactorial diseases that affect the neurons in the nervous system. They have no specific etiology, however, studies have suggested the role of TBI as a primary risk factor secondary to similar nature of their pathologies.<sup>7</sup> Intriguingly, several possible explanations have been proposed in the pathological mechanisms that lead to the development of some neurodegenerative disorders (such as ALS and AD) and concussion but the two major events are deposition of tau proteins (abnormal microtubule proteins) and neuroinflammation.<sup>17</sup>

Various pathophysiologic mechanisms that could trigger the molecular pathways exist resulting in neurodegeneration. These ranges from glutamate excitotoxicity pathways and inflammatory pathways (which leads to a rise in the metabolic demands of microglia cells and neurons), to mitochondrial function via the oxidative pathways<sup>18</sup> (→ Fig. 2).

mTBI could lead to myelin sheath decompaction and fragmentation, it could also result in demyelination thus decreasing the integrity of the white matter. Although detection of damage to white matter remains exigent, atrophy of the white matter is linked to cognitive deficit indicating the progression of neurodegenerative disease.<sup>10,16</sup> Intercellular structural changes after TBI (for example, changes in structural support molecules and tau protein aggregation) have been linked as possible pathological mechanisms in the development of AD and ALS.<sup>12</sup>

**Neurometabolic Cascade of mTBI**



**Fig. 1** Neurometabolic cascade of concussion (Giza CC, Hovda DA. The new neurometabolic cascade of concussion. *Neurosurgery* 2014;75(4):S24-S33).

### Chronic Pathophysiology

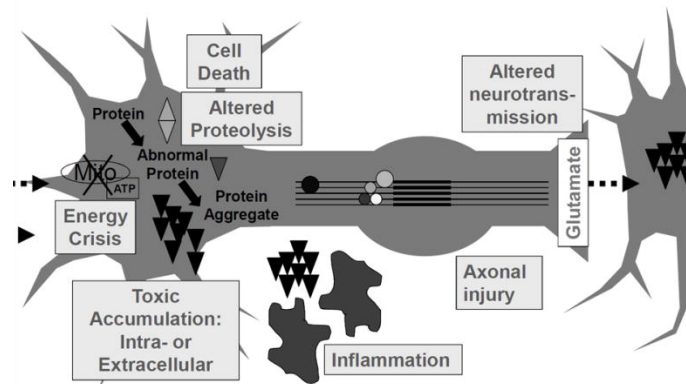


Fig. 2 Possible association between the pathophysiology of acute concussion and neurodegeneration (Giza and Hovda, 2014).

### Does Repetitive Concussion Increase Risk for Neurodegenerative Disorders such as ALS and AD?

Neurodegenerative changes in AD with increase tau pathology in the brain is seen in humans following a repetitive impact-induced concussion.<sup>17</sup> Repetitive mTBI is also linked to neurodegenerative changes not limited to behavioral, cognitive, and sensorimotor deficits.<sup>19</sup> The pathophysiological events of repetitive multiple mTBI can be unveiled with the use of cerebrospinal fluid and blood markers.<sup>20</sup> A study reported changes in the cytoskeletal proteins of the hippocampus and cortex and increase in cellular markers linked in patients with AD following repetitive mTBI. No changes were seen following a single injury in similar patients. Symptoms of repetitive mTBI includes aggression, irritability, difficulty in concentrating, short-term memory loss, suicidal tendencies, impulsivity, sleep problems, and chronic neurological diseases sequelae.<sup>21,22</sup>

Repetitive concussions are common in sports. While CTE has been implicated, it has also been shown to be linked with cases of AD, Lewy body disease, and ALS. Although a study examining effect of repetitive mTBI 2 years postinjury reported no association between repetitive mTBI and  $\beta$ -amyloid accumulation or abnormal tau proteins, other studies have shown the effect of repetitive mTBI on the deposition and accumulation of  $\beta$ -amyloid and tau protein, respectively.<sup>21</sup> Athletes and some military personnel are more prone to the long-term deleterious effects of mTBI during recovery. This is secondary to repetitive trauma and increased impacts athletes are subjected to during physical exertion. Several markers of acute injury to axons following repetitive impacts during a boxing match was reported in a study.<sup>14,20</sup>

An increase in risk of neurodegenerative disease such as AD can be dependent on the interval between repetitive mTBIs. A single mTBI could lead to a short duration of vulnerability of the cerebrum with sensitization of the brain to a subsequent injury. This can lead to a cumulative and extensive damage. Although there is a deficit in clinical data in this area, an animal model study showed that intervals between

repeat mTBI have an effect in the duration of depression of the metabolism of cerebral glucose in young male rats. After a single mTBI, there is recovery in deficits of metabolism within 3 days. However, a sustained second-hit mTBI leads to an extended period of hypometabolism of the cerebrum that is longer, this possibly explains the heterogeneity in future risk for neurodegenerative disease in patients with repeat mTBI.<sup>23</sup>

In animal models of repeated mTBI, novel therapeutic interventions are easily developed following a rapid insight to understanding repeated concussive injury and its pathophysiological mechanisms. That of clinical studies in humans, however, suggests that repeated mTBI neuropathological changes evolve over a long period ranging to years, hence an expensive and complex research layout is required.<sup>19</sup>

Modeling repetitive mTBI-dependent tau pathology can be difficult. The summative effect of repetitive mTBI can be investigated with the use of histological techniques to detect subtle changes in structure such as dendrites and axonal disruption, modifications of selective proteins posttransnationally, and variation in expression.<sup>19,21</sup>

### Amyotrophic Lateral Sclerosis and Concussion

ALS, also known as Lou Gehrig's disease, is a progressive neurodegenerative disease that causes degeneration of upper and motor neurons, resulting to a debilitating voluntary muscle paralysis till progression to death at about 2 to 5 years of diagnosis. The World Health Organization classifies ALS as a major subset of motor neuron disease. It has a point prevalence of about 5 per 100,000 persons.<sup>7,24-26</sup>

About 10% of sporadic ALS and two-thirds of familial ALS have been linked to genetics while about 90% of sporadic ALS etiology is unknown. FUS (protein coding gene), C9ORF72, TDP-43 (transactive response DNA binding protein 43 kDa), and superoxide dismutase 1 (SOD1) gene mutation have been implicated in familial ALS which varies in duration of the disease and age of onset. C9ORF72 repeat expansions are

presently the major genetic cause of ALS. The accumulation of a protein named TDP-43 is a major feature that contributes to the pathology of ALS.<sup>27,28</sup>

While some reports have inferred that the pathological findings of ALS is an extension of CTE, other studies have suggested that a higher risk of ALS is associated with head trauma with inconclusive details.<sup>7,29</sup> Meta-analysis studies have also linked ALS with previous head traumas which occurred at least 5 years before ALS diagnosis.<sup>7</sup>

Interestingly, while a study on Swedish population found no association between ALS and severe head injury, repetitive head injuries, or head injury subtypes, recent reports on humans have shown an unexpectedly high ALS incidence and mortality among professional Italian footballers. This was hypothesized that the increase risk of ALS is associated with repeated neurotrauma sustained while heading the ball during a match.<sup>30,31</sup> A study on retired National Football League players reported a four times increase in ALS mortality compared to the general population.<sup>7</sup> Another study on U.S. veterans reported an increased risk of ALS in those who sustained injury to the head compared to the other veterans without head injuries. A further supporting evidence between ALS and TBI reported not only a significantly increased risk of ALS in individuals with history of head injury in the previous 10 years, but also an 11-fold increase in risk in individuals with multiple head injuries within that time frame.<sup>32</sup>

In an animal model study, evidence was found linking mTBI in rats with increased phosphorylated and cytoplasmic TDP-43, atrophy of the muscle and motor cortex, degeneration and disorganization of the corticospinal tract, and loss of spinal cord motor neurons. All which are suggestive of ALS.<sup>32</sup>

ALS and TBI have similar pathological findings. The major protein involved in the neuropathology of ALS, TDP-43, also play a role in the pathophysiology of patients with TBI. In addition, increased inflammation of microglial cells activity following head trauma (which is chronic and linked to an increased risk in ALS progression), is also reflective in TBI patients, thus suggesting a possible association between ALS and TBI.<sup>7</sup>

Although the findings above linked individuals exposed or have a history of TBI with ALS, the shortcomings of the available studies linking ALS and TBI is the failure to take into cognizant the subclassification of the TBI, that is, if the exposure was to mild, moderate, or severe TBI. A study, however, has suggested that moderate/severe TBI have no significant increase in the risk of ALS compared to mTBI.<sup>26</sup>

## Alzheimer's Disease and Concussion

The long-term effect of mTBI on AD remains vague and sparse but studies on ex-professional footballers show an increase in predisposition to mTBI compared to the general population, that is, they have a higher probability to be diagnosed with AD and have an earlier age onset of the disease.<sup>23</sup> mTBI and Alzheimer's dementia have common clinical symptoms despite the fact they seem to be two separate

disease processes which affects younger and elderly people, respectively.<sup>33</sup>

Amyloid- $\beta$  ( $A\beta$ ) peptides play a key role in the pathophysiology in AD.  $A\beta$  peptide is cleaved from amyloid precursor protein (APP), which is a fast axonal transport marker. A study performed with immunohistochemistry on postmortem cases with mTBI showed APP-immunoreactive multifocal injury of the axons in the fornix. Fascinatingly, disruption of axonal transport has been implicated in  $A\beta$  formation and APP processing in AD.  $A\beta$  and APP have also been associated with clathrin-mediated endocytosis. A study has reported the potential mechanism of mTBI in reducing the thickness of the cortex implicating the genetic pathway linked to AD such as inflammation, cholesterol clathrin-mediated endocytosis signaling, and immune response.<sup>15,34,35</sup>

$A\beta$  oligomers and hyperphosphorylation are known neurodegenerative disease markers that can be promptly activated immediately post-TBI and significantly progress with time.<sup>16</sup> Pathological changes within the hippocampus have also been implicated in AD. Experimental animal models have shown the sensitivity of the hippocampus to mTBI. APOE E4 has been shown to affect  $\beta$ -amyloid pathway. It is involved in  $A\beta$  clearance. A positive correlation has been shown between individuals with history of TBI and those tested positive for the ApoE e4 gene.<sup>7,36</sup>

The role of head injury in the etiology of mild cognitive impairment or AD is explicit. However, it is associated with irreversible cognitive deficits. Neurofilaments redistribution secondary to the head rotational acceleration and genetic vulnerability after TBI has also be linked in nonathletes. The extent of head injury varies directly to the magnitude of the risk of developing AD, hence, head injury involving loss of consciousness is twice the risk of developing AD compared to that without loss of consciousness. Interestingly, there is also a significant higher risk in patients with head injury in the absence of loss of consciousness compared to patients with no head injury.<sup>7</sup>

The overlapping features of the neuropathology of AD and mTBI infer a possible interaction of the pathological proteins seen in these two conditions. Neurofibrillary tangles ( $A\beta$  neuritic plaques and phosphorylated tau) and widespread neuronal loss are seen in AD cases. Brain injured animal model also showed abrupt increase in tau pathology secondary to controlled impact on the cortex.<sup>17</sup> Athletes in position delineated for increase in mTBI frequency were found to have a higher prevalence of AD and a tremendous higher risk among those with increased numbers of prior mTBI. Such injuries have also been linked with increased deposition of  $A\beta$  protein, especially at an older age when postmortem examinations are done.<sup>23</sup>

## Conclusion

mTBI constitutes majority of brain injuries. However, studies have focused mostly on moderate-to-severe TBI as highlighted above with inconclusive and paucity of studies linking concussion and neurodegenerative disorders. Although, it is

highly probable that repetitive concussion (mTBI) and sub-concussive head injuries may be risk factors for ALS and AD from this review. It will be imperative therefore to conduct more research with a focus on mTBI and its association with ALS and AD.

#### Funding

None.

#### Conflict of Interest

None declared.

#### Acknowledgment

The authors thank Dr. Simon Dyall for reviewing this work.

#### References

- 1 Steven P Broglio, James T. Eckner, Henry L Paulson JSK. Cognitive decline and aging: the role of concussive and sub-concussive impacts. *Exerc Sport Sci Rev* 2012;40(3):138–144
- 2 Tagge CA, Fisher AM, Minaeva OV, et al. Concussion, microvascular injury, and early tauopathy in young athletes after impact head injury and an impact concussion mouse model. *Brain* 2018;141(2):422–458
- 3 Steenerson K, Starling AJ. Pathophysiology of sports-related concussion. *Neurol Clin* 2017;35(3):403–408
- 4 LoBue C, Cullum CM, Didehbani N, et al. Neurodegenerative dementias after traumatic brain injury. *J Neuropsychiatry Clin Neurosci* 2018;30(1):7–13
- 5 Oliver JM, Anzalone AJ, Turner SM. Protection before impact: the potential neuroprotective role of nutritional supplementation in sports-related head trauma. *Sports Med* 2018;48(Suppl 1):39–52
- 6 Sundman MH, Hall EE, Chen N-K. Examining the relationship between head trauma and neurodegenerative disease: a review of epidemiology, pathology and neuroimaging techniques. *J Alzheimers Dis Parkinsonism* 2014;4:137
- 7 Rosenman M, Gero J, Al-Chalabi A, et al. Absence of chronic traumatic encephalopathy in retired football players with multiple concussions and neurological symptomatology. *Amyotroph Lateral Scler Front Degener* 2018;7(4):1–10
- 8 Noble JM, Hesdorffer DC. Sport-related concussions: a review of epidemiology, challenges in diagnosis, and potential risk factors. *Neuropsychol Rev* 2013;23(4):273–284
- 9 Mckee A. Military TBI. *Alzheimers Dement J Alzheimers Assoc* 2014;10(3 0):S242–S253
- 10 Shin SS, Pathak S, Presson N, et al. Detection of white matter injury in concussion using high-definition fiber tractography. *Prog Neurol Surg* 2014;28:86–93
- 11 McKee AC, Robinson ME. Military-related traumatic brain injury and neurodegeneration. *Alzheimers Dement* 2014;10(3(Suppl)):S242–S253
- 12 Aging and Cognitive Decline as a Result of Concussive Impacts. Manuscript A, Decline C, Impacts S. 2013;40(3):138–144. [10.1097/JES.0b013e3182524273](https://doi.org/10.1097/JES.0b013e3182524273). Cognitive
- 13 Moore RD, Lepine J, Ellemberg D. The independent influence of concussive and sub-concussive impacts on soccer players' neurophysiological and neuropsychological function. *Int J Psychophysiol* 2017;112:22–30
- 14 Papa L. Potential blood-based biomarkers for concussion. *Sports Med Arthrosc Rev* 2016;24(3):108–115
- 15 Ling H, Hardy J, Zetterberg H. Neurological consequences of traumatic brain injuries in sports. *Mol Cell Neurosci* 2015;66(Pt B):114–122
- 16 Logsdon AF, Lucke-wold BP, Turner RC, Huber JD, Rosen CL, Simpkins JW. Role of microvascular disruption in brain damage from traumatic brain injury. *Compr Physiol* 2015;5(3):1147–1160
- 17 Chen M, Song H, Cui J, et al. Proteomic profiling of mouse brains exposed to blast-induced mild traumatic brain injury reveals changes in axonal proteins and phosphorylated tau. *J Alzheimers Dis* 2018;66(2):751–773
- 18 Pupillo E, Messina P, Logroscino G, et al; EURALS Consortium. Trauma and amyotrophic lateral sclerosis: a case-control study from a population-based registry. *Eur J Neurol* 2012;19(12):1509–1517
- 19 Broussard JI, Acion L, De Jesús-cortés H, et al. Repeated mild traumatic brain injury produces neuroinflammation, anxiety-like behaviour and impaired spatial memory in mice. *Brain Inj* ;32(1):113–122
- 20 DeKosky ST, Asken BM. Injury cascades in TBI-related neurodegeneration. *Brain Inj* 2017;31(9):1177–1182
- 21 Mouzon BC, Bachmeier C, Ojo JO, et al. Lifelong behavioral and neuropathological consequences of repetitive mild traumatic brain injury. *Ann Clin Transl Neurol* 2017;5(1):64–80
- 22 Dashnaw ML, Petraglia AL, Bailes JE. The biophysics of head impact. *Neurosurg Focus* 2012;33(6):E5, 1–9
- 23 Grant DA, Serpa R, Moattari CR, et al. Repeat mild traumatic brain injury in adolescent rats increases subsequent  $\beta$ -amyloid pathogenesis. *J Neurotrauma* 2018;35(1):94–104
- 24 Al-Chalabi A, Hardiman O, Kiernan MC, Chiò A, Rix-Brooks B, van den Berg LH. Amyotrophic lateral sclerosis: moving towards a new classification system. *Lancet Neurol* 2016;15(11):1182–1194
- 25 Fang T, Al Khleifat A, Stahl DR, et al; Uk-Mnd LicalS. Comparison of the King's and MiToS staging systems for ALS. *Amyotroph Lateral Scler Frontotemporal Degener* 2017;18(3–4):227–232
- 26 Brain V. Defense and Veterans brain injury centre information paper on Amyotrophic Lateral Sclerosis and Traumatic Brain Injury issue. *Info Pap* 2018;1:2014–2017
- 27 Cykowski MD, Powell SZ, Peterson LE, et al. Clinical significance of TDP-43 neuropathology in amyotrophic lateral sclerosis. *J Neuropathol Exp Neurol* 2017;76(5):402–413
- 28 Tiryaki E, Horak HA. ALS and other motor neuron diseases. *Am Academy Neurol* 2014;20(5):1185–1207
- 29 Armon C, Nelson LM. Is head trauma a risk factor for amyotrophic lateral sclerosis? An evidence based review. *Amyotroph Lateral Scler* 2012;13(4):351–356
- 30 Peters TL, Fang F, Weibull CE, Sandler DP, Kamel F, Ye W. Severe head injury and amyotrophic lateral sclerosis. *Amyotroph Lateral Scler Frontotemporal Degener* 2013;14(4):267–272
- 31 Rosenman M, Gero J. Evolving designs by generating useful complex gene structures. *Evol Comput* 1999;166(7):345–364
- 32 Wright DK, Liu S, van der Poel C, et al. Traumatic brain injury results in cellular, structural and functional changes resembling motor neuron disease. *Cereb Cortex* 2017;27(9):4503–4515
- 33 Fakhran S, Alhilali L. Neurodegenerative changes after mild traumatic brain injury. *Prog Neurol Surg* 2014;28:234–242
- 34 Nelson EE, Guyer AE. The development of the ventral prefrontal cortex and social flexibility. *Dev Cogn Neurosci* 2011;1(3):233–245
- 35 Hayes JP, Logue MW, Sadeh N, et al. Mild traumatic brain injury is associated with reduced cortical thickness in those at risk for Alzheimer's disease. *Brain* 2017;140(3):813–825
- 36 Tateno A, Sakayori T, Takizawa Y, Yamamoto K, Minagawa K, Okubo Y. A case of Alzheimer's disease following mild traumatic brain injury. *Gen Hosp Psychiatry* 2015;37(1):97.e7–97.e9