

Nasal Dorsum Reduction Simultaneous to Orthognathic Surgery: A Proof-of-Concept Report

Joan Birbe Foraster^{1,2}

¹Facial Plastic Surgery, Private Practice, Barcelona, Spain

²Clinica B I R B E, Private Practice, Barcelona, Spain

Address for correspondence Joan Birbe Foraster, MD, DDS, PhD, Facial Plastic Surgery, Private Practice, Lincoln 29, Barcelona 08006, Spain (e-mail: doctor@birbe.org).

Facial Plast Surg 2021;37:646–650.

Abstract

This report describes a technique to reduce nasal dorsum excess simultaneously to orthognathic surgery (OS) through a Le Fort I osteotomy. It avoids the need to change from endonasal intubation to intraoral intubation. It also eliminates the need to open the dorsum, preserving the integrity of the triangular cartilages at the nasal dorsum keystone area, avoiding iatrogenic nasal dorsum deformities. A sample of five patients referred for OS who also sought improvement of their nasal aesthetics was selected to implement the technique. The aim of this proof-of-concept study was to evaluate the clinical outcome of simultaneous OS and nasal dorsum reduction. The following measurements were used to evaluate the procedure: patient satisfaction with a visual analog scale, photographic assessment, additional operative time, and complications related to the procedure. The average patient age was 23 years (range: 19–32 years). Three patients were women and two were men. In all patients, a high degree of patient satisfaction was observed with the aesthetic result of the nose and OS. No undesirable side effects or surgical complications occurred in any case. Total surgery time was increased by an average of 25 minutes. Nasal dorsum reduction through a Le Fort I approach during OS is a reliable and effective method to reduce nasal dorsum excess in patients seeking simultaneous OS and rhinoplasty.

Keywords

- ▶ rhinoplasty
- ▶ preservation rhinoplasty
- ▶ orthognathic surgery
- ▶ Le Fort I

The simultaneous correction of nasal deformities during orthognathic surgery (OS) is a long-time debated issue.^{1,2} While the simultaneous correction of chin deformities is well accepted, the simultaneous correction of nasal deformities is often avoided. As a consequence, the two surgical steps approach is often not well accepted by patients, leaving an uncorrected nasal deformity in a substantial percentage of patients. However, Le Fort I osteotomy provides an excellent exposure to the nasal base structures and offers an excellent opportunity for a simultaneous dentofacial and nasal deformities correction.

State-of-the-art OS involves not only bite correction but also a comprehensive management of functional and aesthetic disharmonies of the face. OS has evolved to an orthofacial surgery concept that implies the use of adjunctive cosmetic surgical concomitantly with OS.^{3,4}

Rhinoplasty techniques are also evolving. Preservation rhinoplasty is a well-described surgical technique to correct nasal dorsum excess by removing a high septal strip of cartilaginous nasal septum that allows in conjunction with lateral and transverse nasal osteotomies to push down the nasal septum without disturbing the anatomy of the nasal dorsum cartilages.^{5,6}

The aim of this report is to describe an innovative technique to reduce nasal dorsum excess in the context of a Le Fort I osteotomy, hence improving nasal aesthetics and dentofacial aesthetics.

An important drawback for simultaneous orthognathic and rhinoplasty is the cumbersome change of endonasal intubation for OS to intraoral intubation for rhinoplasty. Our

published online
March 11, 2021

Issue Theme Facial Plastic Surgery
Original Research; Guest Editors: Anthony P. Sclafani, MD, MBA, FACS, and Alwyn D'Souza, MBBS, FRCS Eng, FRCS (ORL-HNS)

© 2021, Thieme. All rights reserved.
Thieme Medical Publishers, Inc.,
333 Seventh Avenue, 18th Floor,
New York, NY 10001, USA

DOI <https://doi.org/10.1055/s-0041-1725938>.
ISSN 0736-6825.

technique can be performed without the need of having to change from endonasal to intraoral intubation.

Although the dentofacial deformity correction is in our center a primary indication for surgery, often patients seek a more comprehensive approach to their facial aesthetics and look for a single surgical correction of undesired facial traits.

A sample of five patients seeking correction of their dentofacial deformity and simultaneous nasal dorsum excess correction was selected to implement a new technique for nasal dorsum reduction through a Le Fort I approach.

Compliance with Ethical Standards

All procedures, including the assessment of data from human subjects, were in accordance with the ethical standards of the institutional and national research committee and the 1964 Declaration of Helsinki and its later amendments⁷ All five patients provided written informed consent before inclusion. Only data assessed at our center was used.

Patients

The standard virtual surgical planning software protocol (Dolphin three-dimensional surgery Imaging software) used at our center was used to plan the OS movements. Facial and oral pictures were taken in every patient and a comprehensive facial analysis was performed. The five patients included in our sample had nasal dorsum excess, long face, high mandibular plane angle, and a dental class II relationship.

All five subjects provided written informed consent before surgical treatment. The recruitment, treatment, and follow-up examinations of all patients were performed at our center from February 2018 to March 2019.

Inclusion Criteria

Patients with a nasal dorsum excess, long face, high mandibular plane angle, and a class II dental relationship were enrolled. Exclusion criteria were defined after analysis of a cone-beam computed tomography scan done to virtually plan the OS movements and to assess bony septal abnormalities, turbinate pathology, and sinus disease. High septal deviations or deflections can lead to postoperative dorsal distortion, asymmetry, and deviation. In such instances, we recommend to have the rhinoplasty as a separate procedure. Severe nasal asymmetries, previous rhinoplasty and patients needing changes other than lowering of the dorsum, were also excluding criteria.

Therapy

Patients were operated on under general anesthesia by the same surgeon and author of this article (J.B.F) who had more than 25 years of experience in OS and facial cosmetic surgery. Bimaxillary OS was performed in all patients, with endonasal intubation. Four patients had in addition a sliding advancement genioplasty. Mandible first protocol was used, and a standard bilateral sagittal split osteotomy was done. The mandible was repositioned with the help of a CAD-CAM printed intermediate splint. Rigid fixation was done using three 2 mm in diameter, 12 mm long bicortical screws (Osteomed) in each side. An incision of the maxilla vestibule

from canine to canine was made and subperiosteal dissection of the lateral maxillary walls, piriform rim, and pterygomaxillary fossa was done. A subnasal Le Fort I osteotomy was then made and the maxilla was mobilized. Using the access provided by the Le Fort I down fracture, careful nasal mucosa dissection from the nasal floor was accomplished. Vomer bone was resected all along the maxilla floor. Caudal septum cartilage was dissected free from the nasal mucosa on both sides of the nasal septum cartilage to the level of the planned caudal septal cartilage resection. A vertical nasal mucosa dissection pocket was then made from caudal septum at a level anterior to the ethmoid bone, to just below the nasal bones at the radix level. A vertical cut of the septal cartilage was made through the previously created nasal mucosa pocket (►Fig. 1). Lateral nasal osteotomies were performed using a reciprocating micro saw (Osteomed) through an intraoral approach, using the access provided by the Le Fort I osteotomy (►Fig. 2A and B). Percutaneous transverse nasal osteotomy was made with a 2mm nasal osteotome. Complete digital mobilization of the nasal pyramid was accomplished and a “push down” of the nasal dorsum according to the nasal dorsum preservation technique described by Saban et al.⁵ Two 4.0 PDS (polydioxanone) sutures were placed between the caudal septum and the maxillary floor, maintaining passively the pushed down dorsum in place. Then the maxilla was placed into occlusion using the final splint. Four 1.2 mm “L”-shaped (Osteomed) miniplates with four monocortical screws were used to rigidly fixate the mobilized maxilla into the planned position. Suturing of the incisions was done in a two-layer fashion, muscular and mucosa using 4.0 Vicryl. In case of a sliding genioplasty being planned, it was done at the beginning of the operation before OS. Occlusal splint was removed, occlusion checked, and a dynamic intermaxillary fixation was maintained with two to four guiding elastics. A thermo-plastic nasal splint was placed in the nasal dorsum. Doyle intranasal splints were placed and secured with 4.0 Vicryl sutures to the nasal septum. Once patients had been extubated, a cryotherapy face mask was applied to the face at a 13° to 14°C temperature, and maintained for 72 hours. The care of the patient was then transferred to recovery room. All patients were discharged 24 hours after surgery. Standard antibiotic and anti-inflammatory medication for OS was prescribed. Nasal vasoconstrictor was prescribed for 72 hours (oxymetazoline spray q 8h). Functional training with light guiding elastics and a soft diet was followed for 1 month.

Objective evaluation consisted of four parameters:

1. Improvement in nasal dorsum contour of the nose was readily illustrated in an objective manner. A line was drawn at the level where the nasal dorsum was planned to push down. Once the push-down maneuver was done, the painted line was objectively at the level of the new dorsum position.
2. Preoperative, intraoperative, and postoperative photographic evaluation: Preoperative images were used for facial diagnosis and treatment planning. Intraoperatively,

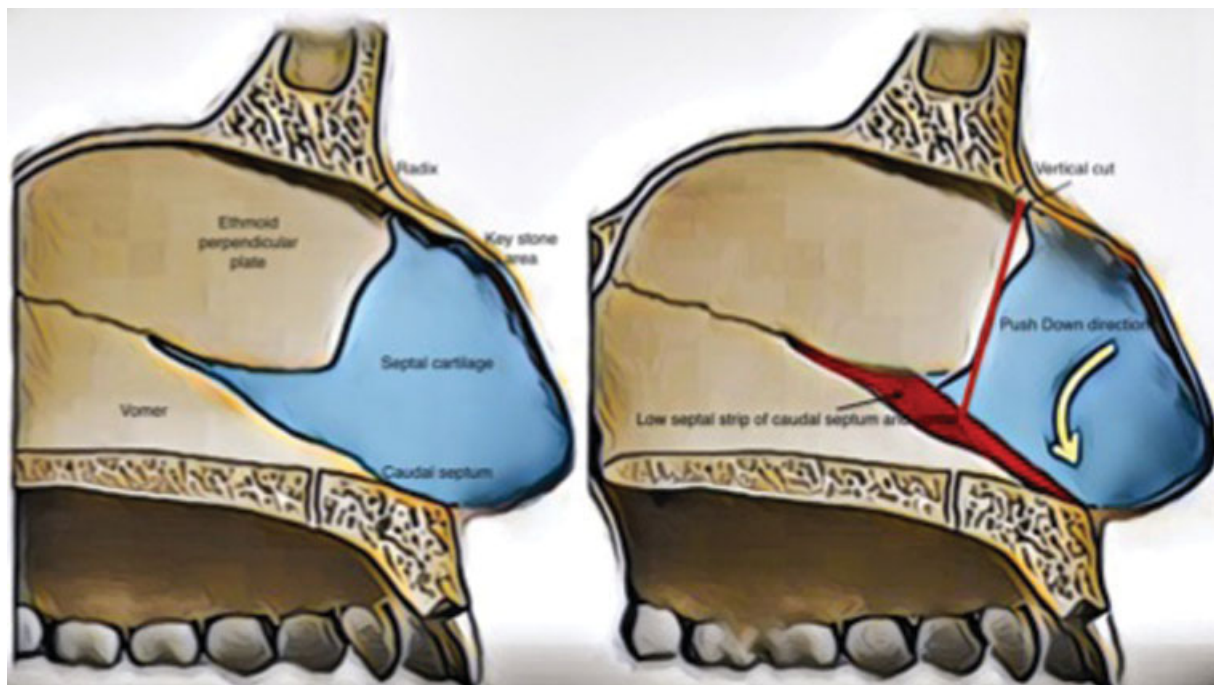


Fig. 1 Lateral nasal osteotomies were performed using a reciprocating micro saw (Osteomed) through an intraoral approach, using the access provided by the Le Fort I osteotomy.

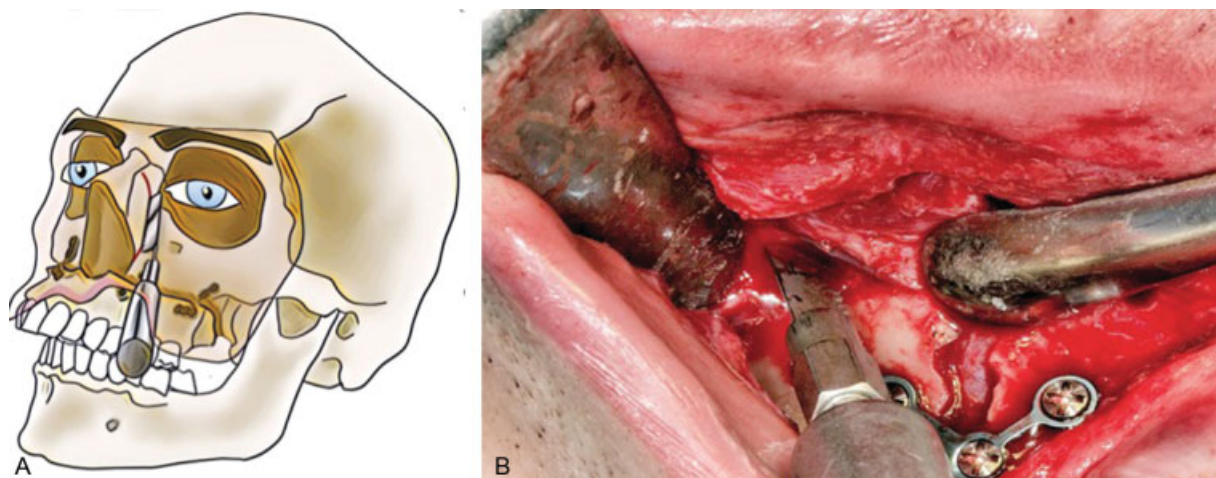


Fig. 2 (A and B) Percutaneous transverse nasal osteotomy was made with a 2 mm nasal osteotome.

- two photographs were taken at two time points: (1) immediately after push down of the dorsum, before maxilla repositioning and (2) immediately after completion of the surgery. Follow-up pictures were taken at 1- and 6-month follow-up to illustrate the immediate and long-term effects of the OS and nasal dorsum push down.
3. Additional operative time needed for nasal dorsum push-down procedure.
 4. Potential complications, including dorsum asymmetry, dorsum irregularities, nasal breathing difficulties.

A visual analog scale (VAS: 0–7) was used to evaluate patients' postoperative satisfaction with the surgical out-

come. Zero representing complete dissatisfaction and 7 representing maximum satisfaction.

Descriptive statistics were employed for quantitative analysis.

Results

Of 35 patients who underwent OS during a 12-month period, five underwent bimaxillary OS with simultaneous rhinoplasty using intraoral dorsum preservation rhinoplasty technique. In all five patients, the OS movement was advancement with counterclockwise rotation. In addition, four patients had a sliding genioplasty. Three patients were

Table 1 Demographic data, surgical procedure, increase of operative time, surgical complications, and VAS satisfaction score of studied sample

Patient	Gender/age(years)	Surgery type	Increase in operating time (min)	Complications	VAS score
1	F/19	bimax adv, CCW, chin, PR	26	None	7
2	F/25	bimax adv, CCW, chin, PR	32	None	6
3	M/27	bimax adv, CCW, chin, PR	24	None	6
4	F/23	bimax adv, CCW, chin, PR	22	None	7
5	M/34	bimax adv, CCW, PR	21	None	7

Abbreviations: adv, advancement; bimax, bimaxillary; CCW, counterclockwise rotation; F, female; M, male; VAS, visual analog scale.

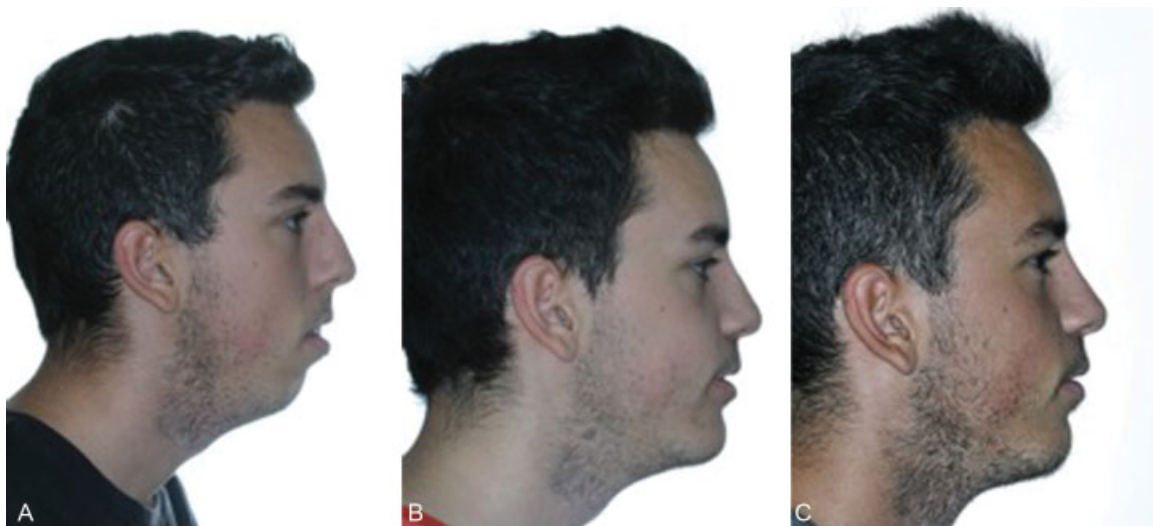women and two were men (►Table 1). The average patient age was 25.6 years (range: 19–34 years) A high degree of patient satisfaction with the result was registered with an average VAS satisfaction score of 6.6. No surgical complications occurred other than light bruising in the infraorbital and paranasal region. The average increase in operative time was 29.4 minutes (range: 20–42 minutes) (Table 1).

Photographic follow-up displayed the immediate, 1-month and 6-month effects of the nasal dorsum reduction through the Le Fort I approach (►Fig. 3).

Discussion

OS aims to correct dentofacial deformities functionally and aesthetically. There is a tendency to indicate OS for aesthetic surgery of the facial skeleton. Patients seek an orthofacial result more than an orthognathic result, giving for granted the bite problem is corrected, and there will be a substantial improvement in facial aesthetics. As so, many patients choose to have additional procedures simultaneously with OS.⁸ The literature supports the simultaneous performance of some additional aesthetic procedures, like genioplasty, while there is a controversy about simultaneous OS and rhinoplasty.⁹ Some of the reasons to not recommend them

is the cumbersome change of endonasal intubation to oral intubation to perform the rhinoplasty, or the distortion of nose aesthetics after maxillary OS due to facial edema and the changes in the nose due to OS.¹⁰ Airway management in patients with complex maxillofacial deformities can be a challenge to anesthesiologists. Submental intubation can be applied to bimaxillary OS with simultaneous rhinoplasty, as an alternative method to switching endotracheal tube from nasal to oral intubation, once the orthognathic procedure has been finished and before starting the rhinoplasty. However, we have found it is difficult for the patient to accept a submental incision and subsequent scar. In cases where there is a preservation nasal dorsum reduction, there is no need to change the intubation from nasal to oral. When nasal tip surgery is necessary, we prefer to change from nasal to oral intubation, at the end of the orthognathic procedure, having already performed the preservation nasal dorsum reduction. It is our experience that facial edema is minimum and does not distort nasal aesthetics, and that rigid maxilla fixation with four miniplates provides a stable foundation to the nose to perform a rhinoplasty. In the author experience, there is no justification to accept the feasibility of a sliding genioplasty to correct chin discrepancies after OS and do not apply the same reasoning for correction of nose deformities.

**Fig. 3** Pre- and postoperative images illustrate preoperative 1-month and 6-month postoperative effects on the nose.

However, preservation rhinoplasty (PR) techniques are well documented. Dorsal PR classical techniques is based on the endonasal resection of a high septal cartilaginous strip and ethmoid bone underneath the nasal bones. Through lateral and transverse osteotomies, then a “push-down” or “let-down” of the nasal dorsum can be easily done, without distorting the key stone area and thus avoiding iatrogenic deformities such as an open roof or an inverted V deformity of the nasal dorsum.¹¹ Our technique instead of using a high septal strip uses a low septal strip of caudal septum cartilage and vomer. A vertical cut from caudal septum to the junction of the septal cartilage below the radix, allows for, in conjunction with intraoral lateral osteotomies and percutaneous transverse osteotomies, performs a push down of the nasal dorsum. This technique does not need to change the intubation, and utilizes the excellent exposure provided by the Le Fort I approach to the base of the nose.

Nevertheless, an important drawback of this study is the small sample, which limits the possibility of drawing meaningful statistically significant conclusions. As such, proof-of-concept reports can be subject to a numerous bias distortion, and although a questionnaire is a valid research instrument, to help assess patients satisfaction, the answers of such questionnaires can also be affected by a bias.

The author suggests an innovative technique to lower the nasal dorsum through an intraoral approach, in the context of OS. An intraoral low septal strip resection of caudal cartilage and vomer, vertical cut to below radix, intraoral lateral nasal osteotomies, and percutaneous transverse osteotomy, allows for a push-down of the nasal dorsum, without the need to open the dorsum and maintaining endonasal intubation. The main limitation of this approach is that in cases where nose tip surgery is required, intubation should be changed from endonasal to oral. Nevertheless, the procedure is effective from the clinical point of view, minimally invasive, technically feasible thanks to the excellent exposure provided by the Le Fort I approach, and finally, it is

time efficient. With the limitations of this proof-of-concept study, we find no additional morbidity and high patient satisfaction.

Conflict of Interest

None declared.

References

- 1 Seah TE, Bellis H, Ilankovan V. Orthognathic patients with nasal deformities: case for simultaneous orthognathic surgery and rhinoplasty. *Br J Oral Maxillofac Surg* 2012;50(01):55–59
- 2 Waite PD, Matukas VJ, Sarver DM. Simultaneous rhinoplasty procedures in orthognathic surgery. *Int J Oral Maxillofac Surg* 1988;17(05):298–302
- 3 Sarver DM, Rousso DR. Plastic surgery combined with orthodontic and orthognathic procedures. *Am J Orthod Dentofacial Orthop* 2004;126(03):305–307
- 4 O’Ryan F, Lassetter J. Optimizing facial esthetics in the orthognathic surgery patient. *J Oral Maxillofac Surg* 2011;69(03):702–715
- 5 Saban Y, Daniel RK, Polselli R, Trapasso M, Palhazi P. Dorsal preservation: the push down technique reassessed. *Aesthet Surg J* 2018;38(02):117–131
- 6 Daniel RK. The preservation rhinoplasty: a new rhinoplasty revolution. *Aesthet Surg J* 2018;38(02):228–229
- 7 Mejia J World Medical Association Declaration of Helsinki - Ethical Principles for Medical Research Involving Human Subjects. 2013. Accessed June 20, 2016 at: <http://www.wma.net/en/30publications/10policies/b3/>
- 8 Mohamed WV, Perenack JD. Aesthetic adjuncts with orthognathic surgery. *Oral Maxillofac Surg Clin North Am* 2014;26(04):573–585
- 9 Waite PD, Matukas VJ, Sarver DM. Simultaneous rhinoplasty procedures in orthognathic surgery. *Int J Oral Maxillofac Surg* 1988;17(05):298–302
- 10 Raffaini M, Cocconi R, Spinelli G, Agostini T. Simultaneous Rhinoseptoplasty and orthognathic surgery: outcome analysis of 250 consecutive patients using a modified Le Fort I osteotomy. *Aesthetic Plast Surg* 2018;42(04):1090–1100
- 11 Saban Y, Çakir B, Daniel R, Palhazi P. Preservation Rhinoplasty. 1st edition Bio Offset: Istanbul; 2018